

Oncology

Renal Extra Skeletal Mesenchymal Chondrosarcoma: A Case Report



Mehdi Salehipour^a, Masood Hosseinzadeh^b, Afshin Molaei Sisakhti^a,
Vahid Abdol Mohammadi Parvin^a, Amin Sadraei^a, Ali Adib^{c,*}

^a Department of Urology, Shiraz University of Medical Sciences, Shiraz, Iran

^b Department of Pathology, Shiraz University of Medical Science, Shiraz, Iran

^c Student Research Committee, Shiraz University of Medical Sciences, Shiraz, Iran

ARTICLE INFO

Article history:

Received 17 November 2016

Received in revised form

15 December 2016

Accepted 28 December 2016

Keywords:

Extra skeletal chondrosarcoma

Kidney

Mesenchymal chondrosarcoma

Renal mass

ABSTRACT

Primary mesenchymal chondrosarcoma of the Kidney is an extremely rare entity and very few cases have been reported in literature. We report a 22-year-old male with a right renal mass; after radical nephrectomy, pathologic examination revealed primary extra skeletal mesenchymal chondrosarcoma.

© 2017 The Authors. Published by Elsevier Inc. This is an open access article under the CC BY-NC-ND license (<http://creativecommons.org/licenses/by-nc-nd/4.0/>).

Introduction

Mesenchymal chondrosarcoma (MC) is a quite rare disease. Bone is the most common organ affected by MC, but one-third of mesenchymal chondrosarcomas originate in the soft tissue and other organs.¹ Most cases of extra skeletal mesenchymal chondrosarcomas are seen in the head and neck region followed by the extremities and trunk.²

Herein, we report a case of MC of the Kidney in a young male. To the best of our knowledge, only nine cases of MC of the kidney have been described in English literature so far.³

Case presentation

A 22-year-old male presented with a 2-month history of vague right flank pain that exacerbated since 2 weeks prior to admission. The patient had a negative history of gross hematuria, trauma and fever. His past medical history was unremarkable. Physical examination revealed mild right costovertebral angle tenderness without abdominal organomegaly. The laboratory findings were as follows:

Hemoglobin = 15.6 g/dL
White blood cell = $6.8 \times 10^3 / \text{mm}^3$
Neutrophil = 51.4%
Lymphocyte = 43.3%
Mixed = 5.3%
Platelet = $256 \times 10^3 / \text{mm}^3$

Blood urea nitrogen = 16 mg/dL
Creatinine = 0.9 mg/dL
Na = 138 mmol/L
K = 4 mmol/L
Erythrocyte sedimentation rate = 3 mm/hr

Liver function test and chest X-ray were normal. Urinalysis showed microhematuria.

Abdominopelvic Ultrasonography showed a large cystic structure (90 mm in diameter) located in the posterolateral portion of the mid pole of the right kidney with large areas of calcification and significant wall thickening. Abdominopelvic CT scan demonstrated a large heterogeneous mass with some areas of coarse calcification in the mid part of the right kidney that enhanced after administration of contrast material (Fig. 1).

Thus, with priminally diagnosis of renal malignancy the patient underwent right radical nephrectomy through a mild line

* Corresponding author. Medical School, Zand Street, Shiraz 7134845794, Iran.
Fax: +98 7132330724.

E-mail address: aliadibmail@gmail.com (A. Adib).

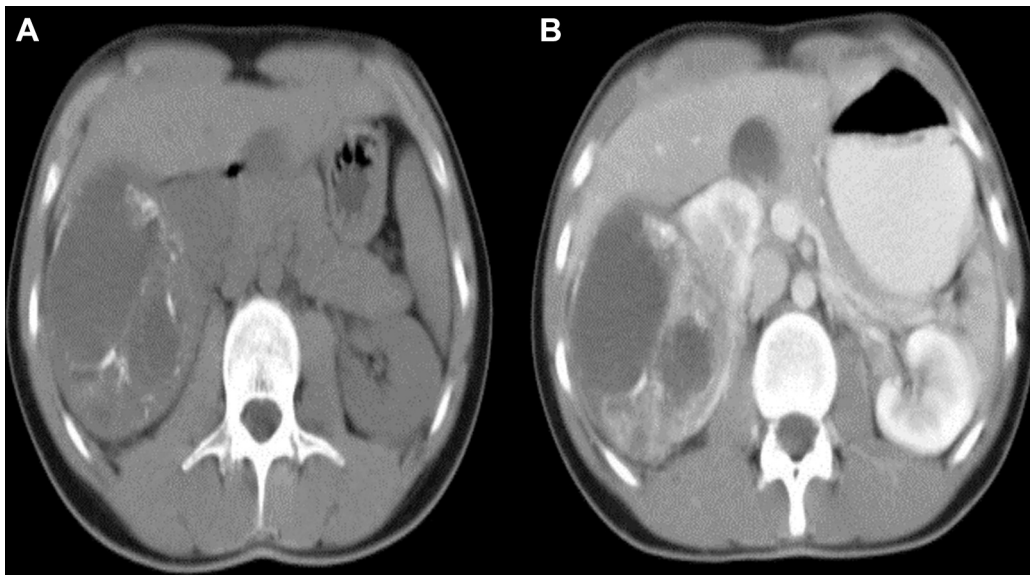


Figure 1. Abdominal CT scan showed: (A) a heterogeneous mass in the mid pole right kidney with some areas of calcification. (B) The mass enhanced after contrast material administration.

abdominal incision. Histological examination indicated a hypercellular tumor with round to spindle shaped hyperchromatic cells with indistinct cytoplasmic borders and inconspicuous nucleoli (Fig. 2A). There were areas of abnormal tortuous blood vessels (Hemangiopericystic pattern like) (Fig. 2B). Islands of mature and immature cartilage with ossification foci were also seen (Fig. 2C). There were foci of necrosis (10–20). There was no sign of invasion to the capsule, lymphovascular, and perineural. The ureter and vascular margin were free of tumor.

Immunohistochemical (IHC) staining showed:

BCL2: Positive, CD10: Negative, CD34: Negative, C.Kit: Negative, Cytokeratin (AE1, AE3): Negative, Desmin (D33): Negative, Ki67 (Mib-1) = 30%

LDA (2Bt1 + PD7/26): negative, MICS (CD99) (12E7): Positive, MODY (5-8A): Negative, S100: Negative, SMA (1AY): Negative, Vimentin (Vim 3 BY): Positive, WTT (6F-H2): Negative

IHC findings on paraffin-embedded formalin-fixed tissue were in favor of MC.

Discussion

MC is a high grade malignancy of the bone and soft tissue. It represents only 2% of all chondrosarcomas.³ MC of the kidney is a very rare entity. In literature review, only nine cases of it have been reported so far. The clinical manifestations of renal MC (RMC) are non-specific, among which pain, microscopic or gross hematuria, and mass are the most common features. Imaging study of choice for evaluating of any renal mass is CT scan. In CT scan, RMC is usually seen as soft tissue masses with dense and granular calcification; however, they may also present as heterogeneous and hypodense masses without calcification.² The definitive diagnosis is based on the histopathologic findings. MC has a biphasic pattern composed of islets of well-differentiated cartilage surrounded by undifferentiated spindle mesenchymal cells. In addition, Immunohistochemical markers aid in diagnosis of MC.⁴

Because of the rarity of RMC and lack of appropriate clinical studies, there are no optimal treatment protocols for management of RMC. Although the role of systemic chemotherapy or radiotherapy has not been evaluated in RMC, it seems that complete

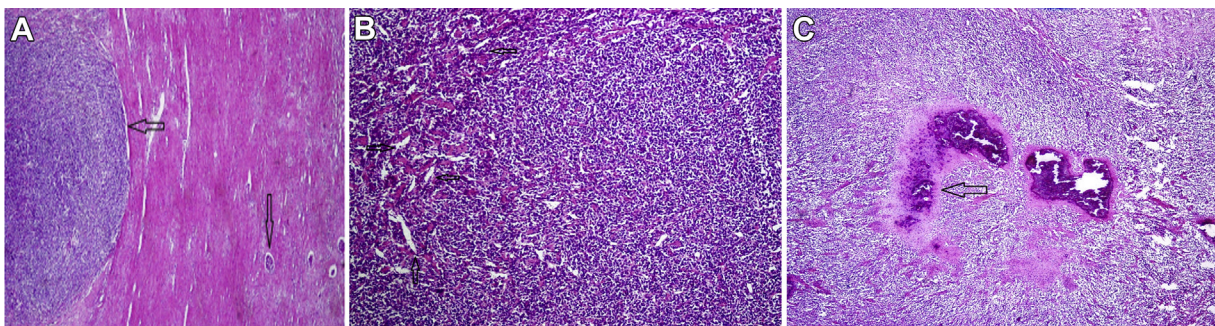


Figure 2. (A) Sections from renal mass (right side: renal parenchyma, vertical arrow) show hypercellular tumor with small and spindle hyperchromatic cells (left side, horizontal arrow); H&E $\times 100$. (B) Sections from renal mass show hypercellular tumor with many small stag-horn blood vessel; H&E $\times 250$. (C) Sections from the renal tumor show cartilage formation (arrow); H&E $\times 250$.

surgical resection with clear margins and adjuvant chemotherapy increase the patient's survival rate.^{3,5} Recommended chemotherapy regimen for MC is a combination of vincristine, doxorubicin and cyclophosphamide alternating with ifosfamide and etoposide. Increased expression of the platelet-derived growth factor receptor α (PDGFR- α) was reported in malignant mesenchymal cells, so target agents such as dasatinib, imatinib, sorafenib and sunitinib that inhibit PDGFR- α function may play a role in treatment of MC.⁵

The prognosis of MC of the bone and soft tissue is poor. Because of the rarity of RMC, the prognosis for this entity is unknown. So regular follow-up is mandatory for early detection of local recurrence and distant metastases.

Conclusion

Renal MC is very rare. Although it is difficult to say with certainty, complete surgical resection and adjuvant chemotherapy may improve the outcome of the patient. Due to aggressive behavior and tendency toward metastasis, regular follow-up is recommended.

Conflicts of interest

The authors declare that they have no conflict of interest.

Acknowledgements

The authors would like to thank Shiraz University of Medical Sciences, Shiraz, Iran and also Center for Development of Clinical Research of Nemazee Hospital and Dr. Nasrin Shokrpour for editorial assistance.

References

1. Xu H, Shao M, Sun H, Li S. Primary mesenchymal chondrosarcoma of the kidney with synchronous implant and infiltrating urothelial carcinoma of the ureter. *Diagn Pathol.* 2012;7(1):1.
2. Chen D, Ye Z, Wu X, et al. Primary mesenchymal chondrosarcoma with bilateral kidney invasion and calcification in renal pelvis: a case report and review of the literature. *Oncol Lett.* 2015;10(2):1075–1078.
3. Gherman V, Tomuleasa C, Bungardean C, et al. Management of renal extra-skeletal mesenchymal chondrosarcoma. *BMC Surg.* 2014;14(1):107.
4. Chen Y, Wang X, Guo L, et al. Radiological features and pathology of extraskeletal mesenchymal chondrosarcoma. *Clin Imaging.* 2012;36(4):365–370.
5. Shakked RJ, Geller DS, Gorlick R, Dorfman HD. Mesenchymalchondrosarcoma: clinicopathologic study of 20 cases. *Arch Pathol Lab Med.* 2012;136(1):61–75.