



Contents lists available at ScienceDirect

Trauma Case Reports

journal homepage: www.elsevier.com/locate/tcr



Case Report

Case report-delayed splenic rupture in combination with medial femoral neck fracture after low energy trauma. Development of hemorrhagic shock 5 days after hip prosthesis due to a rare cause[☆]

M. Leiblein^{a,*}, D. Ullrich^a, N. Habbe^b, M. Keese^c, I. Marzi^a, M. Lehnert^a

^a Department of Trauma, Hand and Reconstructive Surgery, Hospital of the Goethe University, Theodor-Stern-Kai 7, 60590 Frankfurt am Main, Germany

^b Department of General and Visceral Surgery, Hospital of the Goethe University, 60590 Frankfurt am Main, Germany

^c Department of Vascular and Endovascular Surgery, Hospital of the Goethe University, Theodor-Stern-Kai 7, 60590 Frankfurt am Main, Germany

ARTICLE INFO

Article history:

Accepted 11 January 2016

Available online 1 February 2016

ABSTRACT

A 79 year old female patient was admitted to our emergency department with a fracture of the right medial femoral neck six days after a fall on her right side and a cemented hemiprosthesis was implanted. Five days later, she developed a hemorrhagic shock and was diagnosed with a delayed splenic rupture and the spleen was resected. Histopathological examination showed a delayed rupture of an otherwise normal spleen without signs of an underlying pathology. The outcome was fatal: In the postoperative course she developed pneumonia, three weeks later she succumbed due to multiple organ failure.

Even careful reevaluation of the case did not provide any clues to expect an injury of the spleen according to trauma mechanism.

This case shows that delayed splenic rupture of a normal spleen may occur even after a low energy trauma. Injury of the spleen should therefore always be considered, even with an uncharacteristic anamnesis. Physical examination after trauma should therefore always include a careful clinical evaluation. The clinical threshold for a FAST examination should be low.

The coincidence of a femoral neck fracture and a splenic rupture after a low energy trauma has not been reported before.

© 2016 The Authors. Published by Elsevier Ltd. This is an open access article under the CC BY-NC-ND license (<http://creativecommons.org/licenses/by-nc-nd/4.0/>).

[☆] Presented as poster at ECTES 2015, 16th European Congress of Trauma & Emergency Surgery 10–12 May 2015, Netherlands, Amsterdam.

* Corresponding author. Tel.: +49 69 6301 6123.

Introduction

Femoral neck fractures occur frequently in the elderly population after low energy trauma, incidence at about 399.4/100.000 in Germany [1]. Most medial femoral head and neck fractures in the elderly population are treated by implantation of an endoprosthesis to mobilize the patient as early as possible. (See Figs. 1–4.)

Besides cardiovascular incidents and pneumonia after hip surgery, bleeding complications can occur due to vascular injuries i.e. of the deep femoral or intrapelvic vessels. Penetrating damage to the vessels can be caused by i.e. dislocated guidewire pins, dislocated bicortical screws, or displaced Hohmann retractors. Even non-penetrating damage due to traction of calcified arterial vessels is reported [2–5].

Most often bleeding complications occur intraoperatively, there are also cases reported of hypovolemic shock after hip replacement caused by an intraoperative injury to branches from the common femoral artery and vein that retract proximally and do not become obvious via blood loss through the operative approach but continue to bleed to the retroperitoneal space [4].

Injuries of the spleen result from either penetrating or blunt trauma of the left abdomen or the lower thorax. After an abdominal blunt trauma the spleen is the most often affected organ with an incidence of up to 47.6% [6]. The mortality after a splenic rupture is one percent, and in the case of a delayed splenic rupture it is as high as ten percent [7]. In the presence of an isolated splenic injury only hemodynamic compromise triggers an operation. Preservation of the organ is an important principle while obtaining hemostasis. However, in stable patients that are treated conservatively, a delayed rupture of the capsule with subsequent hemorrhagic shock may occur. Inflammatory processes within the healing spleen temporarily weakens the splenic tissue before a stable scar is present – so monitoring as an inpatient is warranted for at least 14 days after trauma.

Case-report

A 79 year old Caucasian woman presented in the emergency department of our level I trauma center on 04/09/2014 with an already diagnosed medial femoral neck fracture on her right side after a low energy trauma that happened on 04/03/2014. Radiographs were conducted at the second visit to an orthopedic private practice and presented by the patient's husband.

Careful anamnesis of the patient and her husband was performed and showed that the patient fell on her right body side on flat ground. Neither the patient nor her husband could remember another traumatic incident.

As preexisting conditions she exhibited arterial hypertension, hypothyreosis, cataract, macular degeneration, hypacusis as well as multiple operations of eyes and hand were recorded.

The patient was fully orientated and exclusively complaining about the pain in her right hip. During initial examination the abdomen presented soft, with no tenderness on palpation and regular peristaltic sounds. As there was no clue of an injury of the spleen according to the trauma mechanism a FAST-sonography was not performed.

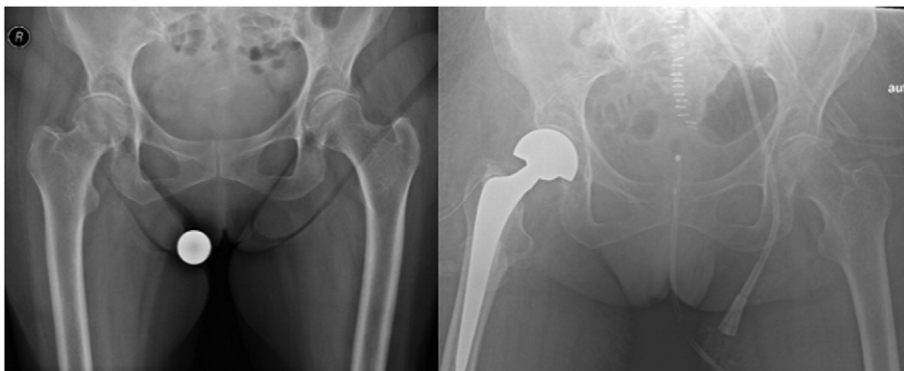


Fig. 1. Pelvic X-ray of the patient pre- and postoperatively.

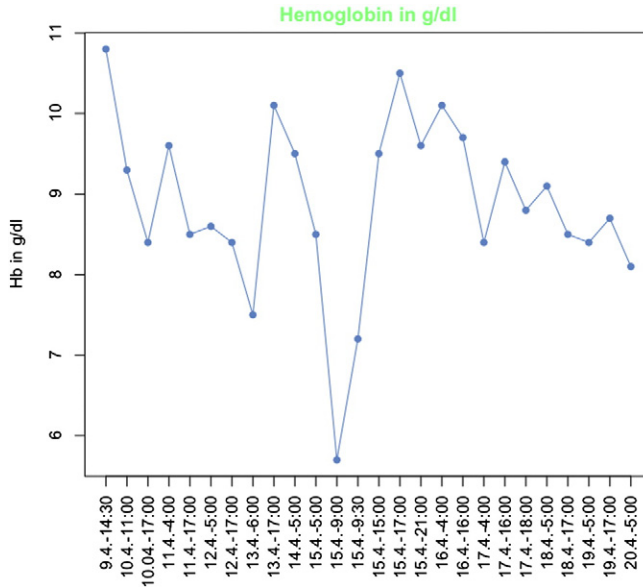


Fig. 2. Chart of the hemoglobin-progression. Down drop to 5.7 g/dl at the time of the delayed rupture.

On 04/10/2014 we implanted a cemented dual head prosthesis on the right side (MS30, shaft: 10, 10/12 centralizer, 44 Bipolar-Shell, 28 Protasul “M”head).

On 04/15/2014 the patient presented – after initially experiencing a regular postoperative course – with progressive hemodynamic instability, decreasing hemoglobin levels down to 5.8 g/dl and progressive serum lactate levels. The patient became vasopressor-dependent, was intubated and a blood transfusion was initiated.

An immediate abdominal sonography showed free intraabdominal fluid. Emergency computed tomography showed a large partially coagulated intraperitoneal hematoma, free abdominal fluid and suprasplenic coagulum, as well as pleural and pericardial effusion.

An emergency splenectomy was then performed.

The postoperative period proceeded without complications until the patient developed respiratory failure due to pneumonia and had to be taken to the intensive care unit again. Following, the patient developed septic shock with multiple organ failure. With no further therapeutic options, the therapy was ended. The patient died on 05/06/2014.

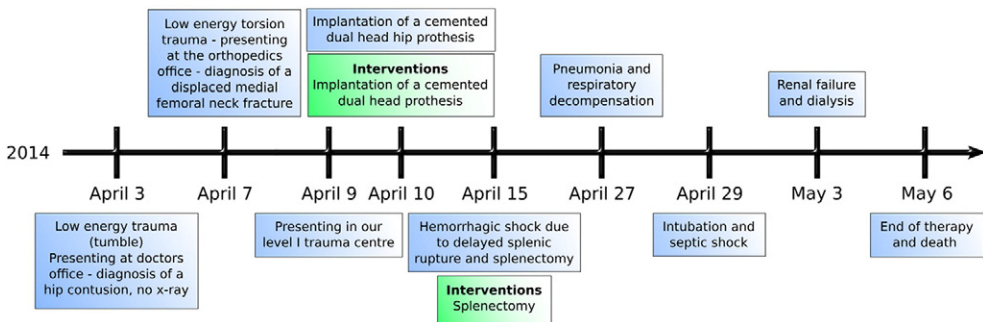


Fig. 3. Timeline of events and interventions.

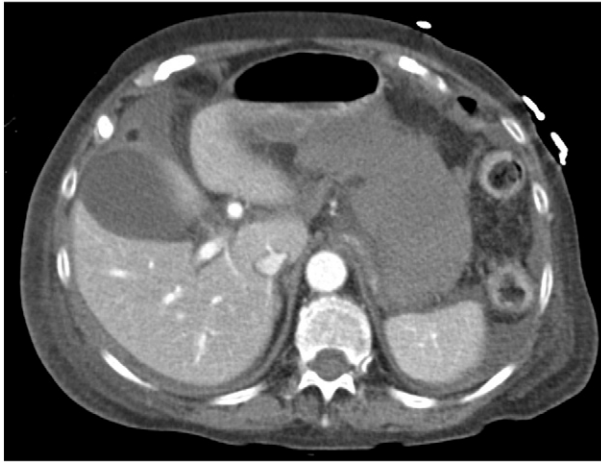


Fig. 4. CT-Scan 04/15/2014. Free abdominal fluid surrounding liver and spleen.

Discussion

Bleeding complications after hip surgery can be caused by injuries of the deep femoral or intrapelvic vessels and appear as hemorrhagic shock caused by retroperitoneal hematoma, hematoma of the thigh or pseudo-aneurysms. Most often bleeding complications occur intraoperatively or during the early postoperative phase.

Late onset bleeding complications are reported, most often appearing as pseudo-aneurysms due to damaged deep femoral vessels, but also retroperitoneal hematoma after four months caused by a secondary dislocated dynamic screw is possible [8].

In this special case the reason for the hemorrhagic shock 5 days postoperatively was initially suspected to be related to a continuously bleeding leakage of a branch of the deep femoral artery caused by a Hohmann retractor.

Computed tomography then revealed a delayed splenic rupture.

Delayed splenic rupture is a rare injury that usually occurs after blunt abdominal trauma [9,10] such as motorcycle accidents [11,12], car accidents [13], falls from great high and riding accidents [4], as well as after abdominal trauma during football matches [14].

Even careful reevaluation of the trauma mechanism in the reported case did not provide clues for abdominal involvement in the trauma.

There was no evidence for a preexisting splenic pathology and the histopathological examination showed a regular organ structure.

Due to the reported trauma mechanism without abdominal involvement, no FAST sonography of the abdomen had been performed initially. The abdominal examination showed a soft abdomen without tenderness on palpation.

Twelve days after the initial trauma, the patient presented with unspecific but retrospectively characteristic signs of a delayed splenic rupture, such as hemodynamic instability, acute abdomen and hemorrhagic shock. A positive Kehr's-sign was not documented.

By definition the time between initial trauma and actual symptoms of a delayed splenic rupture has to be at least 48 h. Time-intervals between one and 26 days are described [15].

Intraoperatively, the typical appearance of a delayed splenic rupture Moore stage IV could be found, as well as a large retropancreatic hematoma and an arterial bleeding of the pancreas. Histopathological examination confirmed the clinical findings.

In the presented case, radiological as well as intraoperative and histopathological findings clearly showed a delayed splenic rupture of a previously healthy organ. Anamnesis, trauma mechanism and initial symptoms gave no indication to the actual pathology.

The intention of this case report is to raise attention to delayed splenic rupture even in cases with uncharacteristic history, untypical trauma mechanism and no history of preexisting splenic pathology. Physical examination after trauma should therefore include a careful examination of the abdomen for the presence of symptoms of splenic rupture.

Conclusion

We found no case in any literature that describes a delayed splenic rupture of a previously normal spleen after a low energy trauma in combination with a femoral neck fracture. Even careful reevaluation of the case did not provide any clues to expect an injury of the spleen according to trauma mechanism.

This case demonstrates that delayed splenic rupture of a normal spleen can occur even after a low energy trauma with an unusual combination of injuries. Injury to the spleen should always be considered, even with an uncharacteristic anamnesis. Physical examination after trauma should include a careful clinical reevaluation for the presence of symptoms of splenic rupture.

Informed consent

This case-report was written after explicit consent was given by the patient's husband.

Conflict of interests

There is no conflict of interest to declare.

References

- [1] D.K. Dhanwal, Epidemiology of hip fracture: worldwide geographic variation, *Indian J. Orthop.* 45 (1) (2011 Jan–Mar) 15–22.
- [2] M. Leunig, Fatal retroperitoneal hemorrhage caused by perforation of a guidewire pin for proximal femur fixation, *Arch. Orthop. Trauma Surg.* 122 (1) (2002) 61–63.
- [3] N. Patelis, Iatrogenic injury of profunda femoris artery branches after intertrochanteric hip screw fixation for intertrochanteric femoral fracture: a case report and literature review, *Case Reports in Vascular Medicine* 2014, pp. 1–3.
- [4] B. Brismar, Injury of the femoral artery in total hip replacement causing abdominal pain and hypovolemic shock. A case report, *J. Bone Joint Surg. Am.* 74 (10) (1992) 1560–1562.
- [5] R. Bansal, Iatrogenic blunt arterial injury during a hip fracture surgery, *Acta Orthop. Belg.* 72 (2006) 96–99.
- [6] E.J. Zabinski, Delayed splenic rupture: a clinical syndrome following trauma, report of four cases with an analysis of one hundred and seventy-seven cases collected from the literature, *Arch. Surg.* 46 (2) (1943) 186–213.
- [7] J.S. Sizer, Delayed rupture of the spleen, review of the literature and report of six cases, *Arch. Surg.* 92 (3) (1966) 362–366.
- [8] C.E. Moreyra, Late vascular injury following intertrochanteric fracture reduction with sliding hip screw, *J. Surg. Orthop. Adv.* 13 (3) (2004) 170–173.
- [9] S. Kodikara, Death due to hemorrhagic shock after delayed rupture of spleen: a rare phenomenon, *Am. J. Forensic Med. Pathol.* 30 (4) (2009) 382–383.
- [10] N. Sowers, Trivial trauma and delayed rupture of a normal spleen: a case report, *J. Med. Case. Rep.* 5 (2011) 591.
- [11] M. Shahzad, Splenic injury after blunt abdominal trauma: an unusual presentation, *J. Emerg. Med.* 41 (5) (2011) 489–491.
- [12] G.A. Farhat, Delayed splenic rupture: real or imaginary? *Am. Surg.* 58 (6) (1992) 340–345.
- [13] Y. Kluger, Delayed rupture of the spleen — myths, facts, and their importance: case reports and literature review, *J. Trauma* 36 (4) (1994) 568–571.
- [14] S.A. Khan, An unusual presentation of nonpathological delayed splenic rupture: a case report, *Cases J.* 2 (2009) 6450.
- [15] R.A. Simpson, Case report: occult splenic injury: delayed presentation manifesting as jaundice, *Emerg. Med. J.* 18 (2001) 504–505.