



The role and clinical relevance of the ligamentum teres: long-term outcomes after hip arthroscopic surgery of cam-type femoroacetabular impingement

Jeong-Kil Lee ¹, Deuk-Soo Hwang ^{2*}, Sang-Bum Kim ¹, Chan Kang ²,
Jung-Mo Hwang ², Gi-Soo Lee ¹ and Eugene Jae-Jin Park ³

¹Department of Orthopaedic Surgery, Chungnam National University Sejong Hospital, Chungnam National University School of Medicine, 20, Bodeum 7-ro, Sejong-si, Daejeon 30099, Republic of Korea, ²Department of Orthopaedic Surgery, Chungnam National University Hospital, Chungnam National University School of Medicine, 282, Munhwa-ro, Jung-gu, Daejeon 35015, Republic of Korea and ³Department of Orthopaedic Surgery, Kyungpook National University Hospital, Kyungpook National University School of Medicine, Dongdeok-ro, Jung-gu, Daegu 41944, Republic of Korea.

*Correspondence to: D.-S. Hwang. E-mail: dshwang@cnu.ac.kr

ABSTRACT

We aimed to compare clinical and radiologic outcomes in patients with cam-type femoroacetabular impingement (FAI), with and without a partial ligamentum teres (LT) tear, who underwent hip arthroscopy (HA) with ≥ 10 years of follow-up. Among the patients who underwent HA for a cam-type FAI diagnosis with a labral tear, 28 patients (28 hips) with a partial LT tear and 87 patients (99 hips) with an intact LT were assigned to Groups A and B, respectively. All patients underwent partial labral debridement and femoroplasty. Debridement and thermal shrinkage were performed for LT tears. The grade of chondral damage was measured intraoperatively. Clinical items were assessed preoperatively and at the last follow-up. Patients' satisfaction with the surgery and changes in postoperative sports ability in those who had previously been active in sports were assessed at the last follow-up. The Tönnis grade was assessed preoperatively and at the last follow-up for radiologic evaluation. Chondral damage to the acetabular and femoral head detected intraoperatively was significantly different between the groups ($P = 0.005$ and $P < 0.001$). At the last follow-up, Group A patients experienced more difficulty performing sports activities than Group B patients ($P = 0.056$), and significantly, more Group A patients had stopped exercising despite their active participation in sports preoperatively ($P = 0.002$). Regarding the Tönnis grade, significant differences were found only at the final follow-up ($P = 0.020$). Patients with partial LT tear showed a higher grade of chondral damage, experienced decreased exercise capacity and had significantly worsened Tönnis grades, suggesting hip osteoarthritis progression compared to those with an intact LT.

INTRODUCTION

Studies on the function of the ligamentum teres (LT) were first published in the 19th century [1]. With the development of hip arthroscopy (HA) in recent decades, interest in and the importance of the function and role of the LT has been gradually emphasized [2, 3]. Leunig *et al.* [4] have reported that the LT possesses a free nerve ending that is responsible for pain, pressure and deep sensation. The LT is known to help distribute synovial fluid into the joint and plays an important role in enhancing hip stability [5, 6]. The role of LT for the biomechanics and function of the hip joint has not been fully described in the literature, and studies on the relationship between LT injury and hip joint injury are lacking.

A match-controlled study by Maldonado *et al.* [7] has found that among patients who underwent HA due to femoroacetabular impingement (FAI) and labral tear, those

with a complete rupture of the LT had a 3-fold increase in the relative risk of undergoing total hip arthroplasty (THA) compared to those with an intact LT. However, The HA debridement procedure has shown excellent short-term results by reducing pain and improving the function of partial LT tears [8–10]. However, no studies have reported clinical and radiologic results of the long-term effects of partial LT tears [11, 12].

Given that the LT contributes to the hip joint stability, we hypothesized that patients with a partial LT tear would develop hip osteoarthritis earlier than those with an intact LT. Therefore, we designed a retrospective case–control study of patients who underwent HA with ≥ 10 years of follow-up. Considering that isolated LT tears are rare [9], we reviewed the patients who had undergone HA for FAI with labral tear and divided them according to LT tear. Furthermore, intraoperative chondral damage,

clinical outcomes and hip osteoarthritis progression according to simple radiographs were analyzed.

MATERIALS AND METHODS

Patient selection

This study was approved by the institutional review board, and the requirement for informed consent was waived due to the retrospective nature of the study. The study was performed according to the ethical standards of the Declaration of Helsinki.

Between January 2005 and December 2009, a total of 205 hips in 188 patients aged ≥ 18 years who received HA for cam-type FAI with a labral tear were included. Cam-type FAI was defined as an alpha angle of $\geq 57^\circ$ on preoperative computed tomography (CT) scan. After a review of the clinical charts and radiologic images, 73 patients with the following history were excluded from the study: (i) childhood hip disorder (slipped capital femoral epiphysis, Legg–Calve–Perthes disease and dysplastic hip, among others), (ii) inflammatory joint disease (ankylosing spondylitis, diffuse idiopathic skeletal hyperostosis and rheumatoid arthritis, among others) and (iii) traumatic hip injury (acetabular fracture and hip dislocation). Patients with advanced osteoarthritis of the hip of Tönnis grade ≥ 2 at the time of HA [13], those who had already undergone ipsilateral hip surgery for various causes and those who had a history of ipsilateral HA were also excluded. Finally, patients who were not followed up for >10 years and those who were considered to have a secondary gain related to their occupations or accidents were also excluded.

Surgical technique

All operations were performed by a senior surgeon with more than 25 years of experience. Patients received HA under general anesthesia in the supine position on a standard hip traction table. The operative limb was retracted in slight hip flexion and abduction positions 15° – 20° of the internal rotation. Anterior, anterolateral (AL) and posterolateral (PL) portals were typically used. The labrum at the PL portal site is smaller than that at the AL portal site [14]. Thus, the PL portal was created first under C-arm guidance, followed by the insertion of an arthroscope to prevent iatrogenic labral injury that might occur while creating the AL portal. Thereafter, the anterior portal was created. Interportal capsulotomy was not performed between these two portals. Only portal widening of the joint capsule was performed. The central compartment was evaluated first to assess and treat LT tears, labral tears and chondral lesions. The operative limb was inspected with a probe while simultaneously rotating the limb internally and externally to assess LT damage. For LT tears, debridement and thermal shrinkage were performed using a shaver or radiofrequency probe. Debridement and partial labral resection were carefully performed for labral tears to maintain the function of the labrum as much as possible. Moreover, debridement and/or microfracture were performed on damaged cartilage as required. After treating the central compartment, traction was released, and the hip was flexed by approximately 40° to access the peripheral compartment. Femoroplasty was performed using a 4.0- or 5.5-mm burr until confirming through the arthroscope that no collision had occurred while performing dynamic hip motion with flexion and rotation (Fig. 1).

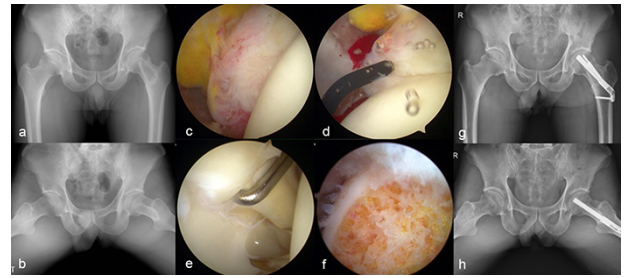


Fig. 1. A 43-year-old male patient with right hip pain and limitation of motion. His anterior impingement and Patrick tests are positive. (a, b) Simple radiographs before surgery show bump on head–neck junction. (c, d) His partial ligamentum teres tear is lesser than 50%; thus, debridement and thermal shrinkage are performed. (e) Labral tear is observed at the labrum–cartilage junction. (f) Femoroplasty is performed on the bump of the head–neck junction. (g, h) Simple radiographs taken at the 12-year follow-up shows worsening of his right hip osteoarthritis.

Clinical evaluation

During HA, the degree of LT damage was classified according to the Gray and Villar classification and Domb classification [2, 15]. Gray and Villar types II and III and Domb types I and II were regarded as partial LT tears. Chondral lesions were classified according to the Outerbridge classification [16].

The visual analog scale (VAS) pain score, modified Harris Hip Score (mHHS), Nonarthritic Hip Score (NAHS), Hip Outcome Score–Activities of Daily Living (HOS-ADL) and Hip Outcome Score–Sports Scale (HOS-SS) were evaluated in all patients. Each questionnaire was administered in an outpatient clinic preoperatively, 6 months postoperatively, 1 year postoperatively and every year thereafter. Scores measured before surgery and at the last follow-up were used for statistical analysis. At the last follow-up, the VAS satisfaction scores for all patients were assessed. In addition, perioperative changes in sports ability were specifically assessed for those who participated in martial arts or amateur sports for at least 2 years preoperatively. Postoperative status regarding sports ability was assessed for the following: at the same level, diminished level, stopped and never participated, compared to the sports ability before the pain had occurred. Because there is no single patient-reported outcome questionnaire for patients who have undergone HA, multiple outcome measurements have been performed [17]. Surgical failure was defined as reoperation such as arthroscopic surgery or THA conversion performed within >10 years of the follow-up period.

Radiologic evaluation

All patients underwent simple radiography, CT scan, magnetic resonance imaging preoperatively and simple radiography at follow-up postoperatively. Simple radiographic examinations included the pelvic anteroposterior view, frog-leg side view, false-profile view and cross-table view. In the pelvic anteroposterior view, the Tönnis grade was assessed using a picture archiving and communication system (Maroview v5.4; Marotech, Seoul, Republic of Korea) [18]. The Tönnis grade was measured four times, twice by a single hip joint specialist orthopedic surgeon who did not participate in the surgery and twice by another musculoskeletal radiologist. Since Tönnis grades 0 and 1 were

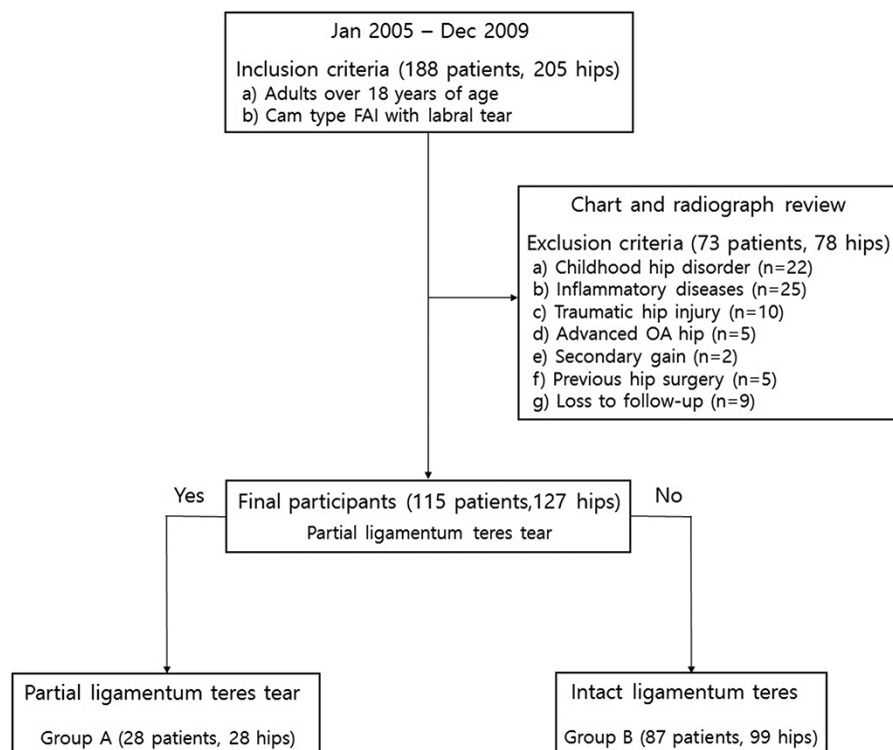


Fig. 2. Flow diagram of patient allocation.

FAI, femoroacetabular impingement; advanced OA, osteoarthritis of a Tönnis grade ≥ 2 .

difficult to distinguish if there was a disagreement between the two observers, an agreement was reached by reviewing the simple radiography together for final grading.

Statistical analysis

SPSS software (IBM SPSS ver. 26.0; IBM Co., Armonk, NY, USA) was used for the statistical analysis. For the comparison of the groups, continuous data including age, body mass index and follow-up period did not satisfy normality. Thus, the Mann–Whitney U test was performed. Among sex, left and right hip, predisposing factor and HA findings, categorical data such as LT tear grade, Outerbridge classification, sports ability and Tönnis grade were analyzed using the chi-square or Fisher's exact tests. The Wilcoxon signed-rank test was performed to compare the changes in clinical outcomes preoperatively and at the last follow-up, and the Mann–Whitney U test was performed to compare the changes in outcomes between Groups A and B. All results were considered significantly different when $P < 0.05$. The intraobserver and interobserver Cohen's kappa values were used to evaluate the reproducibility of the Tönnis grade measured by two doctors.

RESULTS

Based on the HA findings, 28 patients (28 hips) with a partial LT tear and 87 patients (99 hips) with an intact LT were assigned to Groups A and B, respectively (Fig. 2, Table I). Two patients had complete LT tears at the time of HA. However, one patient was lost to follow-up, and the other patient died within

Table I. Patient demographics

	Group A (28 patients, 28 hips)	Group B (87 patients, 99 hips)	P-value
Age, years	36.5 (18, 57)	34.0 (18, 58)	0.549 ^a
Sex, M:F	19:9	72:27	0.614 ^b
Right:left	13:15	49:50	0.774 ^b
BMI, kg/m ²	22.7 (19.3, 30.9)	22.8 (15.9, 38.8)	0.800 ^a
Follow-up, months	131.5 (121, 175)	135.0 (122, 170)	0.464 ^a
Predisposing factor			0.718 ^b
N/S	18	57	
Martial arts	5 (Tae 4, Kick 1)	13 (Tae 11, Kar 2)	
Amateur sports player	3 (Soc 2, Base 1) 2 (TA 2)	19 (Soc 7, Bask 5, Base 5, Ten 2)	
Trauma		10 (TA 7, FFH 3)	

Note: Values are presented as medians (minimum value, maximum value) and numbers.

^aMann–Whitney U test between Groups A and B.

^bChi-square test between Groups A and B.

Abbreviations: M, Male; F, Female; BMI, body mass index; N/S, non-specific; Tae, Taekwondo; Kick, kickboxing; Kar, karate; Soc, soccer; Base, baseball; Bask, basketball; Ten, tennis; TA, traffic accident; FFH, fall from height.

the follow-up period. Thus, these patients were excluded from the study (Fig. 2).

Arthroscopic findings revealed a significant difference in the severity of cartilage damage between the two groups. In Group B, cartilage damage was concentrated in the lower grades

Table II. Arthroscopic findings of ligamentum teres tears and chondral damage

		Group A (28 patients, 28 hips)	Group B (87 patients, 99 hips)	P-value ^a
Ligamentum teres tear grade	Gray and Villar classification			
	0 (normal)	0	99	<0.001
	I (complete tear)	0	0	
	II (partial thickness tear)	21	0	
	III (degenerative tear)	7	0	
	Domb classification			
	0 (normal)	0	99	<0.001
	I (<50%, low grade)	18	0	
II (>50%, high grade)	10	0		
III (full-thickness tear)	0	0		
Chondral injury (Outerbridge classification)	Acetabulum			
	0 (normal)	5	34	0.005
	I (surface fibrillation)	6	35	
	II (cartilage loss <50%, thickness)	8	18	
	III (cartilage loss >50%, thickness)	4	11	
	IV (exposed subchondral bone)	5	1	
	Femoral head			
	0 (normal)	7	36	<0.001
	I (surface fibrillation)	7	45	
	II (cartilage loss <50%, thickness)	6	14	
	III (cartilage loss >50%, thickness)	5	4	
	IV (exposed subchondral bone)	3	0	

Note: Values are presented as numbers only.

^aChi-square or Fisher's exact test between Groups A and B.

Table III. Clinical outcomes of the two groups divided by ligamentum teres tear (Groups A and B)

Score		Preoperative	Last follow-up	Change	P-value ^a	P-value ^b
VAS pain score	Group A	6.5 (5, 9)	2 (1, 7)	4 (0, 7)	<0.001	0.943
	Group B	7.0 (6, 10)	3 (0, 8)	4 (-2, 10)	<0.001	
mHHS	Group A	68.7 (56.0, 84.6)	86.8 (61.5, 98.8)	14.9 (-6.6, 38.5)	<0.001	0.576
	Group B	71.4 (34.1, 83.5)	84.6 (56.0, 100)	13.2 (-9.9, 65.9)	<0.001	
NAHS	Group A	67.5 (51.3, 86.3)	87.6 (65.0, 100)	15.0 (-5.0, 42.5)	<0.001	0.451
	Group B	68.8 (18.8, 92.5)	86.3 (50.0, 100)	15.0 (-13.8, 76.2)	<0.001	
HOS-ADL	Group A	66.2 (47.1, 84.7)	85.0 (60.3, 98.5)	14.7 (-7.4, 39.7)	<0.001	0.627
	Group B	67.6 (29.4, 94.1)	83.8 (51.5, 100)	14.7 (-16.1, 67.7)	<0.001	
HOS-SS	Group A	66.7 (33.3, 83.3)	77.8 (38.9, 94.4)	8.9 (-25.0, 36.1)	<0.001	0.056
	Group B	66.7 (19.4, 92.7)	80.6 (27.8, 100)	11.2 (-27.8, 61.1)	<0.001	

Note: Values are presented as medians (minimum value, maximum value).

^aWilcoxon signed-rank test between preoperative and last follow-up for each group.

^bMann-Whitney U test comparing change values of each score between Groups A and B.

Abbreviations: mHHS, Modified Harris Hip Score; NAHS, Nonarthritic Hip Score; HOS-ADL, Hip Outcome Score—Activity of Daily Living Scale; HOS-SS, Hip Outcome Score—Sports Scale.

according to the Outerbridge classification. In contrast, a relatively even distribution of cartilage damage in both the acetabular and femoral heads was observed in Group A ($P = 0.005$ and $P < 0.001$, Table II).

The clinical evaluation parameters, including the VAS pain, mHHS, NAHS, HOS-ADL and HOS-SS scores, had improved significantly at the last follow-up in both groups. However, there were no significant differences in the amount of change in clinical outcomes between the two groups (Table III). Although the comparison of the amount of change in the HOS-SS revealed no statistical significance ($P = 0.056$), patients in Group A tended

to have more difficulty with sports activities than those in Group B at the last follow-up.

The sports ability showed a significant difference between the two groups. Group A showed a significantly decreased sports ability according to the questionnaire regarding martial arts and amateur sports players (Table IV). However, the VAS satisfaction score or surgical failure rate did not significantly differ between the two groups ($P = 0.573$ and $P = 0.999$).

In terms of radiologic evaluation using the Tönnis grade, although no significant difference between the two groups was found preoperatively ($P = 0.810$), there was a significant

Table IV. Sports ability at last follow-up in preparation for previous exercise capacity

	Same level	Diminished level	Stopped	Never participated	P-value ^b
Group A (n = 8) ^a	0	1	5	2	0.002
Group B (n = 32) ^a	10	16	4	2	

^aGroup A: martial arts (Taekwondo 4, kickboxing 1), amateur sports player (soccer 2, baseball 1).

Group B: martial arts (Taekwondo 11, karate 2), amateur sports player (soccer 7, basketball 5, baseball 5, tennis 2).

^bChi-square or Fisher's exact test between Groups A and B at last follow-up.

difference at the final follow-up ($P = 0.020$, Table V). In addition, the intra- and interobserver Cohen's kappa value for the Tönnis grade showed excellent results, with both values >0.810 .

DISCUSSION

The most important finding in this study was that patients with a partial LT tear demonstrated higher Outerbridge scores at the time of surgery. Notably, patients with a partial LT tear showed satisfactory results with no significant differences in most clinical findings compared to those with an intact LT; however, patients with a partial LT tear also showed decreased athletic performance and were classified with relatively worsened Tönnis grades.

Although the HA debridement procedure alleviates pain and improves function in partial LT tears, leading to excellent short-term results, there are no studies with long-term clinical results [8–12]. Therefore, this study is meaningful for reporting long-term clinical and radiologic outcomes for patients with partial LT tears.

The reported prevalence of LT pathology (including synovitis, partial and complete tears) found during HA surgery varies from 4% to 93% [3, 19]. According to Haviv and O'Donnell, an LT tear is observed in 9% of the patients who undergo HA [9]. Moreover, LT tears occur frequently when there are bony deformities such as hip dysplasia or FAI [20, 21]. Martin *et al.* [19] observed in their cadaveric study that LT damage may result from the levering mechanism of the femoral head in flexion and internal rotation movements beyond the position of hip impingement. In our study, the rate of partial LT tears was 22.0% (28/127). The prevalence of partial LT tears was higher than that of previous studies because our study assessed patients who underwent HA after a cam-type FAI diagnosis.

Intraoperative findings showed that patients in Group A had higher rates of deteriorated chondral damage in the acetabulum and femoral head than those in Group B. According to O'Donnell *et al.* [22], the laxity of the capsule in patients with FAI is increased by the levering mechanism of the femoral head, which leads to LT damage. This increases microinstability and causes chondral damage. The definite role of the LT in hip stability is particularly emphasized in abnormal bone morphology, which occurs in FAI or hip dysplasia. The exact role of the LT remains debatable. However, many studies have shown that the LT contributes to hip joint stability [23–26].

Considering that the surgical method, which was the same for both groups, included only portal widening and not interportal capsulotomy, only partial labral resection without labral repair and adequate femoroplasty, which could affect hip stability, the microinstability resulting from a partial LT tear was thought to be the cause of hip joint instability. Chondral damage to the hip joint is significantly high in patients with an LT tear who have undergone HA for an FAI diagnosis [27, 28]. Furthermore, some studies have shown no significant difference in chondral damage, regardless of an LT tear [2, 7]. Because the exact etiology regarding whether chondral damage is caused by an LT tear or whether an LT tear occurs in the process of osteoarthritis is not known, further research is required [22, 29].

Although there were no significant differences in most clinical results for both groups, patients in Group A tended to report difficulties in performing sports activities. Patients in Group A reported a significant decrease in sports ability among those who required active sports ability. Worsening of hip osteoarthritis due to microinstability and hip pain resulting from a torn LT might be the cause of this observed finding. Kalisvaart and Safran [30] reported that some athletes are able to reach extremes of hip range of motion due to subclinical laxity of their soft tissues, which may be beneficial for sports activities. However, this ability may also place them at a higher risk of hip instability and injury.

Our study revealed that the Tönnis grade at the final follow-up differed significantly between the two groups. The severity of chondral damage observed in HA was already different between the two groups, and there would have been a significant difference in the severity of hip osteoarthritis caused by microinstability resulting from a torn LT. Therefore, when a partial LT tear is observed in patients with labral tears who undergo HA due to FAI, debridement and thermal shrinkage are necessary for pain relief and short-term functional improvement. Capsular plication, in addition to labral repair and femoroplasty, should be performed for hip stability if possible [8–10, 31].

Table V. Radiological outcomes of the two groups divided by ligamentum teres tear

		Tönnis grade 0	Tönnis grade 1	Tönnis grade 2	Tönnis grade 3	P-value
Preoperative	Group A	21	7	0	0	0.810 ^a
	Group B	72	27	0	0	
Last follow-up	Group A	3	12	10	3	0.020 ^b
	Group B	26	54	16	3	

^aChi-square or Fisher's exact test between Groups A and B before surgery (preoperative).

^bChi-square or Fisher's exact test between Groups A and B at last follow-up.

Postoperatively, patients should be educated on hip and core muscle strengthening exercises and be informed that they are more likely to develop hip osteoarthritis than patients with an intact LT. To inhibit and prevent the progression of osteoarthritis, patients should be instructed to avoid squats and attempts to cross one leg behind the other when standing because these movements lead to maximum tension in the LT, which may cause damage [26, 27, 31, 32].

This study had several limitations. First, this study was retrospective in nature; consequently, results other than those evaluated using patient questionnaires, clinical charts and radiologic data could not be obtained. For instance, there are many confounding factors, such as the severity of cam impingement, duration of preoperative symptoms or level of activity, amount of labral debridement and adequacy of cam deformity correction, which could explain differences in cartilage damage observed during HA and also progression to a more severe osteoarthritis during the follow-up. However, we were unable to analyze such factors due to the lack of information. Second, the sample size was small. In particular, there was a small number of patients in Group A. Thus, much of the data were not normally distributed, and non-parametric tests were performed. A well-designed, prospective study on a large number of patients with LT tears is required in the future. Third, labral repair and capsular repair were not attempted in this study. Because this was a clinical study that included patients who were followed up for a minimum 1 of 0 years, labral repair and capsular repair were not yet performed at our hospital. If surgical methods, such as labral repair and capsular repair related to hip stability, had been performed, different results may have been observed [33, 34]. Fourth, because this analysis only focused on patients with FAI with labral tears, there may have been selection bias, and the treatment outcomes may have been affected by the FAI or labral tear treatment itself. Fifth, this study used data from an experienced surgeon who performed a large number of HA surgeries. It is difficult to generalize these results because of the nature of HA [35]. Finally, the inclusion criteria for perioperative sports ability analysis, which included being a martial arts or amateur sports player for at least 2 years preoperatively, were arbitrary.

CONCLUSION

Patients with a partial LT tear showed a higher grade of chondral damage during HA. They tend to have decreased exercise capacity and significantly worse Tönnis grades. Due to the retrospective nature of this study, it is difficult to conclude that severe intraoperative cartilage damage and osteoarthritis progression are solely related to a partial LT tear. Future large-scale, prospective studies regarding the relationship between partial LT tear and chondral damage and osteoarthritis progression are required.

ACKNOWLEDGEMENTS

The authors express their deep gratitude to In-Sun Kwon, Ph.D., for her profound contributions to statistical analyses.

CONFLICT OF INTEREST STATEMENT

The authors declare no conflicts of interest.

FUNDING

None declared.

DATA AVAILABILITY

All data are incorporated into the article.

REFERENCES

1. Savory W. The use of the ligamentum teres of the hip-joint. *J Anat Physiol* 1874; **8**: 291.
2. Botser IB, Martin DE, Stout CE *et al*. Tears of the ligamentum teres prevalence in hip arthroscopy using 2 classification systems. *Am J Sport Med* 2011; **39**: 117s–25s.
3. Martin RL, McDonough C, Enseki K *et al*. Clinical relevance of the ligamentum teres: a literature review. *Int J Sports Phys Ther* 2019; **14**: 459–67.
4. Leunig M, Beck M, Stauffer E *et al*. Free nerve endings in the ligamentum capitis femoris. *Acta Orthop Scand* 2000; **71**: 452–4.
5. Guanche CA, Sikka RS. Acetabular labral tears with underlying chondromalacia: a possible association with high-level running. *Arthroscopy* 2005; **21**: 580–5.
6. Martin HD, Savage A, Braly BA *et al*. The function of the hip capsular ligaments: a quantitative report. *Arthroscopy* 2008; **24**: 188–95.
7. Maldonado DR, Laseter JR, Perets I *et al*. The effect of complete tearing of the ligamentum teres in patients undergoing primary hip arthroscopy for femoroacetabular impingement and labral tears: a match-controlled study. *Arthroscopy* 2019; **35**: 80–8.
8. Rao J, Zhou YX, Villar RN. Injury to the ligamentum teres. Mechanism, findings, and results of treatment. *Clin Sports Med* 2001; **20**: 791–9, vii.
9. Haviv B, O'Donnell J. Arthroscopic debridement of the isolated ligamentum teres rupture. *Knee Surg Sports Traumatol Arthrosc* 2011; **19**: 1510–3.
10. de Darren SA, Phillips M, Philippon MJ *et al*. Ligamentum teres injuries of the hip: a systematic review examining surgical indications, treatment options, and outcomes. *Arthroscopy* 2014; **30**: 1634–41.
11. O'Donnell JM, Pritchard M, Salas AP *et al*. The ligamentum teres-its increasing importance. *J Hip Preserv Surg* 2014; **1**: 3–11.
12. Rosinsky PJ, Shapira J, Lall AC *et al*. All about the ligamentum teres: from biomechanical role to surgical reconstruction. *J Am Acad Orthop Sur* 2020; **28**: E328–E39.
13. Stelzeneder D, Mamisch TC, Kress I *et al*. Patterns of joint damage seen on MRI in early hip osteoarthritis due to structural hip deformities. *Osteoarthritis Cartilage* 2012; **20**: 661–9.
14. Seldes RM, Tan V, Hunt J *et al*. Anatomy, histologic features, and vascularity of the adult acetabular labrum. *Clin Orthop Relat Res* 2001; **382**: 232–40.
15. Gray AJ, Villar RN. The ligamentum teres of the hip: an arthroscopic classification of its pathology. *Arthroscopy* 1997; **13**: 575–8.
16. Outerbridge R. The etiology of chondromalacia patellae. *J Bone Joint Surg Br* 1961; **43**: 752–7.
17. Lodhia P, Slobogean GP, Noonan VK *et al*. Patient-reported outcome instruments for femoroacetabular impingement and hip labral pathology: a systematic review of the clinimetric evidence. *Arthroscopy* 2011; **27**: 279–86.
18. Kovalenko B, Bremjit P, Fernando N. Classifications in brief: Tönnis classification of hip osteoarthritis. *Clin Orthop Relat Res* 2018; **476**: 1680–4.
19. Martin RL, McGovern RP, Martin HD *et al*. A mechanism for ligamentum teres injuries in femoroacetabular impingement: an anatomical study. *Int J Sports Phys Ther* 2018; **13**: 208–13.
20. Domb BG, Martin DE, Botser IB. Risk factors for ligamentum teres tears. *Arthroscopy* 2013; **29**: 64–73.
21. Martin RL, Martin HD. Function and clinical relevance of the ligamentum teres: a current concept. *Curr Orthop Pract* 2015; **26**: 425–8.

22. O'Donnell JM, Devitt BM, Arora M. The role of the ligamentum teres in the adult hip: redundant or relevant? A review. *J Hip Preserv Surg* 2018; **5**: 15–22.
23. Kraeutler MJ, Garabekyan T, Pascual-Garrido C et al. Ligamentum teres tendinopathy and tears. *Muscles Ligaments Tendons J* 2016; **6**: 337–42.
24. Philippon MJ, Rasmussen MT, Turnbull TL et al. Structural properties of the native ligamentum teres. *Orthop J Sports Med* 2014; **2**: 2325967114561962.
25. Martin HD, Hatem MA, Kivlan BR et al. Function of the ligamentum teres in limiting hip rotation: a cadaveric study. *Arthroscopy* 2014; **30**: 1085–91.
26. Kivlan BR, Richard Clemente F, Martin RL et al. Function of the ligamentum teres during multi-planar movement of the hip joint. *Knee Surg Sports Traumatol Arthrosc* 2013; **21**: 1664–8.
27. Chahla J, Soares EA, Devitt BM et al. Ligamentum teres tears and femoroacetabular impingement: prevalence and preoperative findings. *Arthroscopy* 2016; **32**: 1293–7.
28. Kaya M, Suziki T, Minowa T et al. Ligamentum teres injury is associated with the articular damage pattern in patients with femoroacetabular impingement. *Arthroscopy* 2014; **30**: 1582–7.
29. Devitt BM, Damasena I. Editorial commentary: chicken or the egg? The ligamentum teres and degenerative hip disease. *Arthroscopy* 2019; **35**: 89–90. Elsevier.
30. Kalisvaart MM, Safran MR. Microinstability of the hip-it does exist: etiology, diagnosis and treatment. *J Hip Preserv Surg* 2015; **2**: 123–35.
31. Safran MR. Microinstability of the hip-gaining acceptance. *J Am Acad Orthop Surg* 2019; **27**: 12–22.
32. Philippon MJ, Weiss DR, Kuppersmith DA et al. Arthroscopic labral repair and treatment of femoroacetabular impingement in professional hockey players. *Am J Sports Med* 2010; **38**: 99–104.
33. Wu ZX, Ren WX, Ren YM et al. Arthroscopic labral debridement versus labral repair for patients with femoroacetabular impingement: a meta-analysis. *Medicine (Baltimore)* 2020; **99**: e20141.
34. Domb BG, Philippon MJ, Giordano BD. Arthroscopic capsulotomy, capsular repair, and capsular plication of the hip: relation to atraumatic instability. *Arthroscopy* 2013; **29**: 162–73.
35. Mehta N, Chamberlin P, Marx RG et al. Defining the learning curve for hip arthroscopy: a threshold analysis of the volume-outcomes relationship. *Am J Sports Med* 2018; **46**: 1284–93.