



CASE REPORT

REVISED Case Report: Interstitial-intralesional laser therapy and laser-assisted new attachment procedure for the treatment of alveolar bone loss provoked by an aggressive pyogenic granuloma [version 3; peer review: 2 approved]

Previously titled: Case Report: Interstitial-intralesional laser therapy and laser-assisted new attachment procedure for the treatment of an aggressive pyogenic granuloma

Anon Akkarapatum^{1,2}, Poramaporn Klanrit³, Sajee Sattayut ^{1,2}

¹Oral and Maxillofacial Surgery, Faculty of Dentistry, Khon Kaen University, Khon Kaen, 40002, Thailand

²Lasers in Dentistry Research Group, Khon Kaen University, Khon Kaen, 40002, Thailand

³Oral Biomedical Science-Division of Oral Diagnosis, Khon Kaen University, Khon Kaen, 40002, Thailand

V3 First published: 02 Aug 2022, 11:883
<https://doi.org/10.12688/f1000research.122693.1>
 Second version: 06 Sep 2022, 11:883
<https://doi.org/10.12688/f1000research.122693.2>
 Latest published: 07 Oct 2022, 11:883
<https://doi.org/10.12688/f1000research.122693.3>

Abstract

Background: A pyogenic granuloma (PG) is a common benign vascular lesion found in the oral cavity. The gold standard treatment of this lesion, comprising surgical excision and the elimination of etiological factors, cannot avoid tooth loss in the case of an aggressive pyogenic granuloma. Because of the prominent properties of 980 nm and 635 nm diode lasers in photocoagulation and photobiomodulation, we applied these wavelengths in the treatment of a large pyogenic granuloma with alveolar bone loss.







Case presentation: Our objective was to use a combination of interstitial-intralesional laser therapy, photocoagulation and laser-assisted new attachment procedure (LANAP) to preserve the teeth and periodontal tissue in a case of an aggressive pyogenic granuloma.

Results: The patient was a 13-year-old Thai male with a pyogenic granuloma involving the interdental papilla and lingual gingiva of the lower left first and second molars. The teeth were also displaced by the lesion. After treatment with three sessions of photocoagulation, three sessions of interstitial-intralesional laser therapy and two sessions of LANAP, the lesion was completely resolved. The periodontal status of the teeth was improved at the six-month follow-up.


Conclusion: The combination of interstitial-intralesional laser therapy, photocoagulation and LANAP was able to treat an aggressive

Open Peer Review

Approval Status  

	1	2
version 3 (revision) 07 Oct 2022		 view
		
version 2 (revision) 06 Sep 2022		 view
		
version 1 02 Aug 2022	 view	 view

1. **Kenneth Luk**, The University of Hong Kong, Hong Kong, China

2. **Samir Namour** , University of Liege, Liege, Belgium

Any reports and responses or comments on the article can be found at the end of the article.

pyogenic granuloma with tooth preservation.

Keywords

pyogenic granuloma, interstitial-intralesional laser therapy, photocoagulation, LANAP, diode laser, tooth preservation

Corresponding author: Sajee Sattayut (sajee@kku.ac.th)

Author roles: **Akkarapatum A:** Data Curation, Investigation, Methodology, Visualization, Writing – Original Draft Preparation; **Klanrit P:** Data Curation, Investigation, Visualization, Writing – Original Draft Preparation; **Sattayut S:** Conceptualization, Methodology, Project Administration, Supervision, Writing – Review & Editing

Competing interests: No competing interests were disclosed.

Grant information: This work is supported by The Lasers in Dentistry Research Group, Khon Kaen University, Thailand. *The funders had no role in study design, data collection and analysis, decision to publish, or preparation of the manuscript.*

Copyright: © 2022 Akkarapatum A *et al.* This is an open access article distributed under the terms of the [Creative Commons Attribution License](#), which permits unrestricted use, distribution, and reproduction in any medium, provided the original work is properly cited.

How to cite this article: Akkarapatum A, Klanrit P and Sattayut S. **Case Report: Interstitial-intralesional laser therapy and laser-assisted new attachment procedure for the treatment of alveolar bone loss provoked by an aggressive pyogenic granuloma [version 3; peer review: 2 approved]** F1000Research 2022, 11:883 <https://doi.org/10.12688/f1000research.122693.3>

First published: 02 Aug 2022, 11:883 <https://doi.org/10.12688/f1000research.122693.1>

REVISED Amendments from Version 2

This version emphasizes the procedure of photo biomodulation in figure 5 besides explains the interesting result of initial blood clot observation.

Any further responses from the reviewers can be found at the end of the article

Introduction

A pyogenic granuloma is a lobulated exophytic lesion with a painless red erythematous papule. This lesion presents either as a pedunculated mass or with a sessile base. Pathogenic factors include chronic low-grade local irritation, hormonal factors and certain medications.¹ As this lesion is composed of a vascular component, blade excision leads to considerable bleeding and demands hemostatic intervention.

Near-infrared and red diode lasers provide favorable photocoagulation and photobiomodulation. These diode lasers are able to stimulate the formation of blood clots and promote healing after surgery.² Therefore, these wavelengths are widely used for the treatment of vascular lesions in the oral cavity via surface photocoagulation and interstitial-intralesional laser therapy.³

Regarding periodontal disease treatment, laser-assisted new attachment procedure (LANAP) is able to stimulate the formation of new attachments. This technique also has advantages in hemostasis, granulation tissue removal and the reduction of periodontal disease pathogens.⁴

Hence, we introduce an interstitial-intralesional laser technique for the treatment of aggressive pyogenic granulomas, aiming to treat lesions with minor gingival excision and preservation of periodontal tissue. Periodontal tissue recovery was achieved by LANAP. This case report presents a typical pyogenic granuloma with aggressive characteristics treated through the use of interstitial-intralesional laser therapy, photocoagulation and LANAP.

Case report

This case report was authorized by the ethics committee in human research, Khon Kaen University, reference number HE632040. The informed consent in Thai language from the patient and his parent was submitted to the ethics committee. The patient was a 13-year-old Thai male patient with a chief complaint of a rapidly swelling mass of the lower-left molar gingivae without pain for 10 days. There was no history of medical and psychological disorders of the patient and family. There was no systemic disease based on physical examination and laboratory investigation. The oral examination found an approximately 2×2 cm erythematous pedunculated mass with ulceration in the area of the interdental papilla and on the lingual gingiva of tooth no. 36 and tooth no. 37. The mass was soft consistency with no bleeding and no pus

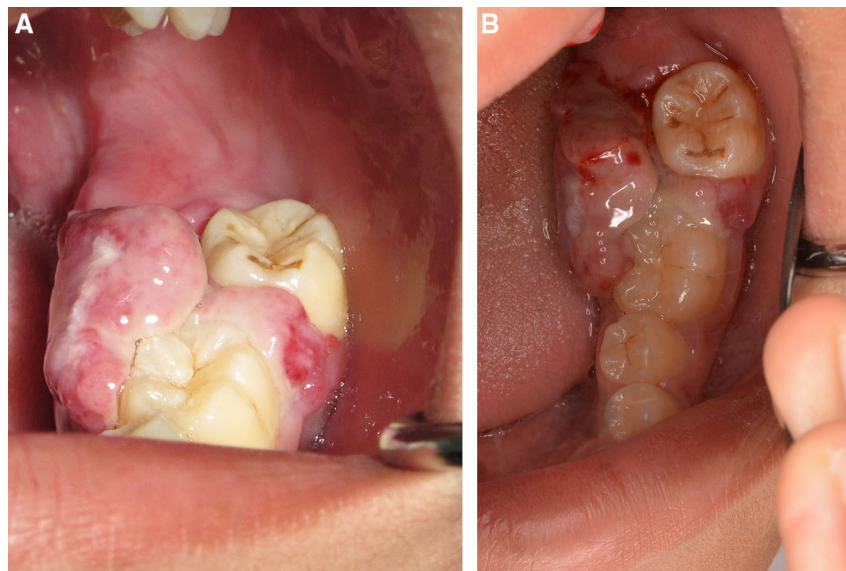


Figure 1. Clinical appearance. A. The erythematous pedunculated mass at tooth no. 36 and tooth no. 37. B. Tooth no. 37 was displaced from the normal position.

(Figure 1A). Tooth no. 37 exhibited buccal displacement, as shown in Figure 1B. Tooth no. 36 and tooth no. 37 exhibited second-degree and third-degree mobility, respectively.

The periapical radiograph showed distinct periapical and proximal bone destruction of tooth no. 36 and tooth no. 37 (Figure 2).

A sample obtained with an incisional biopsy using a 980 nm diode laser at 4 W continuous-wave with a 320-micron optical fiber confirmed the diagnosis of a pyogenic granuloma with histopathological features presenting endothelial cell proliferation, fibroblasts, neutrophils and chronic inflammatory cells in the connective tissue stroma (Figure 3A and B).

The lesion was firstly treated by interstitial-intralesional laser therapy under local anesthesia using a 980 nm diode laser at 3 W continuous-wave with a 200-micron optical fiber, as shown in Figure 4A and B. After the insertion of the optical fiber tangentially to the tooth and root surface into the lesion, the laser was irradiated for five seconds. The lesion became pale and harder, indicating that coagulation was achieved.

This treatment was then immediately followed by treatment with using a 635 nm diode laser via an 8 mm optical fiber at 100 mW, continuous wave and 4 J/cm^2 with non contact mode to the lesion at the buccal and lingual sites for 1 session per area to achieve photobiomodulation (Figure 5). It was interesting that an initial blood clot was also observed over the lesion.

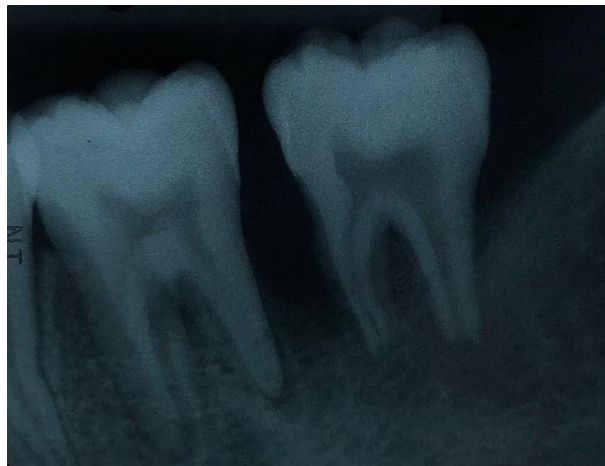

Figure 2. Radiographic examination. The periapical radiograph demonstrating alveolar bone loss at tooth no. 36 and tooth no. 37.

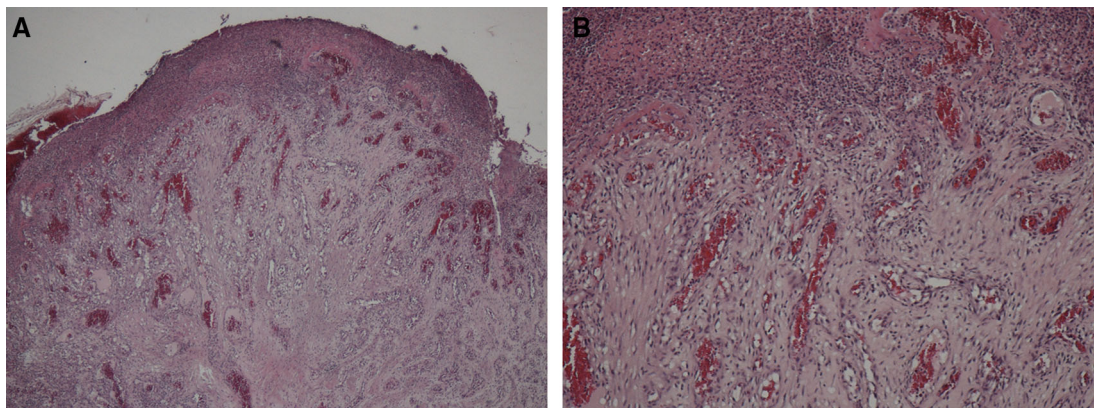


Figure 3. Pathohistological investigation. Histopathology section showing endothelial cell proliferation and distribution throughout the lesion, which are the characteristics of a pyogenic granuloma. A. At $\times 10$ magnification and B. At $\times 40$ magnification.

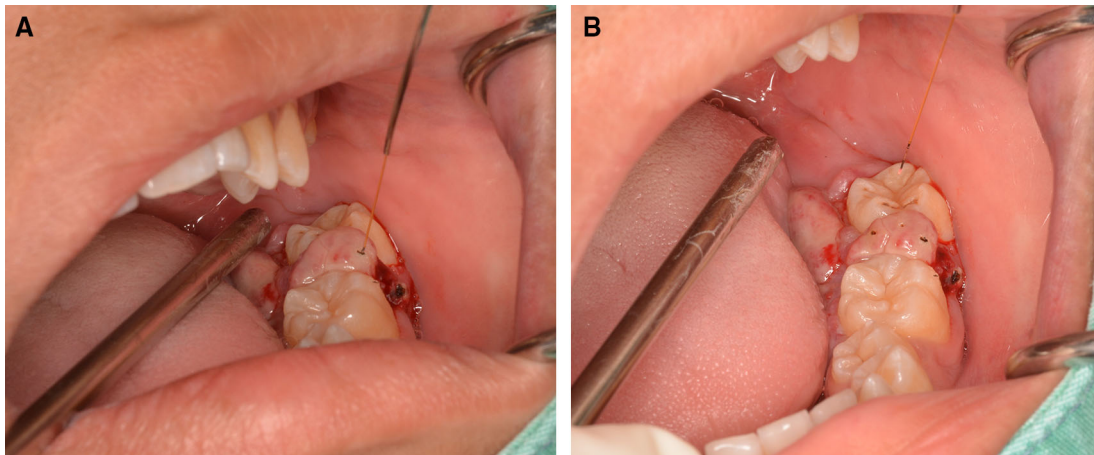


Figure 4. The interstitial-intralesional laser technique. A. The optical fiber was inserted into the lesion, beginning at the base of the lesion and then progressing to the top. The optical fiber was placed tangentially to the tooth and root surface. B. After a single treatment with interstitial-intralesional laser therapy on four areas.

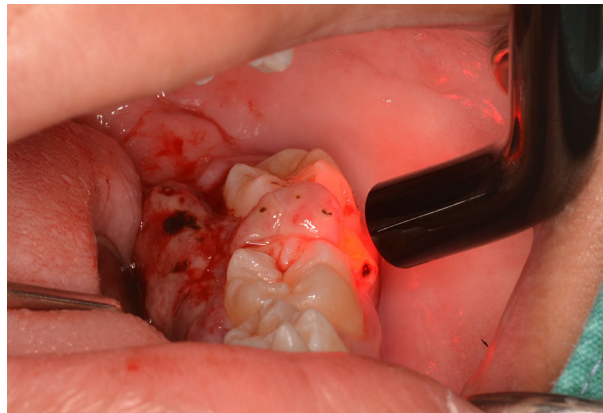


Figure 5. Photobiomodulation using a 635 nm diode laser via an 8 mm optical fiber.

The patient was invited to have appointments for interstitial-intralesional laser therapy as previously described every two to three weeks. The remission of the pyogenic granuloma was observed, as shown in [Figure 6A, B and C](#).

After two months of follow-up, the pyogenic granuloma involving soft tissue lesion was completely resolved. Tooth no. 37 returned to the normal position. The degrees of mobility of tooth no. 36 and tooth no. 37 were reduced to first-degree and second-degree mobility, respectively. The periodontal pocket was approximately 4 to 6 mm. The patient was treated with LANAP under local anesthesia to preserve the teeth.

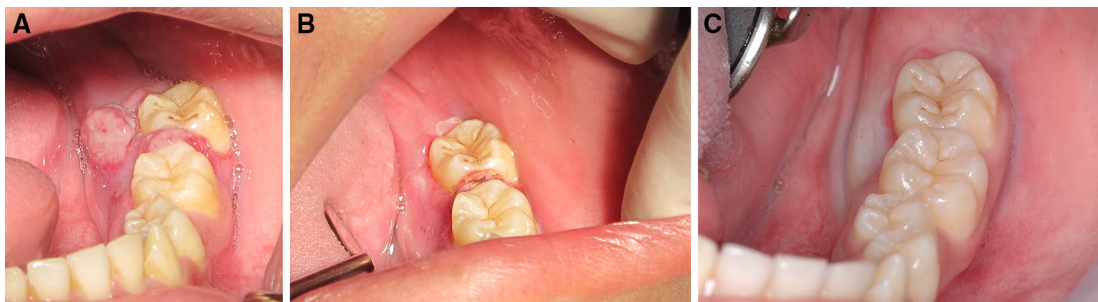

Figure 6. The clinical outcomes after interstitial-intralesional laser therapy. A. 2 weeks after the first therapy. B. 2 weeks after the second therapy. C. 3 weeks after the third therapy.

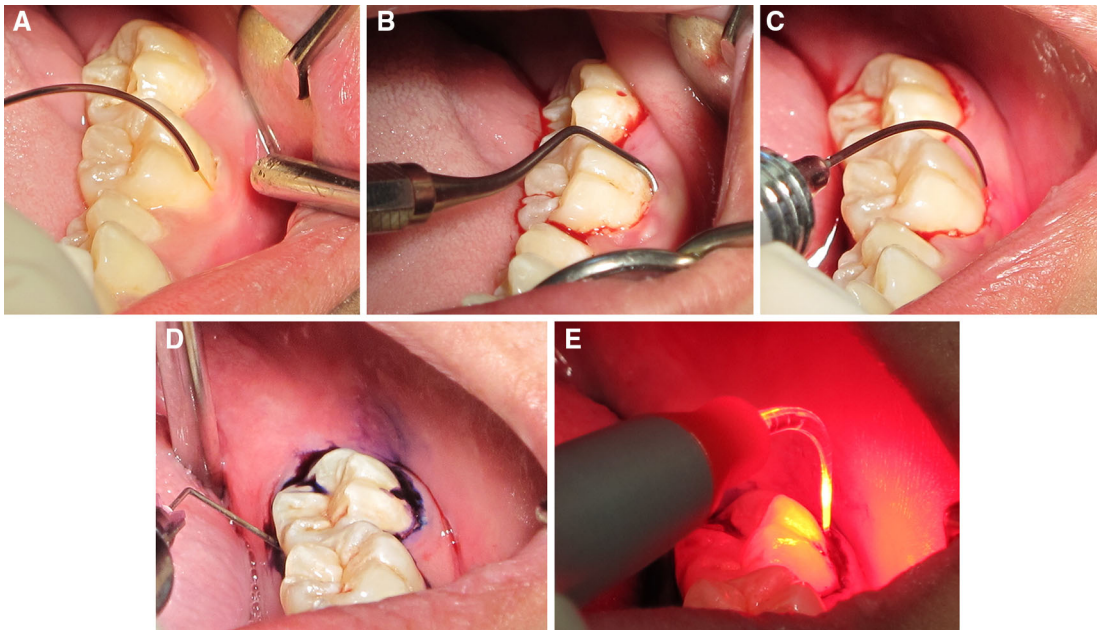


Figure 7. The LANAP procedure. A. The 980 nm diode laser was used for dilating the gingival sulcus. B. Scaling and root planning with hand instruments. C. The 980 nm diode laser was used for ablating the long junctional epithelium and granulation tissue in the gingival sulcus. D. Toluidine blue was injected as a photosensitizer into the gingival sulcus. E. The gingival sulcus was irradiated with a 635 nm diode laser via a 200-micron flexible tip to initiate photosensitizer.

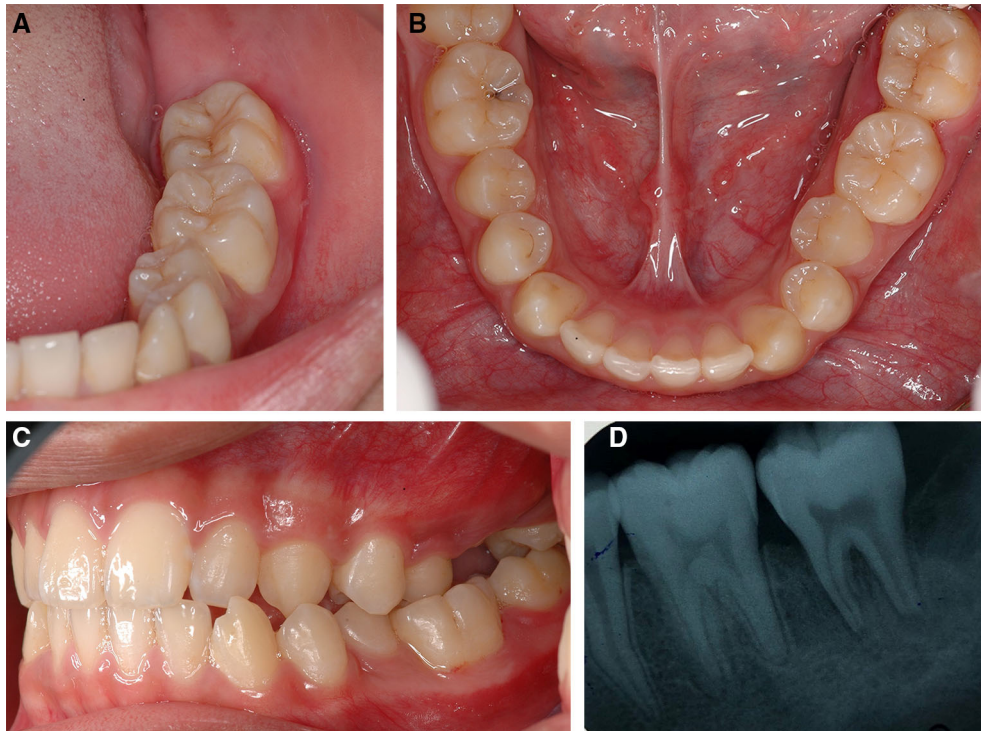


Figure 8. The clinical outcomes after LANAP procedure. A, B and C. Intraoral features after LANAP showing the normal appearance of the gingivae of the lower left molars and the repositioning of the teeth to their previous location and occlusion. D. Periapical radiograph of tooth no. 36 and tooth no. 37 showing an increase in periapical radiopaque characteristics in the previous defect.

The LANAP procedure consisted of three steps⁴ as follows:

Step 1: After supragingival scaling with an ultrasonic scaler, a 980 nm diode laser at 0.7 W and continuous wave was delivered via a 200-micron optical fiber into the gingival sulcus (Figure 7A). Then, it was followed by scaling and root planning (Figure 7B).

Step 2: The epithelium and granulation tissue in the gingival sulcus was photoablated with a CW 980 nm diode laser at 2 W and continuous wave via a 200-micron optical fiber (Figure 7C).

Step 3: Photodynamic therapy was administered using 0.1% toluidine blue as a photosensitizer and a 635 nm diode laser at 200 mW and CW for 15 sec via a 200-micron flexible optical fiber as a light source (Figure 7D and E).

After one month of LANAP, tooth no. 37 showed only first-degree mobility. No recurrence of the pyogenic granuloma was observed. The periodontal pocket depth was reduced, and no gingival recession of tooth no. 36 and tooth no. 37 was observed. The periapical radiograph showed improvement through the indication of bone formation at the periapical areas of tooth no. 36 and tooth no. 37, as shown in Figure 8. The second LANAP was conducted to maintain the periodontal status. There was no adverse and unanticipated event in overall treatments and outcomes.

The chronology of the treatment regime for this patient as follows:

1. interstitial-intralesional laser therapy with photobiomodulation
2. repeating treatments of interstitial-intralesional laser therapy for 2 sessions every two to three weeks
3. the LANAP at a two-month after the third session of the interstitial-intralesional laser therapy and
4. repeating the final LANAP a month after the first LANAP.

Due to the limitation of travelling from the COVID-19 pandemic, the patient was followed up by the dentist at his local health services. We followed the patient for another two sessions every three months for a 6-month. There had been still no sign of recurrent of the lesion.

The patient and his parent were satisfied with the less invasion procedures and remission of the lesion with tooth preservation. Therefore, they allowed the authors as a team of surgeons to present and report this treatment for this may benefit the others who have the same condition.

Discussion

The selection of laser wavelengths for biopsy and therapy is an important choice. An infrared diode laser was chosen in this case because of its low absorption by water of soft tissue and its capacity to generate more heat producing a deeper coagulative zone. This resulted in ablation with hemostasis.²

In this case, using a 635 nm diode laser at a power less than 0.5 W not only initiated clot formation but also resulted in photobiomodulation, which allowed a positive response to the healing process, such as an increase in microcirculation, the stimulation of cell growth, and a reduction in inflammatory substances.⁵

The treatment of the pyogenic granuloma in this report preserved the teeth and surrounding periodontal tissue. This outcome was different from that of a previous report in which the treatment of a pyogenic granuloma at tooth no. 11 in an 11-year-old female patient by total excision of the lesion resulted in gingival defects. The patient had to undergo free connective tissue graft.⁶ Our technique with combined laser therapy showed no gingival defect after the resolution of the lesion.

Regarding the LANAP used in this case report, it was based on the techniques of De Angelis *et al.*⁴ which combined photoablation and photodynamic therapy. This differed from other LANAP techniques by using only either Nd:YAG laser⁸ or diode laser⁹ for ablating epithelium and granulation tissue in the gingival pocket and root resurface.

In addition, there was a case report with a similar lesion: an aggressive pyogenic granuloma near the area of tooth no. 46 and no. tooth no. 47 in an 11-year-old female patient. With the use of surgical excision, tooth no. 46 near the lesion

had to be extracted.⁷ While in our patient, who was treated by a combination of interstitial-intralesional laser therapy, photocoagulation and LANAP, we were able to preserve the teeth and eliminate the lesion.

Conclusions

From this report, a pyogenic granuloma with extensive periapical bone loss in a 13-year-old Thai male patient was treated with 980 nm and 635 nm interstitial-intralesional laser therapy, photocoagulation and LANAP. After six months of follow-up, there was no recurrence of the lesion and no complication of gingival recession. The periodontal status was improved. Therefore, we propose a combination of interstitial-intralesional laser therapy, photocoagulation and LANAP for the treatment of aggressive pyogenic granulomas to preserve the teeth involved in the lesions.

Author contributions

AK: Data Curation, Investigation, Methodology, Visualization, Writing – Original Draft Preparation

PK: Data Curation, Investigation, Visualization, Writing – Original Draft Preparation

SS: Conceptualization, Methodology, Project Administration, Supervision, Writing – Review & Editing

Data availability

All data underlying the results are available as part of the article and no additional source data are required.

Reporting guidelines

Figshare. CARE flowchart. DOI: <https://doi.org/10.6084/m9.figshare.20367705>

References

- Jafarzadeh H, Sanatkhan M, Mohtasham N: **Oral pyogenic granuloma: a review.** *J. Oral Sci.* 2006; **48**(4): 167–175.
[Publisher Full Text](#)
- Black JF, Wade N, Barton JK: **Mechanistic comparison of blood undergoing laser photocoagulation at 532 and 1,064 nm.** *Lasers Surg. Med.* 2005; **36**(2): 155–165.
[PubMed Abstract](#) | [Publisher Full Text](#)
- Azma E, Razaghi M: **Laser treatment of oral and maxillofacial hemangioma.** *J. Lasers Med. Sci.* 2018; **9**(4): 228–232.
[PubMed Abstract](#) | [Publisher Full Text](#)
- De Angelis N, Hanna R, Signore A, et al.: **Effectiveness of dual-wavelength (Diodes 980 Nm and 635 Nm) laser approach as a non-surgical modality in the management of periodontally diseased root surface: a pilot study.** *Biotechnol. Biotechnol. Equip.* 2018; **32**(6): 1575–1582.
[Publisher Full Text](#)
- Karoussis IK, Kyriakidou K, Psarros C, et al.: **Effects and Action Mechanism of Low Level Laser Therapy (LLLT): Applications in Periodontology.** *Dentistry.* 2018; **08**(09): 4–10.
[Publisher Full Text](#)
- Joda T: **Esthetic management of mucogingival defects after total excision in a case of pyogenic granuloma.** *Eur. J. Esthet. Dent.* 2012; **7**(2): 110–119.
[PubMed Abstract](#)
- Kumar D, Agarwal T: **A Case Report: Aggressive Pyogenic Granuloma.** *Dent. J. Adv. Stud.* 2019; **07**(01): 046–050.
[Publisher Full Text](#)
- Jha A, Gupta V, Adinarayan R: **LANAP, Periodontics and Beyond: A Review.** *J. Lasers Med. Sci.* 2018; **9**(2): 76–81.
[PubMed Abstract](#) | [Publisher Full Text](#) | [Free Full Text](#)
- Chandra S, Shashikumar P: **Diode Laser - A Novel Therapeutic Approach in the Treatment of Chronic Periodontitis in Type 2 Diabetes Mellitus Patients: A Prospective Randomized Controlled Clinical Trial.** *J. Lasers Med. Sci.* 2019; **10**(1): 56–63.

Open Peer Review

Current Peer Review Status:  

Version 3

Reviewer Report 10 October 2022

<https://doi.org/10.5256/f1000research.139459.r152706>

© 2022 Namour S. This is an open access peer review report distributed under the terms of the [Creative Commons Attribution License](#), which permits unrestricted use, distribution, and reproduction in any medium, provided the original work is properly cited.



Samir Namour 

Laser Application in Dental Medicine, Department of Dental Sciences, Faculty of Medicine, University of Liege, Liege, Belgium

The manuscript can be indexed in this last version.

Competing Interests: No competing interests were disclosed.

Reviewer Expertise: Oral surgery, laser dentistry

I confirm that I have read this submission and believe that I have an appropriate level of expertise to confirm that it is of an acceptable scientific standard.

Version 2

Reviewer Report 07 September 2022

<https://doi.org/10.5256/f1000research.138280.r149597>

© 2022 Namour S. This is an open access peer review report distributed under the terms of the [Creative Commons Attribution License](#), which permits unrestricted use, distribution, and reproduction in any medium, provided the original work is properly cited.



Samir Namour 

Laser Application in Dental Medicine, Department of Dental Sciences, Faculty of Medicine, University of Liege, Liege, Belgium

Dear Editor,
Authors perfectly adapted the new version of their manuscript.

It still one correction to do before indexing:

Erase the words "**and hemostasis**" from the page 4, paragraph 5th: The sentence becomes: ***"This treatment was then immediately followed by treatment with using a 635 nm diode laser via an 8 mm optical fiber at 100 mW, continuous wave and 4 J/cm² with non contact mode to the lesion at the buccal and lingual sites for 1 session per area to achieve photobiomodulation effects (Figure 5)."***

Because the energy of the Photobiomodulation is not high enough to produce homeostasis effect (very low energy are not able to generate heat). There is a bio-modulation effects only.

There no need to reevaluate the manuscript again after this minor correction. The manuscript can be directly indexed.

Competing Interests: No competing interests were disclosed.

Reviewer Expertise: Oral surgery, laser dentistry

I confirm that I have read this submission and believe that I have an appropriate level of expertise to confirm that it is of an acceptable scientific standard.

Author Response 04 Oct 2022

Sajee Sattayut, Khon Kaen University, Khon Kaen, Thailand

We feel very grateful for your kind and keen suggestion. The modification was made as follows:-

This treatment was then immediately followed by treatment with using a 635 nm diode laser via an 8 mm optical fiber at 100 mW, continuous wave and 4 J/cm² with non contact mode to the lesion at the buccal and lingual sites for 1 session per area to achieve photobiomodulation (Figure 5). It was interesting that an initial blood clot was also observed over the irradiated area.

We just would like to report an interesting result on blood clot formation after photobiomodulation. Your suggestion is true. The dose which we used would not produce any photothermal effect.

Competing Interests: No competing interests

Version 1

Reviewer Report 22 August 2022

<https://doi.org/10.5256/f1000research.134716.r146327>

© 2022 Namour S. This is an open access peer review report distributed under the terms of the [Creative Commons Attribution License](#), which permits unrestricted use, distribution, and reproduction in any medium, provided the original work is properly cited.



Samir Namour

Laser Application in Dental Medicine, Department of Dental Sciences, Faculty of Medicine, University of Liege, Liege, Belgium

Very interesting paper. Authors treated with success the problem of severe bone resorption and tooth mobility that can result in teeth loss by preserving the proximal part of the tumor to avoid food retention and pocket complication in case of total excision of the proximal part at the tumor at the first step of surgery. This way offers a new and original way to treat this kind of risk. The paper is very interesting and an excellent and smart procedure to avoid future pocket complications and the loss of mobile teeth. Congratulations. To resume, this case report is bringing a new procedure and a new clinical management for the treatment of this kind of sensitive clinical cases. I highly recommend the indexing of this paper.

However, we advise authors to do some adaptations to the manuscript:

1. Adaptation of the title to the content of the manuscript:

Actually, the title is : **Case Report: Interstitial-intralesional laser therapy and laser-assisted new attachment procedure for the treatment of an aggressive pyogenic granuloma**. My proposition is to make it as follow: "**Interstitial-intralesional laser therapy and laser-assisted new attachment procedure for the treatment of alveolar bone loss provoked by an aggressive pyogenic granuloma. Case Report**".

1. In the case report description:

- Second paragraph: the sentence is: "*The periapical radiograph showed distinct periapical bone destruction of tooth no. 36 and tooth no. 37*". We propose to add the words: and proximal in the sentence. The sentence becomes as follow: "**The periapical radiograph showed distinct periapical and proximal bone destruction of tooth no. 36 and tooth no. 37** "
- In the description of the photobiomodulation (PBM) paragraph: Authors have to add, despite the description in the photo 5 showing the way of application, a descriptive text mentioning: sites of application of PBM and the way of application, contact or non-contact, more details despite the photo. They have to also mention the total irradiation time per session, diameter of the fiber, etc.
- In the same paragraph of PBM, authors have to erase the word "**photocoagulation**". Because the photobiomodulation can not deliver enough energy to heat tissue and to provoke any coagulate. It is a contradiction with the aim of the Photobiomodulation except if they omit to indicate the power used to induce a coagulation. The Diode (980 nm) can induce a coagulation under some irradiation conditions. The sentence becomes : "*...continuous wave. and 4 J/cm² to achieve photocoagulation and photobiomodulation effects (Figure 5)*".
- Authors have to add a paragraph with the Indication of the chronology of different treatments. Three procedures were used for the complete treatment: The interstitial-

intralesional laser therapy, Photobiomodulation and LANAP were used in the treatment. Authors have to indicate clearly the chronology details. All of the 3 procedures were used in the same session or separately. We understand that Covid pandemic delayed some sessions, but authors should resume and indicate, in a separate paragraph the exact and advised chronology of 3 procedures per each session, the optimal timing for the different sessions and the chronology of the 3 procedures. Did they use the 3 procedures one after another in the same session or in separate sessions? What is the time between sessions? Their precise details and their news protocol has to allow other practitioners to perform similar procedures in order to obtain similar results.

2. In the discussion authors wrote :

- First paragraph: "*An infrared diode laser was chosen in this case because of its hemoglobin absorption ability. This resulted in ablation with hemostasis*". We advise authors to adapt their sentence similar to this way: "**An infrared diode laser was chosen in this case because of its low absorption ability by water of soft tissue and its capacity to generate deeper and more heat. This resulted in ablation with hemostasis**".

In fact, the diode laser (980 nm) has low absorption by hemoglobin. But because of its low absorption by water and by consequence this low absorption by water allows this wavelength to have a deeper penetration in tissue resulting in an important heat generation allowing coagulation.

- Second paragraph, the sentence: "*For the photocoagulation technique, in this case, using a 635 nm diode laser at a power less than 0.5 W not only promoted clot formation but also resulted in photobiomodulation, ...*" We advise authors to reformulate or to erase their paragraph because the Diode laser 635 nm (red light) at 0.1 W (energy delivered in the case report) cannot coagulate. This wavelength at 0.1 W can only induce a Photobiomodulation. To induce a coagulation, the delivered energy has to be used at high output power. We advise authors to erase the word: "**photocoagulate**" from their paragraph and replace it by "**Photobiomodulation**".

Again, congratulations to the authors for this new and very interesting clinical procedure. They are bringing to the lecturer a new way to treat this kind of disease avoiding the loss of teeth.

Is the background of the case's history and progression described in sufficient detail?

Yes

Are enough details provided of any physical examination and diagnostic tests, treatment given and outcomes?

Yes

Is sufficient discussion included of the importance of the findings and their relevance to future understanding of disease processes, diagnosis or treatment?

Yes

Is the case presented with sufficient detail to be useful for other practitioners?

Yes

Competing Interests: No competing interests were disclosed.

Reviewer Expertise: Oral surgery, laser dentistry

I confirm that I have read this submission and believe that I have an appropriate level of expertise to confirm that it is of an acceptable scientific standard, however I have significant reservations, as outlined above.

Author Response 28 Aug 2022

Sajee Sattayut, Khon Kaen University, Khon Kaen, Thailand

We are very grateful to your kind and smart advices. Those provide this manuscript more meaningful. We will modify the manuscript as suggested and will back to reply to you.

Competing Interests: No competing interests were disclosed.

Author Response 04 Sep 2022

Sajee Sattayut, Khon Kaen University, Khon Kaen, Thailand

Reviewer: Samir Nammour

Very interesting paper. Authors treated with success the problem of severe bone resorption and tooth mobility that can result in teeth loss by preserving the proximal part of the tumor to avoid food retention and pocket complication in case of total excision of the proximal part at the tumor at the first step of surgery. This way offers a new and original way to treat this kind of risk. The paper is very interesting and an excellent and smart procedure to avoid future pocket complications and the loss of mobile teeth. Congratulations. To resume, this case report is bringing a new procedure and a new clinical management for the treatment of this kind of sensitive clinical cases. I highly recommend the indexing of this paper.

However, we advise authors to do some adaptations to the manuscript:

Adaptation of the title to the content of the manuscript:

Actually, the title is : Case Report: Interstitial-intralesional laser therapy and laser-assisted new attachment procedure for the treatment of an aggressive pyogenic granuloma. My proposition is to make it as follow: "Interstitial-intralesional laser therapy and laser-assisted new attachment procedure for the treatment of alveolar bone loss provoked by an aggressive pyogenic granuloma. Case Report".

Response: The title was modified as your good suggestion.

In the case report description:

Second paragraph: the sentence is: "The periapical radiograph showed distinct periapical bone destruction of tooth no. 36 and tooth no. 37". We propose to add the words: and proximal in the

sentence. The sentence becomes as follow: "The periapical radiograph showed distinct periapical and proximal bone destruction of tooth no. 36 and tooth no. 37"

Response: More description of radiographic examination was wrote as you suggested.

In the description of the photobiomodulation (PBM) paragraph: Authors have to add, despite the description in the photo 5 showing the way of application, a descriptive text mentioning: sites of application of PBM and the way of application, contact or non-contact, more details despite the photo. They have to also mention the total irradiation time per session, diameter of the fiber, etc. In the same paragraph of PBM, authors have to erase the word "photocoagulation". Because the photobiomodulation can not deliver enough energy to heat tissue and to provoke any coagulate. It is a contradiction with the aim of the Photobiomodulation except if they omit to indicate the power used to induce a coagulation. The Diode (980 nm) can induce a coagulation under some irradiation conditions. The sentence becomes : "...continuous wave. and 4 J/cm² to achieve photocoagulation and photobiomodulation effects (Figure 5)".

Response: More details of laser irradiation and application were added as indicated in red. It was noted that we applied this photobiomodulation to achieve hemostasis effect of the lesion.

Therefore, the alteration was as below:-

This treatment was then immediately followed by treatment with using a 635 nm diode laser via an 8 mm optical fiber at 100 mW, continuous wave and 4 J/cm² with non-contact mode to the lesion at the buccal and lingual sites for 1 session per area to achieve photocoagulation and photobiomodulation and hemostasis effects (Figure 5).

Authors have to add a paragraph with the Indication of the chronology of different treatments. Three procedures were used for the complete treatment: The interstitial-intralesional laser therapy, Photobiomodulation and LANAP were used in the treatment. Authors have to indicate clearly the chronology details. All of the 3 procedures were used in the same session or separately. We understand that Covid pandemic delayed some sessions, but authors should resume and indicate, in a separate paragraph the exact and advised chronology of 3 procedures per each session, the optimal timing for the different sessions and the chronology of the 3 procedures. Did they use the 3 procedures one after another in the same session or in separate sessions? What is the time between sessions? Their precise details and their news protocol has to allow other practitioners to perform similar procedures in order to obtain similar results.

Response: The treatment procedures were defined in chronologically in the part of the case report.

_The chronology of the treatment regime for this patient as follows:-

1. interstitial-intralesional laser therapy with photobiomodulation
2. repeating treatments of interstitial-intralesional laser therapy for 2 sessions every two to three weeks
3. the LANAP at a two-month after the third session of the interstitial-intralesional laser therapy and
4. repeating the final LANAP a month after the first LANAP.

First paragraph: "An infrared diode laser was chosen in this case because of its hemoglobin absorption ability. This resulted in ablation with hemostasis". We advise authors to adapt their sentence similar to this way: "An infrared diode laser was chosen in this case because of its low absorption ability by water of soft tissue and its capacity to generate deeper and more heat. This resulted in ablation with hemostasis".

In fact, the diode laser (980 nm) has low absorption by hemoglobin. But because of its low absorption by water and by consequence this low absorption by water allows this wavelength to have a deeper penetration in tissue resulting in an important heat generation allowing coagulation.

Response: We accepted your advice by altering the sentence as your suggestion. An infrared diode laser was chosen in this case because of its low absorption by water of soft tissue and its capacity to generate more heat producing a deeper coagulative zone. This resulted in ablation with hemostasis.²

Second paragraph, the sentence: "For the photocoagulation technique, in this case, using a 635 nm diode laser at a power less than 0.5 W not only promoted clot formation but also resulted in photobiomodulation, ..." We advise authors to reformulate or to erase their paragraph because the Diode laser 635 nm (red light) at 0.1 W (energy delivered in the case report) cannot coagulate. This wavelength at 0.1 W can only induce a Photobiomodulation. To induce a coagulation, the delivered energy has to be used at high output power. We advise authors to erase the word: "photocoagulate" from their paragraph and replace it by "Photobiomodulation".

Response: We do appreciate your advice to reserve photocoagulation to be a phenomenon from photothermal reaction only besides explaining the real clinical outcome of hemostasis effect. Therefore, we modified the sentences as below:

In this case, using a 635 nm diode laser at a power less than 0.5 W not only initiated clot formation but also resulted in photobiomodulation, which allowed a positive response to the healing process, such as an increase in microcirculation, the stimulation of cell growth, and a reduction in inflammatory substances.⁵

Again, congratulations to the authors for this new and very interesting clinical procedure. They are bringing to the lecturer a new way to treat this kind of disease avoiding the loss of teeth.

Response: We deeply appreciated your kind consideration and suggestion.

Competing Interests: No competing interests were disclosed.

Reviewer Report 17 August 2022

<https://doi.org/10.5256/f1000research.134716.r146326>

© 2022 Luk K. This is an open access peer review report distributed under the terms of the [Creative Commons Attribution License](#), which permits unrestricted use, distribution, and reproduction in any medium, provided the original work is properly cited.



Kenneth Luk

Faculty of Dentistry, The University of Hong Kong, Hong Kong, China

In this case report, the treatment protocol with wavelengths were well thought out. Laser parameters and techniques were well documented. Patient management was comprehensive.

Pulsed Nd:YAG (1064nm) laser for LANAP protocol was cleared by the FDA in 2004.¹ Yukna demonstrated LANAP protocol with Nd:YAG laser can produce new cementum-mediated connective tissue attachment.² Recently, LANAP seem to be broadened to include near-infra-red diode wavelengths.³

In this report, 980nm diode laser was used for LANAP protocol in step 1 and 2. Photodynamic therapy (PDT) with 635nm red laser was used in step 3. The initial LANAP protocol uses only Nd:YAG laser and no PDT was required. It would be more appropriate to describe the LANAP protocol in this case report as a modified LANAP protocol.

Alternative lasers for this case:

Like 980nm, 810nm, 940nm and 970nm are also well absorbed by haemoglobin and melanin. They can also be used for ablation, coagulation and photobiomodulation.

Instead of PDT, photothermal therapy can be considered using Indocyanine green as a photosensitiser with 810nm diode laser.

References

1. Gregg II R. H: The LANAP Protocol: laser-assisted new attachment procedure. *International Journal of Periodontics and Restorative Dentistry*. 2007. 87
2. Yukna RA, Carr RL, Evans GH: Histologic evaluation of an Nd:YAG laser-assisted new attachment procedure in humans. *Int J Periodontics Restorative Dent*. 2007; **27** (6): 577-87 [PubMed Abstract](#)
3. Shetty A, Ramachandra V. K, Shubhashini N. S, Anjali K, et al.: Diode laser assisted management of endo-perio lesion in maxillary incisor using LANAP: A Case Report. *International Dentistry South Africa*. 2010. 38-43

Is the background of the case's history and progression described in sufficient detail?

Partly

Are enough details provided of any physical examination and diagnostic tests, treatment given and outcomes?

Yes

Is sufficient discussion included of the importance of the findings and their relevance to future understanding of disease processes, diagnosis or treatment?

Yes

Is the case presented with sufficient detail to be useful for other practitioners?

Yes

Competing Interests: No competing interests were disclosed.

Reviewer Expertise: Lasers in Dentistry

I confirm that I have read this submission and believe that I have an appropriate level of expertise to confirm that it is of an acceptable scientific standard.

Author Response 28 Aug 2022

Sajee Sattayut, Khon Kaen University, Khon Kaen, Thailand

Many thanks for your comment on expanding the details of LANAP in terms of the development of techniques. We will add these to the manuscript.

Competing Interests: No competing interests were disclosed.

Author Response 04 Sep 2022

Sajee Sattayut, Khon Kaen University, Khon Kaen, Thailand

Reviewer: Ken Luk

In this case report, the treatment protocol with wavelengths were well thought out. Laser parameters and techniques were well documented. Patient management was comprehensive.

Response: Many thanks for your kind consideration.

Pulsed Nd:YAG (1064nm) laser for LANAP protocol was cleared by the FDA in 2004.¹ Yukna demonstrated LANAP protocol with Nd:YAG laser can produce new cementum-mediated connective tissue attachment.² Recently, LANAP seem to be broadened to include near-infra-red diode wavelengths.³

In this report, 980nm diode laser was used for LANAP protocol in step 1 and 2. Photodynamic therapy (PDT) with 635nm red laser was used in step 3. The initial LANAP protocol uses only Nd:YAG laser and no PDT was required. It would be more appropriate to describe the LANAP protocol in this case report as a modified LANAP protocol.

Alternative lasers for this case:

Like 980nm, 810nm, 940nm and 970nm are also well absorbed by haemoglobin and melanin. They can also be used for ablation, coagulation and photobiomodulation.

Instead of PDT, photothermal therapy can be considered using Indocyanine green as a photosensitiser with 810nm diode laser.

Response: Your suggestion on emphasizing the modification of LANPP technique used for this case report was added in a discussion.

Regarding the LANAP used in this case report, it was based on the techniques of De Angelis et al⁴ which combined photoablation and photodynamic therapy. This differed from other

LANAP techniques by using only either Nd:YAG laser⁸ or diode laser⁹ for ablating epithelium and granulation tissue in the gingival pocket and root resurface.

Owing to this being a case report, we would like to reserve other types of lasers or photosensitizers to be claimed that these would be applied as similar results have been proved in this study.

References

1. Gregg II R. H: *The LANAP Protocol: laser-assisted new attachment procedure. International Journal of Periodontics and Restorative Dentistry. 2007. 87*
2. Yukna RA, Carr RL, Evans GH: *Histologic evaluation of an Nd:YAG laser-assisted new attachment procedure in humans. Int J Periodontics Restorative Dent. 2007; 27 (6): 577-87 PubMed Abstract*
3. Shetty A, Ramachandra V. K, Shubhashini N. S, Anjali K, et al.: *Diode laser assisted management of endo-perio lesion in maxillary incisor using LANAP: A Case Report. International Dentistry South Africa. 2010. 38-43*

Response: We could not find your suggested references in the Pubmed database. The references in the Pubmed database that supported the same ideas as you suggested were included.

Jha A, Gupta V, Adinarayan R: LANAP, Periodontics and Beyond: A Review. *J Lasers Med Sci. 2018;9(2):76-81.*

Chandra S, Shashikumar P: Diode Laser - A Novel Therapeutic Approach in the Treatment of Chronic Periodontitis in Type 2 Diabetes Mellitus Patients: A Prospective Randomized Controlled Clinical Trial. *J Lasers Med Sci. 2019;10(1):56-63.*

Competing Interests: No competing interests were disclosed.

Comments on this article

Version 1

Reader Comment 07 Sep 2022

Sineewan Saowarat, faculty of dentistry, Khon Kaen university, KhonKaen, Thailand

This is an interesting article and case study. A *pyogenic granuloma (PG)* is a common benign tumor that is found in the oral cavity. In my general practice, PG has been treated by multiple treatment methods. For example, Improvement Oral hygiene, Removing calculus (scaling & root planing) and sometimes combined with total excision tumor. This article shows the novel and non-invasive treatment, using the knowledge of "**Laser**" for managing benign tumor in a young patient. There are **interstitial-intralesional laser therapy and LANAP**, these therapies can reduce post-op pain and bleeding, remove tumors and save teeth. In my opinion, the article is well written and provides evidence clearly about the progression and improvement of PG lesions.

Competing Interests: No competing interests were disclosed.

The benefits of publishing with F1000Research:

- Your article is published within days, with no editorial bias
- You can publish traditional articles, null/negative results, case reports, data notes and more
- The peer review process is transparent and collaborative
- Your article is indexed in PubMed after passing peer review
- Dedicated customer support at every stage

For pre-submission enquiries, contact research@f1000.com

F1000Research