



Malignancy course of pituitary adenoma in MEN1 syndrome: Clinical-Neuroradiological signs

Francesca Incandela^a, Paola Feraco^{b,c,*}, Valeria Putortì^a, Laura Geraci^a, Giuseppe Salvaggio^d, Caterina Sarno^d, Giuseppe La Tona^a, Giovanni Lasio^e, Cesare Gagliardo^a

^a Section of Radiological Sciences, Department of Biomedicine, Neuroscience and Advanced Diagnostics, University of Palermo, Palermo, Italy

^b Department of Experimental, Diagnostic and Specialty Medicine, University of Bologna, Bologna, Italy

^c Department of Neuroradiology, Ospedale S. Chiara, Azienda Provinciale Per i Servizi Sanitari, Trento, Italy

^d Department of Diagnostic Imaging and Interventional Neurosciences, University-Hospital P. Giaccone of Palermo, Palermo, Italy

^e Department of Neurosurgery, Humanitas Clinical and Research Center IRCCS, Rozzano, (MI), Italy

ARTICLE INFO

Keywords:

Pituitary neoplasms
Pituitary carcinoma
Pituitary adenoma
Neoplasm metastasis
Ki-67 antigen
Magnetic resonance imaging, MRI

ABSTRACT

Pituitary carcinomas (PCa) are extremely rare, indistinguishable from pituitary adenomas on histopathological grounds and have a poor prognosis. Most PCa start as PRL or ACTH secreting tumors in males, with relapsing invasive behaviour, refractoriness to medical and radiotherapy and increasing hormonal levels. The presence of distant metastases is still required for the diagnosis of PCa. The association with genetic endocrine diseases must be taken into account, since it adds further risk of evolution towards malignancy. Intradural spinal metastases have also been reported, so a complete craniospinal MR evaluation is recommended, when clinically indicated. We report a case of PCa, associated with MEN1 syndrome, with evidence of meningeal spread to the tentorium cerebelli, clival dura and spinal drop metastases mimicking spinal nerves schwannomas.

1. Introduction

Pituitary carcinomas (PCa) are extremely rare (less than 0.5 % of all pituitary tumours) [1], with a poor long-term prognosis [1–3]. The aetiology is unknown but most of them develop from the malignant transformation of a usually hormonally active invasive-aggressive adenoma. There are no histological features to distinguish a PCa from ordinary pituitary adenomas, therefore the diagnosis is very difficult prior to metastatization [2]. We report a case of relapsing invasive pituitary adenoma with evidence of meningeal spread to the posterior fossa and spine drop metastases. Moreover, we discuss the clinico-neuroradiological signs suggestive of malignancy.

2. Clinical observation and imaging findings

The medical history of a 43-year-old man with relapsing pituitary adenoma and multiple endocrine neoplasia type 1 (MEN1) syndrome is reported. Patient gave written informed consent in accordance with the Declaration of Helsinki for this case report.

In late 2004 at the age of 27, due to an erectile dysfunction, the patient underwent laboratory investigations that revealed hyperprolactinemia (serum prolactin: 4288 µU/mL). In August 2005 a pituitary

MRI showed the presence of a solid enhancing mass extending to the suprasellar region (at that time a 0,5 T GE Vectra was used; see Fig. 1). Dopamine agonist therapy was started and good control of serum prolactin levels was obtained. In 2007 elevated levels of PRL were again detected and a trans-nasal surgical excision (TNS) of the tumor was performed. A questionable “Rathke cleft cyst” diagnosis resulted from histological analysis.

In 2015 the patient underwent gonadotrophine stimulation to treat azoospermia. In 2016, because of worsening prolactin hormone levels, a pituitary MRI showed a recurrent invasive pituitary lesion, invading the sphenoid sinus, extending beyond the suprasellar cistern and invading the III ventricle, displacing the optic chiasm. A trans-nasal 3D endoscopic extended approach was performed and histopathology was consistent with atypical pituitary adenoma (WHO grade II: PRL+, GH-, LH-, FSH-, TSH-, ACTH-; MIB1: 6–8 %). The post-operative course was complicated by formation of an intraventricular hematoma, which was removed, and by triventricular post haemorrhagic hydrocephalus treated with ventriculo-peritoneal shunting. The patient experienced bitemporal hemianopsia and complete hormonal substitution therapy was necessary thereafter.

In the following two years after surgery, the neuroimaging findings (thereafter a GE Signa HD 1.5 T was used) were stable with no signs of

* Corresponding author at: largo medaglie d'oro 9, 38122, Trento, Italy.

E-mail address: paola.feraco@apss.tn.it (P. Feraco).

<https://doi.org/10.1016/j.ejro.2020.100242>

Received 5 May 2020; Accepted 6 June 2020

2352-0477/ © 2020 The Authors. Published by Elsevier Ltd. This is an open access article under the CC BY-NC-ND license (<http://creativecommons.org/licenses/by-nc-nd/4.0/>).

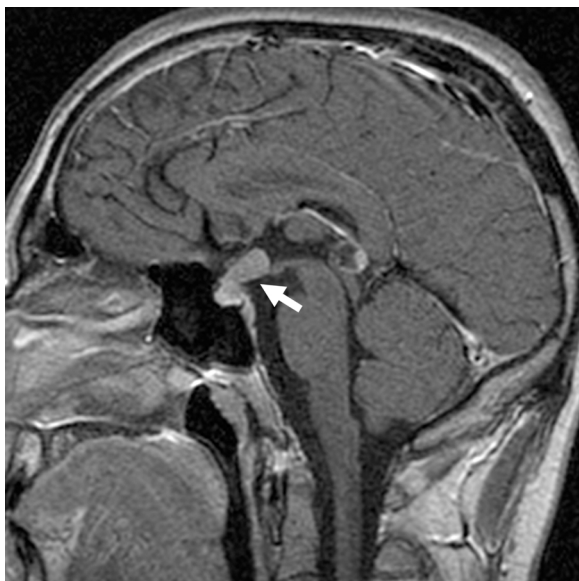

Fig. 1. Sagittal spin-echo (SE) T1-weighted (T1w) acquired after i.v. administration of gadolinium (+Gd) demonstrating a solid enhancing mass (arrow) that extends from the pituitary fossa to the chiasmatic cistern displacing the optic chiasm.

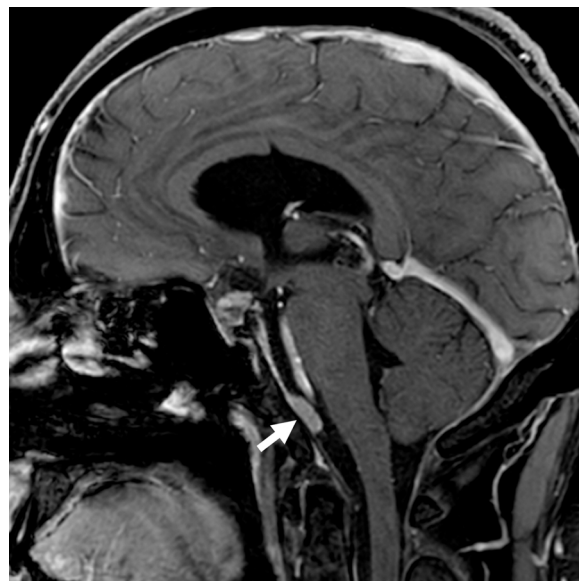


Fig. 3. 3D Sagittal fast spoiled gradient-echo (FSPGR) T1w + Gd from 2018 showing a small token of pathological tissue along the petroclival profile (arrow) misdiagnosed as radiation induced meningioma.

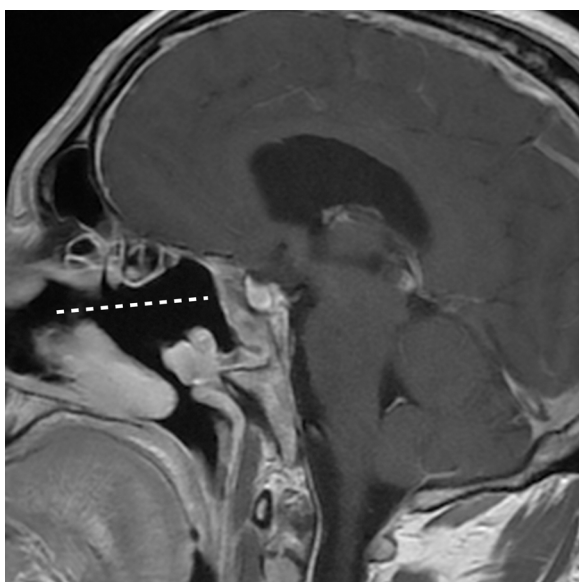


Fig. 2. Sagittal fast-spin-echo (FSE) T1w + Gd acquired in 2017 after the second surgical treatment. Findings are compatible with the result of the trans-nasal surgical excision (dotted line) with no evidence of pathological tissue outside the pituitary fossa.

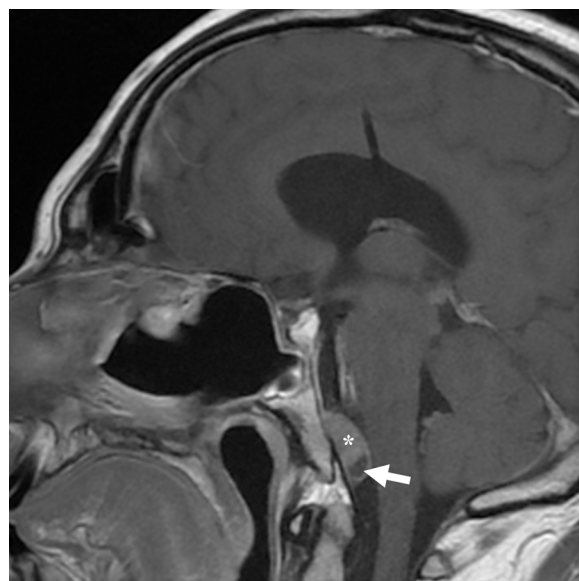


Fig. 4. Sagittal FSE T1w + Gd from 2019 showing increased volume of the previously reported tissue along the petroclival profile (asterisk) which is now characterized by an intralesional necrotic-cystic degeneration area (arrow).

disease recurrence (Fig. 2). In February 2018 parasellar recurrence occurred and fractionated radiotherapy (50 Gy x 25 fr) was delivered, without complications. A control MRI showed partial regression of the parasellar lesion, but revealed a focal thickening along the petroclival profile and the tentorial surface, wrongly interpreted as radiation-induced meningioma (Fig. 3). On subsequent follow-ups (January and April 2019) a progressive growth of the petroclival tissue was reported, with the onset of intralesional necrotic-cystic degeneration areas (Fig. 4).

From August 2019 the patient started complaining of left sided progressively increasing lombosciatalgia resistant to steroid treatment and causing walking disturbances. A lumbar MRI showed three intraspinal rounded lesions consistent with drop metastases or multiple

schwannomas; the largest at the L3 level presented areas of necrotic-cystic degeneration similar to those described in the petroclival region (Fig. 5). An FDG-PET scan (GE PET-CT Discovery 690), detected hypercaptation of the radiotracer in the retroclival region and in the intraspinal space at the L3 level (Fig. 6). In January 2020 an L3 laminectomy with complete microsurgical excision of the bigger lesion was performed. At surgery the lesion appeared to originate from the filum terminale. Histological diagnosis was of pituitary adenoma (PRL+, synaptophysin+, chromogranin+, GATA3-, CKpool-, S100-, SOX10-; MIB1: 5%).

In February 2020 the patient presented with occipital headache not responding to analgesics. A pituitary MRI revealed a huge increase in volume of the heterogeneous petroclival and parasellar tissue, extending down to the atlanto-occipital joint, obliterating the foramen magnum and the interpeduncular-prepontine cisterns, with

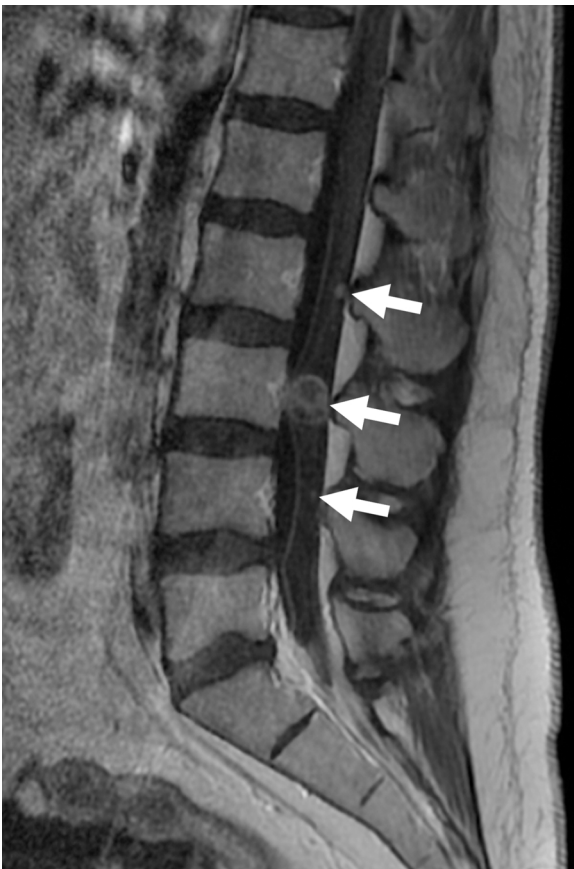

Fig. 5. Sagittal FSE T1w + Gd of the lumbar spine from September 2019 showing multiple intraspedal round dural solid lesions consistent with drop metastasis (arrows). The largest is at the L3 level and also show areas of necrotic-cystic degeneration as the tissue described along the petroclival profile (see Fig. 4).

compressive effect on the brainstem and fourth ventricle (Fig.7). Multiple small solid lesions strictly connected with the tentorial cerebellar surface (Fig. 8) were also demonstrated. New surgery, Gamma Knife treatment or salvage radiotherapy have been ruled out and multidisciplinary evaluation is now pending to establish a possible management of this tumor. Temozolomide approach has been proposed [4,5].

3. Discussion

Pituitary adenoma is one of the most common intracranial tumors, representing 10%–15% of all intracranial neoplasms. About 5% of pituitary adenomas present as invasive lesions and in the most recent WHO classification invasion is noted as an important feature to identify clinically aggressive tumors [1,6–8]. Such adenomas, however, are not histologically malignant; they are a subset of tumors prone to multiple recurrences, resistant to any conventional treatment and radiotherapy [9]. PCa is a very rare tumor, about 0,5% of all pituitary tumors, which remains poorly understood. It is still not clear indeed if a PCa is a pituitary adenoma which undergoes malignant transformation or if a PCa originates as an *ex-novo* malignancy [6], but usually it is the evolution of an invasive aggressive hormonally active adenoma that recurs over several years [10]. Both aggressive adenomas and carcinomas may show the same features, as high p53 immunoreactivity, similar mitotic activity and elevated Ki-67 labeling index. Pituitary carcinomas often have a higher Ki-67 labeling index than atypical adenomas, but this finding is seldom of diagnostic or prognostic value, even because no criteria for Ki-67 cutoff values have been established. Conversely a Ki-

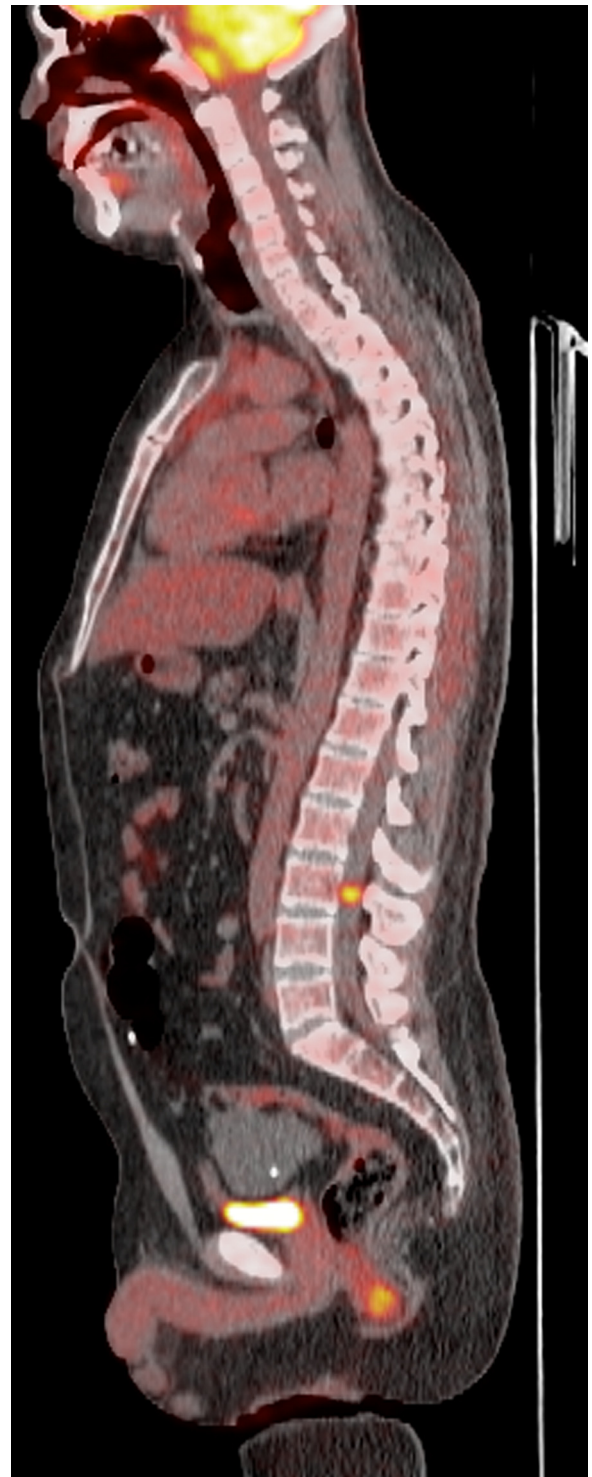


Fig. 6. FDG-PET examination (sagittal multiplanar reconstruction, MPR) from October 2019 showing the radio tracer uptake only in the retroclival region and in the intraspedal space at the L3 level.

67 labeling index > 10 % in an aggressive adenoma is considered to have high malignant potential [1,6,11]. Moreover, there are evidences that not all the previously called atypical adenomas have a clinically aggressive behaviour [9].

According to the 2017 WHO classification, the diagnosis of PCa requires evidence of metastatic disease either as separate non-contiguous foci within (craniospinal metastases) or outside (systemic metastases) the central nervous system [5,8,12].

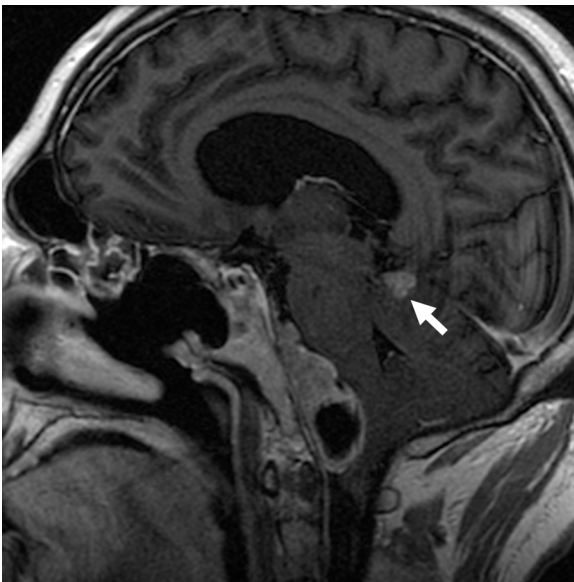

Fig. 7. Sagittal Fluid Attenuated Inversion Recovery (FLAIR) T1w + Gd from February 2020 that reveals a huge increase of the heterogeneous petroclival tissue obliterating periaxial cisterns with mass effect on the brainstem. A dural metastasis is also appreciable (arrow).

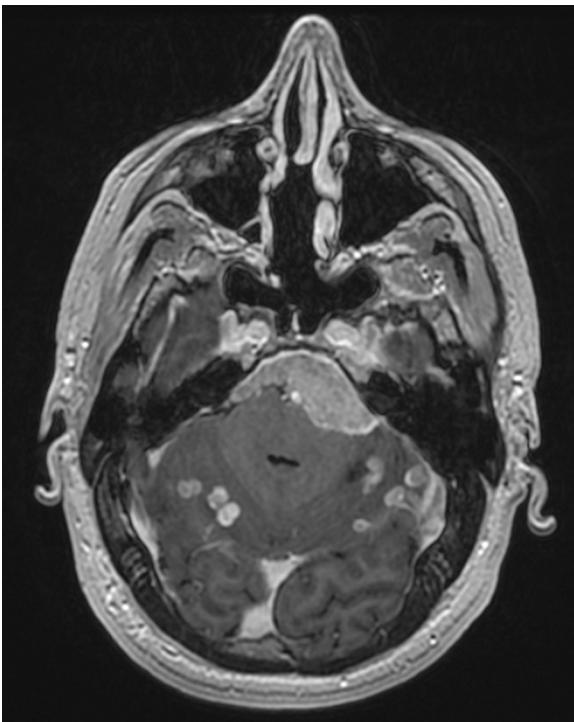


Fig. 8. Axial MPR from 3D Sagittal FSPGR T1w + Gd from February 2020 revealing multiple small solid enhancing lesions consistent with dural metastasis strictly connected with tentorium cerebelli.

The clinical course of the case we described, is a typical example of disease progression of a pituitary PRL secreting adenoma (once classified as atypical, WHO grade II), with a Ki-67 labeling index of 8%, consistent with a greater risk of malignancy. The latency to metastatic progression was 15 years but from the second TNS operation to metastatic disease just two years have passed, and notwithstanding the presence of a VP shunt, peritoneal seeding of the tumor did not occur. In our patient, the spinal intradural lesions were surgically removed, a diagnosis of pituitary PRL secreting adenoma metastasis was obtained,

consistent with the diagnosis of the sellar/suprasellar tumor. Furthermore, considering the associated hereditary disorder (MEN1), multiple spinal nerve schwannomas could be hypothesized. As a matter of fact, it might have seemed that they originated from the spinal roots rather than dural implants that are more frequently reported as dural sac occupying masses [6,13–16].

On the other hand, metastatic lesions typically show neuroradiological characteristics similar to the initial lesion (round intradural lesions with heterogeneous T2 hyperintensity with cystic components). Therefore, in cases with pituitary lesions recurrences, to avoid misdiagnosis and detect drop metastasis whole spine MRI examination should be considered in symptomatic patients.

Dural metastases are common, due to local invasion of the subarachnoid space, with subsequent tumor seeding along the dura surrounding the hemispheres, the cerebellum, and the cerebellopontine angle [1,13,14]; moreover, distant spinal metastases, albeit very rare, have also been reported as the result of dissemination of tumor cells in the cerebrospinal fluid and seeding by gravity, or perilymphatic spread along nerve roots. Intradural metastasis have been reported too, even if these are exceptional [15]. Systemic localizations are also possible through lymphatic or hematogenous transport, probably via the superior petrosal sinus drainage if the cavernous sinus is invaded by the tumor; extracranial sites may include the liver, lymph nodes, bones, and lungs [13,16,17]. MRI is the gold standard to detect pituitary pathology and shows high efficacy in detecting metastatic lesions also [18], but to perform a whole body scan a strong clinical suspicion of metastatic disease should be present. Although invasiveness is not indicative of malignancy, the evidence of invasion of sphenoid and cavernous sinus on pituitary MRI, should be considered a “red flag” because of a higher risk of developing a PCa [19], forcing strict, lifelong, follow ups.

Despite a radical surgical removal of the adenoma, persisting high levels of hormones or progressive worsening of the secretory state under adequate medical therapy, coupled with the results of the pathological examination, may imply malignancy and might indicate the presence of metastases. Moreover, the lack of efficacy of conventional radiotherapy or Gamma Knife treatment in patients with invasive hormonally active tumors, as shown by the clinical course of our case, may also anticipate a more aggressive clinical course with a worse prognosis [2,20].

In our case, a MEN1 syndrome was present. Only a few similar cases of MEN1 syndrome associated with a pituitary carcinoma have been described in the literature (including prolactin and plurihormonal secreting pituitary carcinomas) [21]. Thus, in patients with pituitary adenomas with an aggressive behaviour, genetic endocrine disorders must be evaluated, since MEN1 is usually associated with more aggressive pituitary tumors and this may add further risk of possible evolution towards malignancy. In particular, our patient showed a specific mutation not previously described in the literature: exon 10, 1666 G > T (E556X).

In this case rapid enlargement of the tumor occurred after human chorionic gonadotropin (hCG) hormone therapy for pituitary hypogonadism-related infertility. Some studies reported evidences that exogenous hCG enhances the viability of cancer cells and promotes the growth of tumors in mice [22]. Atypical pituitary adenomas might be at risk of progression during hCG hormone therapy, but further studies are needed to confirm this theory.

Finally, our case could suggest a possible inductive role of radiotherapy for pituitary carcinoma development. Indeed, many studies emphasize the risk of radiation induced tumors after fractionated radiotherapy, that would seem to be linked to different factors such individual genetic susceptibility [23,24].

As illustrated by our case, frequent endocrinological and neuroimaging surveillance is crucial for early detection of malignant transformation with possible metastatic progression of aggressive pituitary tumors.

4. Conclusion

Malignant transformation of a pituitary adenoma into a pituitary carcinoma is very rare, but aggressive PRL or ACTH secreting adenomas, especially in young male patients, should be submitted to strict endocrinological and neuroradiological follow ups as they have a higher potential of clinically malignant transformation. This case is an excellent example of disease progression over sixteen years, with relapsing pituitary adenoma, increasing level of prolactin not responding to therapy, development of dural metastasis and intraspeccal drop metastasis as the results of a malignant progression. In these rare situations, investigation of the underlying genetics is suggested since some endocrine syndromes, like MEN1, may add a further risk of malignant transformation. Even the eventual role of HGC therapy on tumor evolution should be more thoroughly investigated, particularly when neuroendocrine tumors are involved. MRI shows high sensitivity in assessing pituitary disease progression; a complete MRI craniocervical evaluation should be performed when dissemination is suspected in symptomatic patients.

Grant support

N/A.

Authorship credit

IF, PV, GL, SC, FP and GC: concept and design of study, acquisition and interpretation; IF, PV, FP, GL and CG: drafting the article and revising it critically for intellectual content; All authors: final approval of the version to be published.

Declaration of Competing Interest

The authors declare that they have no conflict of interest.

References

- [1] M. Lopes, S. Beatriz, The 2017 World Health Organization classification of tumors of the pituitary gland: a summary, *Acta Neuropathol* 134 (2017) 521–535.
- [2] G.A. Katsas, P. Nomikos, G. Kontogeorgos, et al., Clinical review: diagnosis and management of pituitary carcinomas, *J. Clin. Endocrinol. Metab.* 90 (2005) 3089–3099.
- [3] A.P. Heaney, A.P., Clinical review: pituitary carcinoma: difficult diagnosis and treatment, *J. Clin. Endocrinol. Metab.* 96 (2011) 3649–3660.
- [4] P. Chanson, D. Maiter, The epidemiology, diagnosis and treatment of Prolactinomas: the old and the new, *Best Pract. Res. Clin. Endocrinol. Metab.* 33 (2019) 101290.
- [5] G. Raverot, P. Burman, A. McCormack, et al., European Society of Endocrinology Clinical Practice Guidelines for the management of aggressive pituitary tumours and carcinomas, *Eur. J. Endocrinol.* 78 (2018) G1–G24.
- [6] Y.Q. Wang, T. Fan, X.G. Zhao, et al., Pituitary carcinoma with intraspinal metastasis: report of two cases and review of the literature, *Int. J. Clin. Exp. Pathol.* 8 (2015) 9712–9717.
- [7] B.W. Scheithauer, K.T. Kovacs, E.R. Laws, et al., Pathology of invasive pituitary tumors with special reference to functional classification, *J. Neurosurg.* 65 (1986) 733–744.
- [8] B.T. Ragel, W.T. Couldwell, Pituitary carcinoma: a review of the literature, *Neurosurg. Focus* 16 (2004) E7.
- [9] G. Raverot, F. Castinetti, E. Jouanneau, et al., Pituitary carcinomas and aggressive pituitary tumours: merits and pitfalls of temozolomide treatment, *Clin. Endocrinol. (Oxf)* 76 (2012) 769–775.
- [10] M.B. Lopes, B.W. Scheithauer, D. Schiff, Pituitary carcinoma: diagnosis and treatment, *Endocrine* 28 (2005) 115–121.
- [11] K. Thapar, K. Kovacs, B.W. Scheithauer, et al., Proliferative activity and invasiveness among pituitary adenomas and carcinomas: an analysis using the MIB-1 antibody, *Neurosurgery* 38 (1996) 99–107.
- [12] P.J. Pernicone, B.W. Scheithauer, T.J. Sebo, et al., Pituitary carcinoma: a clinicopathologic study of 15 cases, *Cancer* 79 (1997) 804–812.
- [13] J. Seltzer, J.D. Carmichael, D. Commins, et al., Prolactin-secreting pituitary carcinoma with dural metastasis: diagnosis, treatment, and future directions, *World Neurosurg.* 91 (2016) e623–e678 676.
- [14] B.W. Scheithauer, R.V. Randall, E.R. Laws Jr. et al., Prolactin cell carcinoma of the pituitary, Clinicopathologic, immunohistochemical, and ultrastructural study of a case with cranial and extracranial metastases, *Cancer* 55 (1985) 598–604.
- [15] M. Sivan, D. Nandi, S. Cudlip, Intramedullary spinal metastasis (ISCM) from pituitary carcinoma, *J. Neurooncol.* 80 (2006) 19–20.
- [16] N. Hashimoto, H. Handa, S. Nishi, Intracranial and intraspinal dissemination from a growth hormone-secreting pituitary tumor, Case report, *J. Neurosurg.* 64 (1996) 140–144.
- [17] D.M. Atienza, R.J. Vigersky, E.E. Lack, et al., Prolactin-producing pituitary carcinoma with pulmonary metastases, *Cancer* 68 (1991) 1605–1610.
- [18] G.A. Katsas, A.B. Grossman, Malignant pituitary tumours, *Pituitary* 1 (1998) 69–81.
- [19] Z. Noorimotlagh, S.A. Mirzaee, S.S. Martinez, et al., Environmental exposure to nonylphenol and cancer progression Risk-A systematic review, *Environ. Res.* 184 (2020) 109263.
- [20] M. Philippon, M.I. Morange, M. Barrie, et al., Long-term control of a MEN1 prolactin secreting pituitary carcinoma after temozolomide treatment, *Ann Endocrinol (Paris)* 73 (2012) 225–229.
- [21] B.W. Scheithauer, K. Kovacs, V. Nose, et al., Multiple endocrine neoplasia type 1-associated thyrotropin-producing pituitary carcinoma: report of a probable de novo example, *Hum. Pathol.* 40 (2009) 270–278.
- [22] P. Khare, A. Bose, P. Singh, et al., Gonadotropin and tumorigenesis: direct and indirect effects on inflammatory and immunosuppressive mediators and invasion, *Mol. Carcinog.* 56 (2017) 359–370.
- [23] H. Nishioka, H. Ito, J. Haraoka, et al., Histological changes in the hypofunctional pituitary gland following conventional radiotherapy for adenoma, *Histopathology* 38 (2001) 561–566.
- [24] L. Xu, K. Khaddour, J. Chen, et al., Pituitary carcinoma: two case reports and review of literature, *World J. Clin. Oncol.* 11 (2020) 91–102.