

Received:
13 November 2018
Revised:
24 January 2019
Accepted:
13 March 2019

Online histological atlas of the Göttingen minipig brain

Cite as: Dariusz Orłowski, Andreas N. Glud, Nicola Palomero-Galagher, Jens Christian H. Sørensen, Carsten R. Bjarkam. Online histological atlas of the Göttingen minipig brain. *Heliyon* 5 (2019) e01363. doi: [10.1016/j.heliyon.2019.e01363](https://doi.org/10.1016/j.heliyon.2019.e01363)



Dariusz Orłowski^{a,*}, Andreas N. Glud^a, Nicola Palomero-Galagher^{b,c},
Jens Christian H. Sørensen^{a,d}, Carsten R. Bjarkam^e

^a Center for Experimental Neuroscience (Cense), Institute of Clinical Medicine – The Department of Neurosurgery, Aarhus University, Aarhus Universitetshospital, Palle Juul-Jensens Boulevard 165, Indgang J, Plan 1, J118-125, DK-8200 Aarhus N, Denmark

^b Institute of Neuroscience and Medicine (INM-1), Research Centre Jülich, 52425 Jülich, Germany

^c Department of Psychiatry, Psychotherapy and Psychosomatics, Medical Faculty, RWTH Aachen, Aachen, Germany

^d Department of Neurosurgery, Aarhus University Hospital, Aarhus Universitetshospital, Palle Juul-Jensens Boulevard 165, Indgang J, Plan 6, DK-8200 Aarhus N, Denmark

^e Department of Neurosurgery, Aalborg University Hospital, and Institute of Clinical Medicine, Aalborg University, Høbrovej 18-22, DK-9000 Aalborg, Denmark

* Corresponding author.

E-mail address: Dariusz.orlowski@gmail.com (D. Orłowski).

Abstract

Background: The cytoarchitecture of the Göttingen minipig telencephalon has recently been elucidated in the published article (Bjarkam et al., 2017). The aim of the current paper is to describe how such data can be presented in an online histological atlas of the Göttingen minipig brain and how this atlas was constructed.

Methods: Two sets of histological sections were used. One set was photographed in high resolution and labelled, the other set in low resolution (resized first set) was used for reference on the computer screen. The two sets of microphotographs enable, using the freely available JQuery Image Zoom Plugin, the subsequent construction of a simple HTML-based atlas web page with a “virtual microscope like” style, which allowed magnifying of the base image (low-resolution image) up to the maximum resolution of the high-resolution image. In addition, we describe how the established histological atlas can be accompanied by a set of similar T1-weighted MRI pictures.

Results and conclusion: Histological and MRI pictures are presented in atlas form on www.cense.dk/minipig_atlas/index.html. The described pipeline represent a

cheap and freely available way to present histological images, in online virtual microscopic atlas form, and may thus be of general interest to anyone who would like to present histological data accordingly.

Keywords: Anatomy, Neuroscience

1. Introduction

Neuroanatomical atlases are essential tools for studying the brain and its organization. In the last decades, most of such atlases were published in the form of printed books or articles (Bjarkam et al., 2017; Felix et al., 1999; Kornum et al., 2010; Paxinos and Watson, 2007; Saikali et al., 2010; Villadsen et al., 2018; Watanabe et al., 2001). Those books were usually quite expensive and due to their large size, not very handy to use. Likewise, the articles, due to size restrictions, often do not present overview pictures in high resolution. However, some articles have been associated with an MRI-image based atlas available for download (Saikali et al., 2010; Villadsen et al., 2018). Nowadays, development of high-speed internet connections and the widespread possibility to connect with the World Wide Web allows for low-cost publication of such atlases on the internet. E.g. see the excellent mouse and human brain atlases made by the Allen Institute for Brain Science on brain-map.org (Ding et al., 2016), or the map of the human brain integrating cellular-resolution, whole-brain cytoarchitectonics with receptor density, genetic, electrophysiological, fMRI, and connectivity data which has recently been made available to the public in the framework of the Human Brain Project (Amunts et al., 2014) (<https://www.humanbrainproject.eu/en/explore-the-brain/>). Thus, numerous internet based brain atlases, derived using histology and/or MRI are currently available for many species including human.

The Göttingen minipig has recently been introduced as a non-primate large animal alternative for neuroscience studies (Dolezalova et al., 2014; Sorensen et al., 2011). The brain of the minipig is relatively large (6 months, c.a. 65 g, 6 × 5 × 4 cm), gyrated, and permits to use the same neurosurgical methods and tools that are designed for humans (Bjarkam et al., 2017; Sorensen et al., 2011). Moreover, it is possible to use conventional imaging modalities like MRI, CT or PET (Sorensen et al., 2011). Likewise, it makes this model appropriate for preclinical testing of the new equipment and treatment paradigms, like e.g. deep brain stimulation (Orlowski et al., 2017; Sorensen et al., 2011). However, although several histological and MRI based atlases of the pig are available reflecting the increased use of pigs in neuroscience (Andersen et al., 2005; Felix et al., 1999; Saikali et al., 2010; Villadsen et al., 2018; Watanabe et al., 2001), to our knowledge, a detailed histological on-line atlas of the Göttingen minipig telencephalon was lacking.

Therefore, the aim of this project was to describe how the previously obtained cytoarchitectonic data on the telencephalon of the Göttingen minipig (Bjarkam et al., 2017) was converted into a user-friendly online “virtual microscope like” atlas using the freely available JQuery Image Zoom Plugin. The derived atlas is accompanied by a set of comparable T1-weighted MRI pictures, and is published on the World Wide Web, allowing free access for other researchers working with the minipig brain.

2. Materials and methods

2.1. Histology

The brain from a 1-year-old female Göttingen minipig was embedded *in toto* in paraffin, followed by sectioning into 15 µm thick coronal sections and Nissl stained as previously described in Bjarkam et al. (2017).

2.2. Microphotography

Twenty-four representative coronal sections, covering the minipig cerebrum, was selected with an intentional uneven interspacing so that only new levels with an obvious change in the anatomy compared to the former level are depicted. Accordingly, fewer sections cover the similar coronal anatomy of the frontal and occipital poles, whereas more sections are used to display the anatomically dissimilar coronal levels of the mid cerebrum. The sections, chosen to be used in the atlas, were photographed using a Leica DM5000B microscope with 1.25 x objective and attached Leica DFC480 color digital camera. For every section about 80–100 pictures were obtained and merged using the Adobe Photoshop CC program. The background of the images was corrected and image contrast and intensity optimized (Bjarkam et al., 2017). For use in the internet-based atlas, in order to decrease the image sizes and increase their sharpness, the images were resized to 50% of their original size using the Irfan View program (1996–2017, Irfan Skijan, <http://www.irfanview.com/>) with a resulting final picture size of 6836 × 8223 pixels. The images were saved in jpg file format with high quality (low compression factor).

2.3. MRI images

The histological sections were accompanied by twenty-four T1-weighted MRI images of the minipig brain. The scans were performed using a 3T MAGNETON Trio a Tim System (Siemens). Briefly, six, approx. 6 months old female Göttingen minipigs (Ellegaard Göttingen Minipigs APS, Dalmose, Denmark), weighing 12–15 kg at the imaging time, were used in this study as approved by the Danish National Council of Animal Research Ethics. Animals were initially anesthetized with 10 ml sedative mixture *intramuscular*, containing 4 ml ketamine (25 mg/mL;

Pfizer, Groton, CT, USA) and 6 ml midazolam (5 mg/mL; B. Braun, Frederiksberg, Denmark), followed by artificial ventilation and sevoflurane (ca. 2%; Abbot, Palatine, IL, USA) anesthesia which was used during the remaining procedure (Glud et al., 2017). The head of the animal was then fixed in a stereotaxic localizer box (NeuroLogic MARK III, Aarhus, Denmark) and each animal was scanned in a prone position on a 24-element spine matrix coil. On top of the stereotaxic frame, a 6-element body matrix coil was placed, covering the head. 3D T1-weighted Turbo Flash 3D T1 mode was used: Voxel size: $1 \times 1 \times 1$ mm, Number of slices: 176, FoV: 256×256 mm, TR: 2420 ms, TE: 3,7 ms, TI: 960 ms, flip angle: 9° , Averages: 2, read direction flow compensation, there was no interleave between the 1 mm slices. The imaging sequence was a 3D flash sequence and final image has 1 mm isotropic voxels. The sequence used inversion recovery (IR)-preparation to provide optimal T1-contrast (Glud et al., 2017). The scans were then compared with histology images and the scan-set with the best match with histological sections, in regards to anatomical landmarks, was chosen for presentation on the webpage. Afterwards, the plane of the MRI sectioning was manually adjusted using the RadiAnt DICOM Viewer (2009–2017, Medixant) to obtain the closest match to the overview plane of the histological sections. The resulting MRI sections were saved in png format with a final image dimension of 256×256 pixels. For subsequent presentation on the web page, the images were cropped to the area containing the brain and enlarged to the final size 460×480 pixels.

2.4. Web construction

To maintain the web page structure in an easy, flexible, and independent way from the server architecture, as well as to allow easy change of the used web server, the site was constructed using HTML5 + CSS web description language with a few JavaScript insertions. To ensure proper web standards, the code was validated with W3C Markup Validation Service (The World Wide Web Consortium, <https://validator.w3.org/>) and the W3C CSS Validation Service (The World Wide Web Consortium, <https://jigsaw.w3.org/css-validator/>). Lack of the need to use of PHP language or databases allows for easy transferring of the web site to another server by simple copying it. The atlas web page may also be tested offline, on a computer without configuration of internal web server and without internet access.

To allow the user to see the pictures in full resolution, JQuery Image Zoom Plugin was used (<http://www.elevateweb.co.uk/image-zoom>, 2012 Andrew Eades). This plugin is available under an MIT license, allowing free use and modification of the source code. Moreover, the Image Zoom plugin, differently from traditional virtual microscope systems (Mikula et al., 2008), requires only two pictures – one resized to fit the screen and used for navigation, and the other in full resolution used to show the enlarged fragment of the selection on the picture.

The actual web page design (www.cense.dk/minipig_atlas/index.html) is built using three main elements: A top bar with function buttons (Fig 1A and B), and two windows (frames): a smaller one on the left side which is used for showing thumbnails (Fig. 1A) and abbreviations (Fig. 1E), and a window on the right side serving as the main atlas page (Fig. 1A). The main atlas window is used for showing the atlas figures with their enlarged fragments, help features, and other information (Fig. 1A). The main frame, when the atlas image is open, contains embedded on the top a small navigation bar from where the user can open neighboring sections, the abbreviation list, or the MRI image (Fig 1A and D). The width of the main frame is automatically adjusted (with some limitations due to the size of the atlas picture) to the client screen resolution; similarly, the box with the enlarged image fragment is also adjusted to the window dimension. The size/magnification of the enlarged fragment may be regulated using the mouse wheel and is shown as a gray rectangle on the navigation picture within the brain section (Fig. 1C). The MRI image corresponding to the selected histological section is presented in the modal window, which can be opened as requested (Fig. 1D).

The nomenclature and abbreviations used in presented atlas were described before (Bjarkam et al., 2017) and are in accordance with principles established by Paxinos and Watson for the rat brain (Paxinos and Watson, 2007), but with some modification for pig brain structures which are not present in the rat brain. The list of

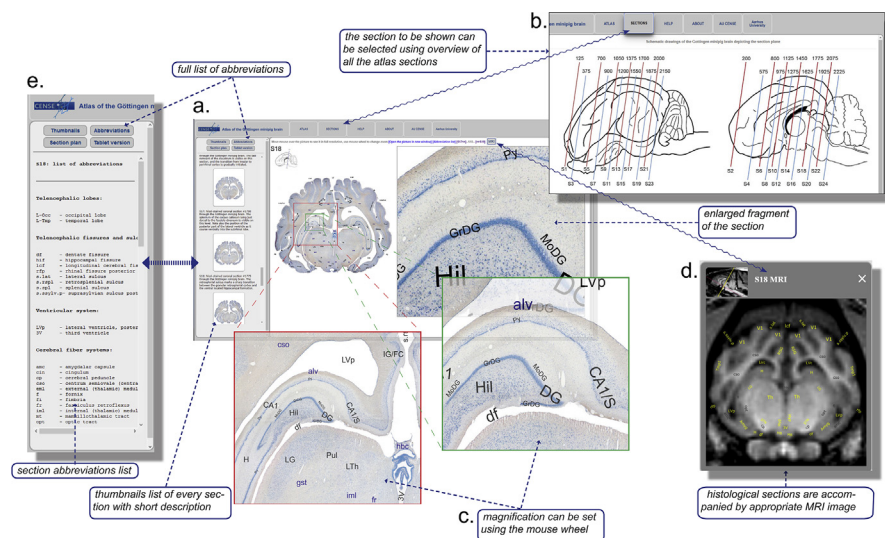


Fig. 1. The Göttingen minipig atlas webpage design and functionality. A) The main atlas window shows the selected coronal histological brain slice in full overview (low resolution) together with a smaller fragment in high magnification. B) The appropriate section can be chosen using the sagittal view of the brain with the depicted sections plan. C) The magnification of the enlarged fragment can be varied by use of the mouse wheel. D) All histological sections are accompanied by a similar corresponding labeled T1 MR image. E) A separate list of abbreviations can be opened for every selected atlas section. Furthermore, the full list of abbreviations contains hyperlinks to the first rostral atlas section where the abbreviated structure appears.

abbreviations can be shown separately for each selected atlas picture (Fig. 1E). Moreover, there is the possibility to show the full list of abbreviations grouped in anatomical order, or sorted in alphabetical order. Those lists include the links to the first atlas page where the structure appears rostrally to ease the search for the regions of interest.

3. Results and discussion

On www.cense.dk/minipig_atlas/index.html we present the derived histological atlas of the Göttingen minipig brain based on 24 coronal Nissl stained sections and 24 accompanying T1-weighted MR-images (Fig. 1). All main brain areas are identified and labeled. Moreover, on the histological pictures the approximate borders between different cortical areas are marked. A section of interest can be chosen by three different approaches: 1) using the sagittal view of the brain with embedded sectioning planes, 2) using the sidebar with descriptive thumbnails of all sections, or 3) by searching the structure of interest in the abbreviation list. To further ease of use, a separate list of abbreviations can be opened from the picture navigation panel of every picture, containing only those abbreviations, which are visible on the selected picture. One can switch, likewise, between neighboring sections using the small navigation panel visible together with the selected histological image. The accompanying MRI pictures can be opened for every selected histological section. However, it should be noted that although the sectioning planes of the selected histological and accompanying MRI images are similar, those images were produced using different brains, and therefore small differences might be present. We do not attempt to correct the MRI images nor present MRI images based on averaging. We have, on purpose, chosen to present the MRI images in a similar quality to the images obtained during the performance of in vivo experimentation where only short time imaging protocols are accessible. Thus, the displayed accompanying MRI images will allow for an easier matching of the structures visible on an obtained pre-operative MRI with the histological structures visible in the atlas.

The atlas is now accessible on the internet and can be freely used (provided proper citation) by other groups working with Göttingen minipigs. Some problems, however, still exist that need to be corrected. The used JQuery script sometimes freezes, especially in older web-browsers, or under low-speed network connections. For optimal screen presentation of the atlas pictures a relatively high resolution of the computer screen is needed (recommended at least 1600 pixels of horizontal resolution) making it difficult to work with this atlas on older computer systems. Moreover, the web page is, based on the use of Java- and JQuery script in combination with high-resolution images, not fully compatible with handheld devices such as tablets or smartphones. To overcome this, we have attached a simplified tablet version to the web page, which allows for visualization high-resolution picture in the album

format. Theoretically, there is a possibility for automatic web browser recognition, but our internal test showed that this function usually do not work correctly.

The presented atlas, with detailed cortical area delineations, is intended to aid Göttingen minipig brain experimental procedures including stereotaxy (Meidahl et al., 2016; Orłowski et al., 2017). Note, however, that due to the age dependent variable minipig skull and brain size, and to progressive frontal sinus pneumatization, our atlas does not include stereotactic coordinates. It is thus intended as an aid in localizing brain structures for MRI-guided stereotaxy as described in Bjarkam et al. (2009), or to help brain area identification on coronally obtained MRI, CT or PET images, or on post-mortem histological sections.

One of our aims was to keep the atlas structure simple and server independent, which resulted in our choice of the JQuery image zoom plugin, instead of using a virtual microscope or publishing the atlas pictures in fixed size. In the current form, one can view the whole cross-section (low resolution) and still at the same time have the ability to enlarge a selected fragment to show histology in detail (full resolution).

Future development of the atlas will include addition of the major fiber pathways reconstructed using MRI-based diffusion tensor imaging (Bech et al., 2018), as well as a more detailed segregation of the hypothalamus (Etrup et al., 2010), the nucleus accumbens (Meidahl et al., 2016), the substantia nigra (Nielsen et al., 2009), the subthalamic nucleus (Larsen et al., 2004), the septal nuclei, amygdala, thalamus and brain stem (research in progress). Our team also has plans to add histological images presenting fragments of the brain using various immunohistochemical methods, e.g. showing neurons positive for tyrosine hydroxylase or calbindin. It is also planned to update the JQuery image zoom plugin to a newest version (<http://igorlino.github.io/elevatezoom-plus/index.html>, 2018, Igor Lino).

The hand written structure of the atlas web page allows, on one hand, the portability and easy transfer of the page to the server, as well as the possibility to use an off-line version of the webpage. On the other hand, all additional changes will require edition of the established page source code, and some knowledge about web page structure and HTML coding.

4. Conclusions

Using freely available software and access to the internet, high-resolution histological sections and accompanying T1-weighted MRI images of the Göttingen minipig brain could be presented as an online atlas allowing “virtual microscopy like” analysis and precise identification of all major brain structures. The provided atlas will be useful for future pre-surgical planning and stereotaxy, and aid in the

identification of pig brain structures visible on acquired MRI, CT, PET and post-mortem histological material.

Declarations

Author contribution statement

Dariusz Orłowski, Carsten R. Bjarkam: Conceived and designed the experiments; Performed the experiments; Analyzed and interpreted the data; Contributed reagents, materials, analysis tools or data; Wrote the paper.

Andreas N. Glud: Performed the experiments; Analyzed and interpreted the data.

Nicola Palomero-Galagher: Performed the experiments; Analyzed and interpreted the data; Contributed reagents, materials, analysis tools or data.

Jens Christian H. Sørensen: Conceived and designed the experiments; Contributed reagents, materials, analysis tools or data.

Funding statement

This work was supported by the Danish Medical Research Council and the Lundbeck Foundation.

Competing interest statement

The authors declare no conflict of interest.

Additional information

Data associated with this study is available online at http://www.cense.dk/minipig_atlas/index.html.

Acknowledgements

The authors acknowledge with gratitude the skillful assistance of Mrs. F. Gün, Ms. D. Jensen, Ms. K. S. Bech and Mr. A. Meier.

References

Amunts, K., Hawrylycz, M.J., Van Essen, D.C., Van Horn, J.D., Harel, N., Poline, J.B., De Martino, F., Bjaalie, J.G., Dehaene-Lambertz, G., Dehaene, S., Valdes-Sosa, P., Thirion, B., Zilles, K., Hill, S.L., Abrams, M.B., Tass, P.A., Vanduffel, W., Evans, A.C., Eickhoff, S.B., 2014. Interoperable atlases of the human brain. *Neuroimage* 99, 525–532.

Andersen, F., Watanabe, H., Bjarkam, C., Danielsen, E.H., Cumming, P., DaNe, X.S.G., 2005. Pig brain stereotaxic standard space: mapping of cerebral blood flow normative values and effect of MPTP-lesioning. *Brain Res. Bull.* 66, 17–29.

Bech, J., Glud, A.N., Sangill, R., Petersen, M., Frandsen, J., Orłowski, D., West, M.J., Pedersen, M., Sorensen, J.C.H., Dyrby, T.B., Bjarkam, C.R., 2018. The porcine corticospinal decussation: a combined neuronal tracing and tractography study. *Brain Res. Bull.* 142, 253–262.

Bjarkam, C.R., Cancian, G., Glud, A.N., Ettrup, K.S., Jorgensen, R.L., Sorensen, J.C., 2009. MRI-guided stereotaxic targeting in pigs based on a stereotaxic localizer box fitted with an isocentric frame and use of SurgiPlan computer-planning software. *J. Neurosci. Meth.* 183, 119–126.

Bjarkam, C.R., Glud, A.N., Orłowski, D., Sorensen, J.C.H., Palomero-Gallagher, N., 2017. The telencephalon of the Gottingen minipig, cytoarchitecture and cortical surface anatomy. *Brain Struct. Funct.* 222, 2093–2114.

Ding, S.L., Royall, J.J., Sunkin, S.M., Ng, L., Facer, B.A., Lesnar, P., Guillozet-Bongaarts, A., McMurray, B., Szafer, A., Dolbeare, T.A., Stevens, A., Tirrell, L., Benner, T., Caldejon, S., Dalley, R.A., Dee, N., Lau, C., Nyhus, J., Reding, M., Riley, Z.L., Sandman, D., Shen, E., van der Kouwe, A., Varjabedian, A., Wright, M., Zollei, L., Dang, C., Knowles, J.A., Koch, C., Phillips, J.W., Sestan, N., Wohnoutka, P., Zielke, H.R., Hohmann, J.G., Jones, A.R., Bernard, A., Hawrylycz, M.J., Hof, P.R., Fischl, B., Lein, E.S., 2016. Comprehensive cellular-resolution atlas of the adult human brain. *J. Comp. Neurol.* 524, 3127–3481.

Dolezalova, D., Hruska-Plochan, M., Bjarkam, C.R., Sorensen, J.C., Cunningham, M., Weingarten, D., Ciacci, J.D., Juhas, S., Juhasova, J., Motlik, J., Hefferan, M.P., Hazel, T., Johe, K., Carromeu, C., Muotri, A., Bui, J., Strnadel, J., Marsala, M., 2014. Pig models of neurodegenerative disorders: utilization in cell replacement-based preclinical safety and efficacy studies. *J. Comp. Neurol.* 522, 2784–2801.

Ettrup, K.S., Sorensen, J.C., Bjarkam, C.R., 2010. The anatomy of the Gottingen minipig hypothalamus. *J. Chem. Neuroanat.* 39, 151–165.

Felix, B., Leger, M.E., Albe-Fessard, D., Marcilloux, J.C., Rampin, O., Laplace, J.P., 1999. Stereotaxic atlas of the pig brain. *Brain Res. Bull.* 49, 1–137. <https://www.ncbi.nlm.nih.gov/pubmed/10466025>.

Glud, A.N., Bech, J., Tvilling, L., Zaer, H., Orłowski, D., Fitting, L.M., Ziedler, D., Geneser, M., Sangill, R., Alstrup, A.K.O., Bjarkam, C.R., Sorensen, J.C.H., 2017.

A fiducial skull marker for precise MRI-based stereotaxic surgery in large animal models. *J. Neurosci. Methods* 285, 45–48.

Kornum, B.R., Stott, S.R., Mattsson, B., Wisman, L., Ettrup, A., Hermening, S., Knudsen, G.M., Kirik, D., 2010. Adeno-associated viral vector serotypes 1 and 5 targeted to the neonatal rat and pig striatum induce widespread transgene expression in the forebrain. *Exp. Neurol.* 222, 70–85.

Larsen, M., Bjarkam, C.R., Ostergaard, K., West, M.J., Sorensen, J.C., 2004. The anatomy of the porcine subthalamic nucleus evaluated with immunohistochemistry and design-based stereology. *Anat. Embryol.* 208, 239–247.

Meidahl, A.C., Orłowski, D., Sorensen, J.C., Bjarkam, C.R., 2016. The retrograde connections and anatomical segregation of the Gottingen minipig nucleus accumbens. *Front. Neuroanat.* 10, 117.

Mikula, S., Stone, J.M., Jones, E.G., 2008. BrainMaps.org - interactive high-resolution digital brain atlases and virtual microscopy. *Brains Minds Media* 3, bmm1426. <https://www.ncbi.nlm.nih.gov/pubmed/19129928>.

Nielsen, M.S., Sorensen, J.C., Bjarkam, C.R., 2009. The substantia nigra pars compacta of the Gottingen minipig: an anatomical and stereological study. *Brain Struct. Funct.* 213, 481–488.

Orłowski, D., Michalis, A., Glud, A.N., Korshoj, A.R., Fitting, L.M., Mikkelsen, T.W., Mercanzini, A., Jordan, A., Dransart, A., Sorensen, J.C.H., 2017. Brain tissue reaction to deep brain stimulation-A longitudinal study of DBS in the Goettingen minipig. *Neuromodulation: J. Int. Neuromodulation Soc.* 20, 417–423.

Paxinos, G., Watson, C., 2007. *The Rat Brain in Stereotaxic Coordinates*, sixth ed. Academic Press/Elsevier, Amsterdam; Boston. Publisher description. <http://www.loc.gov/catdir/enhancements/fy0745/2006937142-d.html>.

Saikali, S., Meurice, P., Sauleau, P., Eliat, P.A., Bellaud, P., Randuineau, G., Verin, M., Malbert, C.H., 2010. A three-dimensional digital segmented and deformable brain atlas of the domestic pig. *J. Neurosci. Methods* 192, 102–109.

Sorensen, J.C., Nielsen, M.S., Rosendal, F., Deding, D., Ettrup, K.S., Jensen, K.N., Jorgensen, R.L., Glud, A.N., Meier, K., Fitting, L.M., Moller, A., Alstrup, A.K., Ostergaard, L., Bjarkam, C.R., 2011. Development of neuromodulation treatments in a large animal model—do neurosurgeons dream of electric pigs? *Prog. Brain Res.* 194, 97–103.

Villadsen, J., Hansen, H.D., Jorgensen, L.M., Keller, S.H., Andersen, F.L., Petersen, I.N., Knudsen, G.M., Svarer, C., 2018. Automatic delineation of brain regions on MRI and PET images from the pig. *J. Neurosci. Methods* 294, 51–58.

Watanabe, H., Andersen, F., Simonsen, C.Z., Evans, S.M., Gjedde, A., Cumming, P., DaNe, X.S.G., 2001. MR-based statistical atlas of the Gottingen minipig brain. *Neuroimage* 14, 1089–1096.