

Transthoracic Needle Biopsy (TNB) under Different Guiding Methods - the Experience of the Thoracic Surgery Clinic of Craiova after the First 235 Cases

A. DEMETRIAN¹, A. DOBRINESCU¹, SERENADA BĂLĂ²,
CAMELIA DEMETRIAN³, IOANA ANDREEA GHEONEA⁴,
DANA MARIA ALBULESCU⁴

¹Thoracic Surgery Clinic – University of Medicine and Pharmacy of Craiova, Romania

²Pathology Department, University of Medicine and Pharmacy of Craiova, Romania

³Pneumology Clinic, University of Medicine and Pharmacy of Craiova, Romania

⁴Radiology and Imaging Department, University of Medicine and Pharmacy of Craiova, Romania

ABSTRACT: Transthoracic needle biopsy (TNB) is a fast and safe method used to establish definitive diagnosis for most thoracic lesions, whether the lesion is located in the pleura, the lung parenchyma, or the mediastinum. Diffuse disease and solitary lesions are equally approachable. TNB can avoid (when technically possible) more complex diagnostic interventions such as mediastinoscopy, thoracoscopy and exploratory thoracotomy. This article focuses on the advantages of TNB which is a safe, affordable and quick method to obtain histopathological confirmation of intrathoracic tumors. **Material and Methods** The study included a total of 235 cases over a period of 4 and a half years (01.01.2011-30.04.2015). We investigated the demographic and clinical parameters, the guiding methods, the histological results and the complications of the procedure. **Results** The median age of the patients was 62 years and the predominant sex was male. We could obtain a tissue biopsy in 99% with a histopathological confirmation of 88%. The most frequently used guiding method was the previous CT scan of the patient and the anatomical landmarks (53%). The main histopathological result was squamous cell carcinoma. **Conclusions** TNB is generally a safe procedure with limited morbidity and extremely rare mortality. It is an affordable and quick method to obtain histopathological confirmation of intrathoracic tumors. Most TNBs can be performed by using local anesthesia without conscious sedation and virtually any location in the chest can be safely addressed.

KEYWORDS: transthoracic needle biopsy, biopsy guns, histopathological diagnosis, thoracic tumors

Introduction

Transthoracic needle biopsy has emerged over the past 30 years as the invasive procedure of choice for diagnosing intrathoracic lesions [1]. The technique has proved extremely accurate in the diagnosis of these lesions. With the advent of cross-sectional imaging using CT and sonography, the applications of TNB have expanded to the diagnosis of mediastinal, hilar, chest wall, and pleural lesions. Diffuse disease and solitary lesions are equally approachable. TNB can avoid (when technically possible) more complex diagnostic interventions such as mediastinoscopy, thoracoscopy and exploratory thoracotomy. This article focuses on the advantages of TNB which is a safe, affordable and quick method to obtain histopathological confirmation of intrathoracic tumors. The instruments used are biopsy guns or needles of varying gauge, lengths, tip configurations, and firing mechanisms. The needle selection depends upon lesion characteristics, type/amount of tissue required, and operator preference.

Material and Methods

The study included a total of 235 consecutive cases of intrathoracic tumors over a period of 4 and a half years (01.01.2011-30.04.2015) in whom a transthoracic needle biopsy was performed in order to obtain a histopathological result.

The guiding method for precise location of the tumor included fluoroscopy (for the first patients of the study), ultrasound, CT scan but mostly a previous CT scan of the patient and the use of anatomical landmarks (what we call a „CT oriented biopsy”).

The CT oriented biopsy method was used for the bigger tumors in the proximity of the pleura. In order to certify the intratumoral location, after the local anesthesia aspiration was performed with the same needle. If no air or blood was aspirated into the syringe the intratumoral location was considered to be confirmed and the biopsy was performed following the same trajectory.

The instruments used were biopsy guns or needles of varying gauge (14 to 20), lengths (20 to 30 mm), tip configurations, and sampling

mechanisms (manual or automatic). The needle selection depended upon lesion characteristics and proximity, operator preference and disponibility of the devices.

Written informed consent was obtained, including consent for possible chest-tube placement. The patient was informed and educated about the procedure, its benefits, and its risks. A special warning was the powerful sound of the automatic needle, in order to avoid the sudden movement of the patient.

The next step of the biopsy procedure consists in choosing the trajectory of the needle which was established by choosing the shortest straight pathway from the skin to the lesion avoiding the vessels (intercostal, subclavian, internal mammary, vena cava and aorta).

The skin site is prepped and draped using a sterile technique. Palpation of underlying anatomical landmarks is very helpful. The procedure was performed under local anesthesia alone (10 ml of lidocain 1%) without sedation in all of the cases. For local anesthesia, a 27-gauge needle is used to inject the anesthetic into the skin and subcutaneous tissues, followed by deeper infiltration of the intercostal muscles.

The biopsy needle is inserted through the skin into the subcutaneous tissues. During needle insertion, one hand should hold the needle at skin level to stabilize and steer the needle. The other hand should hold the device and push gently downward to advance the needle.

After the needle is advanced to the level of the tumor the needle position and angle are verified with a short segment CT scan (only when the CT scan guidance is used). The firing of the biopsy needle is performed during a small period of apnea (3 to 5 seconds) that we request from the patient. 3 to 6 biopsy passages are made using the same trajectory, until we consider that the specimen is adequate for histopathological diagnosis.

After the biopsy, a short spiral CT is performed to evaluate for complications such as pneumothorax, hemothorax or intrapulmonary hematoma. If the scan is normal the patient may be discharged in the same day or the next day in few particular cases (dyspnea, microhemoptysis, local pain).

Usually we do not perform a routine chest X-ray after biopsy unless the clinical signs of complications are revealed.

Results

In the study group of 235 patients the median age was 62 years (ranging from 14 to 86 years) The sex ratio was 3/1 males/females, in accordance with the lung cancer male predominance.

We could obtain a tissue sample in 99% of the cases (in 2 patients the rapid onset of a small pneumothorax after local anesthesia made impossible the biopsy). For the rest of 233 patients, a histopathological confirmation was possible in 82%.

The tumor location was mainly in the lungs, also few other locations were addressed (Fig 1).

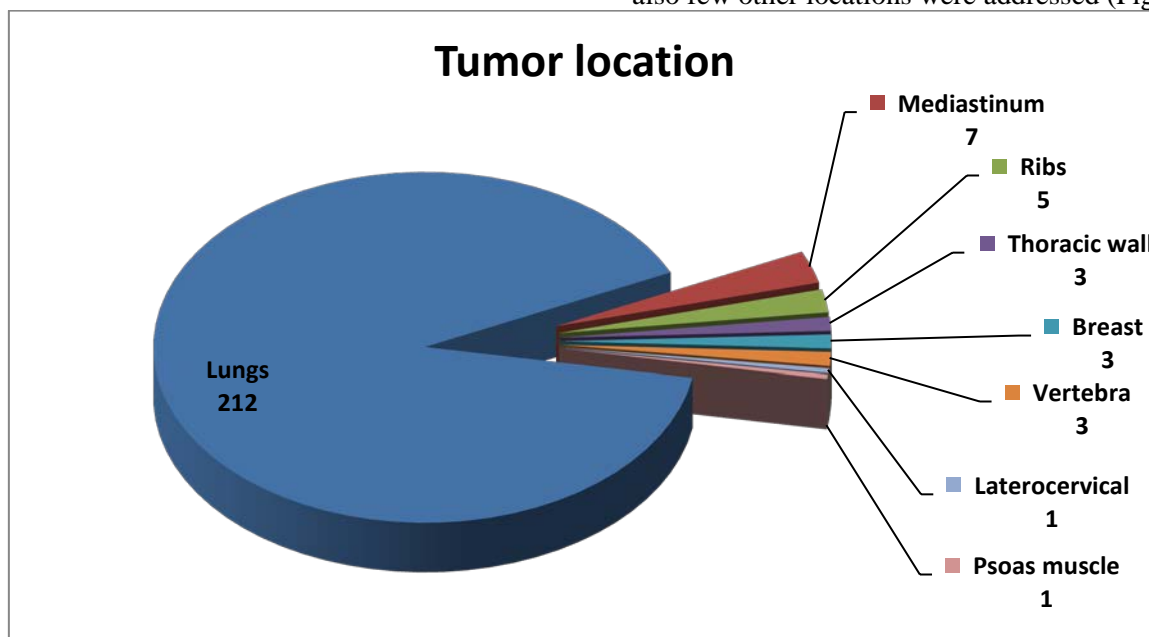


Fig.1 Tumor location

For the most of the cases (125 – 53%), the guiding method was „CT oriented” as we described it above, due to the big size of the tumor and the proximity to the thoracic wall. The other methods included the CT, ultrasound and fluoroscopy (Fig. 2). The fluoroscopy was the first method that we used for the only reason of high availability but we had to abandon due to

the risk of radiation for the patient and the operator and the imperfect location of the tumor. The ultrasound guidance was also used in few cases but the imperfect location of the profound lesions was the reason to abandon it also. Currently we are using only the CT oriented and the CT guided methods.

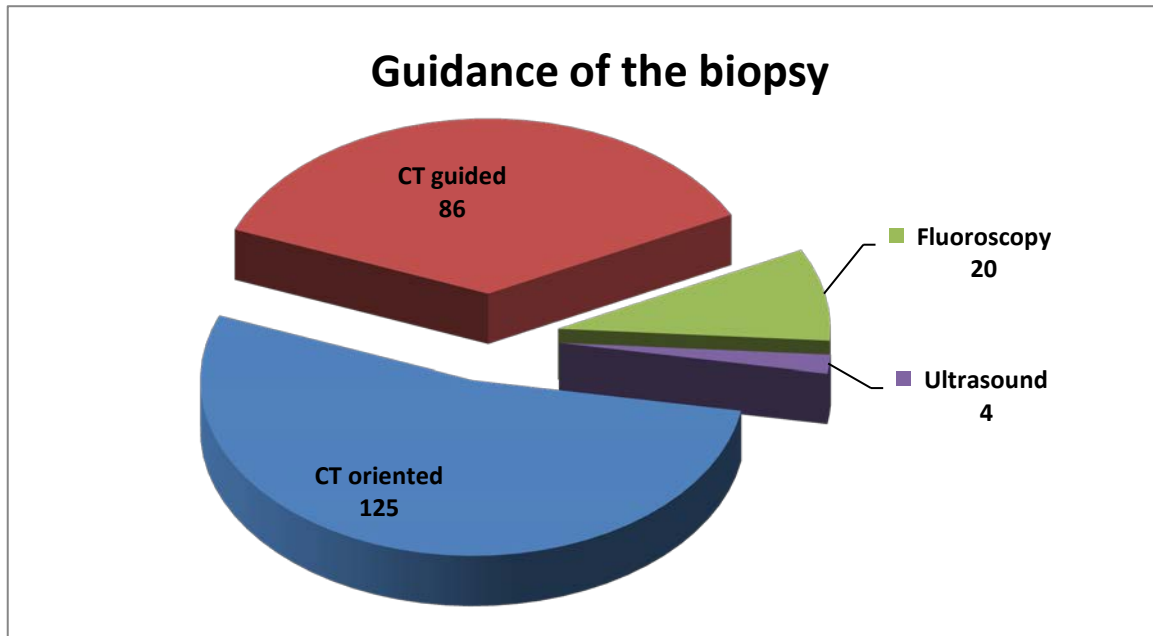


Fig. 2 Guidance method of the biopsy

The histopathological examination revealed mostly squamous cell carcinoma (72 cases) and adenocarcinoma (52 cases) or malignant tumor with no other specification (41 cases) and other

histopathological findings to a lesser extent (Fig.3). A molecular study of those tumors is in progress.

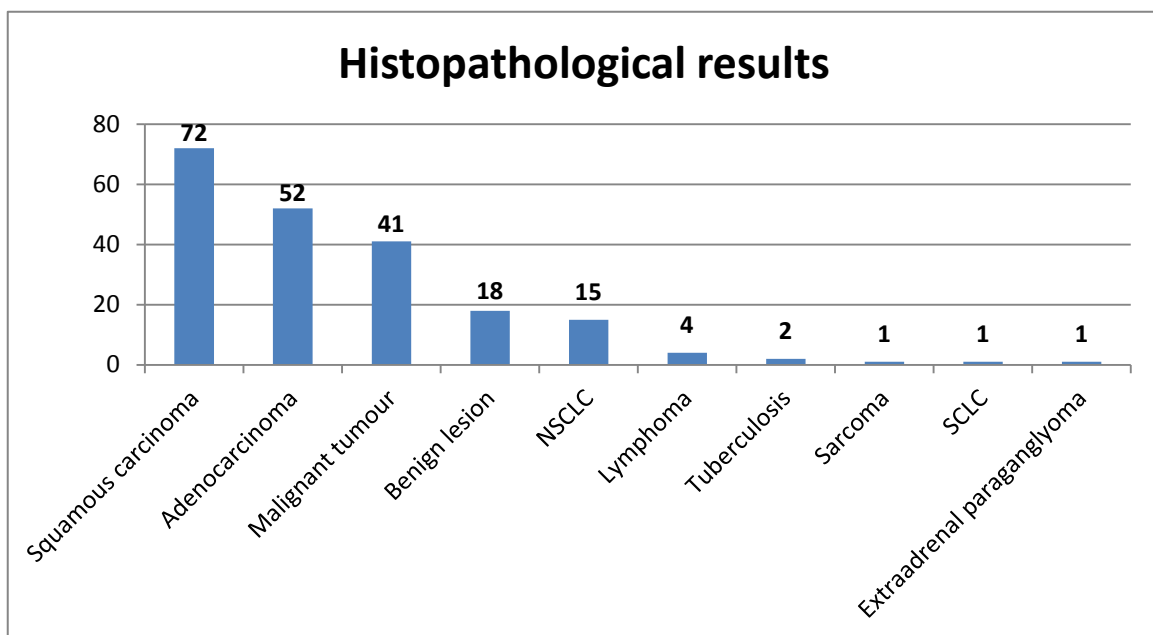


Fig. 3 Histopathological results

We compared the average age of patients with different tumor types using the ANOVA test, and we found that there are highly significant statistical differences between them (p=0.001). Continuing the analysis with post-hoc tests, we established that patients with squamous

carcinoma and adenocarcinoma tend to be older than patients with various other pathologies, and that patients with adenocarcinoma also have the average age greater than patients with malignant tumors with no other specification (Fig.4, Table 1).

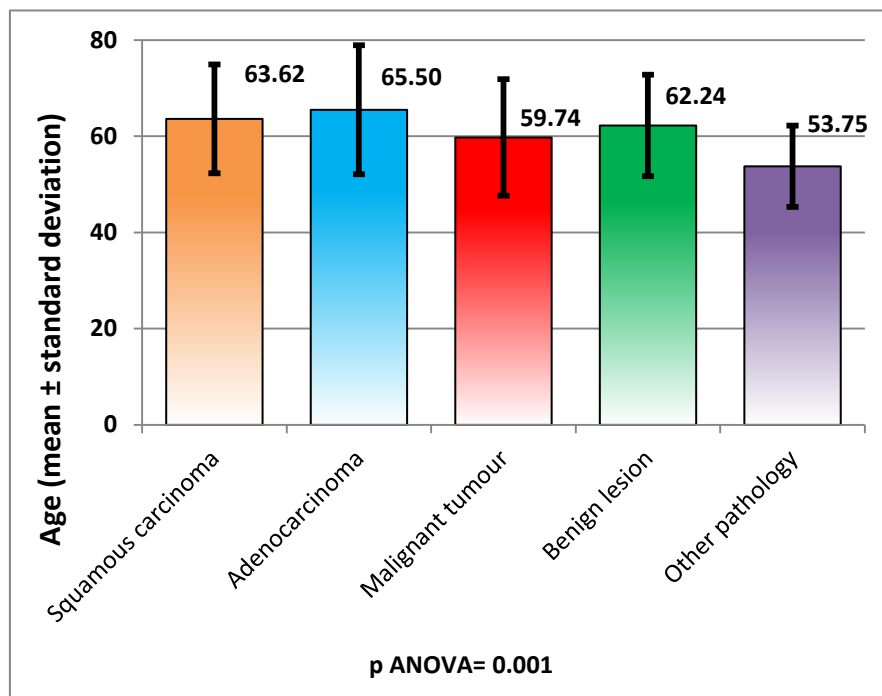


Fig.4. Comparison of the average age for different tumor types

Table 1. Average age of patients with different tumor types

Tumor type	No. of cases	Mean	St.dev.
Squamous carcinoma	72	63.616	11.326
Adenocarcinoma	52	65.5	13.429
Malignant tumor	41	59.744	12.135
Benign lesion	18	62.24	10.557
Other pathology	24	53.75	8.46

Table 2. Gender distribution of patients with different tumor types

Tumor type/Gender	Males	Females
Squamous carcinoma	55 (76.39%)	17 (23.61%)
Adenocarcinoma	40 (76.92%)	12 (23.08%)
Malignant tumor	29 (70.73%)	12 (29.27%)
Benign lesion	12 (66.67%)	6 (33.33%)
Other pathology	16 (66.67%)	8 (33.33%)

Comparing the gender distribution of the different tumor types, we encountered small differences, but, overall, they were not

statistically significant - the Chi square test result was p=0.775<0.05 (Fig.5, Table 2).

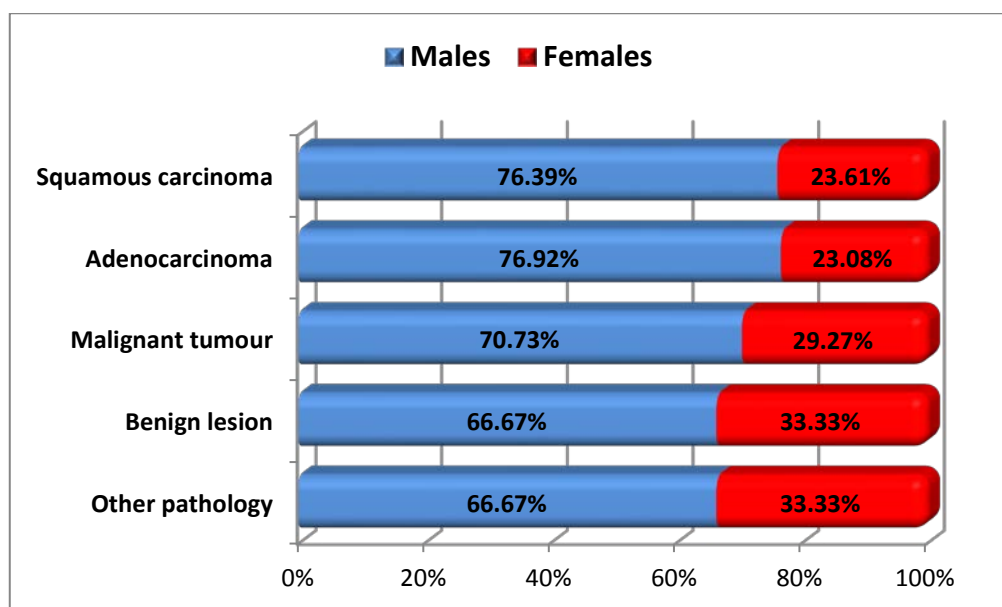


Fig.5. Gender distribution of patients with different tumor types

The most frequent complication that we encountered was the pneumothorax which was minor and was treated conservatively in 14 cases (6%) and significant, requiring chest tube

placement in 4 cases (2%). The other complications are detailed in the Table 1. The mortality of the procedure for the 235 patients was 0.

Table 3. Complications of the procedure

Complication	No of cases	%
Minor pneumothorax	14	6
Significant pneumothorax	4	2
Minor hemoptysis	10	4
Significant hemoptysis	1	0.5
Accidental puncture of the liver (under fluoroscopy guidance)	1	0.5

Analysing the frequency of complications for different guidance methods, we found percentual differences, without any statistical signification (p Chi square=0.773>0.05), mainly because for

two of the four methods used (fluoroscopy and ultrasound), we had a very small number of investigated patients (Fig.6, Table 4).

Table 4. Frequency of complications depending on guidance method

Guidance	Total	Complications	Complications (%)
CT oriented	125	17	13.60%
CT guided	86	9	10.47%
Fluoroscopy	20	3	15.00%
Ultrasound	4	1	25.00%
Total	235	30	12.77%

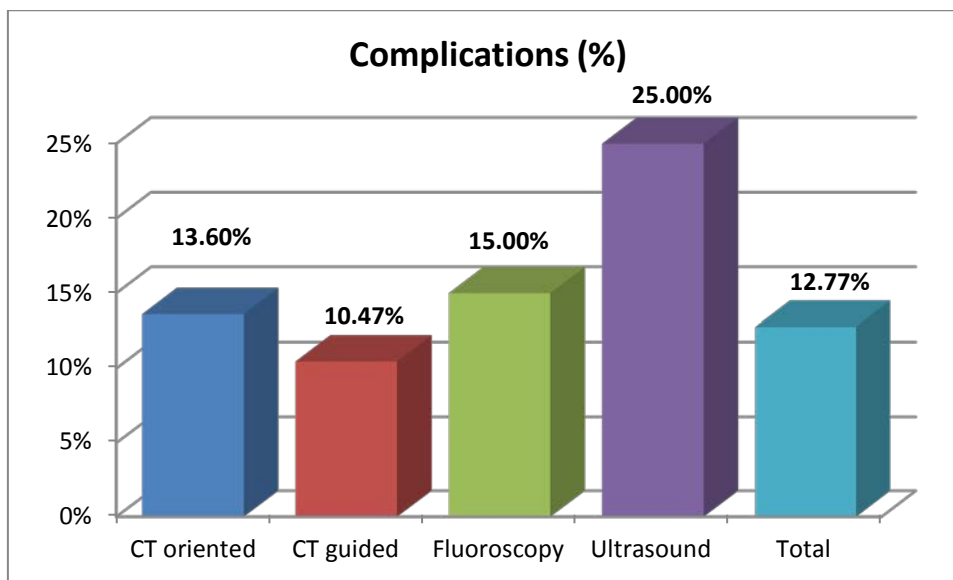


Fig.6. Frequency of complications depending on guidance method

Discussion

TNB is a safe minimal invasive procedure leading to histopathological confirmation of intrathoracic tumors, especially valuable in the diagnosis of small pulmonary nodules [2].

Haaga and Alfid reported the first case of CT-PTNB in 1976 [3] and, since then, CT guided TNB became the procedure of choice for histopathological confirmation of the intrapulmonary lesions. This procedure has several advantages: high true-positive rate [4], minimal invasiveness, low cost and general availability.

Sihoe et al. [5] concluded after a study on 443 consecutive adult patients with a lung mass confirmed or suspected to be an early stage primary lung cancer that proceeding to surgery without preoperative diagnosis in selected patients with a suspicious lung mass is safe and can potentially reduce the interval between presentation and surgical management. However, it is important to exclude a benign lesion in order to avoid unnecessary surgery [6].

Yeow et al. found that in CT-guided coaxial cutting needle biopsy, lesion depth is the single predictor for risk of pneumothorax [7]. We had the same results, with no pneumothorax complication encountered in tumors close to the thoracic wall.

Most TNBs are performed on an outpatient basis by using local anesthesia with or without conscious sedation. Virtually any location in the chest can be safely accessed by means of TNB.

Until the interventional radiologists will become interested about TNB, in Romania the thoracic surgeons are performing this procedure.

Conclusion

TNB is generally a safe procedure with limited morbidity and extremely rare mortality. It is an affordable and quick method to obtain histopathological confirmation of intrathoracic tumors. Most TNBs can be performed by using local anesthesia without conscious sedation and virtually any location in the chest can be safely addressed.

Acknowledgments

This work received financial support through the Project "Program of Excellence in multidisciplinary doctoral and postdoctoral research in chronic diseases", contract no. POSDRU / 159 / 1.5 / S / 133377, co-financed project from the European Social Fund by Operational Sectoral Programme Human Resources Development 2007-2013.

References

1. Capalbo E, Peli M, Lovisatti M, Cosentino M, Mariani P, Berti E, Cariatì M. Trans-thoracic biopsy of lung lesions: FNAB or CNB? Our experience and review of the literature. *Radiol Med.* 2014 August; 119(8): 572–594.
2. Zhan P, Xie H, Xu C, Hao K, Hou Z, Song Y. Management strategy of solitary pulmonary nodules. *J Thorac Dis.* 2013;5(6):824–9.
3. Haaga JR, Alfid RJ. Precise biopsy localization by computer tomography. *Radiology.* 1976;118(3):603–7.

4. Nizzoli R, Tiseo M, Gelsomino F, Bartolotti M, Majori M, Ferrari L et al. Accuracy of fine needle aspiration cytology in the pathological typing of non-small cell lung cancer. *J Thorac Oncol* 2011;6:489–93.
5. Sihoe A, Hiranandani R, Wong H, and Yeung E. Operating on a suspicious lung mass without a preoperative tissue diagnosis: pros and cons. *Eur J Cardiothorac Surg* (2013) 44 (2): 231-237
6. Kiranantawat N, Srisala N, Sungsi J, Geater SL, Tanomkiat W. Transthoracic imaging-guided biopsy of lung lesions: evaluation of benign non-specific pathologic diagnoses. *J Med Assoc Thai*. 2015 May;98(5):501-7.
7. Yeow KM, See LC, Lui KW, Lin MC, Tsao TC, Ng KF, et al. Risk factors for pneumothorax and bleeding after CT-guided percutaneous coaxial cutting needle biopsy of lung lesions. *J Vasc Interv Radiol*. 2001;12(11):1305–12.

*Corresponding Author: Alin Demetrian, Thoracic Surgery Clinic,
University of Medicine and Pharmacy of Craiova, 2 Petru Rareș St, 200349, Craiova, Romania;
e-mail: alin_demetrian@yahoo.com*