



# A study of the diagnostic value of a modified transthoracic lung ultrasound scoring method in interstitial lung disease

Ying Zhang<sup>1,2#</sup>, Xihua Lian<sup>1#</sup>, Shunfa Huang<sup>3</sup>, Liya Li<sup>1</sup>, Yanping Zhao<sup>1</sup>, Hongwei Lai<sup>1</sup>, Guorong Lyu<sup>1,4</sup>

<sup>1</sup>Department of Ultrasound Medicine, the Second Affiliated Hospital of Fujian Medical University, Quanzhou, China; <sup>2</sup>Department of Ultrasound Medicine, Honghui Hospital, Xi'an Jiaotong University, Xi'an, China; <sup>3</sup>Department of Radiology, the Second Affiliated Hospital of Fujian Medical University, Quanzhou, China; <sup>4</sup>Collaborative Innovation Center for Maternal and Infant Health Service Application Technology of Education Ministry, Quanzhou Medical College, Quanzhou, China

**Contributions:** (I) Conception and design: Y Zhang, X Lian, G Lyu; (II) Administrative support: L Li; (III) Provision of study materials or patients: S Huang; (IV) Collection and assembly of data: Y Zhang, Y Zhao, H Lai; (V) Data analysis and interpretation: Y Zhang, X Lian; (VI) Manuscript writing: All authors; (VII) Final approval of manuscript: All authors.

#These authors contributed equally to this work and should be considered as co-first authors.

**Correspondence to:** Guorong Lyu. Quanzhou Medical College, 2 Anji Road, Luojiang District, Quanzhou, China. Email: lgr\_feus@sina.com.

**Background:** Interstitial lung disease (ILD) is a serious complication of connective tissue disease (CTD) with significant morbidity and mortality. Lung ultrasound (LUS) has been widely used in the diagnosis of a variety of lung diseases. However, there is no standard ultrasound scanning method or scoring method for connective tissue disease associated with interstitial lung disease (CTD-ILD); therefore, it is necessary to establish a set of standard evaluation methods.

**Methods:** A total of 60 consecutive patients with clinically confirmed CTD and suspected ILD were prospectively included in this study. LUS and high-resolution computed tomography (HRCT) were used to examine all patients. The time between HRCT and LUS examinations was less than 2 weeks. The ultrasonographic results were evaluated with the modified scoring method and the Buda scoring method. The imaging results were evaluated with the HRCT Warrick scoring method. The primary aim was to evaluate the diagnostic value of a modified ultrasound scoring method in CTD-ILD.

**Results:** The results of the Youden index for the diagnosis of CTD-ILD by the modified method, the Buda method, and the HRCT method were 0.845, 0.711, and 0.911, respectively, with areas under the receiver operating characteristic (ROC) curve (AUC) of 0.982 [95% confidence interval (CI): 0.945–1.000], 0.950 (95% CI: 0.851–0.990), and 0.985 (95% CI: 0.949–1.000), respectively. With a clinical diagnosis as the gold standard, the consistency of the modified method and the HRCT method for CTD-ILD was high (Kappa values =0.872 and 0.913, respectively). The values of the modified method and the Buda method consistently and significantly increased with the increasing severity of CTD-ILD. For the former, there were significant differences between the mild, moderate, and severe groups ( $P<0.05$ ). The ROC curve used to calculate the modified ultrasound score predicted the critical values of mild and severe pulmonary fibrotic lesions at 34 points (sensitivity, 100%; specificity, 92.9%; AUC =0.933; 95% CI: 0.807–1.000) and 64.5 points (sensitivity, 92.0%; specificity, 85.3%; AUC =0.972; 95% CI: 0.929–1.000).

**Conclusions:** The modified ultrasound method has a higher diagnostic value than the Buda method for CTD-ILD.

**Keywords:** Lung ultrasound; interstitial lung disease; connective tissue diseases; high resolution CT

Submitted Feb 16, 2022. Accepted for publication Dec 04, 2022. Published online Jan 14, 2023.

doi: 10.21037/qims-22-153

**View this article at:** <https://dx.doi.org/10.21037/qims-22-153>

## Introduction

Connective tissue disease (CTD) is a group of heterogeneous immune-mediated systemic diseases that can affect various organs and systems. Interstitial lung disease (ILD) is one of the pulmonary manifestations of CTD and can cause significant morbidity and mortality (1,2). Lung ultrasound (LUS) has been widely used to diagnose various lung diseases (3-7). The diagnostic value of LUS in CTD-ILD has been reported worldwide (8-11). However, there is no standard scanning method or scoring method, rendering it necessary to establish a set of standard evaluation methods.

Barskova *et al.* (12) showed that the B-line could appear in the early stage of the disease, and that it had a high sensitivity for the diagnosis of ILD and can be used as a screening tool for ILD. Wang *et al.* (13) found that the B-line score was valuable in diagnosing CTD-ILD and correlated well with the high-resolution computed tomography (HRCT) score. Autopsy studies have shown that up to 70% of rheumatoid arthritis (RA) patients have at least slight pleural changes, which are the signs of lung involvement, and 17% of RA patients without dyspnea have signs of ILD (14). Therefore, the evaluation of CTD-ILD should be based on the number of B-lines as well as a comprehensive evaluation of its possible ultrasonic signs. Buda *et al.* (15) developed a semiquantitative scoring method to comprehensively evaluate the LUS signs that may appear in ILD patients. However, their scoring method had the lowest score in the white lung, which was not consistent with the idea that the white lung was the most seriously affected. Moreover, the whole lung was only divided into 3 regions: upper, middle, and lower; the scanning scope was not sufficiently refined; and the grade score of the B-line and the pleural line was not adequately detailed. Therefore, existing reports have developed a modified LUS scoring method by referring to the Buda ultrasound scoring method (15) and the HRCT Warrick scoring method (16).

In our previous study (17,18), 28 intercostal spaces (ICS) scan of anterior chest wall, 72 ICS scan of anterior and posterior chest wall and modified 14 ICS scan of anterior and posterior chest wall, which are the most commonly used at home and abroad, were used to examine ILD patients, and the feasibility and diagnostic efficiency of each method were analyzed. Finally, it was found that 72 ICS scan had the best diagnostic performance. We combined this approach with the modified LUS scoring method. Then, we inspected patients with CTD-ILD, analyzed the diagnostic

values of the evaluation, and compared those values with the Buda ultrasound scoring method to find a new evaluation scheme for the ultrasonic diagnosis of CTD-ILD. We present the following article in accordance with the STARD reporting checklist (available at <https://qims.amegroups.com/article/view/10.21037/qims-22-153/rc>).

## Methods

### *Patient group*

A total of 60 patients with clinically confirmed CTD and suspected ILD in the Respiratory Department and Immunology Department of the Second Affiliated Hospital of Fujian Medical University from June 2019 to October 2020 were included in the present study. Among the participants, 20 had RA, 19 had systemic lupus erythematosus, 10 had Sjogren's syndrome, 6 had systemic sclerosis, and 5 had polymyositis. There were 18 males and 42 females, aged 27-89 years, with a quartile of 61.0 (range, 50.0-69.0) years (*Table 1*). The general inclusion and exclusion processes are shown in *Figure 1*. The diagnosis of CTD was based on respective international standards (19-25). The diagnosis of ILD followed the 2018 Clinical Guidelines for ILD issued by the American Thoracic Society/European Respiratory Society (ATS/ERS) (26). Patients were included if they had been diagnosed with CTD; had a cough, chest tightness, labored shortness of breath, and other symptoms; and had undergone an HRCT examination. Patients were excluded if they had other lung diseases, such as lung infection, lung tumor, and previous lung surgery; had heart failure, diastolic dysfunction, asthma, pulmonary edema, and other issues caused by interstitial fluid; were unable to cooperate with clinical examination, such as HRCT and ultrasound, had incomplete clinical data; or had poor image quality. All participants underwent HRCT and LUS examinations.

The examinations were performed by 2 sonographers and imaging physicians who had received 3 years of training and had 2 years of experience in pulmonary imaging diagnostic studies. Radiographers used HRCT Warrick scoring. Sonographers used Buda ultrasound scoring and modified ultrasound scoring in a double-blind setting. The study was conducted in accordance with the Declaration of Helsinki (as revised in 2013). The study was approved by the Ethics Committee of the Second Affiliated Hospital of Fujian Medical University (No. 2018-24), and informed

**Table 1** The clinical information of the recruited patients

Parameters	Value of number	LUS scores		
		0–34	34–64.5	>64.5
Gender <sup>#</sup>				
Female	42 (70.0)	19 (45.2)	5 (11.9)	18 (42.9)
Male	18 (30.0)	6 (33.3)	5 (27.8)	7 (38.9)
Age (years) <sup>#</sup>				
<30	3 (5.0)	2 (66.7)	1 (33.3)	0 (0.0)
30–49	12 (20.0)	6 (50.0)	3 (25.0)	3 (25.0)
50–70	38 (63.3)	16 (42.1)	3 (7.9)	19 (50.0)
>70	7 (11.7)	1 (14.3)	3 (42.9)	3 (42.9)
BMI <sup>†</sup> (kg/m <sup>2</sup> )				
Female	20.52±1.75	19.98±1.54	20.98±1.21	20.89±2.12
Male	21.09±1.82	20.65±1.93	19.82±0.58	22.37±1.61
Body temperature <sup>†</sup> (°C)	36.73±0.49	36.60±0.29	36.91±0.60	36.79±0.57
Respiratory rate* (bpm)	21.0 (19.0–26.0)	19.0 (17.0–20.0)	21.0 (20.0–23.0)	27.0 (24.0–28.0)
SaO <sub>2</sub> <sup>†</sup> (%)	96.62±1.15	97.00±0.91	96.20±1.32	96.40±1.22
Primary diagnosis <sup>#</sup>				
Rheumatoid arthritis	20 (33.3)	8 (40.0)	3 (15.0)	9 (45.0)
Systemic lupus erythematosus	19 (31.7)	9 (47.4)	2 (10.5)	8 (42.1)
Sjogren's syndrome	10 (16.7)	3 (30.0)	3 (30.0)	4 (40.0)
Systemic sclerosis	6 (10.0)	3 (50.0)	1 (16.7)	2 (33.3)
Polymyositis	5 (8.3)	2 (40.0)	1 (20.0)	2 (40.0)
Respiratory symptoms <sup>#</sup>				
Cough	58 (96.7)	23 (39.7)	10 (17.2)	25 (43.1)
Chest tightness	42 (70.0)	15 (35.7)	7 (16.7)	20 (47.6)
Labor shortness of breath	51 (85.0)	17 (33.3)	9 (17.6)	25 (49.0)

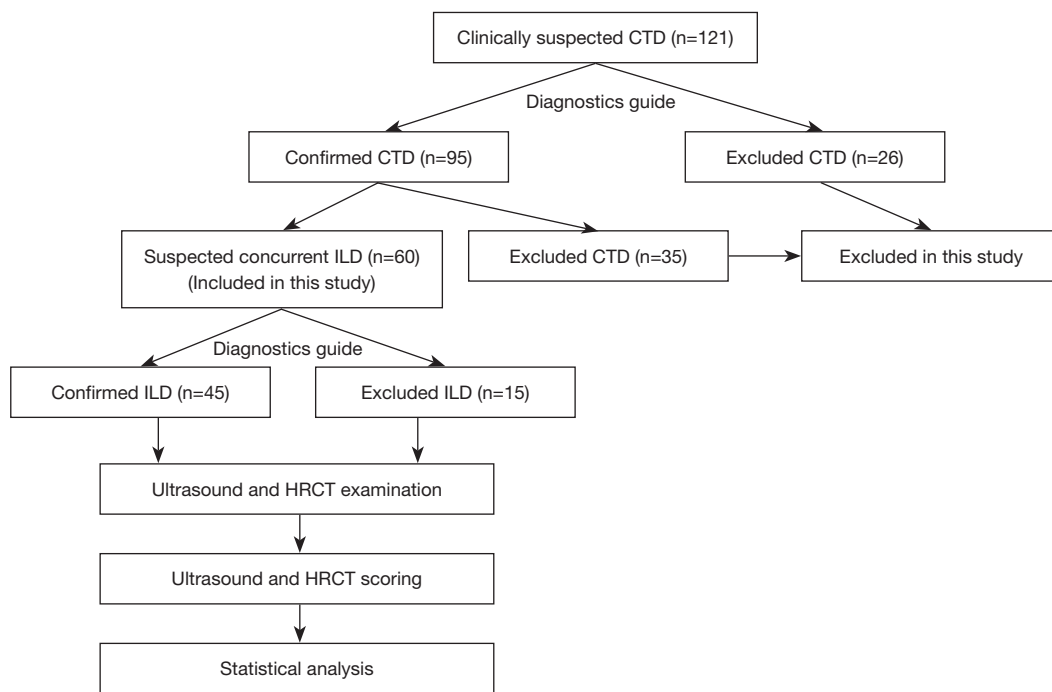
Data in this table are presented as mean ± standard deviation (†), median (interquartile range) (\*), and number (frequency) (#). LUS, lung ultrasound; BMI, body mass index; SaO<sub>2</sub>, oxygen saturation of blood.

consent was provided by all participants.

### LUS examination and scoring method

The tests were carried out using the Voluson E8 system (GE, Chicago, IL, USA) with the use of a linear probe (4.0–13.0 MHz) and a convex probe (1.0–7.0 MHz). The convex probe was used to observe the B-line and chest condition of the lungs. The linear probe was used to observe the pleural line. The anterior, lateral, and posterior chest wall

72 ICS scan method was used to carefully scan and evaluate each participant, including anterior, lateral, and posterior aspects of the chest wall (*Figure 2*) (27). The whole chest of the patient was scanned by positioning the probe sagittal to the chest wall in the ICS. The probe was moved from medial to lateral, from anterior to posterior along the anatomic reference line, including the bilateral parasternal line, midclavicular line, anterior axillary line, midaxillary line; bilateral spinal paravertebral line, scapula line, and posterior axillary line. Each chest wall point was observed



**Figure 1** Flow chart of this study. CTD, connective tissue disease; ILD, interstitial lung disease; HRCT, high-resolution computed tomography.

3 times. Patients were in a supine position to scan the anterior lung area and a sitting position to observe the posterior lung. We appropriately adjusted the grayscale imaging parameters to obtain the maximum contrast between all inspected structures.

Patients were evaluated using the modified ultrasound scoring method and the Buda ultrasound scoring method (Table 2) (15). Values for the Buda ultrasound scoring method were assigned as follows: the different signs of the lung were scored 1 for a white lung, 2 for an irregular pleural line, 3 for  $<3$  B-lines, 4 for  $\leq 4$  B-lines, 5 for a blurred pleural line, and 6 for Am-lines. The lungs were divided into 3 regions: involvement of 1 lung area was counted as 1 point, involvement of 2 lung areas was counted as 2 points, and involvement of 3 lung areas was counted as 3 points. Finally, the lung region scores and sign scores were added. Patients were considered to have mild pulmonary fibrosis when the score was 3–14 points, moderate fibrosis when the score was 15–20 points, and severe fibrosis when the score was 21–35 points.

The modified ultrasound scoring method, which divided the entire chest wall into 16 regions (Figure 2), was developed based on the HRCT Warrick scoring method (16) and the Buda ultrasound scoring method. This new



method divided all ultrasound signs that may appear in CTD-ILD into 2 types: the typical manifestation with the appearance of the B-line (Figure 3A) and pleural line changes (Figure 3A); and an ultrasound manifestation of possible complications, such as pleural effusion and the Am-line (Figure 3B). The lowest score was 1 point, and the highest was 240 points. Considering the positive diagnosis of the Buda scoring method (15) and another study (28), the positive diagnosis of the modified ultrasound scoring method (no less than 4 points) was defined if there was a positive B-line sign and a positive pleural line sign in 2 sections respectively, with or without any complications.

#### **HRCT examination and scoring method**

Chest CT was carried out for all patients in this study in accordance with the standard protocol with a Siemens dual-source CT scanner (Somatom Definition; Siemens, Erlangen, Germany). The patients lay on the examination bed with their hands raised above their head, and the scan was performed from the base of the lungs to the apex of the lungs at a scanning interval of 1 mm and a layer thickness of 1 mm. The lung imaging findings of all patients were recorded. The Warrick scoring criteria were used to score

Right	Midaxillary line	Anterior axillary line	Clavicle midline	Midclavicular line	Intercostal space	Parasternal line	Midclavicular line	Anterior axillary line	Midaxillary line	Left
	1	1	2	2	II	5	5	6	6	
	1	1	2	2	III	5	5	6	6	
	3	3	4	4	IV	7	7	8	8	
	3	3	4	4	V					

Left	Posterior axillary line	Scapular line	Paravertebral line	Intercostal space	Paravertebral line	Scapular line	Posterior axillary line	Right
	9		11	I	13		15	
	9		11	II	13		15	
	9		11	III	13		15	
	9		11	IV	13		15	
	10		12	V	14		16	
	10	12	12	VI	14	14	16	
	10	12	12	VII	14	14	16	
	10	12	12	VIII	14	14	16	
				IX				

**Figure 2** A 72 ICS scan of bilateral anterior, lateral, and posterior chest wall, in which we divided the entire chest into 16 zones as shown. ICS, intercostal space.

the HRCT scores of patients (16). The severity and lesion range scores were assigned as follows: 1 point for a ground glass shadow, 2 points for an irregular pleural margin, 3 points for a thickened lobular septum or subpleural line signs, 4 points for a honeycomb shadow, and 5 points for a subpleural cyst(s). In addition, 1 point was assigned for the involvement of 1–3 lung segments, 2 points for 4–9 lung segments, and 3 points for >9 lung segments, up to 30 points. Finally, we used a semiquantified grading system to assign the Warrick score. A patient was considered normal if they were assigned 0 points, mild if they were assigned <8 points, moderate if they were assigned 8–15 points, and severe if they were assigned >15 points (16).

**Statistics analysis**

For statistical analysis, we used SPSS 22.0 (IBM Corp.,

Armonk, NY, USA). Data with a normal distribution were expressed as the mean ± standard deviation ( $\bar{x}\pm s$ ), data with a nonnormal distribution were expressed as the median (interquartile range), and categorical variables were expressed as a count and percentage. Differences in the test variables were compared using the chi-square test. The area under the ROC curve and 95% CI were used to calculate the diagnostic efficiency of CTD-ILD by the modified ultrasound scoring method, Buda ultrasound scoring method, and HRCT Warrick scoring method. The Kappa consistency test was used to evaluate the consistency of the 3 scoring methods in the diagnosis of CTD-ILD. Pearson correlation was used to analyze the correlation between the 3 scoring methods. The Mann-Whitney U test was used to compare differences in test variables between the different groups. The sensitivity, specificity, and optimal cutoff value of the modified ultrasound score method for predicting

**Table 2** Modified scoring system for CTD-ILD

Ultrasound signs	Scoring based on ultrasonic features in each section
<b>B-line</b>	
None	0
<4	1
4-6	2
>6 or B-lines fully integrated (white lung)	3
<b>Pleural line</b>	
Normal	0
Thickening ( $\geq 0.5$ mm)	1
Irregular	2
Discontinuous, fragmented	3
<b>Complications</b>	
<b>Am-line (pulmonary bulla)</b>	
None	0
Exist	4
<b>Pleural effusion</b>	
None	0
Exist	5

The score for each region was the sum of the three scores of the B-line, pleural line and complications, and the score for the entire lung was obtained by adding the scores of sixteen areas (as shown in *Figure 1*). CTD-ILD, connective tissue disease-associated with interstitial lung disease.

the severity of CTD-ILD were analyzed using ROC curve analysis. P values less than 0.05 were considered statistically significant.

## Results

### *Diagnostic efficacy of the 3 scoring methods for CTD-ILD*

Of the 60 patients, 45 were clinically confirmed to have CTD-ILD, of whom 44 were classified as positive by the modified ultrasound scoring method (no less than 4 points) and the HRCT scoring method, and 41 were classified as positive by the Buda ultrasound scoring method. The sensitivity, specificity, positive predictive value, negative predictive value, and Youden index of the 3 methods for the diagnosis of CTD-ILD are shown in *Table 3*. There

was no significant difference in specificity among the 3 methods ( $P > 0.05$ ), and there was statistical significance in sensitivity between the Buda ultrasound scoring method and the other 2 methods ( $P < 0.01$ ). The areas under the ROC curves (AUC) for the HRCT scoring method, the modified scoring method, and the Buda scoring method were 0.985 (95% CI: 0.949–1.000), 0.982 (95% CI: 0.945–1.000), and 0.950 (95% CI: 0.851–0.990), respectively (*Figure 4*).

### *Consistency of 3 scoring methods to diagnose CTD-ILD*

With a clinical diagnosis as the gold standard, the consistency of the modified ultrasound scoring method and the HRCT scoring method for CTD-ILD was high (Kappa values = 0.872 and 0.913, respectively). The consistency of the Buda ultrasound scoring method for CTD-ILD was general (Kappa value = 0.710).

### *Modified ultrasound score and Buda ultrasound score of CTD-ILD with different severities*

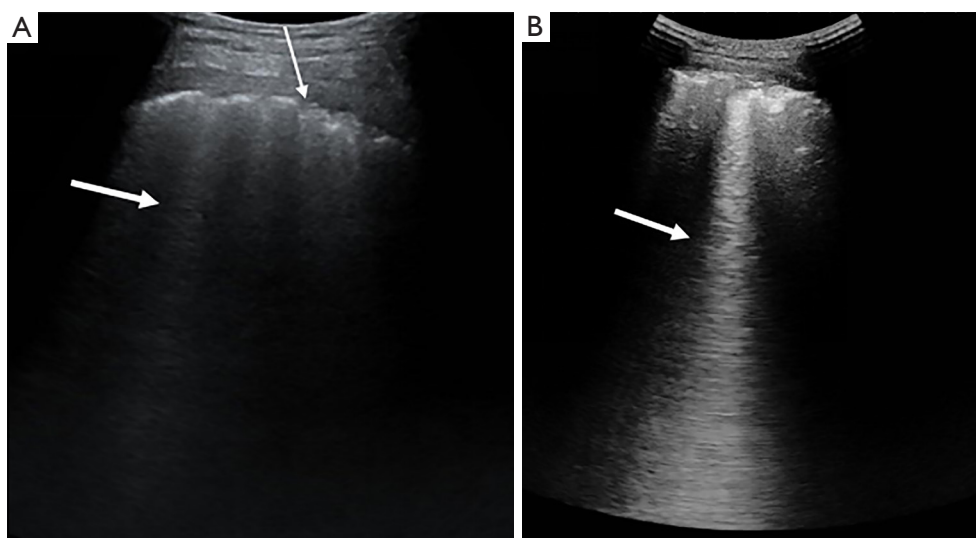
A comparison of the modified ultrasound score and the Buda ultrasound score between the mild, moderate, and severe groups is shown in *Table 4*. The mean values for the modified ultrasound score and the Buda ultrasound score consistently and significantly increased with the increasing severity of CTD-ILD. The severity was scored according to the HRCT score. Among them, 10 cases were mild, 10 cases were moderate, and 25 cases were severe.

### *The calculation of the cutoff value of the modified ultrasound score to predict different pulmonary fibrotic lesions*

The modified ultrasound score predicted the threshold value of mild (Warrick score  $< 8$  points) and severe (Warrick score  $> 15$  points) pulmonary fibrotic lesions, respectively, at 34 points (sensitivity, 100%; specificity, 92.9%; AUC = 0.933; 95% CI: 0.807–1.000) and 64.5 points (sensitivity, 92.0%; specificity, 85.3%; AUC = 0.972; 95% CI: 0.929–1.000; *Figure 5*).

## Discussion

Assessing pulmonary interstitial fibrosis is an important aspect of autoimmune diseases. An accurate assessment of the condition and prognosis of the patient can help with the clinical adjustment of the treatment plan.



**Figure 3** Lung ultrasonogram of CTD-ILD. (A) The thick arrow shows the B-line, and the thin arrow shows the fragmented pleural line. (B) The arrow indicates the Am-line. CTD-ILD, connective tissue disease-associated with interstitial lung disease.

**Table 3** Diagnostic efficacy of three scoring methods in CTD-ILD

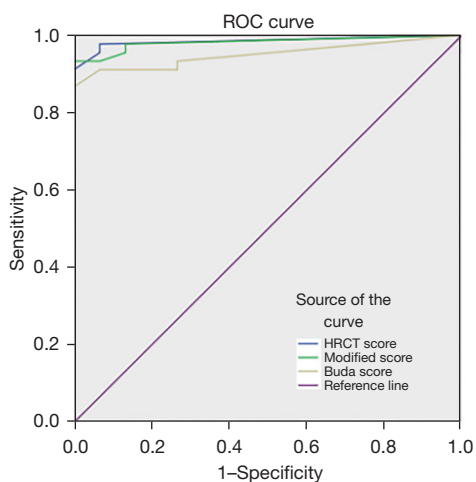
Diagnosis method	Sensitivity (%)	Specificity (%)	Positive predictive value	Negative predictive value	Youden index	AUC
Modified ultrasound scoring method	97.8 <sup>a</sup>	86.7	0.957	0.929	0.845	0.982 (95% CI: 0.945–1.000)
Buda ultrasound scoring method	91.1	80.0	0.932	0.750	0.711	0.950 (95% CI: 0.851–0.990)
HRCT scoring method	97.8 <sup>a</sup>	93.3	0.978	0.933	0.911	0.985 (95% CI: 0.949–1.000)

<sup>a</sup>,  $P < 0.01$  versus Buda scoring method.  $P > 0.05$  among other groups. CTD-ILD, connective tissue disease-associated with interstitial lung disease; AUC, areas under the receiver operating characteristic curve; CI, confidence interval; HRCT, high-resolution computed tomography.

In this study, we developed a modified LUS scoring method that included 3 types of ultrasound performance: typical B-line manifestations of the lungs, abnormal pleural lines, and complications. In contrast to a previous study, the white lung score was adjusted from 1 point to 3 points (15). This new ultrasonic method includes various ultrasonic signs with different degrees of severity, facilitating the accurate diagnosis ability. Evaluation of CTD-ILD should be based on a comprehensive evaluation of possible ultrasound signs. Therefore, the pleural line, pulmonary parenchyma, and complications were comprehensively observed. Furthermore, there were more details in the modified scoring method, such as the more grades of B-line and the addition of pleural thickness, more possible complications as the abnormal manifestations to diagnose

CTD-ILD.

The 72 ICS scanning method is a comprehensive LUS scanning scheme used to scan the whole lung of patients and observe all abnormal signs that may appear in CTD-ILD patients (27). In addition, during the scan, the 2 lungs were divided into 16 areas in the modified scoring system. Compared with the previous 12 divisions, the lateral chest wall was subdivided further. The anterior axillary line and the midaxillary line were combined. The posterior axillary line was disassembled. The first reason for this was that the scan of the ICS in the anterior and midaxillary lines differed from the scan of the ICS in the axillary lines. The second reason was that patients with severe ILD often had diffuse lesions in both lungs. Not having an average score for each division may cause a low score and underestimate the



**Figure 4** ROC curves of the 3 scoring methods to diagnose CTD-ILD. ROC, receiver operating characteristic; HRCT, high-resolution computed tomography; CTD-ILD, connective tissue disease-associated with interstitial lung disease.

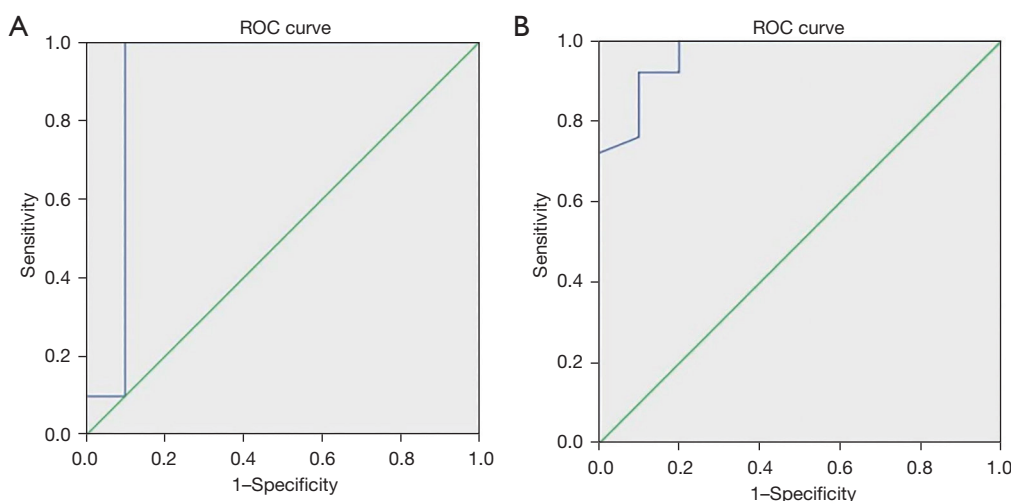
severity of severe patients. Each area was carefully observed, scored independently, and summed to obtain the total score.

The new and modified ultrasound scoring method is more detailed, and the ultrasound evaluation of ILD is more comprehensive. Therefore, LUS could be used for the preliminary diagnosis of CTD-ILD. This is beneficial for prompt diagnosis and effective treatment of CTD patients suspected to have ILD, especially those with ILD-related symptoms, such as dry cough, shortness of breath, and other lung symptoms. Comparing the modified ultrasound scoring method and the Buda ultrasound scoring method and their respective zoning range, in the examination of confirmed CTD patients, the modified ultrasound scoring method was found to be more often positive than the Buda ultrasound scoring method, consistent with HRCT diagnosis. This may be because the Buda ultrasound scoring method is based on lung fiber index scores as a positive diagnostic standard, and the lung fiber index score does

**Table 4** Comparison of modified ultrasound score and Buda ultrasound score of CTD-ILD with different severity

Groups	Modified ultrasound score*	Buda ultrasound score*
Mild group (n=10)	19.00 (14.50–28.50)	8.50 (0.00–12.50)
Moderate group (n=10)	49.00 (47.00–58.00) <sup>a</sup>	17.50 (15.50–23.00)
Severe group (n=25)	89.00 (71.00–96.00) <sup>a,b</sup>	27.00 (23.00–32.00) <sup>a,b</sup>

Data in this table are presented as median (interquartile range) (\*). <sup>a</sup>, P<0.05 versus mild group; <sup>b</sup>, P<0.05 versus moderate group. CTD-ILD, connective tissue disease-associated with interstitial lung disease.



**Figure 5** Cutoff results of modified ultrasound scores for predicting the severity of pulmonary fibrosis. (A) Mild. (B) Severe. ROC, receiver operating characteristic.



not include the white lung score. This score may lead to a misdiagnosis as negative in some patients with no obvious ultrasound signs or only a few white lung signs. However, we defined white lung as 3 points in each section.

Furthermore, Buda *et al.*'s (15) study found a new sign, called the Am-line. An Am-line artifact was defined as reverberation artifacts in the subpleural region, characterized by numerous horizontal lines. An Am-line usually arises from the pleural line (narrow) and reaches the edge of the screen (wide). An Am-line might result from the multiple reflections of ultrasound waves between 2 border surfaces, such as a pulmonary bulla or cavitation (28). The first border surface would be that of the pleural line and the second surface would be the wall of the emphysematous bulla or subpleural cyst. In this study, Am-lines were also found; they often appeared in patients with severe CTD-ILD, which may be the ultrasonic manifestation of subpleural pneumocysts caused by severe ILD. Therefore, we believe that the Am-line is also an important ultrasonic sign of ILD.

The diagnostic efficacy of the modified ultrasound scoring method, Buda ultrasound scoring method, and HRCT scoring method for CTD-ILD was calculated by ROC curve analysis. This assay indicated that the modified LUS scoring method was more accurate and reliable than the Buda ultrasound scoring method, but with values similar to those of HRCT. Then, the consistency of the 3 methods for the diagnosis of CTD-ILD was analyzed. The results suggested that the modified ultrasound scoring method and HRCT scoring method were highly consistent in the diagnosis of CTD-ILD and were better than the Buda ultrasound scoring method.

In the clinical diagnosis of ILD, there are no classification criteria for the severity of ILD. The international classification of the severity of ILD patients that is the most used is the HRCT Warrick scoring method (16). We used the HRCT scoring method to divide the patients with the diagnosis of CTD-ILD into mild, moderate, and severe, and the corresponding modified score and Buda score of different degrees of illness were compared. The results showed that the modified ultrasound score increased with the exacerbation of CTD-ILD, and the modified LUS score had the same value as the Buda ultrasound score in identifying mild/moderate and severe CTD-ILD. It is worth noting that the results of this study also suggest that the modified ultrasound scoring method is more advantageous than the Buda ultrasound scoring method in identifying mild and moderate CTD-ILD. Therefore, we believe that

the modified ultrasound scoring method is more valuable in evaluating the severity of CTD-ILD.

We used ROC curves to calculate the cutoff values of CTD-ILD with different severities as assessed using modified ultrasound scoring. It was found to be mild, below 34 points, and severe, below 64.5 points, with high sensitivity and specificity. This result shows that the modified ultrasound score can predict the severity of CTD-ILD well, and it has a certain value for the judgment of CTD-ILD patients and the follow-up of their prognosis. Thus, it seems that the modified ultrasound scoring method can allow a preliminary and effective diagnosis of CTD-ILD and be used to judge the severity of the disease and as an effective semiquantitative tool for diagnosing and treating CTD-ILD and its follow-up observation.

This study has some limitations. The evaluation of signs such as B-line number, pleural line shape, and the identification of false positive areas (such as pulmonary edema) mainly depended on the subjective judgment of the examiners, which inevitably led to errors. In addition, the sample size of this study was small, and the modified ultrasound scoring method and HRCT scoring method might vary with the different CTD. Consequently, the results of large-sample and multicenter studies are needed for further verification.

## Conclusions

Compared with the Buda ultrasound scoring method, our modified ultrasound scoring method is more comprehensive, more consistent with HRCT diagnosis, and can better distinguish the severity of CTD-ILD.

## Acknowledgments

*Funding:* This study was sponsored by the Youth Research Project of Health and Family Planning Commission of Fujian Province, China (No. 2018-1-62) and the Quanzhou Science and Technology Project (No. 2018N012).

## Footnote

*Reporting Checklist:* The authors have completed the STARD reporting checklist (available at <https://qims.amegroups.com/article/view/10.21037/qims-22-153/rc>).

*Conflicts of Interest:* All authors have completed the ICMJE uniform disclosure form (available at <https://qims>).

[amegroups.com/article/view/10.21037/qims-22-153/coif](https://amegroups.com/article/view/10.21037/qims-22-153/coif)).

The authors have no conflicts of interest to declare.

**Ethical Statement:** The authors are accountable for all aspects of the work in ensuring that questions related to the accuracy or integrity of any part of the work are appropriately investigated and resolved. The study was conducted in accordance with the Declaration of Helsinki (as revised in 2013). The study was approved by the Ethics Committee of the Second Affiliated Hospital of Fujian Medical University (No. 2018-24), and informed consent was provided by all participants.

**Open Access Statement:** This is an Open Access article distributed in accordance with the Creative Commons Attribution-NonCommercial-NoDerivs 4.0 International License (CC BY-NC-ND 4.0), which permits the non-commercial replication and distribution of the article with the strict proviso that no changes or edits are made and the original work is properly cited (including links to both the formal publication through the relevant DOI and the license). See: <https://creativecommons.org/licenses/by-nc-nd/4.0/>.

## References

- Cappelli S, Bellando Randone S, Camiciottoli G, De Paulis A, Guiducci S, Matucci-Cerinic M. Interstitial lung disease in systemic sclerosis: where do we stand? *Eur Respir Rev* 2015;24:411-9.
- Adler S, Huscher D, Siebert E, Allanore Y, Czirják L, DelGaldo F, Denton CP, Distler O, Frerix M, Matucci-Cerinic M, Mueller-Ladner U, Tärner IH, Valentini G, Walker UA, Villiger PM, Riemekasten G; . Systemic sclerosis associated interstitial lung disease - individualized immunosuppressive therapy and course of lung function: results of the EUSTAR group. *Arthritis Res Ther* 2018;20:17.
- Lyu GR. Lung ultrasound in the critically ill. Beijing: Peking University Medical Press, 2018.
- Zhu Z, Lian X, Zeng Y, Wu W, Xu Z, Chen Y, Li J, Su X, Zeng L, Lv G. Point-of-Care Ultrasound-A New Option for Early Quantitative Assessment of Pulmonary Edema. *Ultrasound Med Biol* 2020;46:1-10.
- Tan G, Lian X, Zhu Z, Wang Z, Huang F, Zhang Y, Zhao Y, He S, Wang X, Shen H, Lyu G. Use of Lung Ultrasound to Differentiate Coronavirus Disease 2019 (COVID-19) Pneumonia From Community-Acquired Pneumonia. *Ultrasound Med Biol* 2020;46:2651-8.
- Lyu G, Zhang Y, Wang Z. Modified Scoring Method for COVID-19 Pneumonia. *J Ultrasound Med* 2021;40:429-31.
- Huang S, Guo R, Yuan X, Tang X, Liu T, Xie Q, Qiu L. Evaluation of connective tissue disease-related interstitial lung disease using ultrasound elastography: a preliminary study. *Quant Imaging Med Surg* 2022;12:3778-91.
- Song G, Bae SC, Lee YH. Diagnostic accuracy of lung ultrasound for interstitial lung disease in patients with connective tissue diseases: a meta-analysis. *Clin Exp Rheumatol* 2016;34:11-6.
- Morrisroe K, Stevens W, Huq M, Sahhar J, Ngian GS, Zochling J, Roddy J, Proudman SM, Nikpour M; . Validity of the Workers Productivity and Activity Impairment Questionnaire: Specific Health Problem (WPAI:SHP) in patients with systemic sclerosis. *Clin Exp Rheumatol* 2017;35 Suppl 106:130-7.
- Vasco PG, de Luna Cardenal G, Garrido IM, Pinilla JM, Rodríguez GF, Mateo JJ, Ruiz DC. Assessment of interstitial lung disease in Sjögren's syndrome by lung ultrasound: a pilot study of correlation with high-resolution chest tomography. *Intern Emerg Med* 2017;12:327-31.
- Ji ZY, Liu YJ, Wang XM. A preliminary study for the correlation between lung ultrasound and HRCT of connective tissue disease associated interstitial lung disease. *Chinese J Ultrasound Med* 2019;35:7-11.
- Barskova T, Gargani L, Guiducci S, Randone SB, Bruni C, Carnesecchi G, Conforti ML, Porta F, Pignone A, Caramella D, Picano E, Cerinic MM. Lung ultrasound for the screening of interstitial lung disease in very early systemic sclerosis. *Ann Rheum Dis* 2013;72:390-5.
- Wang Y, Gargani L, Barskova T, Furst DE, Cerinic MM. Usefulness of lung ultrasound B-lines in connective tissue disease-associated interstitial lung disease: a literature review. *Arthritis Res Ther* 2017;19:206.
- Abdul-Ghani M, Dufort D, Stiles R, De Repentigny Y, Kothary R, Megeney LA. Wnt11 promotes cardiomyocyte development by caspase-mediated suppression of canonical Wnt signals. *Mol Cell Biol* 2011;31:163-78.
- Buda N, Piskunowicz M, Porzezi ska M, Kosiak W, Zdrojewski Z. Lung Ultrasonography in the Evaluation of Interstitial Lung Disease in Systemic Connective Tissue Diseases: Criteria and Severity of Pulmonary Fibrosis - Analysis of 52 Patients. *Ultraschall Med* 2016;37:379-85.
- Warrick JH, Bhalla M, Schabel SI, Silver RM. High resolution computed tomography in early scleroderma lung disease. *J Rheumatol* 1991;18:1520-8.
- Lian XH, Zhang Y, Zhu ZX, Lyu GR. Repeatability

- and consistency of three transthoracic lung ultrasound technologies in diagnosis of interstitial lung disease. *Chin J Med Imaging Technol* 2020;36:702-6.
18. Zhang Y, Lian XH, Lyu GR, Huang SF, Li LY, Zhao YP, Lain HW. Diagnostic value of refined transthoracic lung ultrasound scoring method in interstitial lung diseases. *Chin J Ultrasonogr* 2020;29:749-53.
  19. Petri M, Orbai AM, Alarcón GS, Gordon C, Merrill JT, Fortin PR, et al. Derivation and validation of the Systemic Lupus International Collaborating Clinics classification criteria for systemic lupus erythematosus. *Arthritis Rheum* 2012;64:2677-86.
  20. Shiboski CH, Shiboski SC, Seror R, Criswell LA, Labetoulle M, Lietman TM, Rasmussen A, Scofield H, Vitali C, Bowman SJ, Mariette X; . 2016 American College of Rheumatology/European League Against Rheumatism classification criteria for primary Sjögren's syndrome: A consensus and data-driven methodology involving three international patient cohorts. *Ann Rheum Dis* 2017;76:9-16.
  21. van den Hoogen F, Khanna D, Fransen J, Johnson SR, Baron M, Tyndall A, et al. 2013 classification criteria for systemic sclerosis: an American college of rheumatology/ European league against rheumatism collaborative initiative. *Ann Rheum Dis* 2013;72:1747-55.
  22. Aletaha D, Neogi T, Silman AJ, Funovits J, Felson DT, Bingham CO 3rd, et al. 2010 rheumatoid arthritis classification criteria: an American College of Rheumatology/European League Against Rheumatism collaborative initiative. *Ann Rheum Dis* 2010;69:1580-8.
  23. Sharp GC, Irvin WS, Tan EM, Gould RG, Holman HR. Mixed connective tissue disease--an apparently distinct rheumatic disease syndrome associated with a specific antibody to an extractable nuclear antigen (ENA). *Am J Med* 1972;52:148-59.
  24. Bohan A, Peter JB. Polymyositis and dermatomyositis (first of two parts). *N Engl J Med* 1975;292:344-7.
  25. Sontheimer RD. Would a new name hasten the acceptance of amyopathic dermatomyositis (dermatomyositis sine myositis) as a distinctive subset within the idiopathic inflammatory dermatomyopathies spectrum of clinical illness? *J Am Acad Dermatol* 2002;46:626-36.
  26. Raghu G, Remy-Jardin M, Myers JL, Richeldi L, Ryerson CJ, Lederer DJ, et al. Diagnosis of Idiopathic Pulmonary Fibrosis. An Official ATS/ERS/JRS/ALAT Clinical Practice Guideline. *Am J Respir Crit Care Med* 2018;198:e44-68.
  27. Pinal-Fernandez I, Pallisa-Nuñez E, Selva-O'Callaghan A, Castella-Fierro E, Simeon-Aznar CP, Fonollosa-Pla V, Vilardell-Tarres M. Pleural irregularity, a new ultrasound sign for the study of interstitial lung disease in systemic sclerosis and antisynthetase syndrome. *Clin Exp Rheumatol* 2015;33:S136-41.
  28. Fairchild R, Chung M, Yang D, Sharpless L, Li S, Chung L. Development and Assessment of Novel Lung Ultrasound Interpretation Criteria for the Detection of Interstitial Lung Disease in Systemic Sclerosis. *Arthritis Care Res (Hoboken)* 2021;73:1338-42.

**Cite this article as:** Zhang Y, Lian X, Huang S, Li L, Zhao Y, Lai H, Lyu G. A study of the diagnostic value of a modified transthoracic lung ultrasound scoring method in interstitial lung disease. *Quant Imaging Med Surg* 2023;13(2):946-956. doi: 10.21037/qims-22-153