

# EVALUATION OF PATIENTS WITH CARPAL TUNNEL SYNDROME TREATED BY ENDOSCOPIC TECHNIQUE

ALDO OKAMURA<sup>1</sup>, LIA MIYAMOTO MEIRELLES<sup>1</sup>, CARLOS HENRIQUE FERNANDES<sup>1</sup>, JORGE RADUAN NETO<sup>1</sup>,  
JOÃO BAPTISTA GOMES DOS SANTOS<sup>1</sup>, FLÁVIO FALOPPA<sup>1</sup>

## ABSTRACT

**Objective:** To evaluate the postoperative results of patients with carpal tunnel syndrome by the endoscopic release technique with single portal. **Methods:** 78 patients (80 wrists) were evaluated preoperatively and postoperatively at 1, 3 and 6 months by the Boston questionnaire, the visual analogue scale (VAS) for pain, monofilament test sensitivity, grip strength, lateral pinch, pulp to pulp pinch and tripod pinch. **Results:** Statistical analysis was significant ( $p < 0.05$ ) in the progressive decline of pain and improved function (Boston) during follow-up. The sensitivity

significantly improved comparing the data pre and postoperatively. The grip strength, lateral pinch, pulp to pulp pinch and tripod pinch decreased in the first month after surgery, returning to preoperative values around the third month postoperatively. **Conclusion:** The technique proved to be safe and effective in improving pain, function, and return sensitivity and strength.

## Level of Evidence II, Prospective study

**Keywords:** Carpal tunnel syndrome/surgery. Median nerve. Treatment outcome. Hand strength.

**Citation:** Okamura A, Meirelles LM, Fernandes CH, Raduan Neto J, Santos JBG, Faloppa F. Evaluation of patients with carpal tunnel syndrome treated by endoscopic technique. *Acta Ortop Bras.* [online]. 2014;22(1):29-33. Available from URL: <http://www.scielo.br/aob>.

## INTRODUCTION

The carpal tunnel syndrome (CTS) is the most common compressive neuropathy and any condition that increases the volume of structures or decrease the space inside the tunnel can cause symptoms. Inside the carpal tunnel there are nine flexor tendons of the finger and the median nerve. The tunnel's floor is formed by the concave arch of carpal bones covered by ligaments and the ceiling is formed by the transverse carpal ligament. Inside the tunnel the median nerve is located superficial to the superficial flexor tendon of the middle and ring fingers.<sup>1,2</sup> The diagnosis of CTS is clinical, based on history, physical examination and confirmed by electrophysiological studies. Other conditions such as cervical radiculopathy, brachial plexus injuries, thoracic outlet syndrome, pronator syndrome, cubital tunnel syndrome and peripheral neuropathies may present with similar clinical presentation in the hands should be excluded.<sup>3</sup> The treatment of this syndrome is initially conservative with infiltration of corticosteroid into the carpal tunnel, immobilization of the wrist with nocturnal orthosis, anti-inflammatories and oral corticosteroids.<sup>1</sup> Surgical treatment is indicated in patients who did not improve with conservative treatment, patients with thenar atrophy or electrophysiological evidence of denervation. Even in severe cases surgical release of the median nerve provides symptom relief and some functional recovery.<sup>4</sup>

There are several surgical options, including the classic open technique, with mini-incision, the endoscopic way, and the one through retinaculotome. Regardless of the surgical technique, the different anatomical variations in the region require care during carpal tunnel release.

The complications of surgery are well documented in the literature and can occur at any of the employed techniques.<sup>4,5</sup> In recent years there has been an increasing use of endoscopic methods for the release of the carpal tunnel in order to expedite the patient's return to work and reducing morbidity.<sup>6</sup> The disadvantages of this technique are the higher cost of surgery and the highest learning curve of the surgeon, compared to the open technique.<sup>6-8</sup>

The objective of this study is to evaluate the results of surgical treatment in 80 wrists of 78 patients with CTS operated with the single portal technique using the Razek Blade<sup>®</sup> system manufactured in Brazil. A post-operative follow-up of six months was conducted for evaluating pain, function, strength and sensitivity.

## MATERIALS AND METHODS

For the diagnosis of CTS, there were considered patients whose history and physical examination showed three or more diagnostic criteria, according to AAOS parameters. Namely: 1) Paresthesia in the median nerve territory, 2) Nocturnal paresthesia; 3) Thenar

All the authors declare that there is no potential conflict of interest referring to this article.

1. Universidade Federal de São Paulo (Unifesp), São Paulo, SP, Brazil.

Work performed at the Hand and Upper Limb Surgery Unit, Department of Orthopedics and Traumatology, Universidade Federal de São Paulo, Instituto de Cirurgia da Mão e Membro Superior da Universidade Federal de São Paulo, São Paulo, SP, Brazil.  
Correspondence: Rua Borges Lagoa, 786, Vila Clementino, São Paulo, SP, Brazil. 040036-032. [aldookamura@gmail.com](mailto:aldookamura@gmail.com)

atrophy, 4) Positive Tinel test; 5) Positive Phalen test; and 6) Decrease sensitivity.<sup>9</sup>

All patients had a CTS confirmed diagnosis by electromyography examination. Patients who failed the conservative treatment or thenar atrophy underwent surgery.

Eighty wrists of 78 patients undergoing carpal tunnel decompression between May 2009 and April 2012 were evaluated. Assessments were performed preoperatively, and at 1, 3, and 6 months postoperatively.<sup>1</sup> Assessment of included patients was performed through the Boston Questionnaire, the Visual Analog Pain Scale (VAS), sensitivity monofilament test, hand grip strength, lateral pinch, pulp to pulp pinch and tripod pinch. All evaluations were performed by a single hand therapy specialist physiotherapist.

The Boston Questionnaire translated and validated for the Portuguese language was completed by the patient without medical assistance. In case of illiterate patient, self-administered questionnaire was transformed into an interview.<sup>10</sup>

The visual analog pain scale (VAS) was used to quantify the pain reported by the patient, ranging from zero (no pain) to ten (maximum pain).

We performed the measurement of hand grip strength, lateral pinch, pulp to pulp pinch and tripod pinch. A hydraulic palmar grip dynamometer and a digital hydraulic grip dynamometer, both from Baseline® (Irvington, NY, USA) were used. To perform the measurements, subjects were seated with the adducted arm in parallel position to the trunk, elbow flexed at 90°, forearm and wrist in neutral position. (Figure 1) Three measurements were performed per test, with the highest strength possible, adopting the average of the values measured in kilogram-force.<sup>11</sup>

Sensitivity was investigated by the nylon monofilaments testing (Estesiômetro® manufactured by SMILES, Bauru, SP - Brazil). (Figure 2) The use of monofilament allowed to graduate sensitivity at various levels, from normal until deep loss of sensitivity, through intermediate levels. Thus, it was possible to quantify and monitor the evolution of neural function. The collection consists of a set of seven tubes where each one accurately indicates the axial force required to bend the filaments, which are of different colors, and match grade in grams. Green - 0.05 g; blue - 0.20g; violet - 2.00g; dark red - 4.00g; orange - 10.00g; magenta red - 300.00g. The test was performed without visual observation of the patient and demonstrated in an area of skin with normal sensitivity. The patient was asked to move the finger to feel the touch. The test started with the lightest monofilament (0.05g - green)



Figure 1. Measurement of palmar strength.




Figure 2. Esthesiometry of the index finger pulp.

followed by the next heavier monofilament (0.20g - blue) and so on. The green and blue filaments were applied up to three times at each site, being enough only one positive response to confirm sensitivity. The fingertips of all fingers were evaluated, but for statistical purposes we used the data of the index finger since it is an autogenous area of the median nerve.

The mean age was 54.8 years old, ranging from 33 to 81 years. Patients were predominantly female (95%), 52% had jobs, 34% were housewives, and 8% were retired. The most common affected hand was the dominant one in 52% of cases and the mean duration of symptoms was six years (0.5-20 years).

All patients were operated on by the same surgical technique for endoscopic carpal tunnel decompression using the single portal Razek Blade system. (Figure 3) The surgeries were performed with blocking the upper limb using a pneumatic tourniquet after exsanguination. A 3.0cm transverse incision in the crease of the distal wrist flexion between the radial flexor tendons and the ulnar carpal was made. After careful dissection and protection of cutaneous nerves, palpation of the hamate hamulus with a probe inside the carpal tunnel was made. Dilators were then sequentially introduced to feel them subcutaneously after the transverse carpal ligament (TCL). The procedure was followed by curettage of the entire synovial volar region of the TLC to allow a clear view of its transverse fibers. (Figure 4) The blade was introduced by palpating with the thumb of the opposite hand to the palmar region until its presence at the tunnel exit. The blade was driven to cut off only the distal fibers of the TLC after endoscopic visualization. We sectioned it in two stages, keeping intact the proximal ligament, to avoid

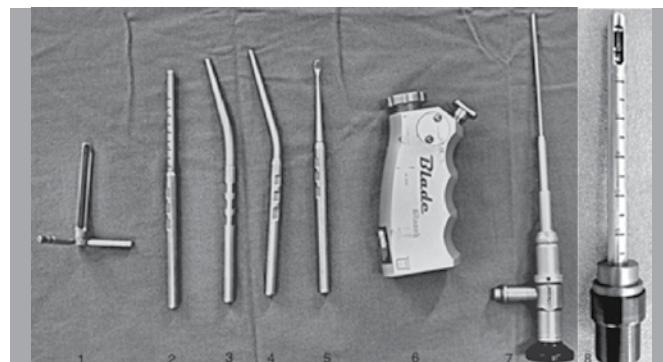


Figure 3. Instruments for endoscopic procedure 1) soft parts protector; 2) scale; 3,4) dialators; 5) curette; 6) hand's part; 7) optics; 8) blade.

the fall of fat tissue. (Figure 5) The cut of the distal ligament was inspected and completely transected, followed by the incision of the remainder. The blade was placed again in the tunnel to inspect the incised TLC. Optics was slightly rotated 20° to allow viewing of the sectioned edge of TLC. (Figure 6) Through the same incision, the antebrachial fascia was dissected and sectioned proximally. The surgery was completed by skin closure followed by dressing and bandaging. Patients were instructed to start active movement of the fingers as soon as the pain would allow.




Figure 4. Endoscopic view of terminal TLC.

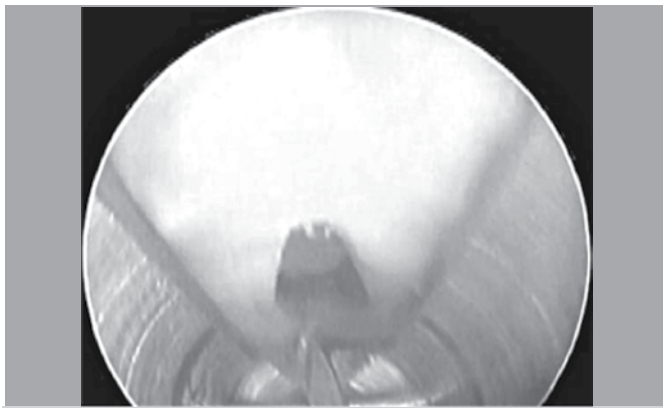


Figure 5. Endoscopic view of the distal section of the TLC fibers.

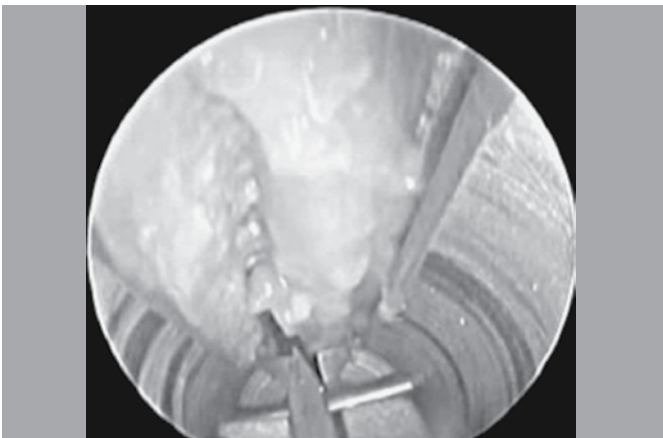

Figure 6. View of sectioned TLC (20 degrees optical rotation).

### Statistical analysis

To test for means equality a parametric variance analysis was performed, with contrasts made by Bonferroni method. When it was not possible to perform parametric variance analysis, a Friedman's non-parametric test for related samples was used to compare whether the mean of each variable was the same in four stages. All hypothesis tests were conducted using a significance level of 5%. Thus, the analysis of significance and scale Visual Analog Pain Scale (VAS), Boston questionnaire and sensitivity scale were made through analysis of variance (ANOVA), non-parametric multiple comparisons for paired data and the Friedman's test. The variables grip strength, lateral pinch, pulp-pulp pinch and tripod pinch were assessed by ANOVA and Bonferroni multiple comparisons.

### RESULTS

There was a statistically significance of the variable pain (VAS) when comparing the data of preoperative to 1, 3 and 6 months postoperative (Table 1) and also between the 1<sup>st</sup> and 6<sup>th</sup> months postoperatively. (Table 2) We observed a progressive reduction of pain intensity throughout the treatment, decreasing 7.4 points from preoperatively to 2.4 points at 6 months postoperatively. (Figure 7) At the individual analysis of patients, it was evident that all showed significant improvement in pain on the first postoperative evaluation. At the functional assessment (Boston questionnaire) there was also significance when comparing data from the preoperative to one, three and six months postoperative (Table 1) but also

Table 1. Result of ANOVA with repeated measurements.

Variable	Follow up	Mean	St. Dev.	Median	Minimum	Maximum	p
Pain Scale	Preop. -	7.43	2.61	8	0	10	<0.001*
	1 month	3.96	3.31	4	0	10	
	3 months	3.33	3.03	3	0	10	
	6 months	2.46	2.96	1	0	10	
Boston	Preop. -	65.99	13.57	66	33	96	<0.001*
	1 month	40.49	15.69	37.5	20	94	
	3 months	33.83	13.46	31	16	79	
	6 months	33.10	15.74	26	19	77	
Sensitivity scale	Preop. -	2.53	0.94	3	1	5	<0.001*
	1 month	1.81	0.89	2	1	4	
	3 months	1.70	0.88	1	1	4	
	6 months	1.49	0.75	1	1	4	

\*Result of Friedman's test

Table 2. Result of non-parametric multiple comparisons for paired data

Variable	Comparison	Difference	Max diff	T	p
Pain scale	Preop. - 1 month	98.0	23.09	8.359	<0.001
	Preop. - 3 months	121.5	23.09	10.363	<0.001
	Preop. - 6 months	144.5	23.09	12.325	<0.001
	1 month - 3 months	23.5	23.09	2.004	0.046
	1 month - 6 months	46.5	23.09	3.966	<0.001
	3 months - 6 months	23.0	23.09	1.962	0.051
Boston	Preop. - 1 month	110.0	19.75	10.973	<0.001
	Preop. - 3 months	167.5	19.75	16.708	<0.001
	Preop. - 6 months	184.5	19.75	18.404	<0.001
	1 month - 3 months	57.5	19.75	5.736	<0.001
	1 month - 6 months	74.5	19.75	7.432	<0.001
	3 months - 6 months	17.0	19.75	1.696	0.091
Sensitivity scale	Preop. - 1 month	64.0	20.17	6.255	<0.001
	Preop. - 3 months	76.5	20.17	7.477	<0.001
	Preop. - 6 months	99.5	20.17	9.725	<0.001
	1 month - 3 months	12.5	20.17	1.222	0.223
	1 month - 6 months	35.5	20.17	3.470	0.001
	3 months - 6 months	23.0	20.17	2.248	0.026

between the 1<sup>st</sup> and 3<sup>rd</sup> and 1<sup>st</sup> and 6<sup>th</sup> months post-surgery. (Table 2) The decline of 50% in the score, from 66 preoperatively to 33 at the 6<sup>th</sup> months postoperatively translates the improvement in symptoms and manual ability. (Figure 8)

Sensitivity of the index finger's pulp was statistically significant when comparing the data from the preoperative period to one, three and six months postoperative, (Table 1) also between the 1<sup>st</sup> and 6<sup>th</sup> months and between the 3<sup>rd</sup> and 6<sup>th</sup> months post-surgery. (Table 2)

When we analyze the variance for grip strength, lateral pinch, pulp to pulp pinch and tripod pinch there were no statistically significant differences in all variables, (Table 3) however, the Bonferroni test showed no significant difference between the preoperative and at six months postoperatively values, except for the tripod clamp. (Table 4)

There were no complications such as nerve injury, vascular injury of the palmar arch, infection, complex regional pain syndrome or need for reoperation.

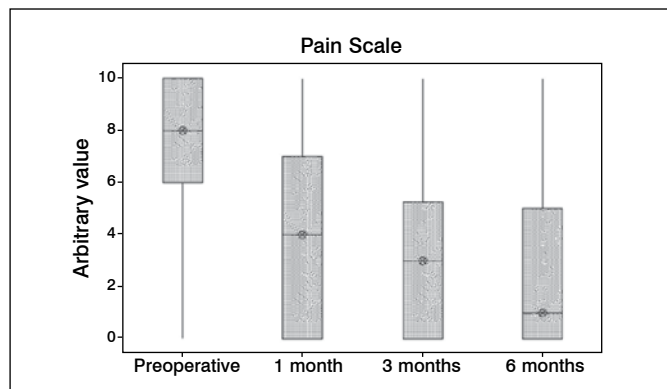
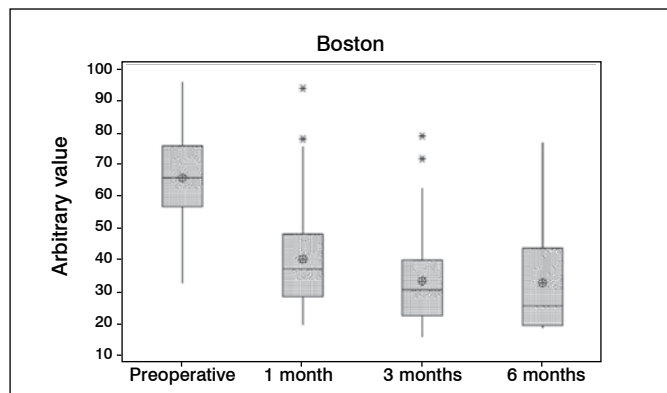


Figure 7. Visual analog pain scale (VAS).



\* Possible outliers.

Figure 8. Points in Boston questionnaire.

## DISCUSSION

The carpal tunnel syndrome is the most common compressive neuropathy with a prevalence of 51-125:100,000 persons.<sup>4</sup> It occurs mainly in women between the fourth and sixth decades of life.<sup>1</sup> We observed incidence in females of 95% and mean age of 54.8 year, consistent with the literature data.

CTS surgery is a procedure performed worldwide, often in an outpatient unit and usually indicated due to low rates of clinical

**Table 3.** Result of ANOVA with repeated measurements to variables grip strength, pulp to pulp pinch, lateral pinch and tripod pinch.

Variable	Follow up	Mean	St. Dev.	Median	Minimum	Maximum	p
Grip strength	Preop.-	13.54	6.54	14	1	30	<0.001
	1 month-	10.36	4.76	10	1	27.5	
	3 months-	13.04	4.97	12.8	2.5	26	
	6 months-	14.65	5.57	15.25	3.8	29.5	
Pulp to pulp pinch	Preop.-	2.45	1.06	2.5	0.5	5.5	<0.001
	1 month-	2.20	0.97	2	0.5	5	
	3 months-	2.60	1.19	2.5	0.5	6	
	6 months-	2.90	1.24	2.9	0.5	6.5	
Lateral pinch	Preop.-	4.39	1.88	4.5	0.5	8.5	<0.001
	1 month-	3.65	1.57	3.5	1	7.5	
	3 months-	4.29	1.69	4.1	1	8.5	
	6 months-	4.90	1.75	5	0.5	9.5	
Tripod pinch	Preop.-	3.09	1.37	3	0.5	6.5	<0.001
	1 month-	2.64	1.24	2.5	0.5	6	
	3 months-	3.12	1.38	3	1	7	
	6 months-	3.61	1.39	3.5	0.5	8	

**Table 4.** Result of Bonferroni's multiple comparisons for the variables grip strength, lateral pinch, pulp to pulp pinch and tripod pinch.

Variable	Comparison	Mean Difference	St. Deviation	p Inferior	IC (95%)	
					Superior	
Grip strength	Preop. - 1 month	3,18	0,61	<0,001	1,54	4,82
	Preop. - 3 months	0,50	0,69	>0,999	-1,37	2,37
	Preop. - 6 months	-1,11	0,68	0,647	-2,96	0,74
	1 month - 3 months	-2,68	0,47	<0,001	-3,95	-1,40
	1 month - 6 months	-4,29	0,58	<0,001	-5,85	-2,73
Pulp to pulp pinch	3 months - 6 months	-1,61	0,47	0,005	-2,87	-0,35
	Preop. - 1 month	0,26	0,11	0,161	-0,05	0,57
	Preop. - 3 months	-0,12	0,13	>0,999	-0,46	0,22
	Preop. - 6 months	-0,43	0,14	0,015	-0,80	-0,06
	1 month - 3 months	-0,38	0,11	0,005	-0,68	-0,09
Lateral pinch	1 month - 6 months	-0,69	0,12	<0,001	-1,01	-0,36
	3 months - 6 months	-0,30	0,12	0,061	-0,62	0,01
	Preop. - 1 month	0,73	0,19	0,002	0,20	1,26
	Preop. - 3 months	0,12	0,20	>0,999	-0,42	0,67
	Preop. - 6 months	-0,50	0,20	0,077	-1,04	0,03
Tripod pinch	1 month - 3 months	-0,61	0,14	<0,001	-0,99	-0,22
	1 month - 6 months	-1,24	0,17	<0,001	-1,69	-0,78
	3 months - 6 months	-0,63	0,13	<0,001	-0,97	-0,29
	Preop. - 1 month	0,45	0,13	0,005	0,10	0,81
	Preop. - 3 months	-0,01	0,13	>0,999	-0,36	0,33
Tripod pinch	Preop. - 6 months	-0,50	0,14	0,003	-0,88	-0,12
	1 month - 3 months	-0,46	0,11	0,001	-0,78	-0,15
	1 month - 6 months	-0,96	0,13	<0,001	-1,30	-0,61
	3 months - 6 months	-0,49	0,11	<0,001	-0,78	-0,20

improvement with conservative treatment.<sup>3-5</sup> Due to the great frequency with which this surgery is performed as there is interest in the possibility of new techniques in order to improve outcomes such as postoperative pain, pinch strength, function and return to work. Thus, the endoscopic technique was introduced, which although has higher costs due to instruments and increased surgical time in the operating room, this can be minimized since patients undergoing endoscopic release can return earlier to work.<sup>6,7,12</sup>

In our sample, more than half (52%) of the patients had jobs and 34% were exclusively housewives. The disease primarily affects women, and in our culture, especially in the lower social classes, housewives are responsible for a large number of heavy and repetitive household activities that are of great importance for the everyday family's life. Hence, it is of great economic and social importance the rapid postoperative recovery and early return to work.

Pain relief after release with open carpal tunnel technique is

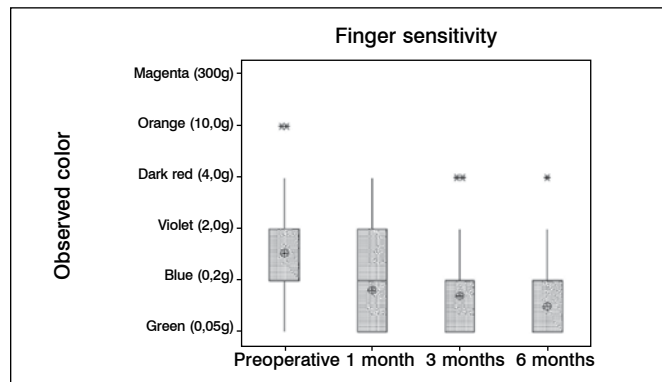
well documented in the literature.<sup>1,3,4,8</sup> Endoscopic carpal tunnel release according to Chow<sup>13</sup> has demonstrated a rapid recovery with little pain postoperatively all 109 patients evaluated, similar to results found in our study.

The Boston questionnaire has been validated in several countries and it is widely used for the evaluation of patients with CTS as it provides a standardization of subjective results.<sup>10,14,15</sup> This questionnaire has 19 questions that after being answered generates a score ranging from 18 to 90 points. The studies evaluating the questionnaire items independently show that the highest scores regarding the severity of the symptoms are related to pain (pain frequency and duration of pain episodes during the day), muscle weakness and regarding functional status they are related to strength (housework, open jar lid and carry grocery bags).<sup>10</sup> Regarding the open technique, literature show improvement in the scores between 25 and 79% after a minimum follow-up period of six months.<sup>14,15</sup> In our study we found a score improvement of 50 % using the endoscopic technique. The nylon monofilament test is widely used to assess sensitivity in patients with CTS.<sup>6,16-18</sup> Szabo *et al.*<sup>16</sup> demonstrated that out of 83% of patients who had preoperative changes, 65% have returned to normal sensitivity after six weeks with the open technique. In our study out of 87% of patients who had abnormal sensitivity preoperatively, 54% regained normal sensitivity after the first month and 62% after six months postoperatively. (Figure 9) Brown *et al.*,<sup>6</sup> comparing a group which underwent endoscopic release and another submitted to classical surgery, observed not statistically significant differences between them and between pre- and postoperative measurements.

The decrease in grip strength and thumb pinch the in patients with CTS is well reported in the literature.<sup>6,18-20</sup> Gellman *et al.*<sup>17</sup> demonstrated that recovery of strength after classical open surgery occurred between the 3<sup>rd</sup> and the 6<sup>th</sup> months post-surgery. In our study we observed the recovery of palmar strength and digital clamp around the 3<sup>rd</sup> month, exceeding values before surgery at the 6<sup>th</sup> month postoperatively for all strengths measured (Table 3), however, we found no statistically significant difference between data preoperatively and at the 6th months postoperatively, except for tripod pinch. (Table 4) Santos *et al.*<sup>18</sup>

## REFERENCES

- Mackinnon SE, Novak CB. Compression neuropathies. In: Green DP. Green's operative hand surgery. 6th ed. Philadelphia: Elsevier; 2010. p. 977-1015.
- Caetano EB. Bases anatômicas e funcionais das cirurgias do membro superior. Rio de Janeiro: Medbook; 2010. p. 303-14.
- Fernandes CH, Meirelles LM, Carneiro RS, Faloppa F, Albertoni WM. Tratamento cirúrgico da síndrome do canal do carpo por incisão palmar e utilização do instrumento de Paine®. Rev Bras Ortop. 1999;34(4):260-70.
- Alves MPT. Liberação do canal do carpo por mini-incisão transversa. Acta Ortop Bras. 2011;19(6):362-7.
- de Paula SEC, Santos LL, Meirelles LY, Santos JBG, Faloppa F, Albertoni WM, et al. Avaliação clínica a longo prazo – pelo sinal de Phalen, Tinel e parestesia noturna – dos pacientes submetidos a cirurgia de liberação do túnel do carpo com instrumento de Paine. Acta Ortop Bras. 2006;14(4):213-6.
- Brown RA, Gelberman RH, Seiler JGI, Abrahamsson SO, Weiland AJ, Urbaniack JR, et al. Carpal tunnel release: a prospective, randomized assesment of open and endoscopic methods. J Bone Joint Surg Am. 1993;75(9):1265-75.
- Trumble TE, Diao E, Abrams RA, Gilbert-Anderson MM. Single-portal endoscopic carpal tunnel release compared with open release: a prospective, randomized trial. J Bone Joint Surg Am. 2002;84(7):1107-15.
- Ferdinand RD, MacLean JGB. Endoscopic versus open carpal tunnel release in bilateral carpal tunnel syndrome. A prospective, randomized, blind assesment. J Bone Joint Surg Br. 2002;84(3):375-9.
- Kyle D, Bickel MD: Carpal Tunnel Syndrome. J Hand Surg Am. 2010;35(1):147-52.
- Meirelles LM, dos Santos JB, dos Santos LL, Branco MA, Faloppa F, Leite VM, et al. Avaliação do questionário de Boston aplicado nos pós-operatório tardio



\* Possible outliers.

Figure 9. Esthesiometry of the index finger pulp.

suggest that 15 to 20% of patients never achieve their original strength due to the change in configuration of the carpal bones, or to loss of the pulley effect of the retinaculum.

The safety of the endoscopic technique reflects the increasing complexity of the method versus the open technique. This emphasizes the need for adequate training programs.<sup>6</sup> In our study despite the surgeries have been performed solely by residents of the Hand Surgery unit assisted by mentors, there were no complications such as nerve injury, vascular injury of palmar arch, infection, reflex sympathetic dystrophy, nor need for reoperation. This demonstrates the safety of the method when applied with the correct technique.

A recent Cochrane's systematic review<sup>20</sup> comparing the open technique versus the endoscopic one found no significant difference between them, therefore, the decision of the technique to be used should be the physician's along with the patient. Limitations of the study were the convenience sample and the absence of a control group.

## CONCLUSION

Surgical treatment of patients with carpal tunnel syndrome operated with the single portal technique proved to be a safe and effective method in improving pain, function, and regain of sensitivity and strength.

da síndrome do túnel do carpo operados pela técnica de retinaculótomo de Paine por via palmar. Acta Ortop Bras. 2006;14(3):126-32.

- Young VL, Logan SE, Fernando B, Grasse P, Seaton M, Young AE. Grip strength before and after carpal tunnel decompression. South Med J. 1992;85(9):897-900.
- Agee JM, Peimer CA, Pyrek JD, Walsh WE. Endoscopic carpal tunnel release: a prospective study of complications and surgical experience. J Hand Surg Am. 1995;20(2):165-71.
- Chow JC. Endoscopic release of the carpal ligament for carpal tunnel syndrome: 22-month clinical result. Arthroscopy. 1990;6(4):288-96.
- Badger SA, O'Donnell ME, Sherigan JM, Conolly P, Spence RAJ. Carpal tunnel decompression: two different mini-incision technique. Ulster Med J. 2008;77(1):22-4.
- Uçar BY, Dermitas A, Bulut M, Azboy I, Uçar D. Carpal tunnel decompression: two different mini-incision technique. Eur Rev Med Pharmacol Sci. 2012;16(4):533-8.
- Szabo RM, Gelberman RH, Dimick MP. Sensibility testing in patients with carpal tunnel syndrome. J Bone Joint Surg Am. 1984;66(1):60-4.
- Gellman H, Kan D, Gee V, Kuschner SH, Botte MJ. Analysis of pinch and grip strength after carpal tunnel release. J Hand Surg Am. 1989;14(5):863-4.
- Santos LL, Branco MA, Meirelles LM, Santos JBG, Faloppa F, Albertoni WM, et al. Reavaliação a longo prazo do tratamento cirúrgico da síndrome do túnel do carpo por incisão palmar e utilização do instrumento de Paine®. Acta Ortop Bras. 2005;13(5):225-8.
- Phalen GS. Reflections on 21 years' experience with the carpal-tunnel syndrome. JAMA. 1970;212(8):1365-7.
- Scholten RJ, Mink van der Molen A, Uitdehaag BM, Bouter LM, de Vet HC. Surgical treatment options for carpal tunnel syndrome. Cochrane Database Syst Rev. 2007;(4):CD003905.