

[CASE REPORT]

Percutaneous Left Atrial Appendage Closure in a Patient with Diffuse Alveolar Hemorrhaging Associated with Anticoagulant Therapy and Atrial Fibrillation

Takaaki Ogoshi¹, Masato Fukunaga², Yu Suzuki¹, Yusuke Taura¹ and Kazuhiro Yatera³

Abstract:

Diffuse alveolar hemorrhaging (DAH) due to oral anticoagulation (OAC) is a life-threatening condition that leads to severe respiratory failure. There is a clinical dilemma in that OAC-induced DAH often forces the discontinuation of OAC therapy and the administration of high-dose corticosteroids, which increases the risk of stroke and cardiovascular events. We herein report the first case of OAC-induced DAH and atrial fibrillation (AF) in a patient who completely discontinued OAC therapy and high-dose corticosteroids after experiencing percutaneous left atrial appendage (LAA) occlusion. This case suggests that percutaneous LAA closure may aid in the management of OAC-induced DAH and AF.

Key words: diffuse alveolar hemorrhaging, respiratory failure, corticosteroid, atrial fibrillation, percutaneous left atrial appendage closure

(Intern Med 61: 2045-2050, 2022)

(DOI: 10.2169/internalmedicine.8551-21)

Introduction

Hemorrhaging into the alveolar spaces of the lungs characterizes the syndrome of diffuse alveolar hemorrhaging (DAH) and is due to disruption of the alveolar-capillary basement membrane, which is caused by injury or inflammation of the arterioles, venules, or alveolar septal capillaries (1-3). DAH can cause severe acute respiratory failure, and the reported prognosis of DAH is poor, with in-hospital mortality rates ranging from 20% to 70% (2, 4, 5).

Atrial fibrillation (AF) is the most common cardiac arrhythmia, and patients with AF should receive long-term oral anticoagulation (OAC), with medicines such as warfarin or direct oral anticoagulants to decrease the risk of AF-induced stroke. However, there is no anticoagulant therapy that reduces the thrombotic risk without simultaneously increasing the risk of bleeding including DAH. In this context, a common clinical dilemma occurs, in that OAC-induced DAH often forces the discontinuation of anticoagulant therapy and the administration of high-dose corticosteroids,

which increases the risk of ischemic stroke and cardiovascular events.

To resolve this dilemma, we herein report a case in which percutaneous left atrial appendage (LAA) closure was performed in a patient with OAC-induced DAH and AF.

Case Report

The patient was a 74-year-old man who had been taking an anticoagulant (apixaban, 10 mg/day) for non-valvular AF for more than 5 years. He had undergone left lower lobectomy for squamous cell carcinoma of the lung (pT1bN0M0, stage IA) two months previously, and subsequently, his post-operative course had been good. However, he was emergently admitted to our hospital due to the appearance of bloody sputum for the past two weeks and a worsening of his respiratory condition for the past week.

Chest X-ray and high-resolution computed tomography (HRCT) on admission demonstrated extensive alveolar infiltration in the right lung and left pleural effusion due to left lower lobectomy (Fig. 1). Laboratory findings revealed se-

¹Department of Respiratory, Kokura Memorial Hospital, Japan, ²Department of Cardiovascular Medicine, Kokura Memorial Hospital, Japan and

³Department of Respiratory Medicine, University of Occupational and Environmental Health, Japan

Received: August 22, 2021; Accepted: October 14, 2021; Advance Publication by J-STAGE: November 27, 2021

Correspondence to Dr. Takaaki Ogoshi, togoshi@med.uoeh-u.ac.jp

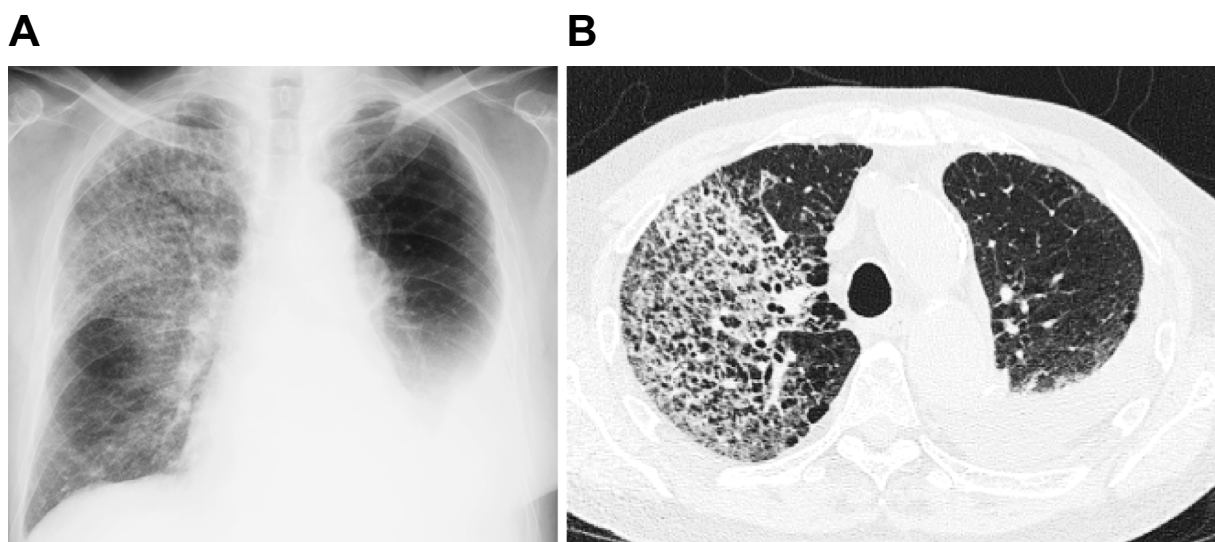


Figure 1. Chest X-ray film (A) and high-resolution computed tomography (B) on admission demonstrated extensive alveolar infiltration in the right lung, and left pleural effusion due to left lower lobectomy.

vere inflammation with a white blood cell count of 8,200/ μ L (neutrophils: 85.1%; lymphocytes: 10.2%; eosinophils: 1.1%) and a C-reactive protein level of 11.8 mg/dL. The patient's platelet count was 213,000/ mm^3 , his hemoglobin level was 14.4 mg/ μ L, his prothrombin time-international normalized ratio was 1.19, his activated partial thromboplastin time was 31.8 seconds, his serum creatinine level was 0.75 mg/dL, and his Krebs von den Lugen 6 value was 253 IU/mL. His serum levels of antineutrophil cytoplasmic antibody, perinuclear antineutrophil cytoplasmic antibody, antinuclear antibody by indirect fluorescent antibody method, anti-dsDNA antibody, anti-Ro (SS-A) antibody, anti-La (SS-B) antibody, anti Jo-1 antibody, and antiglomerular basement membrane antibody were all negative. The results of echocardiography showed an almost normal left ventricular function and no valvular disease.

After admission, as he was resistant to antibiotics (levofloxacin and meropenem) for 7 days, flexible bronchoscopy was performed for definitive diagnostic purposes on day 10. Flexible bronchoscopy showed no abnormal findings, including in the trachea, right middle bronchus, and stump of the left lower bronchus after lobectomy (Fig. 2A-C), and subsequent bronchoalveolar lavage (BAL) findings from the middle bronchus showed a bloody gross appearance with hemosiderin-filled macrophages and no malignant cells (Fig. 2D-F). The analyses of the BAL fluid (BALF) and sputum revealed no causative pathogen or evidence of relapse of lung cancer. In addition, there was no evidence of disseminated intravascular coagulation or hemorrhagic events occurring elsewhere in the body. Given the clinical findings, a diagnosis of apixaban-induced DAH was established.

After the diagnosis, apixaban was withdrawn, and prednisolone (30 mg/day, 0.5 mg/kg/day) was administered on the 10th day. His respiratory status and chest imaging findings

improved quickly within two weeks (Fig. 3), and he became asymptomatic. However, as he was in a high-risk group for stroke (CHA₂DS₂-VASc 3 points), we were concerned that prolonged withdrawal of apixaban would lead to stroke and other embolic events, in addition to long-term use of high-dose corticosteroids. Furthermore, because he was at a high risk for bleeding with a HAS-BLED score of 5 points, we were also concerned that the resumption of OAC increased the risk of rebleeding, which posed a therapeutic dilemma. Therefore, in view of the high risk of recurrent DAH, and to prevent stroke, low-dose apixaban (5 mg/day) was restarted on the 7th day after the diagnosis, and percutaneous placement of a 30-mm WATCHMAN™ device (Boston Scientific, Natick, USA) for LAA closure was performed on the 35th day after the diagnosis (Fig. 4). The results were excellent without any significant residual leak, pericardial effusion, or embolic complication.

After the procedure, low-dose apixaban plus aspirin (81 mg/day) was continued for the initial 45 days, and since transoesophageal echocardiogram after 45 days showed a stable device position and LAA occlusion without any significant residual leak or device-related thrombus, he discontinued apixaban completely. Thereafter, clopidogrel (75 mg/day) were also administered for 6 months, and then only aspirin was administered indefinitely with adequate prednisolone tapering. No prednisolone was given after four months, but no relapse of DAH or stroke has occurred thus far.

Discussion

Most patients with AF should receive long-term OAC to reduce the risk of ischemic stroke and other embolic events. However, anticoagulation increases the risk of major bleeding and is responsible for severe events in up to 2.3% of patients per year (6). Most bleeding occurs in the gastrointesti-

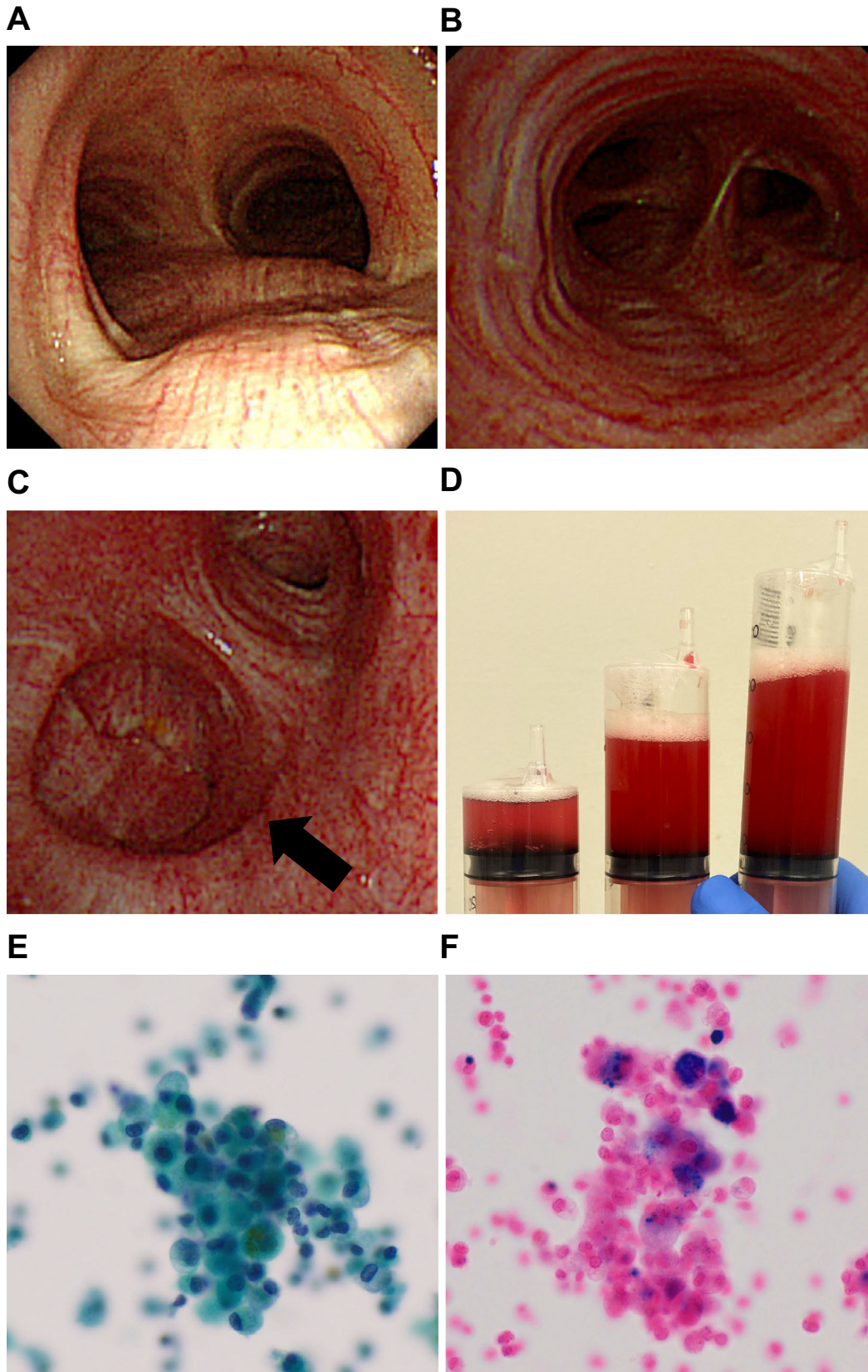


Figure 2. Flexible bronchoscopy demonstrated that there were no abnormal findings, including in the trachea (A), right middle bronchus (B), or stump of the left lower bronchus after lobectomy (C). Bronchoalveolar lavage fluid from the middle bronchus showed a bloody gross appearance (D) with numerous hemosiderin-filled macrophages detected by Papanicolaou (E) and Berlin blue (F) staining ($\times 20$).

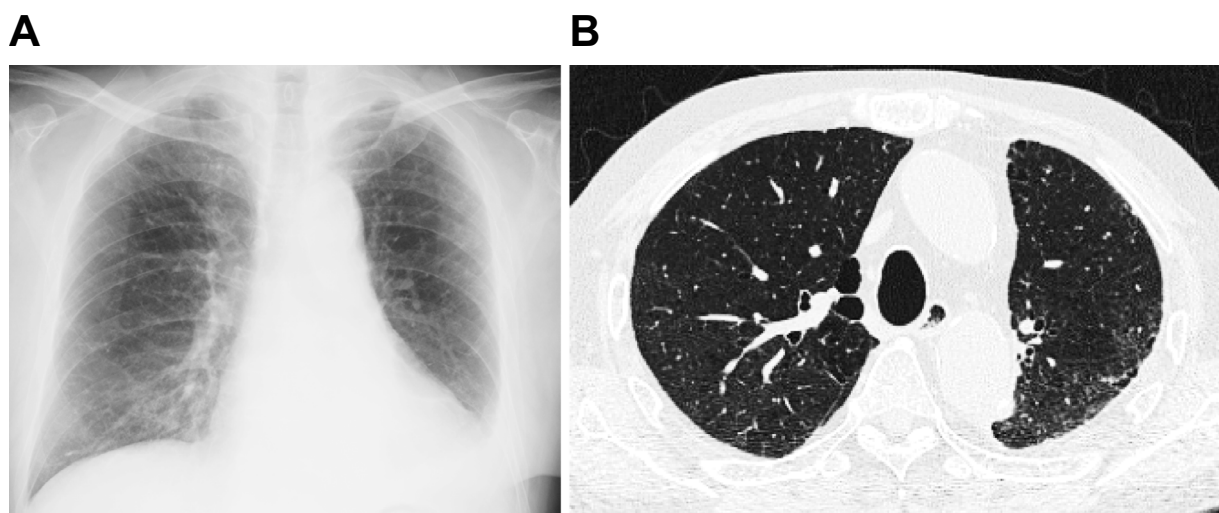


Figure 3. Chest X-ray film (A) and high-resolution computed tomography (B) on two weeks after discontinuation of apixaban and administration of prednisolone therapy revealed remarkable improvement.

nal tract and brain, but there have been several reports on DAH as well (7-13).

OAC-induced DAH is a very serious condition, with a very high in-hospital mortality rate of about 50%, similar to other causes of DAH (14). Although there are no published data to guide the management of patients with OAC-induced DAH and AF, we believe there are three reasons why this management can be quite challenging. First, the definitive diagnosis of OAC-induced DAH is often difficult because symptoms are non-specific, hemoptysis is absent in up to one-third of patients, and radiographic imaging is also non-specific and similar to other diseases, such as pneumonitis (3, 15). This means that the discontinuation of OAC is delayed, and the clinical condition tends to be exacerbated, leading to a fatal outcome. In addition, although it is often possible to make a definitive diagnosis only by performing BALF by bronchoscopy, it is difficult to perform flexible bronchoscopy, as many patients have severe respiratory failure. In fact, in the present case, although bloody sputum was found two weeks before admission, the definitive diagnosis and withdrawal of apixaban could only be made based on the analysis of BALF on day 10 of hospitalization. Second, previous reports, including our case, have shown that DAH is often treated with the long-term use of high-dose corticosteroids to suppress the cytokine storm caused by lung injury or inflammation (3, 14, 16). However, the long-term use of high-dose corticosteroids is known to further worsen the prognosis, as it greatly increases the risk of stroke and cardiovascular events (17). In addition, corticosteroid use is also known to be associated with a dose- and time-dependent increase in serious infections (18, 19). Finally, restarting OAC poses a clinical dilemma due to the high risk of recurrence of DAH and the occurrence of AF-induced stroke. Furthermore, there have been no previous reports detailing whether or not patients with OAC-induced

DAH restarted OAC after stabilization.

For this reason, we focused our attention on LAA closure in the management of both OAC-induced DAH and AF. The LAA is the main location of thrombus formation in approximately 90% of nonrheumatic patients with AF (20). In this context, the WATCHMAN™ device was developed as a mechanical barrier to avoid embolization from the LAA by sealing the orifice of the LAA. Percutaneous LAA closure using the WATCHMAN™ device is feasible, safe, and effective, and previous data indicate no increase in rates of stroke or death in comparison to OAC (6, 21-23). In particular, a recent prospective clinical trial from Japan demonstrated that the rate of implantation success of the WATCHMAN™ device was 100%. The 2-year incidence was 7.1% for ischemic stroke, 0.0% for hemorrhagic stroke, 0.0% for systemic infarction, and 2.4% for cardiovascular death or death from unknown causes, which is an excellent implantation success rate with acceptable safety and promising clinical data (24). Therefore, percutaneous LAA closure seems to be a viable alternative to OAC in patients with AF and DAH who are at high risk for embolic and bleeding complications, and over the long term, it has a potential to be more effective than OAC therapy, as it is associated with less use of high-dose corticosteroids and re-bleeding. However, since there are no data on the long-term prognostic efficacy and safety of percutaneous LAA closure in OAC-induced DAH. In addition, since the optimal management of systemic glucocorticoids and postprocedural antithrombotic therapy in OAC-induced DAH is also uncertain at this time (25), further studies are needed.

To our knowledge, this is the first report on percutaneous LAA closure using a WATCHMAN™ device in a patient apixaban-induced DAH and permanent AF. Percutaneous LAA closure can aid in the management of OAC-induced DAH and AF.

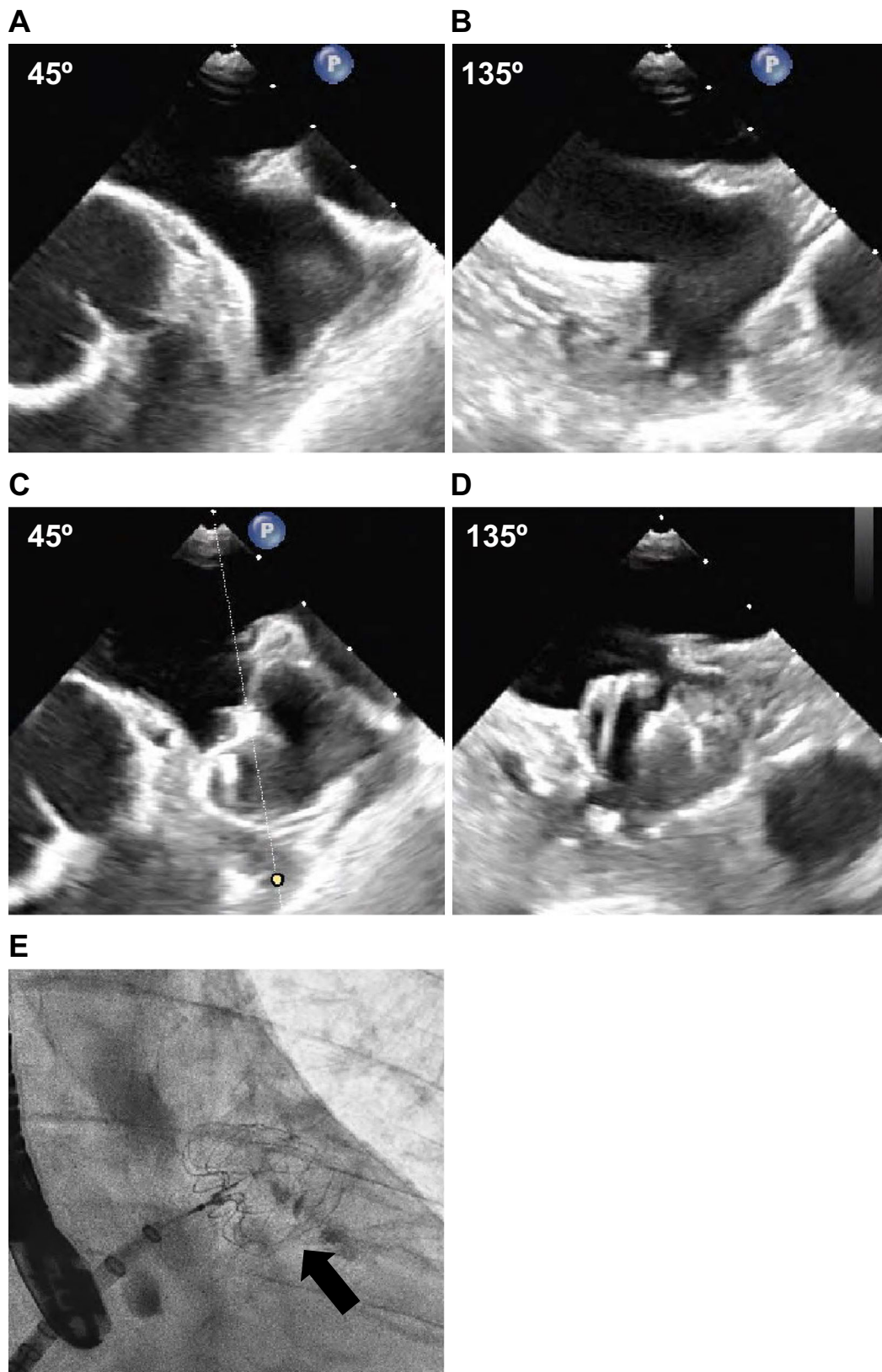


Figure 4. Two-dimensional transesophageal echocardiography image of left atrial appendage before procedure showed normal left atrium without thrombus (A, B). Subsequently, the deployed left atrial appendage closure device (30-mm WATCHMAN™) was confirmed with transesophageal echocardiographic imaging (C, D) and fluoroscopic imaging (E).

The authors state that they have no Conflict of Interest (COI).

References

- Colby TV, Fukuoka J, Ewaskow SP, Helmers R, Leslie KO. Pathologic approach to pulmonary hemorrhage. *Ann Diagn Pathol* **5**: 309-319, 2001.
- Franks TJ, Koss MN. Pulmonary capillaritis. *Curr Opin Pulm Med* **6**: 430-435, 2000.
- Lara AR, Schwarz MI. Diffuse alveolar hemorrhage. *Chest* **137**: 1164-1171, 2010.
- De Prost N, Parrot A, Picar C, et al. Diffuse alveolar haemorrhage: factors associated with in-hospital and long-term mortality. *Eur Resp J* **35**: 1303-1311, 2010.
- Quadrelli S, Dubinsky D, Solis M, et al. Immune diffuse alveolar hemorrhage: clinical presentation and outcome. *Respir Med* **129**: 59-62, 2017.
- Holmes DR, Reddy VY, Turi ZG, et al. Percutaneous closure of the left atrial appendage versus warfarin therapy for prevention of stroke in patients with atrial fibrillation: a randomised non-inferiority trial. *Lancet* **374**: 534-542, 2009.
- Gabrilovich MI, Buxton DE, Lykins DM, McMillen SM, Onadeko OO. Diffuse alveolar hemorrhage secondary to apixaban administration. *Chest* **146**: e115-e116, 2014.
- Waness A, Aldabbagh T, Harakati M. Diffuse alveolar haemorrhage secondary to warfarin therapy for atrial fibrillation: a case report and literature review. *BMJ Case Rep* **2009**: bcr0820080757, 2009.
- Borjian S, Hakkak N, Borjian MA. A rare case of diffuse alveolar hemorrhage (DAH) due to warfarin toxicity. *Rom J Intern Med* **58**: 35-39, 2020.
- Erdogan D, Kocaman O, Oflaz H, Goren T. Alveolar hemorrhage associated with warfarin therapy: a case report and literature review. *Int J Cardiovasc Imaging* **20**: 155-159, 2004.
- Heffler E, Campisi R, Ferri S, Crimi N. A bloody mess: an unusual case of diffuse alveolar hemorrhage because of warfarin overdose. *Am J Ther* **23**: e1280-e1283, 2016.
- Kunal S, Bagarhatta R, Singh S, Sharma SK. Warfarin-induced diffuse alveolar hemorrhage: case report and a review of the literature. *Lung India* **36**: 534-539, 2019.
- Nitta K, Imamura H, Yashio A, Kashima S, Mochizuki K. Diffuse alveolar hemorrhage associated with edoxaban therapy. *Case Rep Crit Care* **2016**: 7938062, 2016.
- Otoshi T, Kataoka Y, Nakagawa A, Otsuka K, Tomii K. Clinical features and outcomes of diffuse alveolar hemorrhage during antithrombotic therapy: a retrospective cohort study. *Lung* **194**: 475-481, 2016.
- Lichtenberger III JP, Digumarthy SR, Abbott GF, Shepard JAO, Sharma A. Diffuse pulmonary hemorrhage: clues to the diagnosis. *Curr Probl Diagn Radiol* **43**: 128-139, 2014.
- Aggarwal NR, King LS, D'Alessio FR. Diverse macrophage populations mediate acute lung inflammation and resolution. *Am J Physiol Lung Cell Mol Physiol* **306**: L709-L725, 2014.
- Johannesdottir SA, Horváth-Puhó E, Dekkers OM, et al. Use of glucocorticoids and risk of venous thromboembolism: a nationwide population-based case-control study. *JAMA Int Med* **173**: 743-752, 2013.
- Curtis JR, Patkar N, Xie A, et al. Risk of serious bacterial infections among rheumatoid arthritis patients exposed to tumor necrosis factor α antagonists. *Arthritis Rheum* **56**: 1125-1133, 2007.
- Dixon WG, Abrahamowicz M, Beauchamp ME, et al. Immediate and delayed impact of oral glucocorticoid therapy on risk of serious infection in older patients with rheumatoid arthritis: a nested case - control analysis. *Ann Rheum Dis* **71**: 1128-1133, 2012.
- Blackshear JL, Odell JA. Appendage obliteration to reduce stroke in cardiac surgical patients with atrial fibrillation. *Ann Thorac Surg* **61**: 755-759, 1996.
- Reddy VY, Doshi SK, Sievert H, et al. Percutaneous left atrial appendage closure for stroke prophylaxis in patients with atrial fibrillation: 2.3-year follow-up of the PROTECT AF (Watchman Left Atrial Appendage System for Embolic Protection in Patients with Atrial Fibrillation) trial. *Circulation* **127**: 720-729, 2013.
- Boersma LV, Schmidt B, Betts TR, et al. Implant success and safety of left atrial appendage closure with the WATCHMAN device: peri-procedural outcomes from the EWOLUTION registry. *Eur Heart J* **37**: 2465-2474, 2016.
- Osmancik P, Herman D, Neuzil P, et al. Left atrial appendage closure versus direct oral anticoagulants in high-risk patients with atrial fibrillation. *J Am Coll Cardiol* **75**: 3122-3135, 2020.
- Aonuma K, Yamasaki H, Nakamura M, et al. Efficacy and safety of left atrial appendage closure with WATCHMAN in Japanese nonvalvular atrial fibrillation patients - final 2-year follow-up outcome data from the SALUTE trial -. *Circ J* **84**: 1237-1243, 2020.
- Chew DS, Piccini JP. Postprocedural antithrombotic therapy following left atrial appendage occlusion: no longer adrift in uncertainty? *Circ Cardiovasc Interv* **13**: e009534, 2020.

The Internal Medicine is an Open Access journal distributed under the Creative Commons Attribution-NonCommercial-NoDerivatives 4.0 International License. To view the details of this license, please visit (<https://creativecommons.org/licenses/by-nc-nd/4.0/>).