

Case Report

Use of Amniotic Membrane Transplant and Deep Anterior Keratoplasty in a Patient with Bilateral Acanthamoeba Infectious Keratitis: A Case Report

Carlos A. Müller-Morales Guillermo Raul Vera-Duarte
Valeria Oliva-Bienzobas Arturo Ramirez-Miranda Alejandro Navas
Enrique O. Graue-Hernandez

Instituto De Oftalmologia Fundacion Conde De Valenciana FAP, Department of Cornea, External Diseases and Refractive Surgery, Mexico City, Mexico

Keywords

Acanthamoeba keratitis · Amniotic membrane transplant · Deep anterior keratoplasty

Abstract

The aim of this study was to report a case with the use of amniotic membrane transplant and deep anterior keratoplasty in a patient with bilateral Acanthamoeba infectious keratitis as a treatment. A 20-year-old male presented with bilateral Acanthamoeba keratitis (AK) who was initially diagnosed with herpetic keratitis receiving full antiviral and corticosteroid topical treatment without any improvement. Corneal biopsy was performed to confirm the suspected diagnosis, and Acanthamoeba stromal cysts were identified in the sample. Treatment was initiated with 0.02% chlorhexidine, 0.1% propamidine isethionate, neomycin, and tropicamide/phenylephrine. Symptoms and clinical improvement were achieved between the 8th and 10th weeks, so corticosteroids were initiated. Treatment was continued until we observed a poor response in the left eye; therefore, an epithelial scraping and amniotic membrane placement were performed. Lately, the right eye underwent a deep anterior lamellar keratoplasty. A challenging case of bilateral AK managed with topical medications, amniotic membrane, and corneal keratoplasty. The earlier the disease is diagnosed, the better the outcome. If the diagnosis is delayed, the amoebas have penetrated deep into the corneal stroma, and successful therapy becomes difficult. A surgical option can be an early solution with a good prognosis for these cases.

© 2023 The Author(s).
Published by S. Karger AG, Basel

Correspondence to:
Enrique O. Graue-Hernandez, egraueh@gmail.com

Introduction

Corneal infections caused by parasites are rare; however, they constitute one of the most important causes of morbidity and blindness worldwide. *Acanthamoeba* is a rare pathogenic agent, but its incidence is increasing [1, 2]. *Acanthamoeba* spp. are ubiquitous free-living protozoa isolated from various habitats, including air, soil, dust, water from ponds, swimming pools, and contact lens solutions [2, 3].

The first case of *Acanthamoeba* keratitis (AK) was reported in 1974 by Nagington, after which numerous cases have been reported. Most of these have been related to the use of contact lenses, although other risk factors, such as corneal trauma and exposure to contaminated water, have been identified [4]. It can affect patients of all ages; however, it is more common in young, healthy, and immunocompetent adults [5].

Case Report

A 20-year-old male presented to the clinic with bilateral painful red eyes, photophobia, and tearing associated with profound visual loss after 2 months of evolution. He had a previous diagnosis of herpetic keratitis and was treated with topical and oral antivirals, topical antibiotics, and topical corticosteroids without improvement. He was a soft contact lens user with poor care of maintenance solutions. He stopped using his contact lens at the beginning of symptoms and kept them with him until consultation.

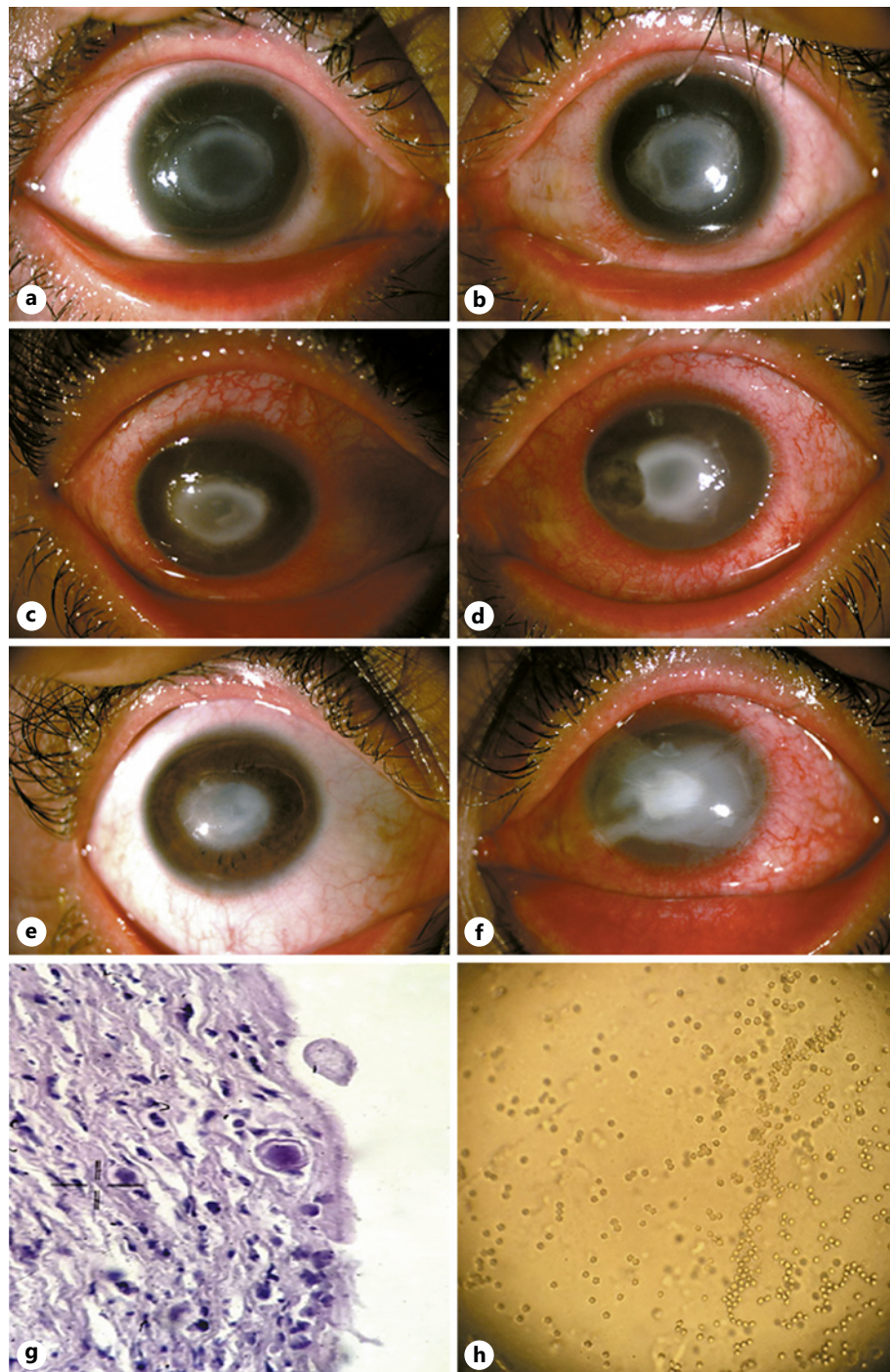
On physical examination, at first consultation, visual acuity in the right eye (RE) was 4/200 and in the left eye (LE) was 2/200. Biomicroscopy of both eyes revealed palpebral edema, diffuse ciliary injection, conjunctival congestion, 360-degree limbitis, corneal stromal edema associated with whitish annular infiltrate extending toward the posterior stroma (Fig. 1a, b); fluorescein staining showed an epithelial defect extending throughout the lesion.

All medications were suspended for 48 h to obtain corneal cultures, stain scrapings, and patient's contact lens solutions. Corneal microbiological cultures and PCR testing were negative, although contact lens solutions were positive in both tests. Microbiological culture showed *Acanthamoeba* cyst development; these were seeded in non-nutrient agar plate covered with a lawn of a 24-old culture of non-mucous bacteria (containing *Escherichia coli*) solution. We underwent corneal biopsy of the LE to confirm the suspected diagnosis, and *Acanthamoeba* cysts were identified in the sample (Fig. 1g).

Once the diagnosis was confirmed, treatment was initiated with 0.02% chlorhexidine (CHX) every hour, 0.1% propamidine isethionate every hour, neomycin every 2 h, and tropicamide/phenylephrine every 12 h. We started seeing a slow improvement after 2 weeks, so the same regimen was continued for 8 weeks. By this time, we gained symptomatic and clinical improvement, with less pain and better visual acuity (Fig. 1e). Therefore, treatment was adjusted: amebicides were tapered (CHX q4 h, propamidine isethionate q4 h, neomycin q8 h), and steroids (prednisolone acetate) were initiated every 4 h.

After 15 weeks of treatment, the clinical improvement of the LE diminished; therefore, we decided to perform epithelial scraping with amniotic membrane placement (Fig. 1f). Likewise, the possibility of a RE corneal transplant was raised, and the patient was enrolled in the eye bank.

At week 25, RE underwent a deep anterior lamellar keratoplasty (DALK) (Fig. 2a). The patient had a postoperative course without complications and continued anti-amoebic therapy for 3 weeks. A final visual acuity was 20/70 in the RE and 20/200 in the LE.



1

(For legend see next page.)

Discussion

The presentation of this case is unusual, as it was a bilateral case. Wilhelmus et al. [6] reported an incidence rate of 11% for bilateral AK cases, and they suggest a potential increase in prevalence. Clinically, the infection is initially characterized by limbitis, punctate keratopathy, and epithelial, subepithelial, or perineural infiltrates, conjunctival and ciliary

hyperemia, tearing, photophobia, and pain of varying intensity, disproportionate to the ocular signs, as well as decreased visual acuity.

Like many others with the same condition, the main risk factors were the use of soft contact lenses, misuse of maintenance solutions, and/or occasional use of tap water to clean them. It has been estimated that up to 26% of patients reported using tap water to clean their contact lenses [7].

As in our report, initial misdiagnosis and incorrect use of corticosteroids are common [8]. It is important to note that the agent's pathophysiology with using corticosteroids promotes the parasite's encystment and, therefore, the perpetuation of the infection [5, 9].

Diagnosis requires high clinical suspicion as well as complementary studies. The clinical manifestations are often confused with those of herpetic, fungal, or mycobacterial keratitis, delaying the correct diagnosis and initiation of treatment. A delay in diagnosis is associated with a worse visual prognosis and a longer recovery time. Consideration of Acanthamoeba diagnosis is suspected in patients presenting with atypical HSK or in cases where the disease exhibits suboptimal response to appropriate antiviral therapy [10, 11]. The definitive diagnosis of AK is based on the presence of trophozoites in samples and/or cultures of the corneal scraping; in certain circumstances, a biopsy is required, for example, when the cultures are negative and clinical suspicion persists [12]. Free-living amoebas in contact lenses or conservation cases do not necessarily imply infection by this microorganism since they can be found as contaminants in up to 8% [13]. Although microbiology can help derive a definitive diagnosis by isolating the cysts or trophozoites of Acanthamoeba, noninvasive in vivo confocal microscopy and anterior segment optical coherence tomography can be used as adjuncts for the diagnosis of AK [14–16].

Medical treatment has limited therapeutic options, a deficiency of available drugs, and a lack of standardization of optimal therapy. Amebicide agents are diamidines and biguanides, the first inhibits oxygen consumption and induces amino acid efflux from the cell, and cell surface damage (e.g., Brolene and PHMB); biguanide's primary site of action is the cytoplasmic membrane due to electrostatic interactions with acid phospholipids (e.g., CHX). Biguanides are the first-choice drug, alone or associated with diamidines [5, 17–19]. PHMB can be prescribed within a concentration range of 0.02–0.06%, while CHX, initially prescribed at 0.02%, can be escalated up to 0.2% [20]. Topical CHX was administered hourly, both day and night, based on the initial clinical response. Subsequently, the dosage was gradually tapered, and due to the plateauing of improvement during treatment, the decision was made to implement an amniotic membrane intervention. Previous studies advocate using 0.02% CHX as a viable and promising initial treatment option for AK. However, these studies also underscore the importance of considering the potential toxicity associated with its use [21, 22]. Early intensive therapy is more effective as the cysts have not had time to penetrate deep into the corneal tissue [5]. Complementary treatment is aminoglycosides that limits the availability of food for the agent. However, their prolonged use can promote resistance and hypersensitivity [23].

Fig. 1. a Slit-lamp photograph of RE at initial presentation showing patchy stromal infiltrates with radial keratoneuritis. **b** Slit-lamp photograph of LE showing an epithelial defect along with a ring-shaped infiltrate with radial keratoneuritis and stromal edema. **c** Slit-lamp photograph of RE at 1-month follow-up showing resolving stromal infiltrates with early stromal scarring with radial keratoneuritis. **d** Slit-lamp photograph of LE at 1 month follow-up showing resolving stromal infiltrates with central stromal scarring with radial keratoneuritis. **e** Slit-lamp photograph of RE at 8 weeks of follow-up after complete resolution showing the faint stromal scar. **f** Slit-lamp photograph of LE at 15 weeks of follow-up showing central stromal scarring with amniotic membrane placement. **g** Anterior stroma biopsy specimen stained with 10% potassium hydroxide and 0.1% calcofluor white showing multiple bluish-white polygonal double-walled structures suggestive of Acanthamoeba cysts observed under $\times 20$ magnification in the fluorescent microscope. **h** Acanthamoeba cysts in clusters isolated on non-nutrient agar overlaid with *Escherichia coli* from one of the contact lenses culture.

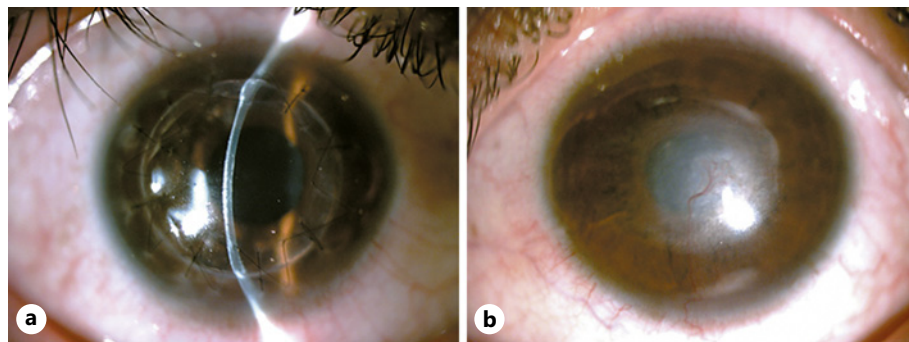


Fig. 2. **a** Slit-lamp photograph of RE showing DALK of the RE. **b** LE showing central stromal scarring.

Use of topical corticosteroids remains controversial, necessitating cautious initiation. Avoiding or delaying their use is recommended, as they can lead to prolonged medical treatment [24]. Evidence suggests starting corticosteroids after starting anti-amoebic drugs because it improves pain and does not interfere with visual prognosis [9]. At the beginning of treatment, they are unnecessary. However, when significant anterior segment inflammation is present, steroids may facilitate rapid resolution of symptoms but should be used judiciously due to the potential risk of worsening the condition. Corticosteroids suppress the activity of neutrophils and macrophages and promote trophozoite encystment, decreasing the potency of anti-amoebic agents [9, 25, 26].

Secondary glaucoma should be taken as a potential complication in AK, where the findings indicate angle closure without pupillary blockage, resulting from excessive and chronic inflammation at the angle and subsequent formation of peripheral anterior synechiae [27–29]. Fortunately, our patient did not develop glaucoma.

Several options are available for surgical management. Debridement of the corneal epithelium promotes drug penetration into the corneal stroma and decreases the viral load of the pathogen [25]. Urgent penetrating keratoplasty should be used in cases with a corneal perforation or poor response to medical management; the prognosis for these cases is reserved [30] and should be delayed until such time as the eye is uninflamed and medically cured of *Acanthamoeba* [31]. Amniotic membranes as a complementary measure have shown several benefits, including mechanical protection and anti-inflammatory effect [32]. In a series of 6 cases with active stromal inflammation or epithelial defect, the benefit of its use was reported, demonstrating improvement of the inflammatory state, closure of the epithelial defect, and symptom reduction, similar to that of our patient [33]. Treatment can be extended up to 6–12 months if follow-up cultures and stains continue to show the pathogen. Once these show a negative result, monotherapy with biguanides can be extended for several weeks until they are discontinued [34].

Recurrence of infection is one of the most important complications after keratoplasty. A two-fold higher rate of recurrence has been reported in therapeutic keratoplasty compared to optical keratoplasty in AK (41% vs. 22%) [35]. Cysts have been shown to persist for many months after initiation of medical therapy, and reactivation of cysts found in the peripheral cornea is responsible for the recurrence of infection. In our patient, optical coherence tomography of the anterior segment documented that the deepest layers of the cornea were spared; therefore, DALK was considered an option. In cases of AK, the performance of DALK serves multiple purposes, including reducing the trophozoite's mass, restoring visual acuity, minimizing the risk of intraocular entry of infectious organisms during surgery, therefore the risk of secondary endophthalmitis, and potentially improving graft survival rates by

reducing endothelial rejection and failure [36, 37]. Multiple studies, including significant case series, have been published, demonstrating favorable outcomes [37–42]. The best time to perform surgery is when the infection is controlled and there are at least 6 months of medical treatment, a criterion that was met with our patient [6]. On the other hand, authors like Sarnicola et al. [40] suggested that early surgical intervention may enhance the likelihood of DALK achieving curative outcomes, leading to improved graft survival and visual outcomes. Furthermore, it is advisable to prolong the administration of anti-amoebic treatment for a period of 2–4 weeks after the surgical procedure [12, 25, 43].

Conclusions

A challenging case of bilateral AK managed with medications, amniotic membrane, and corneal keratoplasty in a patient, leading to a successful resolution. Highlighting pharmacological treatment needs to be better established, although there are therapeutic outlines that have shown promising results, as in our case. Regarding soft contact lenses, it is essential to note that using non-sterile conservation solutions, tap water, or uncovered containers for a long time constitutes a risk of transmitting infection. The earlier the disease is diagnosed, the better the outcome. If the diagnosis is delayed, the amoebas have penetrated deep into the corneal stroma, and successful therapy becomes difficult. The CARE Checklist has been completed by the authors for this case report, attached as online supplementary material (for all online suppl. material, see <https://doi.org/10.1159/000533988>).

Statement of Ethics

This case report abided the tenets of the Declaration of Helsinki and obtained written informed consent to publish and use relevant images from the subject. Written informed consent was obtained from the patient for publication of the details of their medical case and any accompanying images. Ethical approval is not required for this study in accordance with local or national guidelines.

Conflict of Interest Statement

The authors have no conflicts of interest to declare.

Funding Sources

The authors did not receive financial support for this research.

Author Contributions

C.A.M.M., G.R.V.D., and V.O.B.: patient follow-up, data collection, and writing; A.R.M., A.N., and E.O.G.H.: planning, supervision, validation, and visualization. All authors discussed the results and contributed to the final manuscript, and all authors attest that they meet the current ICMJE criteria for authorship.

Data Availability Statement

All data generated or analyzed during this study are included in this article and its supplementary material files. Further inquiries can be directed to the corresponding author.

References

- 1 Niederkorn JY, Alizadeh H, Leher H, McCulley JP. The pathogenesis of Acanthamoeba keratitis. *Microbes Infect.* 1999 May;1(6):437–43.
- 2 Ramírez Molas L, Kang H, Ayala Lugo R, Fariña N, Sanabria R, Miño de Kaspar H. Queratitis por Acanthamoeba sp. Reporte de caso. *An Fac Cienc Médicas Asunción.* 2005;38:44–7.
- 3 Clarke DW, Niederkorn JY. The pathophysiology of Acanthamoeba keratitis. *Trends Parasitol.* 2006 Apr;22(4):175–80.
- 4 McAllum P, Bahar I, Kaiserman I, Srinivasan S, Slomovic A, Rootman D. Temporal and seasonal trends in acanthamoeba keratitis. *Cornea.* 2009;28(1):7–10.
- 5 Maycock NJR, Jayaswal R. Update on acanthamoeba keratitis: diagnosis, treatment, and outcomes. *Cornea.* 2016 May;35(5):713–20.
- 6 Wilhelmus KR, Jones DB, Matoba AY, Hamill MB, Pflugfelder SC, Weikert MP. Bilateral acanthamoeba keratitis. *Am J Ophthalmol.* 2008 Feb;145(2):193–7.
- 7 Kaiserman I, Bahar I, McAllum P, Srinivasan S, Elbaz U, Slomovic AR, et al. Prognostic factors in Acanthamoeba keratitis. *Can J Ophthalmol.* 2012 Jun;47(3):312–7.
- 8 Obeid WN, Araújo R, Vieira LA, Machado MA. Ceratite bilateral por Acanthamoeba: relato de caso. *Arq Bras Oftalmol.* 2003;66(6):876–80.
- 9 Carnt N, Robaei D, Watson SL, Minassian DC, Dart JKG. The impact of topical corticosteroids used in conjunction with antiamebic therapy on the outcome of acanthamoeba keratitis. *Ophthalmology.* 2016 May;123(5):984–90.
- 10 Johns KJ, O'Day DM, Head WS, Neff RJ, Elliott JH. Herpes simplex masquerade syndrome: acanthamoeba keratitis. *Curr Eye Res.* 1987 Jan;6(1):207–12.
- 11 Tay-Kearney ML, McGhee CN, Crawford GJ, Trown K. Acanthamoeba keratitis. A masquerade of presentation in six cases. *Aust N Z J Ophthalmol.* 1993 Nov;21(4):237–45.
- 12 Lorenzo-Morales J, Khan NA, Walochnik J. An update on Acanthamoeba keratitis: diagnosis, pathogenesis and treatment. *Parasite.* 2015;22:10.
- 13 Lee WB, Gotay A. Bilateral Acanthamoeba keratitis in Synergeyes contact lens wear: clinical and confocal microscopy findings. *Eye Contact Lens.* 2010 May;36(3):164–9.
- 14 Kasparova EA, Marchenko NR, Surnina ZV, Mitichkina TS. Confocal microscopy in the diagnosis of acanthamoeba keratitis. *Vestn Oftalmol.* 2021;137(5. Vyp. 2):201–8.
- 15 Yamazaki N, Kobayashi A, Yokogawa H, Ishibashi Y, Oikawa Y, Tokoro M, et al. In vivo imaging of radial keratoneuritis in patients with Acanthamoeba keratitis by anterior-segment optical coherence tomography. *Ophthalmology.* 2014 Nov;121(11):2153–8.
- 16 Füst Á, Tóth J, Simon G, Imre L, Nagy ZZ. Specificity of in vivo confocal cornea microscopy in Acanthamoeba keratitis. *Eur J Ophthalmol.* 2017 Jan;27(1):10–5.
- 17 Chin J, Young AL, Hui M, Jhanji V. Acanthamoeba keratitis: 10-year study at a tertiary eye care center in Hong Kong. *Cont Lens Anterior Eye.* 2015 Apr;38(2):99–103.
- 18 Duguid IG, Dart JK, Morlet N, Allan BD, Matheson M, Ficker L, et al. Outcome of acanthamoeba keratitis treated with polyhexamethyl biguanide and propamidine. *Ophthalmology.* 1997 Oct;104(10):1587–92.
- 19 Mathers W. Use of higher medication concentrations in the treatment of acanthamoeba keratitis. *Arch Ophthalmol.* 2006 Jun;124(6):923–.
- 20 Wang X, Jacobs DS. An update on the initial treatment of acanthamoeba keratitis. *Int Ophthalmol Clin.* 2022 Apr;62(2):101–10.
- 21 Wysenbeek YS, Blank-Porat D, Harizman N, Wagnanski-Jaffe T, Keller N, Avni I. The reculture technique: individualizing the treatment of Acanthamoeba keratitis. *Cornea.* 2000 Jul;19(4):464–7.
- 22 Rahimi F, Hashemian SMN, Tafti MF, Mehjerdi MZ, Safizadeh MS, Pour EK, et al. Chlorhexidine monotherapy with adjunctive topical corticosteroids for acanthamoeba keratitis. *J Ophthalmic Vis Res.* 2015;10(2):106–11.
- 23 Seal DV. Acanthamoeba keratitis update-incidence, molecular epidemiology and new drugs for treatment. *Eye Lond Engl.* 2003 Nov;17(8):893–905.
- 24 Park DH, Palay DA, Daya SM, Stulting RD, Krachmer JH, Holland EJ. The role of topical corticosteroids in the management of Acanthamoeba keratitis. *Cornea.* 1997 May;16(3):277–83.
- 25 Dart JKG, Saw VPJ, Kilvington S. Acanthamoeba keratitis: diagnosis and treatment update 2009. *Am J Ophthalmol.* 2009 Oct;148(4):487–99.e2.
- 26 Robaei D, Carnt N, Minassian DC, Dart JKG. The impact of topical corticosteroid use before diagnosis on the outcome of Acanthamoeba keratitis. *Ophthalmology.* 2014 Jul;121(7):1383–8.

- 27 Al Owaifeer AM, Al-Omair S, Alrefaie S, Alenezi SH, Al-Shahwan S. Incidence and risk factors of ocular hypertension and glaucoma in patients with acanthamoeba keratitis. *Eye Contact Lens*. 2021 Nov;47(11):588–91.
- 28 Dossey AP, Patel D, Whitson J, Cavanaugh HD. Secondary glaucoma associated with acanthamoeba keratitis. *Invest Ophthalmol Vis Sci*. 2004 May;45(13):5533.
- 29 Kelley PS, Dossey AP, Patel D, Whitson JT, Hogan RN, Cavanagh HD. Secondary glaucoma associated with advanced acanthamoeba keratitis. *Eye Contact Lens*. 2006 Jul;32(4):178–82.
- 30 Nguyen TH, Weisenthal RW, Florakis GJ, Reidy JJ, Gaster RN, Tom D. Penetrating keratoplasty in active Acanthamoeba keratitis. *Cornea*. 2010 Sep;29(9):1000–4.
- 31 Robaei D, Carnt N, Minassian DC, Dart JKG. Therapeutic and optical keratoplasty in the management of Acanthamoeba keratitis: risk factors, outcomes, and summary of the literature. *Ophthalmology*. 2015 Jan;122(1):17–24.
- 32 Abdulhalim BEH, Wagih MM, Gad AAM, Boghdadi G, Nagy RRS. Amniotic membrane graft to conjunctival flap in treatment of non-viral resistant infectious keratitis: a randomised clinical study. *Br J Ophthalmol*. 2015 Jan;99(1):59–63.
- 33 Bourcier T, Patteau F, Borderie V, Baudrimont M, Rondeau N, Bonnel S, et al. Intérêt de la greffe de membrane amniotique dans le traitement des kératites amibiennes sévères. *Can J Ophthalmol*. 2004 Oct;39(6):621–31.
- 34 Hassanlou M, Bhargava A, Hodge WG. Bilateral acanthamoeba keratitis and treatment strategy based on lesion depth. *Can J Ophthalmol*. 2006 Feb;41(1):71–3.
- 35 Kitzmann AS, Goins KM, Sutphin JE, Wagoner MD. Keratoplasty for treatment of Acanthamoeba keratitis. *Ophthalmology*. 2009 May;116(5):864–9.
- 36 Parthasarathy A, Tan DT. Deep lamellar keratoplasty for acanthamoeba keratitis. *Cornea*. 2007 Sep;26(8):1021–3.
- 37 Anshu A, Parthasarathy A, Mehta JS, Htoon HM, Tan DTH. Outcomes of therapeutic deep lamellar keratoplasty and penetrating keratoplasty for advanced infectious keratitis: a comparative study. *Ophthalmology*. 2009 Apr;116(4):615–23.
- 38 Lee YC, Kim SY. Treatment of neurotrophic keratopathy with nicergoline. *Cornea*. 2015 Mar;34(3):303–7.
- 39 Por YM, Mehta JS, Chua JLL, Koh TH, Khor WB, Fong ACY, et al. Acanthamoeba keratitis associated with contact lens wear in Singapore. *Am J Ophthalmol*. 2009 Jul;148(1):7–12.e2.
- 40 Sarnicola E, Sarnicola C, Sabatino F, Tosi GM, Perri P, Sarnicola V. Early deep anterior lamellar keratoplasty (DALK) for acanthamoeba keratitis poorly responsive to medical treatment. *Cornea*. 2016 Jan;35(1):1–5.
- 41 Bagga B, Garg P, Joseph J, Mohamed A, Kalra P. Outcome of therapeutic deep anterior lamellar keratoplasty in advanced Acanthamoeba keratitis. *Indian J Ophthalmol*. 2020 Mar;68(3):442–6.
- 42 Wang H, Jhanji V, Ye C, Ren Y, Zheng Q, Li J, et al. Elliptical deep anterior lamellar keratoplasty in severe Acanthamoeba keratitis. *Indian J Ophthalmol*. 2023 Mar;71(3):999–1004.
- 43 Varacalli G, Di Zazzo A, Mori T, Dohlman TH, Spelta S, Coassin M, et al. Challenges in acanthamoeba keratitis: a review. *J Clin Med*. 2021 Mar;10(5):942.