

## Two-stage Prepectoral Breast Reconstruction with Expander and Acellular Dermal Matrix: Why and When

Alessio Baccarani, MD, FACS; Claudio Gio Francesco Blessent, MD; Caterina Marra, MD; Federico De Maria, MD; Marco Pappalardo, MD; Giorgio De Santis, MD

**B**reast cancer is the most common malignancy developing in women with increasing trend. According to the 2022 GLOBOCAN statistics, more than 2 million women worldwide have been diagnosed with breast cancer, with an age-standardized incidence of 46.8 per 100,000.<sup>1</sup> The widespread diffusion of breast screening allows for an early disease diagnosis, thus increasing the overall survival rate.<sup>2</sup>

Today, breast reconstruction is considered a crucial part of breast cancer therapy because of the physical and psychological impact that mastectomy has on the patient's quality of life. More than 150,000 breast reconstructions were estimated in the United States in 2022.<sup>3</sup>

In this scenario, direct-to-implant prepectoral reconstruction is becoming increasingly widespread for several reasons, including (1) single operation simplicity; (2) preservation of pectoralis major muscle with consequent less postoperative pain and faster recovery; and (3) quality of results that, according to some authors, show no animation deformities.<sup>4</sup>

Despite several techniques being proposed to sustain the prepectoral implant, such as prosthetic mesh, tabbed expanders, and others,<sup>5</sup> the use of acellular dermal matrix (ADM) represents a significant adjunct because of its capability of integration. This allowed for increase in the stability and thickness of the skin flaps and, possibly, reduction of the incidence of capsular contracture. Furthermore, an ADM-enhanced skin flap may represent an adequate setting for lipofilling.

This technique, however, suffers some drawbacks because of the relatively high incidence of complications, including skin necrosis, wound dehiscence, seroma, and infection, determining the need for implant removal and consequent reconstruction failure.<sup>6</sup> For these reasons, very strict patient selection should be performed, with eventual commitment taken only at the operatory table.

Mastectomy skin flap should be vital, thick enough, well perfused, and not congested, to allow for optimal mesh integration. To assess the perfusion status of the mastectomy skin flap, fluorescence angiography with indocyanine green is routinely used intraoperatively by many groups, including ours.

The two-stage prepectoral technique with expander was devised to possibly extend the indications for a prepectoral reconstruction. In most instances, green indocyanine fluorescence angiography reveals a suboptimal perfusion of mastectomy flaps, which we consider a contraindication for a direct prepectoral reconstruction (Fig. 1). In such circumstances, a two-staged prepectoral reconstruction with expander and ADM is our indication (Fig. 2).

We have devised a clinical decision-making algorithm by which, only for intermediate mastectomy skin flap thickness (4–10 mm), indocyanine fluorescence analysis of perfusion is performed. If the indocyanine green test reveals an intermediate perfusion, a two-stage prepectoral reconstruction with tissue expander and ADM is our commitment (Fig. 3).

By this approach, a better management of complications is definitely possible: the expander may be partially deflated to support wound healing if skin sufferance occurs, and even in the case of focal skin necrosis requiring debridement, primary closure may be obtained without losing the implant.

Additionally, we strongly feel that performing the final implant-based reconstruction on stabilized tissues greatly enhances the quality of our aesthetic results in terms of symmetry. Of course, this approach is quite expensive because an expander, an ADM, and a prosthesis are used for a single reconstruction, in addition to at least two surgical steps.

Finally, this report builds on other groups' experience<sup>5</sup> using clinical intraoperative examination only before committing for a prepectoral, versus a subpectoral, implant placement. Further studies are necessary to compare complication rates, reconstructive quality, and costs.

*From the Department of Plastic and Reconstructive Surgery, Azienda Ospedaliero-Universitaria di Modena, Università di Modena e Reggio Emilia, Modena, Italy.*

*Received for publication August 30, 2023; accepted March 4, 2024.*

*Copyright © 2024 The Authors. Published by Wolters Kluwer Health, Inc. on behalf of The American Society of Plastic Surgeons. This is an open-access article distributed under the terms of the Creative Commons Attribution-Non Commercial-No Derivatives License 4.0 (CCBY-NC-ND), where it is permissible to download and share the work provided it is properly cited. The work cannot be changed in any way or used commercially without permission from the journal.*

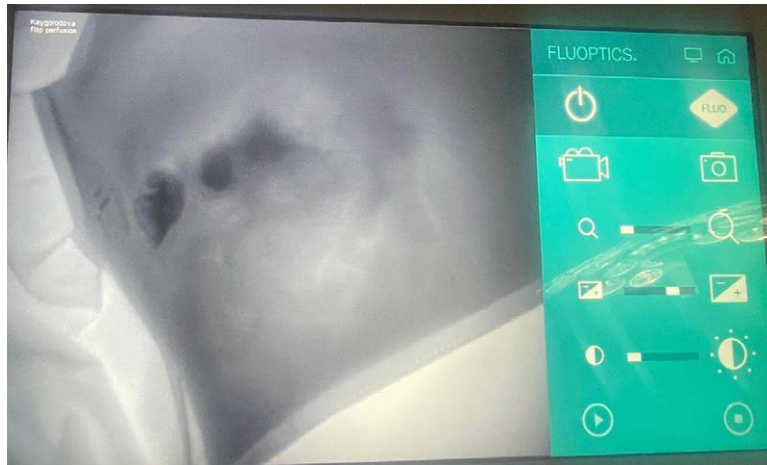
*Plast Reconstr Surg Glob Open 2024; 12:e5774; doi: 10.1097/GOX.0000000000005774; Published online 29 April 2024.*

**Caterina Marra, MD**

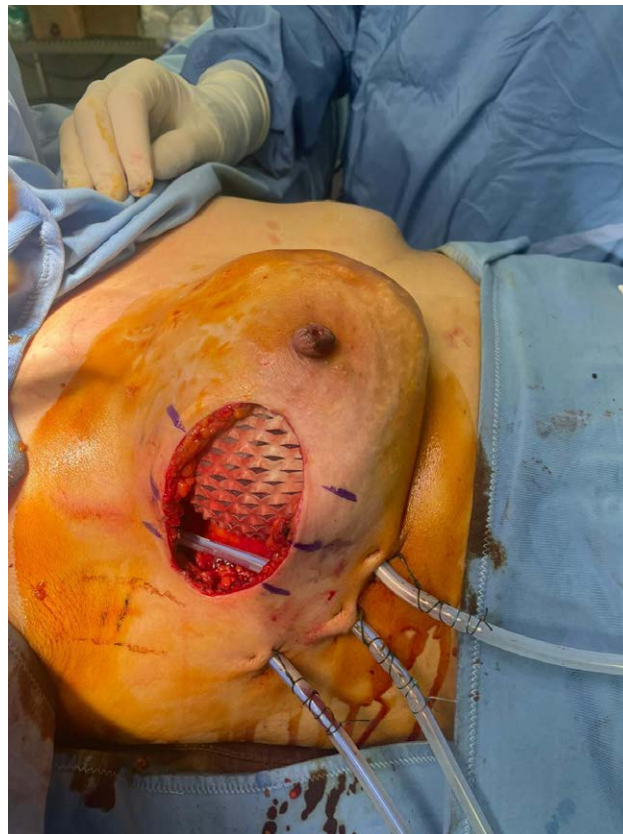
Department of Plastic and Reconstructive Surgery  
Azienda Ospedaliero-Universitaria di Modena  
Università di Modena e Reggio Emilia  
Via del Pozzo 71  
Modena, Italy  
E-mail: caterinamarra92@gmail.com

### DISCLOSURE

*The authors have no financial interest to declare in relation to the content of this article.*



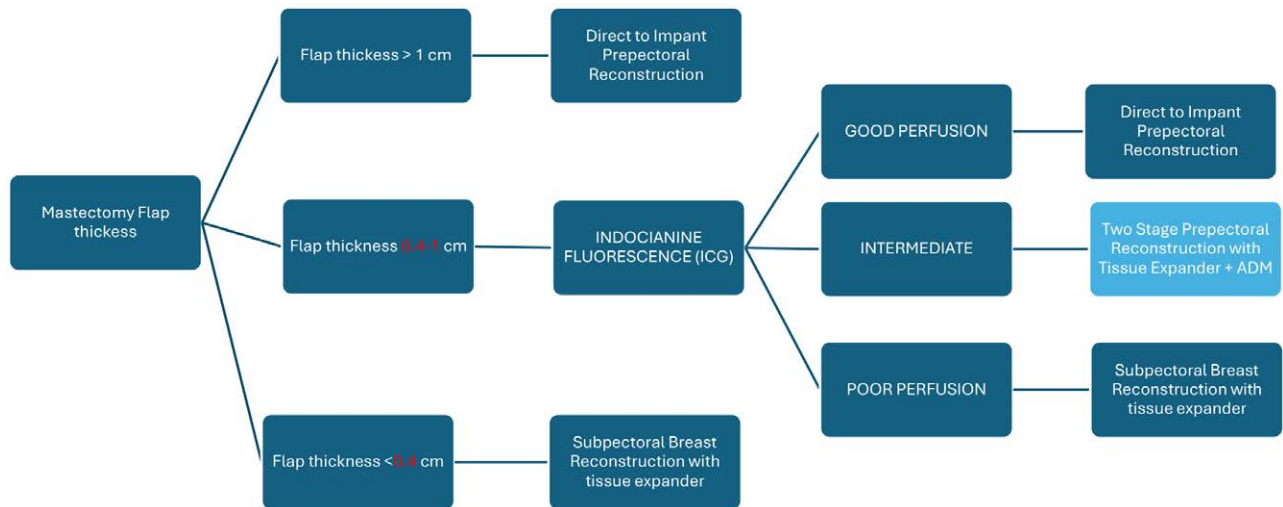
**Fig. 1.** Green indocyanine fluorescence angiography reveals a suboptimal perfusion of the dye into the mastectomy skin flaps.



**Fig. 2.** Intraoperative positioning into the subcutaneous pocket of the expander wrapped by the ADM.

### REFERENCES

1. Ferlay J, Ervik M, Lam F, et al. Global Cancer Observatory: Cancer Today. Lyon, France: International Agency for Research on Cancer; 2024. Available from: <https://gco.iarc.who.int/media/globocan/factsheets/cancers/20-breast-fact-sheet.pdf>. Accessed April 6, 2024.
2. Gutnik L, Fayanju OM. Controversies in breast cancer surgery. *Surg Clin North Am.* 2021;101:1033–1044.
3. American Society of Plastic Surgeons. 2022 ASPS Procedural Statistics Release. <https://www.plasticsurgery.org/documents/News/Statistics/2022/plastic-surgery-statistics-report-2022.pdf>. Accessed April 6, 2024.
4. Cattelani L, Polotto S, Arcuri MF, et al. One-step prepectoral breast reconstruction with dermal matrix-covered implant compared to submuscular implantation: functional and cost evaluation. *Clin Breast Cancer.* 2018;18:e703–e711.



**Fig. 3.** Clinical decision-making algorithm for two-stage prepectoral reconstruction with tissue expander and ADM.

5. Salibian AA, Bekisz JM, Kussie HC, et al. Do we need support in prepectoral breast reconstruction? Comparing outcomes with and without ADM. *Plast Reconstr Surg Glob Open.* 2021;9:e3745.
6. Antony AK, Robinson EC. An algorithmic approach to prepectoral direct-to-implant breast reconstruction: version 2.0. *Plast Reconstr Surg.* 2019;143:1311–1319.