

Autologous Mandible Reconstruction in a Hypercoagulable Patient following Multiple Failed Free Flaps

Mark A. Maier, BS*
Richard F. Guidry, MD†
Patrick A. Palines, MD†
Mark W. Stalder, MD‡

Summary: Coagulopathies affect 3% of free flap patients and are among the leading causes of free flap failure. This report describes the case of a head and neck cancer patient that experienced two remote free flap failures before successful autologous mandibular reconstruction. Following identification of an unrecognized thrombophilic state, a focused anticoagulation strategy was executed, including an intraoperative heparin drip, stringent postoperative maintenance of Factor Xa levels between 0.3 and 0.5 IU per mL, and transition to an outpatient enoxaparin regimen of 1 mg per kg twice daily for 1.5 months following surgery. Here, we demonstrate that free tissue transfer following multiple previous failed attempts in the setting of hypercoagulability remains a viable reconstructive option with close interdisciplinary collaboration, close clinical monitoring, and patient-specific anti-thrombotic protocols. (*Plast Reconstr Surg Glob Open* 2022;10:e3872; doi: 10.1097/GOX.0000000000003872; Published online 21 January 2022.)

Free flap failure in head and neck surgery has become a relatively infrequent occurrence over the last two decades, with reported incidences as low as 1.3% in high-volume practices.¹ With ever-improving microsurgical technical expertise, intrinsic patient factors such as coagulopathies represent an increasingly greater proportion of flap failure etiology. Unfortunately, the first indication of a hypercoagulable state is often vascular thrombosis following a free tissue transfer.² Coagulopathies are reported to affect roughly 3% of all free flap recipients, and those that experience primary flap failure have a lower chance of future flap success.³ Wang et al demonstrated that even with anticoagulation measures in place, thrombophilic patients experience a perioperative thrombosis rate of up to 20.7% and total flap failure rate of up to 15.5%.³

Nevertheless, free tissue transfer is often required for adequate anatomic reconstruction of large composite defects.⁴ Hostile wound beds compromised by multiple previous procedures, radiation, and infection may consequently

lack subsequent local and regional reconstructive options.⁴ Recent reports have suggested that the risk of flap failure in patients predisposed to thrombophilia can be mitigated by a comprehensive hematologic workup, close collaboration with a hematologist, and a suitable patient-specific anticoagulation strategy.^{3,5} We present the case of a patient who experienced two failed free flaps before identification of an intrinsic coagulopathy, followed by a successful double free flap transfer after a hematology consult.

CASE

A 53-year-old man presented to our clinic with a history of previous T4aN0M0 squamous cell carcinoma of the floor of mouth. The patient had previously undergone a remote ablative procedure of the floor of mouth and anterior segment of the mandible with multiple reconstructive procedures by a different plastic surgery team. His initial clinical course was complicated by two consecutive failed free fibula flaps: the first due to venous thrombosis and hematoma, while the second failed due to intraoperative arterial thrombosis. Successful reconstruction was subsequently achieved with a pedicled pectoral flap and a titanium reconstruction plate, which was followed by radiation. Physical examination at his subsequent presentation demonstrated threatened hardware exposure through the native skin of his mental protuberance (Fig. 1).

Following our examination, a hematology consult and full hypercoagulability workup uncovered the presence of antiphospholipid syndrome. The patient required an

From the *School of Medicine, Louisiana State University Health Sciences Center, New Orleans, La.; †Division of Plastic and Reconstructive Surgery, Department of Surgery, Louisiana State University Health Sciences Center, New Orleans, La.; and ‡University Medical Center – LCMC Health New Orleans, La.

Received for publication July 10, 2021; accepted August 31, 2021.

Copyright © 2022 The Authors. Published by Wolters Kluwer Health, Inc. on behalf of The American Society of Plastic Surgeons. This is an open-access article distributed under the terms of the Creative Commons Attribution-Non Commercial-No Derivatives License 4.0 (CCBY-NC-ND), where it is permissible to download and share the work provided it is properly cited. The work cannot be changed in any way or used commercially without permission from the journal.

DOI: 10.1097/GOX.0000000000003872

Disclosure: The authors have no financial interest to declare in relation to the content of this article. The study received no funding.

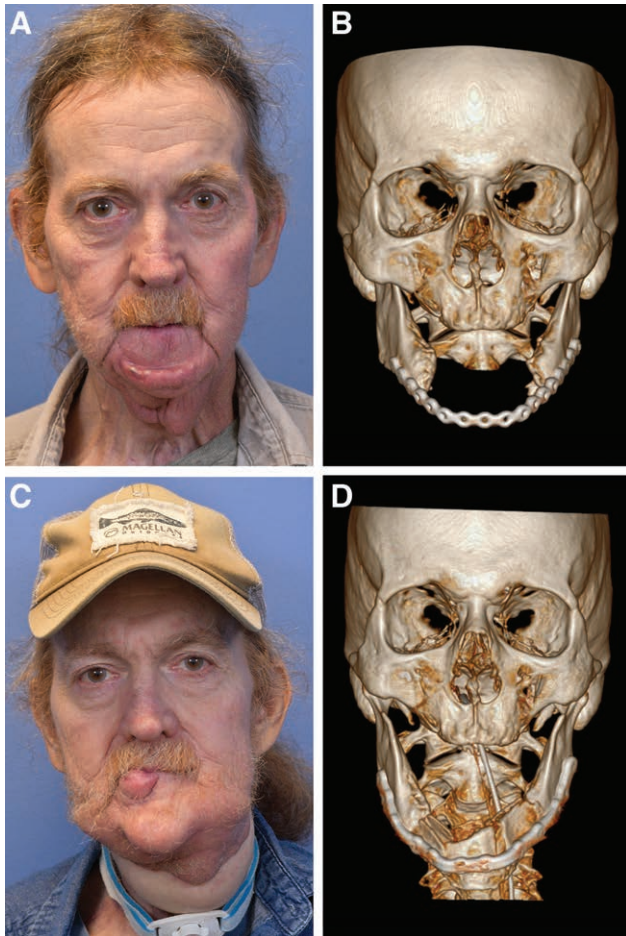


Fig. 1. Preoperative and postoperative imaging of autologous mandibular reconstruction in a hypercoagulable patient. A, Preoperative photograph demonstrating impending hardware extrusion. B, Preoperative computed tomography demonstrating anterior segmental defect of the mandible. C, Postoperative photograph showing successful free flap reconstruction before debulking and revision of external anterolateral thigh flap, and release of lower lip tethering. D, Postoperative computed tomography showing three-segment iliac crest bone flap in place following reconstruction of the anterior segment of the mandible.

autologous solution for the impending failure of his previous reconstruction, but in the setting of a hypercoagulable state and an irradiated, vessel-depleted neck. Virtual surgical planning was used to design osteotomy guides for a three-segment deep circumflex iliac artery free flap for bony reconstruction of the anterior segment of the mandible, with a segment of internal oblique muscle for intra-oral coverage. An anterior lateral thigh fasciocutaneous flap was used to provide additional soft tissue to assist in tension-free closure of the irradiated neck. The flap was used in a flow-through configuration from the left facial vessels due to a paucity of available recipient vasculature. Due to the need for additional pedicle length to reach the recipient vessels, a composite arterial/venous graft was harvested from the deep inferior epigastric system. The subsequent microsurgical construct proceeded as follows: left facial artery/vein → composite deep inferior

epigastric artery/vein arterial/venous graft → ALT free flap → deep circumflex iliac artery free flap. Per hematology recommendations, an unfractionated heparin drip was started at 12 units per kg per hour prior to division of the flap vasculature as prophylaxis for anastomotic thrombosis. There were no intraoperative complications.

Initially, postoperative heparin drip with anti-Xa was used to maintain factor Xa levels between 0.3 and 0.5 IU per mL (monitored every 6 hours), followed by an outpatient regimen of 1 mg per kg enoxaparin twice daily. The patient required two returns to the operating room: one for a right neck hematoma and revision of the arterial anastomosis on postoperative day 4 and another for evacuation of a left thigh hematoma and revision of a right orocutaneous fistula on postoperative day 23. Following these early postoperative issues, the patient's recovery was uncomplicated. Outpatient anticoagulation was stopped on postoperative day 44, and he underwent a successful flap debulking 3 months later.

DISCUSSION

Free flap reconstruction of postablative defects of the head and neck are inherently difficult procedures, the complexity of which can be compounded by radiation changes, previously operated fields, and potentially unidentified patient-related conditions.⁴ In cases of free flap failure, delineating the etiology requires close consideration of patient-related factors because technical issues have become far less common with improvements in microsurgical training and efficiency, and surgeons should consider acquiring a complete hematological history and workup in these cases when technical issues are not apparent.^{6,7} Before reoperation in these patients, screening should include lupus anticoagulant, protein S deficiency, activated protein C resistance (factor V Leiden), anti-thrombin III deficiency, sickle cell disease, and elevated factor VIII.⁸

If a hypercoagulable state is diagnosed, close collaboration with a hematologist should be pursued to mitigate future complications in patients that still require free tissue transfer.⁹ Prophylactic anticoagulation regimens primarily incorporate intra- and postoperative use of sequential compression devices, heparin (bolus, infusion, and subcutaneous), enoxaparin, and warfarin. Our standard protocol includes sequential compression devices and 40 mg of subcutaneous enoxaparin daily. Some groups have developed protocols specific for secondary free flaps in hypercoagulable patients.^{5,9,10} For example, Pannucci et al recommend starting with a low-dose heparin infusion at 800 U per hour, with a bolus of 3000 U of intravenous heparin before clamping vessels, and continuing a therapeutic dose at a partial thromboplastin time of 50–70 seconds until anastomotic completion. Their postoperative therapeutic anticoagulation is continued using 1.5 mg per kg per day or 1.0 mg per kg twice daily of enoxaparin for 4 weeks total.¹⁰ Overall, identification of the hypercoagulable state is of utmost importance so that the appropriate antithrombotic intervention may be undertaken to facilitate a successful transfer.

Although there are reports of secondary free flap success after antithrombotic approaches are employed,

we found no cases in the literature discussing success with simultaneous free flaps following multiple prior flap failures in the setting of hypercoagulability.^{5,8} This report reinforces that close collaboration with a hematologist, clinical monitoring, and a carefully considered antithrombotic protocol can lead to successful outcomes when free tissue transfer is indicated in these challenging cases.

CONCLUSIONS

Hypercoagulopathies are among the leading causes of free flap failure. Subsequent reoperation following multiple flap failures due to thrombosis may be considered in certain cases in conjunction with a complete hypercoagulability workup and hematology consultation.

Mark W. Stalder, MD

Division of Plastic and Reconstructive Surgery
Louisiana State University Health Sciences Center
School of Medicine
1542 Tulane Ave, Room 734
New Orleans, LA 70112
E-mail: mstald@lsuhsc.edu

REFERENCES

1. Corbitt C, Skoracki RJ, Yu P, et al. Free flap failure in head and neck reconstruction. *Head Neck*. 2014;36:1440–1445.
2. Davison SP, Kessler CM, Al-Attar A. Microvascular free flap failure caused by unrecognized hypercoagulability. *Plast Reconstr Surg*. 2009;124:490–495.
3. Wang TY, Serletti JM, Cuker A, et al. Free tissue transfer in the hypercoagulable patient: a review of 58 flaps. *Plast Reconstr Surg*. 2012;129:443–453.
4. Chang EI, Zhang H, Liu J, et al. Analysis of risk factors for flap loss and salvage in free flap head and neck reconstruction. *Head Neck*. 2016;38 suppl 1:E771–E775.
5. Barton BM, Riley CA, Fitzpatrick JC, et al. Postoperative anticoagulation after free flap reconstruction for head and neck cancer: a systematic review. *Laryngoscope*. 2018;128:412–421.
6. Froemel D, Fitzsimons SJ, Frank J, et al. A review of thrombosis and antithrombotic therapy in microvascular surgery. *Eur Surg Res*. 2013;50:32–43.
7. Friedman T, O'Brien Coon D, Michaels VJ, et al. Hereditary coagulopathies: practical diagnosis and management for the plastic surgeon. *Plast Reconstr Surg*. 2010;125:1544–1552.
8. Baumeister S, Follmar KE, Zenn MR, et al. Strategy for reoperative free flaps after failure of a first flap. *Plast Reconstr Surg*. 2008;122:962–971.
9. Zavlin D, Chegireddy V, Jubbal KT, et al. Management of microsurgical patients using intraoperative unfractionated heparin and thromboelastography. *J Reconstr Microsurg*. 2019;35:198–208.
10. Pannucci CJ, Kovach SJ, Cuker A. Microsurgery and the hypercoagulable state: a hematologist's perspective. *Plast Reconstr Surg*. 2015;136:545e–552e.