

Neurovascular complications related to nerve stimulator-guided lumbosacral plexus block for proximal femur nailing in geriatric patients—A retrospective study

INTRODUCTION

Closed reduction and internal fixation (CRIF) with proximal femur nail (PFN) performed under lumbosacral plexus block (LSPB) as a sole anaesthetic technique has proved feasible. It is relatively safe in terms of maintaining stable haemodynamics and avoiding a general anaesthetic. We conducted this retrospective study to record the neurovascular complications related to nerve stimulator (NS)-guided LSPB in geriatric patients who underwent PFN.

METHODS

For this retrospective study, institutional ethics committee approval (IEC-SIOR/060) was obtained, and the study was conducted in accordance with the principles of the declaration of Helsinki. Medical records of patients aged above 70 years, who underwent CRIF with PFN under NS-guided LSPB as a sole anaesthetic technique at a tertiary care teaching hospital, were reviewed. The cases where block could not be performed or recorded neuropathy due to other reasons were excluded. The primary objective was to identify the incidence of peripheral nerve injury (PNI) from NS-guided LSPB for PFN surgery in geriatric patients. The secondary objectives included severity and recovery from PNI, incidence of vascular and other complications. The records were reviewed for mention of postoperative neurological events from 24th hour until the patient was discharged from the hospital, vascular punctures during the block or haematoma post block, epidural spread and conversion to a general anaesthetic. The patient's physical characteristics, block procedural data, local anaesthetic (LA) volume used, block outcomes, complications and postoperative outcomes were recorded. Once the block was established, surgery proceeded in the same lateral decubitus position without a fracture table. Following surgery, the patients were monitored for neurological recovery. The postoperative surgeon's and physiotherapist's

notes were also reviewed. If neurological weakness persisted after 24 hours of surgery, a neurological evaluation and neurology consultation was obtained as per the institute's protocol.

The records satisfying inclusion and exclusion, between January 2015 and July 2020, were reviewed manually. Records detailing any complication were segregated and further scrutinised. For each complication, the incidence was presented using point estimates and 95% confidence interval (CI), with number of complications as the numerator and total records reviewed as the denominator.

RESULTS

A total of 1920 PFN procedures had taken place over the study period of which the records of 146 patients had satisfied the inclusion and exclusion criteria. This included 92 males and 54 females, with a median (25th–75th percentile) age of 85 (76–94) years [Table 1]. All blocks were performed by a single anaesthesiologist with an experience of more than 25 years in regional anaesthesia. The block technique was as described by Diwan *et al.*^[1] All patients were in the lateral decubitus position, and a 21 gauge/100 mm (Pajunk®, Germany) NS needle was used to perform both the blocks separately. A standard quadriceps response for lumbar plexus (LP) and either dorsi or plantar flexion of the foot for sacral plexus (SP) was evoked at a current between 0.4 and 0.2 milliamperes. After a negative test dose (5 ml of 1% lignocaine), 20–22 ml of 0.5% bupivacaine with 30 µg of clonidine and 10–12 ml of 0.5% bupivacaine were injected using compressed air injection technique^[2] at LP and SP, respectively. The records of 24 patients (16.4%) included recorded complications related to the LSPB block. None of the records showed more than one complication occurring in the same patient. Procedural data of lumbar block revealed three reports of vascular puncture (2%; 95% CI, 0–4%) and one case with a psoas haematoma following LP block (0.6%; 95% CI,

Table 1: Demographic data

Parameter	Value
Age (median with 25 th to 75 th percentile)	85 (76–94) years
Gender (male/female) (n)	92/54
Weight (mean±standard deviation)	62.7±4.5 kg
Duration of surgery (mean±standard deviation)	37±14 minutes
Type of fracture: subtrochanteric/intertrochanteric (n)	67/82
Comorbid conditions (n)	24/15/8*

*Diabetes mellitus/spine instrumentation/spinal stenosis. n: number of cases

0-2%), detected by ultrasound done for examination of quadriceps weakness in the postoperative period. In 11 patients, the intraoperative notes revealed a weak knee flexion on the non-operative side, indicating probable epidural spread (7.5%; 95% CI, 3.2-11%); nevertheless, none of the patients required a general anaesthetic for the completion of surgery. In five patients, hypotension (blood pressure drop more than 20% from baseline) was noted, and all these happened to be the patients with epidural spread. Hypotension was managed with fluids.

There were nine patients with PNI (6.2%; 95% CI, 2-10%) with five cases (56%) having quadriceps weakening and four (44%) cases with footdrop. Nerve conduction studies revealed axonal injuries in the femoral nerve (femoral neuropathy) in the five patients with quadriceps weakness and sciatic nerve (sciatic neuropathy) in the four patients with footdrop [Figure 1]. Of the nine cases, five had type II diabetes, three of them had spinal canal stenosis, and one case had a prior spine instrumentation surgery at the lumbar region; however, none of these cases had any overt neurological systems. Following neurologist consultation, all these patients were enrolled in the institution's comprehensive rehabilitation programme and received oral serotonin norepinephrine reuptake inhibitors. Out of five patients with femoral neuropathy, two patients recovered with 90–95% quadriceps muscle strength by the third month, while three patients recovered by the sixth month. In the four patients with sciatic neuropathy, three of them had 90–95% recovery from foot drop between the 7th and 8th month; however, in one patient, only a partial recovery[50%] was evident by one year.

DISCUSSION

Regional techniques provide distinct advantages over general anaesthesia,^[3] and peripheral nerve blocks can avoid hypotension caused by central

neuraxial blockade, which geriatric patients with hip fractures may be prone to.^[4] In this single-centre cohort of 146 elderly patients who underwent PFN with a single bolus NS-guided LSPB, we observed a 6.2% [9/146 patients] incidence of neuropathies. Inadvertent intravascular placement of the needle tip was detected in five patients, and post block psoas haematoma was detected in one patient.

Three factors contribute towards a PNI in orthopaedic surgeries, namely surgical, patient or block related. The surgical technique of PFN does not affect the LP and SP components unlike the total hip replacement. The surgeries were not performed on a fracture table, and the limb traction was applied by an assistant orthopaedic surgeon, so perineal post and traction-related injuries could have played a minor role. Elderly patients with multiple comorbid conditions may have an underlying component of neuropathy. Subclinical neuropathy affects 50% of diabetics,^[5] and nutritional deficiencies are common in the geriatric cohort [15-40%], leading to sensory-motor dysfunction.^[6] A plausible explanation for PNI could be the double-crush phenomenon, which states that when an insult occurs to a damaged nerve, the consequential neuropathy may be more severe and out of proportion to the insult.^[7] It is interesting to note that all the patients with reported PNI in this cohort had a pre-existing comorbid condition with the risk of neuropathy. Five out of 24 diabetics (20.1%), 1 of 15 (6.7%) patients with spine instrumentation and 3/8 (37.5%) patients with spinal canal stenosis had PNI. Nonetheless, larger, prospective studies are required to correlate the interaction between block related PNI and comorbid conditions. Pre-operative exclusion of a subclinical or clinical neuropathy may not be always possible in patients presenting with fractures. However, since the technique involves two separate plexuses which are technically difficult to access, it becomes imperative to exclude a pre-existing neuropathy related to a prior metabolic or neurological disorder as much as possible.

With NS-guided blocks, the stimulating current does not always exclude an intraneural needle placement, and the PNI is known to increase in difficult anatomy.^[8,9] Despite a meticulous injection technique performed by an experienced anaesthesiologist, the incidence of PNI was high. A needle-nerve contact leading to paraesthesia-related inflammation and local anaesthetic-related neurotoxicity can also attribute to PNI.^[9] Our observations reveal a higher incidence of PNI compared to literature, possibly due

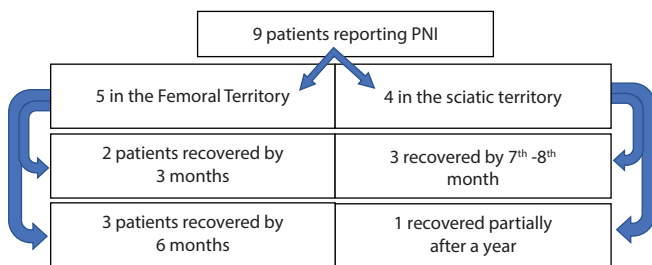


Figure 1: Flowchart of the patients with PNI. PNI: Peripheral nerve injury

to the small cohort of a primarily geriatric population. Additionally, these studies mention the incidence of complication in landmark-based technique with no mention of needle–nerve contact for the LP block.^[10] Our observations suggest that geriatric patients may pose a higher risk for PNI; however, larger prospective studies are required to investigate this association.

The vascular structures are in close proximity to the target nerves,^[1] and even though vascular injury is reportedly rare in this block, it is not impossible and when undetected can be devastating, considering the difficulty in applying external compression.^[10] Though vascular punctures were identified in 5/146 patients (four in lumbar and one in sacral), the needle tip was withdrawn and redirected to obtain neurostimulation followed by a successful block with no further consequences. The geriatric population requiring prophylactic anticoagulant therapy to prevent deep vein thrombosis would require meticulous needle placement in the lumbar paravertebral area with continued vigilance during LSPB. This would enable the early detection of complications.^[11] Application of dual modality, ultrasonography and neurostimulation, may improve the safety profile of the LSPB by avoiding multiple re-directions. However, one must be aware that in patients more than 65 years of age, the topographical change in the lumbar paravertebral area may complicate the visualisation of neural targets.^[12]

The major limitations of this study are that it includes retrospective data of a small cohort from a single centre. The strengths include observation with a similar surgical stimulus in all patients and aggressive follow-up protocols by the entire perioperative team to detect the complications.

CONCLUSION

This study revealed a high incidence of PNI (6.2%) with landmark-based neurostimulation-guided LSPB in geriatric patients with multiple comorbidities. Recovery from the PNI took place within 6 months to a year with physiotherapy. The incidence of vascular complications was less (0.6%) with this technique.

Financial support and sponsorship

Nil.

Conflicts of interest

There are no conflicts of interest.

Sandeep Diwan, Archana Areti¹, Sivashanmugam T¹, Parag Sancheti²

Departments of Anaesthesiology and ²Orthopaedic Surgery, Sancheti Hospital for Orthopaedics and Rehabilitation, Pune, Maharashtra, ¹Department of Anaesthesiology, Mahatma Gandhi and Research Institute, Sri Balaji Vidyapeeth Deemed to be University, Puducherry, India

Address for correspondence:

Dr. Archana Areti,
Department of Anaesthesiology, Mahatma Gandhi and Research Institute, Sri Balaji Vidyapeeth Deemed to be University, Pillaiyarkuppam, Puducherry - 607402, India.
E-mail: archanaareti@gmail.com

Submitted: 26-May-2022

Revised: 31-Oct-2022

Accepted: 02-Nov-2022


Published: 18-Nov-2022

REFERENCES

1. Diwan S, Chetan P, Atul P, Chetan P, Parag S. Combined lumbar and sacral plexus block in geriatric high-risk patients undergoing an awake repair of fracture intertrochanteric of femur. *Journal of Anaesthesia and Critical Care Case Reports* 2018;4:21-30.
2. Tsui BCH. Compressed air injection technique for Shamrock lumbar plexus block. *Eur J Anaesthesiol* 2017;34:629-31.
3. Mehdiratta L, Bajwa SS, Malhotra N, Joshi M. Exploring cocktails, remixes and innovations in regional nerve blocks: The clinical research journey continues. *Indian J Anaesth* 2020;64:1003-6.
4. Alghanem S, Massad I, Almustafa M, Al-Shwiat L, El-Masri M, Samarah O, et al. Relationship between intra-operative hypotension and post-operative complications in traumatic hip surgery. *Indian J Anaesth* 2020;64:18-23.
5. Hicks CW, Selvin E. Epidemiology of peripheral neuropathy and lower extremity disease in diabetes. *Curr Diab Rep* 2019;19:86.
6. Leishear K, Boudreau RM, Studenski SA, Ferrucci L, Rosano C, Rekeneire N, et al. Relationship between vitamin B12 and sensory and motor peripheral nerve function in older adults. *J Am Geriatr Soc* 2012;60:1057-63.
7. Kane PM, Daniels AH, Akelman E. Double crush syndrome. *J Am Acad Orthop Surg* 2015;23:558-62.
8. Sala Blanch X, López AM, Carazo J, Hadzic A, Carrera A, Pomés J, et al. Intraneural injection during nerve stimulator-guided sciatic nerve block at the popliteal fossa. *Br J Anaesth* 2009;102:855-61.
9. Jeng CL, Torrillo TM, Rosenblatt MA. Complications of peripheral nerve blocks. *Br J Anaesth* 2010;105:i97-107.
10. Njathi CW, Johnson RL, Laughlin RS, Schroeder DR, Jacob AK,

- Kopp SL. Complications after continuous posterior lumbar plexus blockade for total hip arthroplasty: A retrospective cohort study. *Reg Anesth Pain Med* 2017;42:446-50.
11. Weller RS, Gerancher JC, Crews JC, Wade KL. Extensive retroperitoneal hematoma without neurologic deficit in two patients who underwent lumbar plexus block and were later anticoagulated. *Anesthesiology* 2003;98:581-5.
 12. Diwan S, Nair A, Dadke M, Sancheti P. Intricacies of ultrasound-guided lumbar plexus block in octogenarians: A retrospective case series. *J Med Ultrasound* 2022;30:26-9.

This is an open access journal, and articles are distributed under the terms of the Creative Commons Attribution-NonCommercial-ShareAlike 4.0 License, which allows others to remix, tweak, and build upon the work non-commercially, as long as appropriate credit is given and the new creations are licensed under the identical terms.

Access this article online	
Quick response code	Website: www.ijaweb.org
	DOI: 10.4103/ija.ija_462_22

How to cite this article: Diwan S, Areti A, Sivashanmugam T, Sancheti P. Neurovascular complications related to nerve stimulator-guided lumbosacral plexus block for proximal femur nailing in geriatric patients-A retrospective study. *Indian J Anaesth* 2022;66:800-3.