

# Encephalopathy mimicking non-convulsive status Epilepticus

Ramachandiran Nandbagopal, DM, FRCP, Fathiya Al-Murshedi, MD, FRCPC, Mujabid Al-Busaidi, MD, FRCPC, Amna Al-Busaidi, MD.

## ABSTRACT

تتجلى اضطرابات دورة اليوريا (UCD) عادة مع عدم الاستجابة العرضية وهذا الكيان السريري لا يتم تضمينها في كثير من الأحيان في تفريق التشخيص لحالة الصرع غير التشنجية (NCSE). ومع ذلك، هذا الاعتبار التشخيصي له آثار علاجية. في هذا التقرير، نوثق الأهمية العلاجية لتوضيح السبب المحدد للاعتلال الدماغى لفَرْطُ أُمُونِيا الدَّم الذي يحاكي بشكل مشابه NCSE من خلال 2 حالات توضيحية فريدة من نوعها.

Primary hyperammonemic encephalopathy due to urea cycle disorders (UCD) typically manifests with episodic unresponsiveness and this clinical entity is not often included in the differential diagnosis of presumed non-convulsive status epilepticus (NCSE). However, this diagnostic consideration has therapeutic implications. In this report, we document the therapeutic importance of elucidating the specific cause of hyperammonemic encephalopathy that closely mimicked NCSE through 2 unique illustrative cases.

*Neurosciences 2018; Vol. 23 (1): 52-56  
doi: 10.17712/nsj.2018.1.20170214*

From the Neurology unit (Nandbagopal), Department of Medicine, Internal Medicine (Al-Busaidi), Genetic and Developmental Medicine Clinic (Al-Murshedi), College of Medicine and Health Sciences, Muscat, Oman and Oman Medical Specialty Board (Al-Busaidi A), Internal Medicine Residency Program, Oman.

Received 19th April 2017. Accepted 15th November 2017.

Address correspondence and reprint request to: Dr. Ramachandiran Nandbagopal, College of Medicine and Health Sciences, Sultan Qaboos University, Muscat, Oman. E-mail: rnandagopal@yahoo.com

Primary hyperammonemic encephalopathy due to urea cycle disorders (UCD) typically manifests with episodic unresponsiveness<sup>1,2</sup> and this clinical entity is not often included in the differential diagnosis of presumed non-convulsive status epilepticus (NCSE). However, this diagnostic consideration has

therapeutic implications.<sup>1</sup> In this report, we document the therapeutic importance of elucidating the specific cause of hyperammonemic encephalopathy that closely mimicked NCSE through 2 unique illustrative cases.

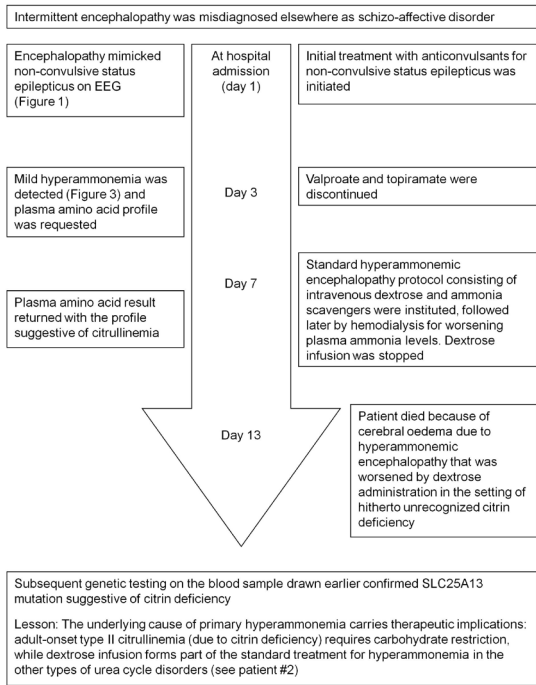
**Case Report. Patient 1.** A 30-year-old woman, who was hitherto diagnosed with schizo-affective disorder and catatonia elsewhere, presented to the Sultan Qaboos University hospital, Muscat, Oman (in the year 2014) with a 5-year-history of episodic unresponsiveness (akinetic mutism) lasting for several hours to a few days with postictal amnesia; there were no apparent triggers (she did not display any particular aversion or fondness for carbohydrate or protein diet) for these episodes that occurred approximately once every 2 months. She was initially admitted under the psychiatry service [of Sultan Qaboos University Hospital (Muscat, Oman)] with such a typical episode, when an EEG was obtained. Patient information and clinical findings are shown in Figure 1.

### *Diagnostic assessment and therapeutic interventions.*

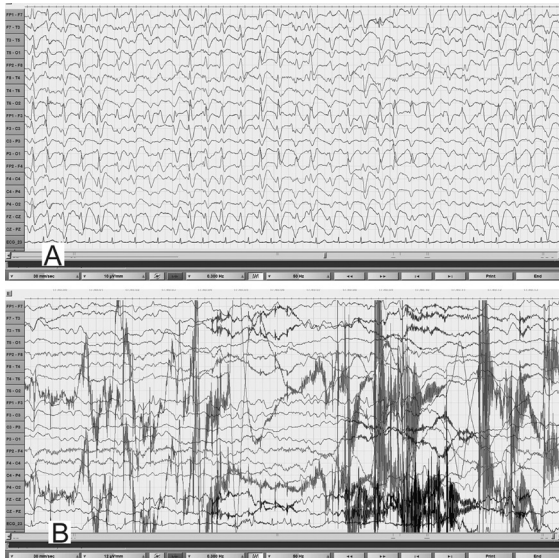
During the EEG recording (on day 3 of hospitalization), she was in coma with her eyes closed and there were continuous, generalized, 2.5 Hz sharp and slow wave discharges (Figure 2A) and she was transferred to the Neurology service. A diazepam (10 mg) trial resulted in the disappearance of the ictal sharp waves and she responded partially to painful stimuli by opening her eyes and localizing to pain (Figure 2B). There were no focal neurological deficits. In view of the continuous discharges at >2 Hz and the apparent clinical and EEG response to diazepam, a diagnosis of probable NCSE was made<sup>3</sup> and she was placed on intravenous sodium valproate 1500 mg/day. On the subsequent day, she was again unresponsive and continuous EEG recording showed similar findings as observed in Figure 2A.

**Disclosure.** The authors declare no conflicting interests, support or funding from any drug company.

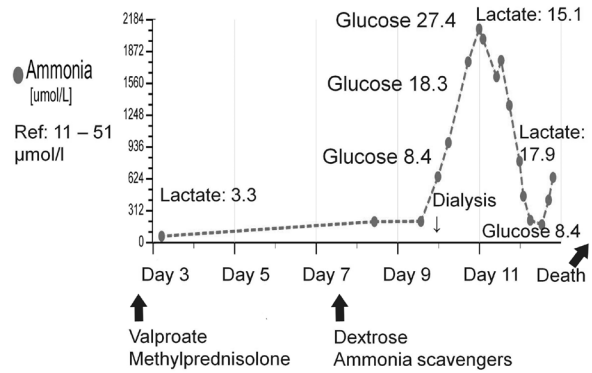
**Clinical Course: Timeline Picture**



**Figure 1** - Timeline picture of the clinical course of Patient #1 (a 30-year-old woman) with hyperammonemic encephalopathy mimicking non-convulsive status epilepticus

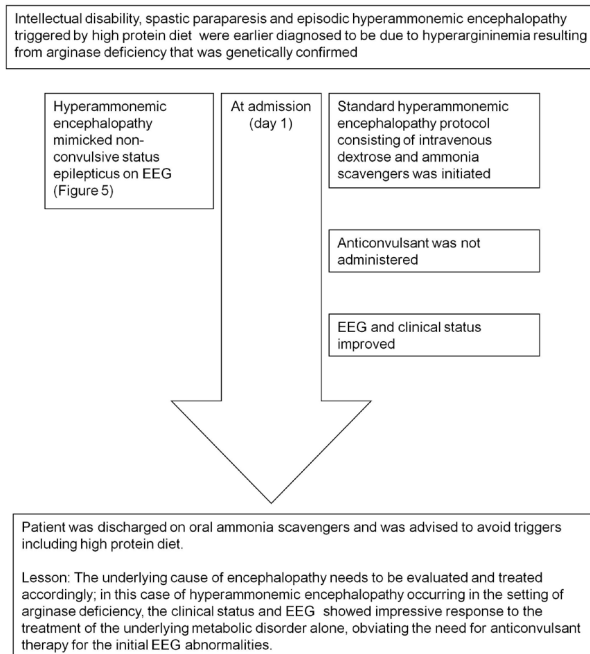


**Figure 2** - EEG obtained during an unresponsive episode (A) in a 30-year-old woman (Patient# 1) showed continuous, frontally dominant, generalized, 2.5 Hz sharp and wave discharges, with a triphasic morphology in some channels (e.g., Fz-Cz). Following intravenous administration of diazepam (B), there was complete resolution of this pattern, with the appearance of diffuse slowing in the theta range and movement artefacts (patient opened her eyes and withdrew her limbs to painful stimuli and then sat up in the bed and attempted to remove the electrodes) indicating arousal. (Low-frequency filter 0.3 Hz, high-frequency filter 50 Hz).



**Figure 3** - Marked worsening of hyperammonemia in relation to carbohydrate infusion that was provided as part of the standard treatment protocol for episodic hyperammonemic encephalopathy (mimicking non-convulsive status epilepticus) in a previously undiagnosed case (patient#1) of adult-onset citrullinemia. The plasma glucose and lactate values are in mmol/l.

However, from this moment onward, there had been no significant electro-clinical improvement with 10 mg of intravenous midazolam followed by the sequential addition of intravenous levetiracetam, phenytoin and oral topiramate in adequate doses (along with the pulse dose of methylprednisolone for presumed autoimmune encephalitis). Despite the intensive care treatment for presumed refractory NCSE, there was no appreciable clinical recovery. Her MRI brain, CSF study and autoimmune encephalitis antibody panel were unremarkable. Based on the finding of mild hyperammonemia (Figure 3) with a normal liver function test, valproate and topiramate were discontinued. While awaiting for the result of plasma amino acid profile, she was started on the standard protocol for hyperammonemic encephalopathy that consisted of 10% dextrose (with correction of extreme hyperglycemia) and intravenous sodium benzoate and sodium phenyl butyrate as ammonia scavengers. In view of the alarmingly rising hyperammonemia (Figures 1& 3), she was also started on hemodialysis that failed to provide any definite clinical benefits. Her CT brain showed diffuse cerebral edema and repeat EEG showed nearly iso-electrical recording. At this point of time, the previously submitted plasma amino acid profile returned the following results: citrulline: 199.33 µmol/l (reference range: <55 µmol/l), arginine: 112.86 (reference range: <108.00 µmol/l), Fischer ratio=1.4 (controls: ~3.4), threonine:serine=1.8 (controls:~1.1). She was ultimately diagnosed to have adult onset type II citrullinemia (OMIM #603471) that was further

**Clinical Course: Timeline Picture**

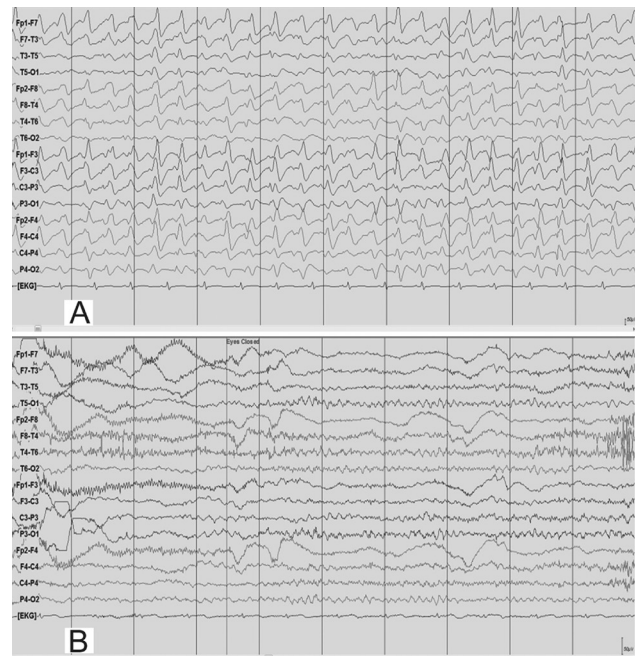
**Figure 4** - Timeline picture of the clinical course of Patient #2 (a 19-year-old man) with hyperammonemic encephalopathy mimicking non-convulsive status epilepticus

confirmed genetically by the detection of homozygous deletion encompassing exon 5 of SLC25A13 gene on chromosome 7q21.3 by quantitative polymerase chain reaction.

**Follow-up and outcome.** Although dextrose infusion was discontinued, she died of worsening encephalopathy and refractory cerebral edema 15 days after admission possibly in the context of prior carbohydrate induced biochemical deterioration in citrin deficiency (Figure 3). Consent for publication has been obtained from the patient's relative.

**Patient 2.** A 19-year-old man was evaluated in the Sultan Qaboos University hospital, Muscat, Oman (in the year 2014) for a 10-year-history of progressive intellectual decline, spastic paraparesis and episodic drowsiness (that was triggered by high protein diet). Patient information and clinical findings are shown in Figure 4 for the timeline picture of the clinical course of patient#2.

**Diagnostic assessment.** He was ultimately diagnosed to have arginase deficiency (OMIM #207800) based on the plasma amino acid profile that showed hyperargininemia (arginine: 406.85  $\mu\text{mol/l}$ ) and normal level of citrulline (39  $\mu\text{mol/l}$ ) during an episode



**Figure 5** - EEG obtained during an episode of hyperammonemic encephalopathy (A) with a plasma ammonia level of 105  $\mu\text{mol/l}$  in a 19-year-old man (patient# 2) with a known diagnosis of arginase deficiency showed continuous, frontally dominant, generalized, 2.5 Hz sharp and wave discharges, similar to Figure 1A. Twenty hours following the standard treatment protocol for hyperammonemia that included infusion of dextrose and ammonia scavenger (B), he was conscious and alert and the corresponding EEG normalized to a posterior dominant alpha background rhythm without any ictal discharges. (Low-frequency filter 1 Hz, high-frequency filter 70 Hz).

of mild hyperammonemia (ammonia: 73.43  $\mu\text{mol/l}$ ; reference range: 11-51  $\mu\text{mol/l}$ ). Molecular genetic testing revealed a homozygous substitution c.914G>T in exon 8 of ARG1 gene on chromosome 6q23.2 that resulted in the amino acid substitution p.Gly305Val. During an episode of drowsiness triggered by high protein diet, his plasma ammonia was 105  $\mu\text{mol/l}$  and EEG (Figure 5A) showed identical findings as in case#1. Patient information and clinical findings are shown in Figure 4 for the timeline picture of the clinical course of patient#2.

**Therapeutic intervention, follow-up and outcome.** As the patient was an already diagnosed case of hyperargininemia, he was maintained on the standard hyperammonemic encephalopathy protocol consisting of intravenous dextrose and ammonia scavengers that resulted in marked clinical recovery. Pari passu, his EEG normalized to an alpha rhythm without any epileptiform, periodic or abnormal rhythmic discharges (Figure 5B). Of note, he did not receive any anticonvulsant treatment during the episode;

subsequently he was continued on the oral formulation of ammonia scavengers and advised to avoid triggers such as high protein diet. The patient's relative provided consent for publication.

**Discussion.** Our UCD cases (patient 1-previously undiagnosed adult-onset type II citrullinemia and patient 2- known hyperargininemia) presented with episodic hyperammonemic encephalopathy with or without obvious trigger and the electro-clinical syndrome had a close resemblance to NCSE. While the anticonvulsant therapy provided only transient electro-clinical improvement in patient 1 and was not considered in patient 2 (with the already established diagnosis of arginase deficiency), the clinical outcomes were different following the standard treatment protocol for hyperammonemia. In patient 1, in whom the rare diagnosis of adult-onset type II citrullinemia was not initially recognized, the anticonvulsant therapy was suitably modified by discontinuing sodium valproate and topiramate from the polypharmacy for presumed refractory NCSE when mild hyperammonemia was initially uncovered. However, because of her unusual electro-clinical presentation that was hitherto mistaken for catatonia and schizoaffective disorder for nearly 5 years and the latest episode being refractory to treatment with anticonvulsants, we persisted with the work-up for hyperammonemia. The timely availability of the amino acid result (not a routinely ordered biochemical test for NCSE) could have made a therapeutic difference (by the restriction of carbohydrate from the hyperammonemic encephalopathy treatment protocol in patient 1) by improving the diagnostic categorization to a specific UCD such as adult onset citrullinemia and minimizing the diagnostic and therapeutic delay.

In the context of hyperammonemic encephalopathy, pattern recognition of the amino acid abnormalities carries therapeutic implications.<sup>4,5</sup> Thus, routine administration of dextrose should be avoided in the setting of adult onset citrullinemia, as carbohydrate loading unfavorably influences the biochemical milieu in citrin deficiency<sup>6</sup> and this biochemical deterioration was also vividly illustrated in patient 1 (Figure 3). For the metabolic crisis of UCD mimicking NCSE, the therapeutic focus should be on improving hyperammonemia (as progressively worsening hyperammonemia has deleterious effects on brain function), instead of the overemphasis on anticonvulsant treatment alone.

To the best of our knowledge, this is the first clinical report of adult-onset type II citrullinemia from Oman. Although adult-onset citrullinemia is panethnic, there are regional differences in the reported

frequency of adult-onset citrullinemia cases.<sup>7,8</sup> For instance, a prevalence of 1:100,000-1:230,000 cases has been reported from east Asian countries such as Japan.<sup>8</sup> At present, except for occasional case reports, population-based epidemiological studies addressing the true prevalence of adult-onset citrullinemia from other parts of the world are lacking. It is possible that this condition remains vastly under-diagnosed in many parts of the world. We hope that the present report will provide an educational impetus in raising awareness and improving the early recognition of this potentially treatable condition.

Our cases provide several learning points (take-away lessons): 1) in an otherwise unexplained encephalopathy mimicking NCSE, plasma ammonia and amino acid profile should be included in the initial laboratory panel in view of the diagnostic and therapeutic implications. Often, the genetic confirmation is not quickly available to guide the diagnostic and therapeutic pursuits at the time of metabolic crisis; 2) the standard therapeutic guideline (that excludes cases of adult-onset type II citrullinemia) suggesting dextrose infusion in primary hyperammonemic encephalopathy should be reviewed and individualized; in particular, carbohydrate restriction should be considered in the rare cases of adult-onset type II citrullinemia; 3) apart from the classical phenotype of spastic paraparesis, additional feature of hyperargininemia includes episodic hyperammonemic encephalopathy.<sup>9</sup>

We emphasize the importance of recognizing hyperammonemic encephalopathy as an imitator of NCSE, as hyperammonemia is an eminently treatable medical emergency and would prove fatal if not adequately or appropriately treated. Timely review of the amino acid profile can guide therapeutic decisions at the time of metabolic crisis.

## References

1. Häberle J, Boddaert N, Burlina A, Chakrapani A, Dixon M, Huemer M, et al. Suggested guidelines for the diagnosis and management of urea cycle disorders. *Orphanet J Rare Dis* 2012; 7: 32.
2. Grioni D, Furlan F, Canonico F, Parini R. Epilepsia partialis continua and generalized nonconvulsive status epilepticus during the course of argininemia: a report on two cases. *Neuropediatrics* 2014; 45: 123-8.
3. Beniczky S, Hirsch LJ, Kaplan PW, Pressler R, Bauer G, Aurlen H, et al. Unified EEG terminology and criteria for nonconvulsive status epilepticus. *Epilepsia* 2013; 54: 28-29.
4. Takahashi H, Kagawa T, Kobayashi K, Hirabayashi H, Yui M, Begum L, et al. A case of adult-onset type II citrullinemia--deterioration of clinical course after infusion of hyperosmotic and high sugar solutions. *Med Sci Monit* 2006; 12: CS13-CS15.

5. Nakamura M, Yazaki M, Kobayashi Y, Fukushima K, Ikeda S, Kobayashi K, et al. The characteristics of food intake in patients with type II citrullinemia. *J Nutr Sci Vitaminol (Tokyo)* 2011; 57: 239-245.
6. Saheki T, Inoue K, Ono H, Katsura N, Yokogawa M, Yoshidumi Y, et al. Effects of supplementation on food intake, body weight and hepatic metabolites in the citrin/mitochondrial glycerol-3-phosphate dehydrogenase double-knockout mouse model of human citrin deficiency. *Mol Genet Metab* 2012; 107: 322-329.
7. Dimmock D, Maranda B, Dionisi-Vici C, Wang J, Kleppe S, Fiermonte G, et al. Citrin deficiency, a perplexing global disorder. *Mol Genet Metab* 2009; 96: 44-49.
8. Kobayashi K, Iijima M, Ushikai M, Ikeda S, Saheki T. Citrin deficiency. *J Jpn Pediatr Soc* 2006; 110: 1047-1059.
9. Zhang Y, Landau YE, Miller DT, Marsden D, Berry GT, Kellogg MD. Recurrent unexplained hyperammonemia in an adolescent with arginase deficiency. *Clin Biochem* 2012; 45: 1583-1586.

### Authorship entitlement

Excerpts from the Uniform Requirements for Manuscripts Submitted to Biomedical Journals updated November 2003.

Available from [www.icmje.org](http://www.icmje.org)

---

The international Committee of Medical Journal Editors has recommended the following criteria for authorship; these criteria are still appropriate for those journals that distinguish authors from other contributors.

Authorship credit should be based on 1) substantial contributions to conception and design, or acquisition of data, or analysis and interpretation of data; 2) intellectual content; and 3) final approval of the version to be published. Authors should meet conditions 1, 2, and 3.

Acquisition of funding, collection of data, or general supervision of the research group, alone, does not justify authorship.

An author should be prepared to explain the order in which authors are listed.