



Case report

Bilateral adrenal hemorrhage in a total knee patient associated with enoxaparin usage

Kwan Jun Park, MD^a, Marty Bushmiaer, APN^b, C. Lowry Barnes, MD^{a, b, *}^a Department of Orthopaedics, University of Arkansas for Medical Sciences, Little Rock, AR, USA^b HipKnee Arkansas Foundation, Little Rock, AR, USA

ARTICLE INFO

Article history:

Received 9 December 2014

Received in revised form

2 February 2015

Accepted 15 February 2015

Available online 28 August 2015

Keywords:

Bilateral adrenal hemorrhage

Total joint replacement

Anticoagulation

Enoxaparin

ABSTRACT

Bilateral adrenal hemorrhage is a rare but potentially catastrophic complication of chemoprophylaxis. We report a patient who underwent a total knee arthroplasty and subsequently developed bilateral adrenal hemorrhage from enoxaparin. Once the patient was diagnosed with acute adrenal insufficiency, corticosteroids were promptly started, and the patient made a dramatic recovery and did not suffer further complications.

Copyright © 2015 Published by Elsevier Inc. on behalf of American Association of Hip and Knee Surgeons. This is an open access article under the CC BY-NC-ND license (<http://creativecommons.org/licenses/by-nc-nd/4.0/>).

Introduction

Deep venous thrombosis (DVT) is a known complication of total joint replacement surgery and, without appropriate anticoagulation prophylaxis, the prevalence of DVT is reported to be 40–80% in total knee replacements, 50–60% in total hip replacements, and 30–60% after hip fracture [1,2]. The associated risk of pulmonary embolism is approximately 10% with an overall fatality rate of 5% [1,2]. Several anticoagulation prophylaxis modalities, including pharmacological and mechanical methods, have been designed to prevent this complication. However, pharmacological agents, such as unfractionated heparin, warfarin, low-molecular-weight-heparin, or rivaroxaban, are not without risks [3]. Development of hematoma, persistent hemorrhage, and wound complications are among the commonly reported pharmacophylaxis-related complications [3,4].

Acute bilateral adrenal hemorrhage (BAH), although rare, has been reported as a potentially catastrophic complication of anticoagulation

therapy [1,5–7]. However, this condition also occurs in the settings of post-operative period, septicemia, pregnancy, anti-phospholipid syndrome, heparin-associated thrombocytopenia, trauma, and coagulopathies [1,5–7].

BAH presents a diagnostic challenge to treating physicians due to non-specific complaints and symptoms that range from vague abdominal pain, nausea, vomiting, neuropsychiatric symptoms, hypotension or shock, and fever [5–7].

To our knowledge, several case reports of BAH from warfarin and unfractionated heparin exist in a subset of orthopedic patients undergoing joint replacement surgeries [1,5–20]. However, this is the first reported case of enoxaparin-induced BAH following arthroplasty. We report a case of BAH secondary to enoxaparin use after unilateral knee replacement surgery.

Case history

A 65 year-old female with end-stage osteoarthritis of the right knee had progressively worsening joint pain that was refractory to all non-operative measures. The patient's medical comorbidities included well-controlled hypertension, gastroesophageal reflux disease, and remote history of DVT. Once the patient failed non-operative management of her osteoarthritis, the patient was recommended to undergo right total knee arthroplasty. The risks and the benefits of the surgery were explained, and informed consent was obtained. The patient's perioperative and post-operative

One or more of the authors of this paper have disclosed potential or pertinent conflicts of interest, which may include receipt of payment, either direct or indirect, institutional support, or association with an entity in the biomedical field which may be perceived to have potential conflict of interest with this work. For full disclosure statements refer to <http://dx.doi.org/10.1016/j.artd.2015.02.001>.

* Corresponding author. 1701 Aldersgate Road, Suite 3, Little Rock, AR 72205, USA. Tel.: +1 501 246 4439.

E-mail address: lbarnes@arspecialty.com

<http://dx.doi.org/10.1016/j.artd.2015.02.001>

2352-3441/Copyright © 2015 Published by Elsevier Inc. on behalf of American Association of Hip and Knee Surgeons. This is an open access article under the CC BY-NC-ND license (<http://creativecommons.org/licenses/by-nc-nd/4.0/>).

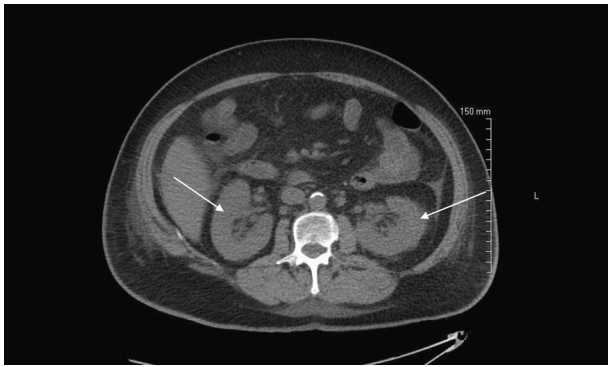


Figure 1. Axial CT image demonstrating bilateral adrenal gland enlargements and diffuse hemorrhage (arrows).

courses were uncomplicated, and was discharged home on post-operative day (POD) two. The patient was placed on enoxaparin (30 mg B.I.D) for DVT prophylaxis on POD one and was discharged home with the same regimen for an additional ten days.

On POD eight, the patient was admitted with complaints of vague epigastric pain, lethargy, and febrile episodes. Symptoms included decreased appetite, somnolence, anxiety, and nausea without vomiting. Physical examination was unremarkable, and vital signs included temperature 101.7 F, heart rate 111, respiration 20, blood pressure 123/87, and oxygen saturation 92% at admission. Laboratory values showed significant hyponatremia (126),

hypokalemia (2.6), glucose (60), hematocrit (25.3), creatinine (0.8), WBC count (14,900), and platelet count (161,000). The patient was immediately evaluated, and the differential diagnosis included pulmonary embolism, sepsis, metabolic encephalopathy, and adrenal insufficiency.

However, the patient's chest CT scan was negative for pulmonary embolism, and the MRI of the brain was negative for acute pathology. The medicine team was concerned for presumed sepsis, and empirical intravenous antibiotics (ceftriaxone, vancomycin, and acyclovir) were promptly started, and various cultures including CSF, urine, and blood were obtained.

The patient deteriorated rapidly and was transferred to the intensive care unit and received aggressive intravenous volume support with pressors. Subsequent clinical and laboratory findings suggested possible adrenal insufficiency. Basal cortisol levels were obtained before and after cosyntropin (ACTH) stimulation, and both values were 0.3 nmol/L. Abdominal CT revealed bilateral adrenal hemorrhages (Fig. 1). Enoxaparin was immediately discontinued, and the patient was started on high dose hydrocortisone. The patient improved dramatically and subsequently left the intensive care unit within 24–48 h of glucocorticoid administration. Glucocorticoid was tapered, and the patient improved clinically and was discharged without further complications.

The patient most recently followed up with the senior author at her 1-year visit, and her knee has excellent range of motion, and X-rays demonstrate well-placed components with no evidence of loosening. She has since returned to her previous activity level including bowling.

Table 1
Characteristics of total arthroplasty patients who suffered bilateral adrenal hemorrhages (BAH).

Author	Age	Sex	Procedure	Post op days	Dvt prophylaxis	Outcome	Complaints	Initial labs	Imaging	HIT	Tx
Laban et al. [1]	83	F	B/L TKA	8	SQ heparin and warfarin	DC home	Epigastric pain, nausea	Na 126, K 3.4, no anemia	CT	Unk	Hydrocortisone
Rajamanickam et al. [5]	52	M	B/L TKA	9	Enoxaparin	dc home	Abdominal pain, nausea, vomiting, constipation, shock, confusion, fever	Na 134, hct 30, HIT neg	CT	No	Hidorcortisone
Barrou et al. [8]	80	M	TKA	6	Enoxaparin	DC home	Abdominal pain, anxiety, confusion, fever, hypotension	Na 129, K 5.5	CT	No	Corticosteroids
Best et al. [9]	75	F	THA	9	Dabigatran	Unknown	Sob, fever, ab pain	Unknown	CT	Unk	Unknown
Bleasel et al. [10]	69	F	TKA rev	Unknown	SQ heparin	Unknown	Fever, nausea, vomiting, abdominal pain	Unknown	None	Yes	Unknown
Chow et al. [11]	44	M	B/L TKA	10	Heparin drip	DC home	Abdominal pain, tachycardia, fever	Na 124, K 4.9, low platelets	CT	Yes	Methylprednisolone, hydrocortisone taper
Cozzolino et al. [12]	66	F	TKA	7	Coumadin	DC home	Nausea, anorexia, and emesis	Na 129, K 5.2, Hct 23	CT	Unk	Corticosteroids
Delhumeau et al. [13]	74	M	THA	4	SQ heparin	Unknown	Abdominal pain, fever, hypotension, ab tenderness	Unknown	CT	Yes	Unknown
Ernest et al. [14]	68	F	THA	Unknown	SQ heparin	Unknown	Shock			Yes	
Hardwicke et al. [15]	63	F	B/L TKA	7	SQ heparin and warfarin	DC home	Nausea, vomiting, anorexia, vague feeling of illness, hypotension, dizziness	Na 127, K 4.6	CT	Unk	Dexamthasone
Kurtz et al. [16]	54	F	THA	Unknown	SQ dalteparin	Alive	Fever, abdominal pain, anorexia	Na 131, NL K, low PLT	CT	Yes	Corticosteroids
Mongardon et al. [17]	64	M	THA	7	SQ heparin	Alive	Fever, abdominal pain, shock	Normal labs	CT	Yes	Corticosteroids
Schuchmann et al. [19]	83	F	B/L TKA	5	SQ heparin	Death	Anxious, sob, shock, fever	Na 122, K 4.2, Hct 31.2	None	Unk	None
Souied et al. [20]	63	F	THA	10	SQ heparin	Death	Hypotension, shock, fever	Na 138, K 4.5, PLT 380000	CT	Yes	Corticosteroids
Ries, Guiney et al. [21]	61	M	B/L TKA	9	Warfarin	Death	Abdominal pain, nausea, fever, hypotension	Unknown	None	Unk	None
Park et al.*	65	F	TKA	8	Enoxaparin	DC home	Abdominal pain, nausea, fever, hypotension	Na 126, K 2.6, Hct 25.3	CT	No	Corticosteroids

*Our patient described in the case report.

Discussion

Multiple guidelines exist in order to assist physicians with clinical decisions regarding DVT prophylaxis for elective joint replacement surgery patients [3,11]. While both mechanical and pharmacological methods are effective, chemoprophylaxis remains a popular choice due to its higher compliance rate and ease of use [3,11]. However, chemoprophylaxis is associated with increased risk of bleeding, wound complications, and heparin-induced thrombocytopenia [3,4,6,11,17]. BAH is a rare complication of chemoprophylaxis. While spontaneous adrenal hemorrhage has been reported, BAH has been reported in settings of sepsis, trauma, intra-operative/post-operative complications, severe burns, anti-coagulant therapy, other coagulopathies [6,7,17].

Following a detailed literature search for BAH cases in hip and knee arthroplasty patients, a total of 16 cases were identified (Table 1). The mean age was 66.5. Six patients (37.5%) underwent bilateral total knee replacements, and one patient underwent revision total knee arthroplasty. Clinical symptoms and signs are summarized in Table 2. Some patients presented with laboratory abnormalities, such as, hyponatremia (8 patients) and hypokalemia (2). Acute anemia was present in two patients, and thrombocytopenia was present in seven patients. BAH was determined at the time of autopsy in two cases.

In seven cases, heparin-induced-thrombocytopenia was identified as the cause of BAH after confirmatory HIT antibody tests, however, in three cases (including our case), the HIT antibody test was negative. In our patient, platelet count was 161,000 at initial presentation, and remained between 200,000 and 250,000 during hospitalization. Abdominal CT scans revealed BAH in 12 of 16 patients, and it was the most reliable diagnostic test. In 10 of 16 patients, acute adrenal insufficiency was further confirmed by a cosyntropin stimulation test, and these patients received corticosteroids and made remarkable recovery within 24–48 h.

BAH often presents with non-specific signs and symptoms, and clinical associations are commonly unrecognized, making prospective diagnosis and early treatment exceedingly difficult. Physical examinations are rarely diagnostic, with fever and abdominal pain being two consistent clinical features [5,18,19]. Laboratory clues include unexplained drop in hematocrit, leukocytosis, eosinophilia, hyponatremia, hyperkalemia, and hypoglycemia [1,5–8,11,12,19,20,23]. While the biochemical evidence of adrenal insufficiency including hyponatremia and hyperkalemia with volume contraction can provide diagnostic clues for acute adrenal insufficiency, not all patients presented with such laboratory abnormalities. Only 8 of 16 patients presented with hyponatremia, two patients had hypokalemia only, and no patient had hyperkalemia at the time of presentation.

CT, MRI and U/S are recommended diagnostic BAH imaging modalities [19]. Diagnosis is made on abdominal CT or MRI with common characteristics featuring bilateral rounded adrenal gland enlargement, confirmed by cosyntropin stimulation. The mass seen on CT and MRI of adrenal gland with no enhancement or enhancement only in a pattern of a thin peripheral rim can be used to distinguish hematoma from other pathologies [12,21].

Table 2
Clinical signs and symptoms of the patients from reported BAH cases.

Symptoms	Number of patients
Nausea	8/16 (50%)
Abdominal pain	16/16 (100%)
Emesis	3/16 (19%)
Febrile	12/16 (75%)
Confusion/neuropsychiatric symptoms	5/16 (31%)
Hypotension/Shock	9/16 (56%)
Shortness of breath	2/16 (13%)

When suspicious for acute adrenal insufficiency, cosyntropin stimulation should be performed to measure the adrenal gland response to a cosyntropin challenge at 30 and 60 min intervals. A normal, appropriate response is approximately a two-fold increase in serum cortisol levels after cosyntropin administration [5,6,18]. With steroid administration, the dramatic improvement in the cardiovascular status was usually seen, and all patients who received the corticosteroid therapy made remarkable recovery within 24–48 h of administration [7,18,22]. However, the clinical course of this disease does not always follow a favorable one, and, once the shock is too severe, even large doses of steroids may be ineffective [18].

The loss of adrenal function associated with adrenal atrophy is almost universal in patients who survived acute adrenal insufficiency [22]. While our patient did not require long-term steroid therapy, all 10 patients in the literature who recovered via the corticosteroid replacement therapy were placed on long-term replacement therapy.

Rao et al. reported their experience in treating several patients with BAH and developed an algorithm for the diagnosis and treatment of bilateral massive adrenal hemorrhage [18]. In this algorithm, they have categorized the progression of the disease into different levels depending on the severity of cardiopulmonary status [18]. They emphasized the importance of having high clinical suspicion for BAH and recommended early intervention with intravenous corticosteroids.

Summary

BAH is a rare complication that can occur with DVT prophylaxis such as enoxaparin or coumadin. Total joint patients with chemoprophylaxis, who present with non-specific symptoms including abdominal distress, fever, and anxiety related complaints on post-operative day 4–10, should not be ignored, and a high index of clinical suspicion is required to prevent this catastrophic event. CT scans and hormone assays should be obtained at earliest suspicion of acute adrenal insufficiency, and presumptive steroid treatment should be initiated while awaiting confirmatory tests.

References

- [1] LaBan MM, Whitmore CE, Taylor RS. Bilateral adrenal hemorrhage after anticoagulation prophylaxis for bilateral knee arthroplasty. *Am J Phys Med Rehabil* 2003;82(5):418.
- [2] Stringer MD, Steadman CA, Hedges AR, et al. Deep vein thrombosis after elective knee surgery. An incidence study in 312 patients. *J Bone Joint Surg Br* 1989;71(3):492.
- [3] Johanson NA. Venous thromboembolism guidelines and prophylaxis. Hip and Knee Reconstruction. Orthopedic Knowledge Update (OKU), 4. American Association of Orthopaedic Surgeons; 2011. Rosemont, IL.
- [4] Colwell Jr CW, Froimson MI, Anseth SD, et al. A mobile compression device for thrombosis prevention in hip and knee arthroplasty. *J Bone Joint Surg Am* 2014;96(3):177.
- [5] Rajamanickam A, Patel P, Anbazhagan P, Harte B. A life threatening complication of anticoagulation prophylaxis-bilateral adrenal hemorrhage. *J Hosp Med* 2009;4(9):E25.
- [6] Rosenberger LH, Smith PW, Sawyer RG, et al. Bilateral adrenal hemorrhage: the unrecognized cause of hemodynamic collapse associated with heparin-induced thrombocytopenia. *Crit Care Med* 2011;39(4):833.
- [7] Vella A, Nippoldt TB, Morris 3rd JC. Adrenal hemorrhage: a 25-year experience at the Mayo Clinic. *Mayo Clin Proc* 2001;76(2):161.
- [8] Barrou Z, Verny C, Cohen-Bittan J, Verny M. Bilateral adrenal necrosis after knee arthroplasty. *J Am Geriatr Soc* 2010;58(11):2248.
- [9] Best M, Palmer K, Jones QC, Wathen CG. Acute adrenal failure following anticoagulation with dabigatran after hip replacement and thrombolysis for massive pulmonary embolism. *BMJ Case Rep* 2013;2013.
- [10] Bleasel JF, Rasko JE, Rickard KA, Richards G. Acute adrenal insufficiency secondary to heparin-induced thrombocytopenia-thrombosis syndrome. *Med J Aust* 1992;157(3):192.
- [11] Chow VW, Abnoui F, Huddleston JL, Lin LH. Heparin-induced thrombocytopenia after total knee arthroplasty, with subsequent adrenal hemorrhage. *J Arthroplasty* 2012;27(7):1413 e15.

- [12] Cozzolino D, Peerzada J, Heaney JA. Adrenal insufficiency from bilateral adrenal hemorrhage after total knee replacement surgery. *Urology* 1997;50(1):125.
- [13] Delhumeau A, Moreau X, Chapotte C, Houi N, Bigorgne JC. Heparin-associated thrombocytopenia syndrome: an underestimated etiology of adrenal hemorrhage. *Intensive Care Med* 1993;19(8):475.
- [14] Ernest D, Fisher MM. Heparin-induced thrombocytopenia complicated by bilateral adrenal haemorrhage. *Intensive Care Med* 1991;17(4):238.
- [15] Hardwicke MB, Kisly A. Prophylactic subcutaneous heparin therapy as a cause of bilateral adrenal hemorrhage. *Arch Intern Med* 1992;152(4):845.
- [16] Kurtz LE, Yang S. Bilateral adrenal hemorrhage associated with heparin induced thrombocytopenia. *Am J Hematol* 2007;82(6):493.
- [17] Mongardon N, Bruneel F, Henry-Lagarrigue M, et al. Shock during heparin-induced thrombocytopenia: look for adrenal insufficiency! *Intensive Care Med* 2007;33(3):547.
- [18] Rao RH, Vagnucci AH, Amico JA. Bilateral massive adrenal hemorrhage: early recognition and treatment. *Ann Intern Med* 1989;110(3):227.
- [19] Schuchmann JA, Friedman PA. Bilateral adrenal hemorrhage: an unusual complication after bilateral total knee arthroplasty. *Am J Phys Med Rehabil* 2005;84(11):899.
- [20] Souied F, Pourriat JL, Le Roux G, et al. Adrenal hemorrhagic necrosis related to heparin-associated thrombocytopenia. *Crit Care Med* 1991;19(2):297.
- [21] Hoeffel C, Legmann P, Luton JP, Chapuis Y, Fayet-Bonnin P. Spontaneous unilateral adrenal hemorrhage: computerized tomography and magnetic resonance imaging findings in 8 cases. *J Urol* 1995;154(5):1647.
- [22] Kovacs KA, Lam YM, Pater JL. Bilateral massive adrenal hemorrhage. Assessment of putative risk factors by the case-control method. *Medicine (Baltimore)* 2001;80(1):45.
- [23] Ries MD, Guiney W, Lynch F. Fatal massive adrenal hemorrhage after bilateral total knee arthroplasty. *J Arthroplasty* 1994;9(5):559.