

Single-port robotic partial nephrectomy: impact on perioperative outcomes and hospital stay

Umberto Carbonara^{ID}, Daniele Amparore, Leonardo D. Borregales, Anna Caliò, Chiara Ciccacese, Pietro Diana, Selcuk Erdem^{ID}, Laura Marandino, Michele Marchioni, Constantijn H.J. Muselaers, Carlotta Palumbo, Nicola Pavan, Angela Pecoraro, Eduard Roussel, Hannah Warren, Zhen-Jie Wu, Riccardo Campi^{ID} and Riccardo Bertolo; On behalf of the European Association of Urology Young Academic Urologists Renal Cancer Working Group

Abstract: Single-port (SP) robotic surgery is a novel technology and is at the beginning of its adoption curve in urology. The goal of this narrative review is to provide an overview of SP-robotic partial nephrectomy (PN) 4 years after the introduction of the da Vinci SP dedicated platform, focusing on perioperative outcomes, length of stay, and surgical technique. A nonsystematic review of the literature was conducted. The research included the most updated articles that referred to SP robotic PN. Since its commercial release in 2018, several institutions have reproduced robotic PN by using the SP platform, both *via* a transperitoneal and a retroperitoneal approach. The published SP-robotic PN series are generally based on preliminary experiences by surgeons who had previous experience with conventional multi-arms robotic platforms. The reported outcomes are encouraging. Overall, three studies reported that SP-robotic PN cases had nonsignificantly different operative time, estimated blood loss, overall complications rate, and length of stay compared to the conventional 'multi-arms' robotic PN. However, in all these series, renal masses treated by SP had overall lower complexity. Moreover, two studies underlined decreased postoperative pain as a major pro of adopting the SP system. This should reduce/avoid the need for opioids after surgery. No study compared SP-robotic *versus* multi-arms robotic PN in cost-effectiveness. Published experience with SP-robotic PN has reported the feasibility and safety of the approach. Preliminary results are encouraging and at least noninferior with respect to those from the multi-arms series. Prospective comparative studies with long-term oncologic and functional results are awaited to draw more definitive conclusions and better establish the more appropriate indications of SP robotics in the field of PN.

Keywords: nephrectomy, nephroureterectomy, partial nephrectomy, pyeloplasty, RAPN, single-port, SP, robotic, renal surgery

Received: 11 January 2023; revised manuscript accepted: 13 April 2023.

Background

The laparoscopic approach to partial nephrectomy (PN) has emerged during the last two decades showing similar perioperative, oncological, and functional outcomes to those of the

traditional open approach.^{1,2} *Laparo-endoscopic single-site surgery* (LESS) was conceived more than 15 years ago as an evolution in laparoscopic surgery to potentially further reduce invasiveness.^{3,4} The term 'LESS' has been coined to

Ther Adv Urol

2023, Vol. 15: 1–13

DOI: 10.1177/
17562872231172834

© The Author(s), 2023.
Article reuse guidelines:
sagepub.com/journals-
permissions

Correspondence to:

Umberto Carbonara
Andrology and Kidney
Transplantation
Unit, Department of
Emergency and Organ
Transplantation-Urology,
University of Bari Aldo
Moro, Piazza Giulio
Cesare, 11, 70125, Bari,
Italy.

Department of Urology,
Royal Surrey Country
Hospital, Guildford, United
Kingdom

Renal Cancer Working
Group, Young Academic
Urologists (YAU), European
Association of Urology
(EAU), Arnhem, The
Netherlands
u.carbonara@gmail.com

Daniele Amparore
Renal Cancer Working
Group, Young Academic
Urologists (YAU), European
Association of Urology
(EAU), Arnhem, The
Netherlands

Division of Urology,
Department of Oncology,
School of Medicine, San
Luigi Hospital, University
of Turin, Turin, Italy

Leonardo D. Borregales
Renal Cancer Working
Group, Young Academic
Urologists (YAU), European
Association of Urology
(EAU), Arnhem, The
Netherlands

Department of Urology,
Weill Cornell Medicine,
New York-Presbyterian,
New York, NY, USA

Anna Caliò
Department of Pathology
and Diagnostic, University
of Verona, Verona, Italy

Chiara Ciccacese
Renal Cancer Working
Group, Young Academic
Urologists (YAU), European
Association of Urology
(EAU), Arnhem, The
Netherlands

Medical Oncology Unit,
Comprehensive Cancer
Center, Fondazione

Polliclinico Universitario
Agostino Gemelli IRCCS,
Rome, Italy

Pietro Diana

Renal Cancer Working
Group, Young Academic
Urologists (YAU), European
Association of Urology
(EAU), Arnhem, The
Netherlands

Department of Urology,
Fundació Puigvert,
Autonoma University of
Barcelona, Barcelona,
Spain

Selcuk Erdem

Renal Cancer Working
Group, Young Academic
Urologists (YAU), European
Association of Urology
(EAU), Arnhem, The
Netherlands

Division of Urologic
Oncology, Department of
Urology, Istanbul Faculty
of Medicine, Istanbul
University, Istanbul, Turkey

Laura Marandino

Renal Cancer Working
Group, Young Academic
Urologists (YAU), European
Association of Urology
(EAU), Arnhem, The
Netherlands

Department of Medical
Oncology, IRCCS Ospedale
San Raffaele, Vita-Salute
San Raffaele University,
Milan, Italy

Michele Marchioni

Renal Cancer Working
Group, Young Academic
Urologists (YAU), European
Association of Urology
(EAU), Arnhem, The
Netherlands

Department of Urology, SS
Annunziata Hospital, 'G.
D'Annunzio' University of
Chieti, Chieti, Italy

Constantijn H.J.

Muselaers

Renal Cancer Working
Group, Young Academic
Urologists (YAU), European
Association of Urology
(EAU), Arnhem, The
Netherlands

Department of Urology,
Radboud University
Medical Center, Nijmegen,
The Netherlands

Carlotta Palumbo

Renal Cancer Working
Group, Young Academic
Urologists (YAU), European
Association of Urology
(EAU), Arnhem, The
Netherlands; Urology Unit,
Ospedale Maggiore della
Carità, Novara, Italy

Nicola Pavan

Renal Cancer Working
Group, Young Academic
Urologists (YAU), European
Association of Urology
(EAU), Arnhem, The
Netherlands

incorporate a group of related techniques that perform laparoscopic surgery through a single abdominal access site, typically at the level of the umbilicus.⁵ Indeed, LESS increase its popularity due to a perceived impression that reducing the number of ports would result in reduced morbidity and improved cosmesis compared to conventional multiport laparoscopy.

Since the initial report by Raman *et al.*,⁴ LESS has been used to perform various major urological procedures, including PN. Although many reports demonstrated the feasibility of LESS, this approach is even more technically demanding than the standard pure laparoscopic one. This has prevented the widespread diffusion of the technique, particularly for performing PN.⁶

The advent of robotic platforms permitted to overcome some technical challenges of laparoscopy (such as limited moving space within the abdomen, lack of a wrist, and other technical difficulties) and helped to widen the indications of minimally invasive PN to more surgeons. Nowadays, the preferred approach to PN is *de facto* the robotic approach.^{7,8}

Similarly to traditional laparoscopy, the robot has been used in an attempt to improve the performance with LESS, since it allows for the console left- and right-hand masters to be interchanged electronically, thus eliminating the 'reverse handedness effect' typical of conventional LESS.⁹ Several studies on robotic LESS applied to many urological procedures including PN followed,¹⁰ but despite some reported improvements, consistent drawbacks remained, including the external clashing and the limited accessibility for the bedside assistant. This was because the da Vinci (Intuitive, Sunnyvale, CA, USA) robotic platform was not primarily conceived for LESS purposes.¹¹

Similar to the history of pure LESS relative to pure laparoscopy, robotic LESS did not gain popularity.¹² In 2018, the USA Food and Drug Administration (FDA) approved the use of a 'purpose-built' robotic platform specifically conceived for the single-site approach. All the major urologic surgeries were duplicated by using the novel 'da Vinci SP' (Intuitive) robotic platform.¹³ Specifically, the first single-port (SP)-robotic PN was published by Kaouk *et al.*¹⁴ in November 2018. Since then, promising perioperative outcomes have been reported in the field of PN.¹⁴⁻²²

The history of robotic single-site surgery in urology

What led us to the availability (although in the United States and Far East only at the moment) of the SP robotic platform is the hypothesis that a virtually 'scarless' surgery could decrease the morbidity associated with surgical access, given the lower numbers of transcutaneous points of access (i.e. the trocar sites). Such an approach could potentially translate into superior outcomes, lower complication rates, and faster recovery than the traditional multi-port surgery.²³

The idea of single-access surgery was born decades ago.²⁴ However, only in the early 1990s the first excision laparoscopic procedure was published in gynecology.²⁴ In 2007, at the 25th World Congress of Endourology, Rane *et al.*²⁵ presented the first LESS successful case in urology. Nevertheless, the genuine enthusiasm progressively decreased due to the intrinsic technical challenges associated with the use of a single access point, namely the reduced instruments' range of motion and the unfavorable ergonomics.²⁶

Robotic single-site surgery: the beginning

The advent of robotic platforms renewed the interest in LESS.¹⁴ In 2009, the Cleveland Clinic (Cleveland, OH, USA) group led by Kaouk reported the first successful series of robot-assisted single-site surgeries (including prostatectomy, pyeloplasty, and nephrectomy) performed in humans by using the multi-arms da Vinci S (Intuitive) robotic platform.⁶ The authors underlined that, although the da Vinci S platform was not primarily conceived to perform single-site surgery, it facilitated the surgical dissection and the intracorporeal suturing if compared to non-robot-assisted LESS.⁶ However, plenty of limitations remained, mostly relative to the clashing of robotic arms due to the instruments working in parallel (Figure 1).

Robot-assisted VeSPA single-site surgery

Intuitive Surgical Inc. then developed a novel set of instruments and accessories specifically dedicated to SP robotic surgery, named 'VeSPA single site', in an attempt to overcome such limitations.²⁷

The set included a multichannel access port with room for four cannulas and an insufflation valve:

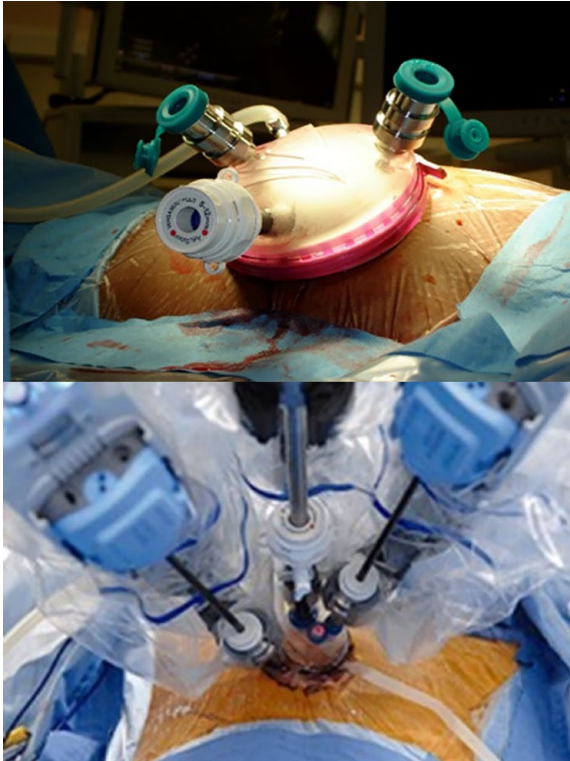


Figure 1. Robotic single-site approach: the beginning.

Standard robotic instruments with straight shafts were introduced together into a single incision on the skin/fascia. Different combinations of access ports and trocars were used to allow for such a tricky approach.

two out of four curved cannulas were for robotic instruments, and the other two straight cannulas (8.5 mm cannula for the robotic endoscope and a 5 mm for the bed-side port). Crossing the curved cannulas midway through the access port permitted the instruments to achieve triangulation of the target.

Si system software allowed to maintain the same-sided hand-eye control of the instruments. The surgeon's right-hand controls the screen-right instrument even though the instrument was in the left robotic arm (and vice versa) (Figure 2).

The Cleveland Clinic group again pioneered an early experience on the animal and the human cadaver models.^{28,29} The authors reported reduced external collisions among the robotic arms since the curved cannulas angled the robotic arms distant from each other.

Several clinical experiences witnessed the feasibility, safety, and efficacy of the VeSPA single-site




Figure 2. The 'VeSPA single-site' instruments used with the Si da Vinci platform.

The multichannel access port includes two straight cannulas and two curved cannulas plus an insufflation valve. One straight 8.5 mm cannula accommodates the robotic endoscope, and the other straight 5 mm cannula is available to accommodate the bedside-assistant instrument. The two curved cannulas accommodate the dedicated curved robotic instruments. The triangulation is achieved by crossing the curved cannulas midway through the access port. Same-sided hand-eye control of the instruments is maintained through the assignment of the Si system software enabling the surgeon's right hand to control the screen right instrument even though the instrument was in the left robotic arm (and vice versa).

approach for performing major urological procedures in selected patients. Particular emphasis was put on the cosmetic results.^{30–32}

On the other hand, contrary to the 'standard' robotic instruments, the curved VeSPA single-site instruments did not include the EndoWrist® technology at their distal end, which made intracorporeal suturing more onerous and, again, prevented a widespread diffusion of the approach.^{28,29}

Robot-assisted SP surgery: the advent of the purpose-built platforms

In 2014, the Cleveland Clinic and the University of Lille groups reported the first experience with a

Urology Clinic, Department of Surgical, Oncological, and Oral Sciences, University of Palermo, Palermo, Italy

Angela Pecoraro
Renal Cancer Working Group, Young Academic Urologists (YAU), European Association of Urology (EAU), Arnhem, The Netherlands

Department of Urology, Pederzoli Hospital, Peschiera del Garda, Italy

Eduard Roussel
Renal Cancer Working Group, Young Academic Urologists (YAU), European Association of Urology (EAU), Arnhem, The Netherlands

Department of Urology, University Hospitals Leuven, Leuven, Belgium

Hannah Warren
Renal Cancer Working Group, Young Academic Urologists (YAU), European Association of Urology (EAU), Arnhem, The Netherlands

Division of Surgery and Interventional Science, University College London, London, UK

Zhen-Jie Wu
Renal Cancer Working Group, Young Academic Urologists (YAU), European Association of Urology (EAU), Arnhem, The Netherlands

Department of Urology, Changhai Hospital, Naval Medical University, Shanghai, China

Riccardo Campi
Renal Cancer Working Group, Young Academic Urologists (YAU), European Association of Urology (EAU), Arnhem, The Netherlands

Unit of Urological Robotic Surgery and Renal Transplantation, Careggi University Hospital, University of Florence, Florence, Italy

Department of Experimental and Clinical Medicine, University of Florence, University of Florence, Florence, Italy

Riccardo Bertolo
Renal Cancer Working Group, Young Academic Urologists (YAU), European Association of Urology (EAU), Arnhem, The Netherlands

Department of Urology, San Carlo Di Nancy Hospital, Rome, Italy

*Anna Calò is also affiliated to Renal Cancer Working Group, Young Academic Urologists (YAU), European Association of Urology (EAU), Arnhem, The Netherlands

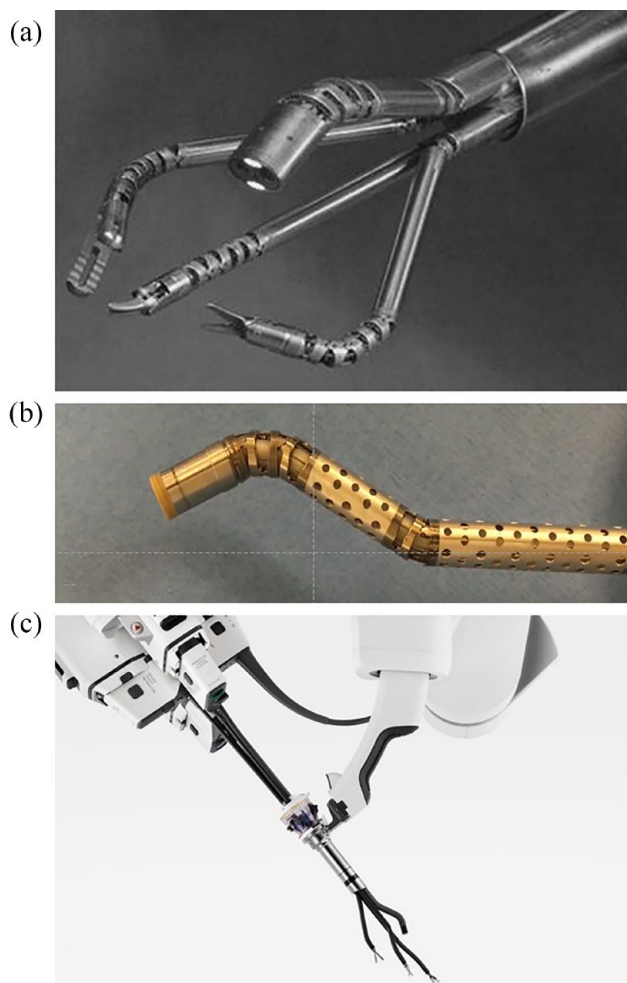


Figure 3. The evolution of the Intuitive Inc. purpose-built da Vinci robotic platform, from the prototype SP999. (a) Used for the very first clinical experiences, through its second generation the prototype SP1098. (b) Used exclusively for pre-clinical experiences on the human cadaver model, till the USA FDA approved SP platform. (c) Nowadays available on the market.

new robotic platform specifically designed to perform SP robotic surgery, namely the prototype SP999 of the da Vinci SP surgical system.⁷ Prostatectomy, nephrectomy, and pyeloplasty interventions were performed on humans, with encouraging perioperative results and no conversions.

The system was designed to guarantee the surgeon the same intraoperative abilities as the existing multi-arms da Vinci platforms, except that three articulating instruments and an articulating camera were inserted into the patient through a single, multichannel port. Exclusive to this novel platform was an additional joint, the so-called elbow, which provides triangulation at the surgical site through the SP.

The SP1098 prototype was introduced as a ‘second-generation’ evolution of the SP999 that was tested within a preclinical setting only.^{33–37} Its components were virtually unmodified from the former model. Considering innovations, the SP1098 included a novel 25-mm multichannel port. Moreover, it has high-definition 3D optics, implementing instrument arm control, and an instrument guidance system.¹¹

Finally, the third-generation da Vinci SP platform included further refinements and received clearance from the USA FDA on May 31, 2018, and became available on the market (Figure 3).

Herein, we provide a narrative review of the ‘state of the art’ of SP-robotic PN 4 years after the introduction of the da Vinci SP platform on the market. Specific focus is given to perioperative outcomes of surgery. Finally, details of the surgical technique are provided.

Methods

A nonsystematic review of the literature within the PubMed (MEDLINE) and Ovid databases was accomplished using the keywords ‘single-port’, ‘partial nephrectomy’, and ‘nephron-sparing surgery’ (Table 1). The research included the most up-to-date articles (published since 2018 – namely, the FDA approval year of the SP platform) that were published in core clinical journals in the English language (up to 30 November 2022).

The peer-review process was independently performed by two authors (U.C. and R.B.). Discrepancies were solved by a third party (R.C.). After a first screening based on the title and abstract, full texts of potentially eligible studies were evaluated and selected. Additional relevant articles were selected from manuscript bibliographies.

The reviewers carried out data extraction collecting the main studies’ features, including first author, year of publication, country, number of patients treated, main characteristics of patients, and perioperative outcomes.

Results were reported in the form of a narrative review. The primary aim was to evaluate the impact of SP-robotic PN on perioperative outcomes and length of hospitalization. The secondary aim of this review was to provide an overview

Table 1. Methodology overview.

Items	Specification
Date of search (specified to date, month and year)	30 November 2022
Databases and other sources searched	PubMed (MEDLINE) and Ovid.
Search terms used (including MeSH and free text search terms and filters) Note: please use an independent supplement table to present the detailed search strategy of one database as an example	'single-port', 'partial nephrectomy', and 'nephron-sparing surgery'
Timeframe	1 November 2022 to 30 November 2022
Inclusion and exclusion criteria (study type, language restrictions, etc.)	The research included cutting-edge articles (almost the last 10 years) that were published in core clinical journals in the English language
Selection process (who conducted the selection, whether it was conducted independently, how consensus was obtained, etc.)	The peer-review process was performed by two authors (U.C. and R.B.) and supervised by a senior author (R.C.). After a first screening based on the title and abstract, full texts of potentially eligible studies were evaluated and selected. The reviewers independently carried out data extraction collecting the main study's features
Any additional considerations, if applicable	None

PubMed (MEDLINE) and Ovid databases were completed using the keywords 'single-port', 'partial nephrectomy', and 'nephron-sparing surgery', filtered for human and adult pathologic conditions.

of the SP-robotic PN techniques. Because of the absence of clinical trials (randomized and non-randomized), weighted cumulative analysis and comparative analyses were not performed.

Evidence synthesis

The principal features of the studies included in the present literature review are summarized in Tables 2 and 3. The narrative review includes three areas of interest as discussed below.

Outcomes of robotic single-site partial nephrectomy before the advent of the purpose-built platforms

Within the setting of the pioneer experiences in robot-assisted single-site surgery described in Table 2, the limited range of motions, the collisions, and the challenges relative to the incorporation of the fourth robotic arm somehow 'compromised' the outcomes of PN. Nevertheless, several reports described shorter convalescence, less pain, and improved cosmesis.^{39,40}

On the other hand, within a series of 51 PN cases performed for 3 cm renal masses on average, Lee *et al.*⁴¹ reported a mean ischemia time of 27 min

(range, 12–65 min), mean operative time >200 min, 2 conversions, and a relatively high transfusion rate (14%). On the same page, by a comparative analysis between 89 patients treated with 'conventional' robotic PN and 78 patients treated with robot-assisted single-site PN, Komnios *et al.*⁴² reported a much lower rate of trifecta achievement *via* the robotic LESS approach (43% *versus* 26%, respectively).

Outcomes of SP-robotic partial nephrectomy

The feasibility of SP-robotic PN was first reported in 2017 by Maurice *et al.*⁴² The SP1098 platform was used in the human cadaver model to perform PN approaching both the anterior and posterior surface of the kidney. All cases were completed with neither intraoperative complications nor the need for conversion.

Since the commercial release in 2018, several institutions have reproduced robotic PN by using the SP platform, both *via* a transperitoneal and a retroperitoneal approach.^{15–22} Note, the SP platform is relatively new, so published SP-robotic PN series are generally based on the preliminary experiences of surgeons with previous experience in conventional multi-arms robotic platforms.^{15–22}

Table 2. Overview of collected studies on cadaver models and initial experience.

Reference	Robotic system	Approach (%)	N ^a	Tumor size (cm) ^b	OT (min)	WIT (min)	EBL (mL)	Conversion (n)	Complications (n) ^c	LOS (days)
Cadaver model experiences										
Maurice <i>et al.</i> ³⁸	Vinci SP1098	Retroperitoneal (100%)	4	3	91.8	21.3		None	None	N/R
Initial experience										
Kaouk <i>et al.</i> ⁷	da Vinci SP999	Transperitoneal (100%)	4	3.25	232	38	55	NR	1 (Intraoperative bleeding due to partial clamping of the renal hilum)	5.8
Kaouk <i>et al.</i> ¹⁴	da Vinci SP1098	Transperitoneal (100%)	3	N/R	180	25	180	None	1 (Postoperative hemorrhage requiring angioembolization – CD: IIIa)	N/R
Fang <i>et al.</i> ¹⁶	da Vinci SP robotic system	Transperitoneal (46.2%) Retroperitoneal (53.8%)	13	3.3	176.9	N/R	200	1 (Conversion to open approach)	3 (all CD: II)	2
Kaouk <i>et al.</i> ¹⁵		Transperitoneal (83.3%) Retroperitoneal (17.7%)	6	2.5	240	26	25	None	1 (Pseudoaneurysm underwent angioembolization – CD: IIIa)	1
Shukla <i>et al.</i> ¹⁷		Transperitoneal (100%)	12	3.2	171.6	< 25	68.3	None	None	1.2
Francavilla <i>et al.</i> ¹⁸		Transperitoneal (100%)	14	2.6	202	18	50	None	2 (Postoperative acute bleeding requiring angioembolization – CD: IIIa)	1
Kim <i>et al.</i> ²²		Transperitoneal (100%)	25	N/R	130–280	N/R	30–500	None	None	3–7

CD, Clavien-Dindo; EBL, estimated blood loss; LOS, length of stay; N/R, not reported; N, number of patients; OT, operative time; SP, single-port; WIT, warm ischemia time.

^aOnly SP robotic partial nephrectomy cases are considered, even in series reporting different types of SP robotic procedures.

^bTumor size considered on the pathological sample (pathological tumor size).

^cIt is clarified if it is an intraoperative, postoperative, or overall complication. For postoperative complications, the Clavien-Dindo grade is indicated when reported in the original manuscript.

Interestingly, a number of authors agreed that a learning curve for SP cases does exist, even for surgeons who have an extensive experience with multi-arms platforms. This is mostly associated with the ability to use the new articulating SP camera. The instruments of the SP system provide similar degrees of freedom of standard multi-arms da Vinci platforms, with some differences in intracorporeal suturing (typical of PN). It has been reported that the loss of the EndoWrist technology could mostly affect expert robotic surgeons (with a consistent number of procedures

performed using the earlier multi-arms da Vinci platforms).⁴³

Finally, the SP platform requires accurate coordination between the instruments' and the camera's movements to compensate for the smaller working area and the narrower visual field.¹⁸ It is interesting to underline that expert robotic surgeons reported cases of postoperative acute bleeding (3 cases considering all included studies – Table 2), managed with angioembolization. This is probably relative to the different feelings and tension

Table 3. Collected comparative studies of single-port *versus* multi-port robotic partial nephrectomies.

Reference	Study design	Robotic system	N ^a	Tumor size (cm) ^b	R.E.N.A.L. score (n)	OT (min)	WIT (min)	EBL (mL)	Conversion (n, %)	Complications (n, %) ^c	LOS (days)
Okhawere <i>et al.</i> ¹⁹	Match paired analysis	SP	146	2.8	6^d	142	18	89	N/R	12 (8.2%) ^e	1.2
		MP	146	2.9	7^d	137	13	112	N/R	9 (6.1%) ^e	1.3
Harrison <i>et al.</i> ²⁰		SP	48	2.4	7	102		50	None	None	1
		MP	48	2.2	7	96.5		60	None	1 (2.1%) ^e	1
Glaser <i>et al.</i> ²¹	Time-match analysis	SP	26	3.5	–	183	N/R	8	1 (3.8%)	3 (11.5%) ^e	–
		MP	52	3.3	–	208	N/R	8	5 (9.6%)	3 (5.8%) ^e	–

EBL, estimated blood loss; LOS, length of stay; MP, multi-port; N/R, not reported; N, number of patients; OT, operative time; SP, single-port; WIT, warm ischemia time. R.E.N.A.L., nephrometry score

In bold are reported significantly different outcomes ($p < 0.05$).

^aOnly SP robotic partial nephrectomy cases are considered, even in series reporting different types of single-port robotic procedures.

^bTumor size considered on the pathological sample [pathological tumor size].

^cIt is clarified if it is an intraoperative, postoperative, or overall complication. For postoperative complications, the Clavien-Dindo grade is indicated when reported in the original manuscript.

^dThese values are reported before a match-paired analysis.

^eAny complications.

forces applied during suturing. Such a complication is generally rare within the robotic PN series, especially among expert robotic surgeons.^{14,15,18} At the moment, the literature is unable to suggest a minimum number of procedures to perform before surgeons can feel confident with the technology. Undoubtedly, patient selection is key.

In the setting of a match-paired analysis of 146 SP *versus* 146 standard robotic PN by the ‘Single Port Advanced Robotics Consortium’ (SPARC), Okhawere *et al.*¹⁹ showed that the majority of the SP-robotic PN cases treated (52%) presented with a low tumor complexity. Such lower complexity masses can be more appropriate to start with the SP learning curve. Before matching, the SP group had a lower mean tumor size (2.93 *versus* 3.42 cm, $p = 0.0001$) and a significantly lower median R.E.N.A.L. score (6 *versus* 7, $p < 0.001$). Matching balanced for these differences, with both groups having similar mean tumor size (2.9 cm) and median RENAL nephrometry score of 6. Regarding perioperative outcomes, SP and conventional robotic PN groups had nonsignificantly different operative times, estimated blood loss, overall complications rate (8 *versus* 6%, $p = 0.2$), and length of stay. Notably, when stratifying by tumor complexity, the operative time of

SP-robotic PN procedures for high-complexity renal masses was shorter (108 *versus* 167 min, $p < 0.05$). Finally, notwithstanding the overall low complexity of the renal masses included in the study, SP-robotic PN had a longer mean ischemia time (18.3 *versus* 13.8 min; $p < 0.001$). In summary, although the differences in the port configurations and the surgical technique/approach used typically of a multicentric design represented a limitation of the analysis, the SPARC analysis showed that SP-robotic PN is a safe procedure in the hands of expert robotic surgeons.¹⁹

Similarly, Harrison *et al.*²⁰ compared the perioperative and short-term functional and oncological outcomes of SP-robotic *versus* multi-arms robotic PN by a propensity-score analysis. Before matching, the cohort included 48 and 238 patients who underwent SP and multi-arms procedures, respectively. This study overstressed the concept that one major strong point of the SP system was decreased postoperative pain, which theoretically avoids (or at least decreases) the need for opioids after surgery.²⁰ While there was only a subtle difference in terms of median length of stay (1.4 *versus* 1.6 days, $p = 0.004$), following 1:1 propensity-score matching, the SP cohort had

lower opioids use both on postoperative day 1 (4.6 *versus* 9.8 morphine milligram equivalents [MME], $p=0.02$) and cumulative during the in-hospital stay (5.1 *versus* 9.3 MME, $p=0.03$).

Conversely, other groups published different experiences reporting a similar length of stay (the vast majority of patients were discharged on postoperative day 1) and without any differences in the MME administered either during the hospitalization or in the outpatient setting.²¹ The reader will argue that such differences are ‘relevant’ from a statistical point of view rather than from a clinical one.^{20,21} Another explanation for the lack of relevant differences between SP and conventional multi-arms robotic PN is that a number of centers worldwide already use a same-day/overnight discharge pattern after robotic PN. Thus, even if SP-robotic can decrease the number of skin incisions and the relative pain associated, we can conclude that robotic PN has achieved a high standard whatever the platform used.⁴⁴

Focus on length of stay after SP-robotic PN

It is a common feeling in the literature that a potential benefit of SP-robotics is the chance to more likely consider a same-day discharge pattern after surgery. Promising results have been reported by various single-center studies both on PN and other surgical interventions.^{45,46} Abaza *et al.*⁴⁵ assessed the impact of the adoption of the SP-dedicated platform on the length of stay after their initial 100 SP procedures (performed between 2019 and 2020). Their series was also compared to a cohort of ‘conventional’ robotic PN cases.

Note, Abaza *et al.*⁴⁵ routinely offer same-day/overnight discharge after robotic procedures performed at their Institution since 2016, which means they have consolidated an outpatient pathway even before the advent of the SP platform. The SP group evaluated included 59 prostatectomies, 18 PNs, and other procedures. Interestingly, the rate of same-day discharge in the SP group was higher compared to multi-arms surgeries, despite the authors declaring they equally offer this discharge pattern to all patients (88% *versus* 51%, $p<0.0001$). Specifically, among PN patients, 83% of SP patients went home the same day of surgery *versus* 17% of multi-arms cases ($p<0.001$).

On the other hand, we remark that other series analyzed such discharge patterns after urological robotic procedures underlying that the same-day discharge is feasible even when using the multi-arms robotic platforms.⁴⁴

In the setting of a bi-centric USA experience that reported the outcomes of robotic PN cases performed between 2010 and 2019 by using multi-arms robotic platforms, 173 (60.5%) patients who were discharged on the first postoperative day had lower BMI (29 *versus* 32, $p=0.02$), were more likely treated *via* a retroperitoneal approach (13 *versus* 9%, $p<0.001$), and had lower rates of overall (3.6 *versus* 30.5%, $p<0.001$) and major (Clavien-Dindo grade \geq III) postoperative complications (1.8 *versus* 6.1%, $p<0.001$). Logistic regression analysis found operative time and the occurrence of a postoperative complication as independent predictors of prolonged hospital stay.

A concept always stressed at congresses and meetings by Jihad Kaouk, the first adopter of the SP platform, is that the purpose-built SP robot allows for ‘*regionalizing the surgery to the location of the disease*’, leading to a ‘*minimal impact surgery*’ Simone Crivellaro says. For example, it is interesting to note how surgeons performing SP-robotic PN are more likely to choose a retroperitoneal approach, which in many series has been associated with a shorter length of stay.^{19,20,47} This finding is likely due to one of the key features of the SP robot, which is well suited to work within narrow spaces such as the retroperitoneum, facilitates access and docking, and reduces the need for dissecting several anatomical structures before performing the resection of the renal mass.⁴⁸

Hospital stay and cost-effectiveness

To date, no study compared SP-robotic *versus* multi-arms robotic PN in cost-effectiveness. The restriction in terms of financial resources of the health systems brings an honest and deep reflection on the costs. It can be considered a priority and should be a crucial component of the approval process for any medical innovation/technology, especially in surgery. Innovations in surgery often require the use of expensive equipment which required a careful demonstration of their feasibility, safety, and health benefits, as well as cost-effectiveness. Likewise, the use of the da Vinci SP

as a dedicated surgical instrument for PN cases will have to be assessed and compared financially to the standard of care.

SP robotic partial nephrectomy: technical details and main differences with the multi-port robotic system

The SP system presents a number of intrinsic key differences compared to the multi-arms platforms that necessarily lead to some modifications in the PN technique.^{11,19,43}

The fully wristed camera and its ‘cobra’ mode, together with the possibility of an en-bloc rotation of all the instruments, allow for the optimal vision of the target anatomy and are unique to the SP platform. As we already mentioned before, the instruments of the SP surgical system allow degrees of freedom comparable to those of the standard multiport da Vinci platforms, but differences can be perceived, particularly during the renorrhaphy phase of PN, because of the novel elbow, so that the dynamics of suturing is modified. Moreover, the reader should keep in mind that the SP platform lacks the EndoWrist technology.

From a technical point of view, by utilizing the ‘Hasson technique’, a 2- to 2.5-cm fascial opening is performed to place the cannula with a blunt obturator directly through it. Otherwise, it can be practiced a slight extension of the incision with the aim of accommodating adjacent additional ports and instruments. Moreover, a gel cap such as the GelPORT (Applied Medical, Rancho Santa Margarita, CA) can also be used (Figure 4(a) and (b)).

For a transperitoneal approach, allocating the port on the umbilicus may provide a muscle-sparing incision. It can also be further extended to extract the specimen. The whole instruments and the robotic camera are put in place through the multichannel SP port. Interestingly, the latest SP system requires a 10-cm working distance between the port site and the target anatomy.¹⁹ With shorter distances, there will not be an unfold of the robotic instruments and the full range of motion. It is common when patients have thin body habitus as well as large masses at the lower pole approached retroperitoneally. Two solutions are generally used to manage this aspect: the first one is to allocate the ports far away from the target anatomy (which is not always possible in the case of large masses approached *via* a retroperitoneal route); the

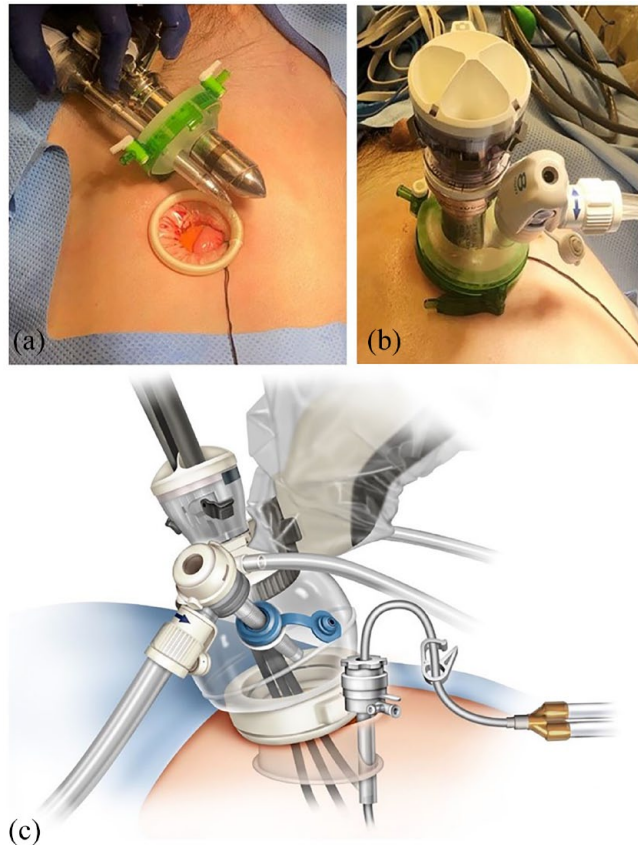


Figure 4. (a, b) The dedicated SP multichannel cannula and an assistant port are introduced through the same incision *via* a wound protector GelPORT. (c) Sketch of the concept of ‘floating docking’ aimed to increase the working distance needed from the port site and the target anatomy.

second one is the so-called floating docking technique, which consists in moving the seal of the wound protector system, through which the trocars are placed, further from the skin level (Figure 4(c)).^{19,49}

Concerning the assistant port, this can be allocated just adjacent to the SP cannula but is ‘hand-cuffed’ to it having restricted maneuverability.¹⁹

Limitations in suction should be overcome using a flexible suction catheter managed by the operator, like the ‘Remotely Operated Suction Irrigation System’ (ROSI, VTI, Nashua, NHI), which is normally allocated through the adjacent assistant port through the same cut or the fourth channel of the SP cannula if the fourth arm instruments are not used.

At present, the SP instruments’ armamentarium is restricted in its scope with respect to that of the multi-arms X and Xi platform.^{50,51} For instance,

the ProGrasp™ forceps are not currently available, as well as cutting-edge energy devices like the Vessel-sealer and large clip applier. Furthermore, near-infrared fluorescence is not on the market yet.

Another limitation is due to the fact that most of the series published about SP robotic procedures (including SP -robotic PN) had been affected by the recent COVID-19 pandemic that could have limited the diffusion and utilization of the SP robotic platform. However, a number of centers had used some strategies to minimize the impact of the worldwide pandemic.⁵²

Conclusion

The SP-robotic approach to PN appears to be feasible and safe. The preliminary reports about perioperative outcomes are encouraging and at least noninferior to those from the multi-arms series. We believe that the continued use of the platform is justified in centers where the technology is available. Well-designed comparative studies with long-term oncologic and functional results will be necessary to draw more definitive conclusions and better establish the future role and appropriate indications of the SP platform.

Declarations

Ethics approval and consent to participate

Not applicable.

Consent for publication

Not applicable.

Author contributions

Umberto Carbonara: Conceptualization; Data curation; Formal analysis; Funding acquisition; Investigation; Methodology; Project administration.

Daniele Amparore: Writing – review & editing.

Leonardo D. Borregales: Writing – review & editing.

Anna Calìo: Writing – review & editing.

Chiara Ciccacese: Writing – review & editing.

Pietro Diana: Writing – review & editing.

Selcuk Erdem: Writing – review & editing.

Laura Marandino: Writing – review & editing.

Michele Marchioni: Writing – review & editing.

Constantijn H.J. Muselaers: Writing – review & editing.

Carlotta Palumbo: Writing – review & editing.

Nicola Pavan: Writing – review & editing.

Angela Pecoraro: Writing – review & editing.

Eduard Roussel: Writing – review & editing.

Hannah Warren: Writing – review & editing.

Zhen-Jie Wu: Writing – review & editing.

Riccardo Campi: Data curation; Methodology; Supervision; Writing – review & editing.

Riccardo Bertolo: Conceptualization; Data curation; Investigation; Methodology; Project administration; Supervision; Writing – original draft; Writing – review & editing.

Acknowledgements

None.

Funding

The authors received no financial support for the research, authorship, and/or publication of this article.

Competing interests

The authors declared no potential conflicts of interest with respect to the research, authorship, and/or publication of this article.

Availability of data and materials

Not applicable.

ORCID iDs

Umberto Carbonara  <https://orcid.org/0000-0002-3179-630X>

Selcuk Erdem  <https://orcid.org/0000-0002-3514-1394>

Riccardo Campi  <https://orcid.org/0000-0001-5237-0888>

References


1. Porpiglia F, Mari A, Bertolo R, *et al.* Partial nephrectomy in clinical T1b renal tumors:

- multicenter comparative study of open, laparoscopic and robot-assisted approach (the RECORD project). *Urology* 2016; 89: 45–51.
2. You C, Du Y, Wang H, *et al.* Laparoscopic versus open partial nephrectomy: a systemic review and meta-analysis of surgical, oncological, and functional outcomes. *Front Oncol* 2020; 10: 583979.
 3. White WM, Haber GP, Goel RK, *et al.* Single-port urological surgery: single-center experience with the first 100 cases. *Urology* 2009; 74: 801–804.
 4. Raman JD, Bensalah K, Bagrodia A, *et al.* Laboratory and clinical development of single keyhole umbilical nephrectomy. *Urology* 2007; 70: 1039–1042.
 5. Gill IS, Advincula AP, Aron M, *et al.* Consensus statement of the consortium for laparoendoscopic single-site surgery. *Surg Endosc* 2010; 24: 762–768.
 6. Kaouk JH, Goel RK, Haber GP, *et al.* Robotic single-port transumbilical surgery in humans: initial report. *BJU Int* 2009; 103: 366–369.
 7. Kaouk JH, Haber GP, Autorino R, *et al.* A novel robotic system for single-port urologic surgery: first clinical investigation. *Eur Urol* 2014; 66: 1033–1043.
 8. Carbonara U, Simone G, Capitanio U, *et al.* Robot-assisted partial nephrectomy: 7-year outcomes. *Minerva Urol Nefrol* 2021; 73: 540–543.
 9. Joseph RA, Goh AC, Cuevas SP, *et al.* ‘Chopstick’ surgery: a novel technique improves surgeon performance and eliminates arm collision in robotic single-incision laparoscopic surgery. *Surg Endosc* 2010; 24: 1331–1335.
 10. Nelson RJ, Chavali JSS, Yerram N, *et al.* Current status of robotic single-port surgery. *Urol Ann* 2017; 9: 217–222.
 11. Bertolo R, Garisto J, Gettman M, *et al.* Novel system for robotic single-port surgery: feasibility and state of the art in urology. *Eur Urol Focus* 2018; 4: 669–673.
 12. Bertolo R, Cipriani C, Garisto J, *et al.* Single-port versus multi-port: will ‘one for all’ ever become a new standard for robot-assisted radical prostatectomy? *J Robot Surg* 2020; 15: 143–145.
 13. Kaouk JH and Bertolo R. Single-site robotic platform in clinical practice: first cases in the USA. *Minerva Urol Nefrol* 2019; 71: 294–298.
 14. Kaouk J, Garisto J, Eltemamy M, *et al.* Pure single-site robot-assisted partial nephrectomy using the SP surgical system: initial clinical experience. *Urology* 2019; 124: 282–285.
 15. Kaouk J, Aminsharifi A, Sawczyn G, *et al.* Single-port robotic urological surgery using purpose-built single-port surgical system: single-institutional experience with the first 100 cases. *Urology* 2020; 140: 77–84.
 16. Fang AM, Saidian A, Magi-Galluzzi C, *et al.* Single-port robotic partial and radical nephrectomies for renal cortical tumors: initial clinical experience. *J Robot Surg* 2020; 14: 773–780.
 17. Shukla D, Small A, Mehrazin R, *et al.* Single-port robotic-assisted partial nephrectomy: initial clinical experience and lessons learned for successful outcomes. *J Robot Surg* 2021; 15: 293–298.
 18. Francavilla S, Abern MR, Dobbs RW, *et al.* Single-port robot assisted partial nephrectomy: initial experience and technique with the da Vinci single-port platform (IDEAL phase 1). *Minerva Urol Nefrol* 2022; 74: 216–224.
 19. Okhawere KE, Beksac AT, Wilson MP, *et al.* A propensity-matched comparison of the perioperative outcomes between single-port and multi-port robotic assisted partial nephrectomy: a report from the single port advanced research consortium (SPARC). *J Endourol* 2022; 36: 1526–1531.
 20. Harrison R, Ahmed M, Billah M, *et al.* Single-port versus multiport partial nephrectomy: a propensity-score-matched comparison of perioperative and short-term outcomes. *J Robot Surg* 2023; 17: 223–231.
 21. Glaser ZA, Burns ZR, Fang AM, *et al.* Single-versus multi-port robotic partial nephrectomy: a comparative analysis of perioperative outcomes and analgesic requirements. *J Robot Surg* 2022; 16: 695–703.
 22. Kim KH, Ahn HK, Kim M, *et al.* Technique and perioperative outcomes of single-port robotic surgery using the da Vinci SP platform in urology. *Asian J Surg* 2023; 46: 472–477.
 23. Autorino R, Cadeddu JA, Desai MM, *et al.* Laparoendoscopic single-site and natural orifice transluminal endoscopic surgery in urology: a critical analysis of the literature. *Eur Urol* 2011; 59: 26–45.
 24. Pelosi MA and Pelosi MA 3rd. Laparoscopic hysterectomy with bilateral salpingo-oophorectomy using a single umbilical puncture. *N J Med* 1991; 88: 721–726.
 25. Rane A, Rao P and Rao P. Clinical evaluation of a novel laparoscopic port (R-PORTTM) in urology and evolution of the single laparoscopic

- port procedure (SLIPP) and one port umbilical surgery (OPUS). *Eur Urol Suppl* 2008; 7: 193.
26. Kaouk JH, Autorino R, Kim FJ, *et al.* Laparoendoscopic single-site surgery in urology: worldwide multi-institutional analysis of 1076 cases. *Eur Urol* 2011; 60: 998–1005.
 27. Autorino R, Kaouk JH, Stolzenburg JU, *et al.* Current status and future directions of robotic single-site surgery: a systematic review. *Eur Urol* 2013; 63: 266–280.
 28. Haber GP, White MA, Autorino R, *et al.* Novel robotic da Vinci instruments for laparoendoscopic single-site surgery. *Urology* 2010; 76: 1279–1282.
 29. Kaouk JH, Autorino R, Laydner H, *et al.* Robotic single-site kidney surgery: evaluation of second-generation instruments in a cadaver model. *Urology* 2012; 79: 975–979.
 30. Cestari A, Buffi NM, Lista G, *et al.* Feasibility and preliminary clinical outcomes of robotic laparoendoscopic single-site (R-LESS) pyeloplasty using a new single-port platform. *Eur Urol* 2012; 62: 175–179.
 31. Mathieu R, Verhoest G, Vincendeau S, *et al.* Robotic-assisted laparoendoscopic single-site radical nephrectomy: first experience with the novel Da Vinci single-site platform. *World J Urol* 2014; 32: 273–276.
 32. Fiori C, Bertolo R, Manfredi M, *et al.* Robot-assisted laparoendoscopic single-site versus mini-laparoscopic pyeloplasty: a comparison of perioperative, functional and cosmetic results. *Minerva Urol Nefrol* 2017; 69: 604–612.
 33. Kaouk JH, Sagalovich D and Garisto J. Robot-assisted transvesical partial prostatectomy using a purpose-built single-port robotic system. *BJU Int* 2018; 122: 520–524.
 34. Ramirez D, Maurice MJ and Kaouk JH. Robotic perineal radical prostatectomy and pelvic lymph node dissection using a purpose-built single-port robotic platform. *BJU Int* 2016; 118: 829–833.
 35. Garisto JD, Bertolo R and Kaouk J. Technique for docking and port placement using a purpose-built robotic system (SP1098) in Human Cadaver. *Urology* 2018; 119: 91–96.
 36. Garisto J, Bertolo R, Chan E, *et al.* Single-port trans-perineal approach to cystoprostatectomy with intracorporeal ileal conduit urinary diversion and lymph-nodes dissection using a purpose-built robotic system: surgical steps in a preclinical model. *Int Braz J Urol* 2019; 45: 854–855.
 37. Garisto J, Bertolo R and Kaouk J. Transperineal approach for intracorporeal ileal conduit urinary diversion using a purpose-built single-port robotic system: step-by-step. *Urology* 2018; 122: 179–184.
 38. Maurice MJ, Ramirez D and Kaouk JH. Robotic laparoendoscopic single-site retroperitoneal renal surgery: initial investigation of a purpose-built single-port surgical system. *Eur Urol* 2017; 71: 643–647.
 39. Tiu A, Shin TY, Kim KH, *et al.* Robotic laparoendoscopic single-site transumbilical partial nephrectomy: functional and oncologic outcomes at 2 years. *Urology* 2013; 82: 595–599.
 40. Fan X, Lin T, Xu K, *et al.* Laparoendoscopic single-site nephrectomy compared with conventional laparoscopic nephrectomy: a systematic review and meta-analysis of comparative studies. *Eur Urol* 2012; 62: 601–612.
 41. Lee WJ, Arkoncel FR, Rha KH, *et al.* Urologic robot-assisted laparoendoscopic single-site surgery using a homemade single-port device: a single-center experience of 68 cases. *J Endourol* 2011; 25: 1481–1485.
 42. Komninos C, Shin TY, Tuliao P, *et al.* R-LESS partial nephrectomy trifecta outcome is inferior to multiport robotic partial nephrectomy: comparative analysis. *Eur Urol* 2014; 66: 512–517.
 43. Kaouk J, Garisto J and Bertolo R. Robotic urologic surgical interventions performed with the single port dedicated platform: first clinical investigation. *Eur Urol* 2019; 75: 684–691.
 44. Carbonara U, Lee J, Crocero F, *et al.* Single overnight stay after robot-assisted partial nephrectomy: a bi-center experience. *Minerva Urol Nefrol* 2021; 73: 773–780.
 45. Abaza R, Murphy C, Bsate A, *et al.* Single-port robotic surgery allows same-day discharge in majority of cases. *Urology* 2021; 148: 159–165.
 46. Wilson CA, Aminsharifi A, Sawczyn G, *et al.* Outpatient extraperitoneal single-port robotic radical prostatectomy. *Urology* 2020; 144: 142–146.
 47. Carbonara U, Crocero F, Campi R, *et al.* Retroperitoneal robot-assisted partial nephrectomy: a systematic review and pooled analysis of comparative outcomes. *Eur Urol Open Sci* 2022; 40: 27–37.
 48. Carbonara U, Eun D, Derweesh I, *et al.* Retroperitoneal versus transepritoneal robot-assisted partial nephrectomy for postero-lateral

- renal masses: an international multicenter analysis. *World J Urol* 2021; 39: 4175–4182.
49. Sentell KT, Badani KK, Paulucci DJ, *et al.* A single overnight stay after robotic partial nephrectomy does not increase complications. *J Endourol* 2019; 33: 1003–1008.
50. Cisu T, Crocero F, Carbonara U, *et al.* New robotic surgical systems in urology: an update. *Curr Opin Urol* 2021; 31(1): 37–42.
51. Veccia A, Carbonara U, Derweesh I, *et al.* Single-stage Xi® robotic radical nephroureterectomy for upper tract urothelial carcinoma: surgical technique and outcomes. *Minerva Urol Nephrol* 2022; 74(2): 233–241.
52. Quarto G, Grimaldi G, Castaldo L, *et al.* Avoiding disruption of timely surgical management of genitourinary cancers during the early phase of the COVID-19 pandemic. *BJU Int* 2020; 126(4): 425–427.

Visit SAGE journals online
[journals.sagepub.com/
home/tau](https://journals.sagepub.com/home/tau)

 SAGE journals