

RESEARCH

Open Access



Acute vascular complications of femoral veno-arterial ECMO: a single-centre retrospective study

Mohamed Laimoud^{1,2*} , Elias Saad¹ and Samer Koussayer^{3,4}

Abstract

Background: Femoral arterial cannulation to initiate veno-arterial ECMO may result in ipsilateral limb ischemia due to reduced distal blood flow below the insertion point of the cannula. We retrospectively studied adult patients supported with femoral VA-ECMO for cardiogenic shock between 2015 and 2019 at our tertiary care hospital.

Results: The study included 65 adult patients supported with femoral VA-ECMO for refractory cardiogenic shock. The studied patients had a mean age of 37.9 ± 14.87 years, mostly males (70.8%), a mean BSA of 1.77 ± 0.27 m², and a mean BMI of 26.1 ± 6.7 kg/m². Twenty-one (32.3%) patients developed acute lower limb ischemia. The patients who developed acute limb ischemia had significantly frequent AKI ($p < 0.001$) without significant use of haemodialysis ($p = 0.07$) and longer ICU stay ($p = 0.028$) compared to the patients without limb ischemia. The hospital mortality occurred in 29 (44.6%) patients without significant difference between the patients with and without acute limb ischemia. The occurrence of acute limb ischemia was significantly correlated with failed percutaneous cannulation ($p = 0.039$), while there was no significant statistical correlation between the cut-down technique and occurrence of limb ischemia ($p = 0.053$). The occurrence of femoral cannulation site bleeding was significantly correlated with failed percutaneous cannulation ($p = 0.001$) and cut-down technique ($p = 0.001$).

Conclusion: Acute vascular complications are frequent after femoral VA-ECMO. Failed percutaneous femoral cannulation has been, in this study, identified as the most important risk factor for acute limb ischemia and cannulation site bleeding. A careful approach during femoral cannulation is recommended to prevent occurrence of acute limb ischemia and femoral cannulation site bleeding.

Keywords: Veno-arterial ECMO, Femoral, Limb ischemia, Percutaneous cannulation, Ultrasound, Cut-down

Background

Emergent veno-arterial extracorporeal membrane oxygenation (VA-ECMO) is increasingly used to provide rapid cardiopulmonary resuscitation in adult patients with refractory cardiogenic shock [1–3]. The emergent nature of the haemodynamics deterioration, as in cardiac arrest or post-cardiotomy shock conditions, makes

peripheral ECMO initiation via femoral vessels the preferred approach. Either percutaneous or surgical cut-down approaches are being used for emergent femoral cannulation to initiate VA-ECMO support [4, 5]. Femoral arterial cannulation may result in ipsilateral limb ischemia due to reduced distal blood flow below the insertion point of the cannula [6–8]. Recent studies have demonstrated that the development of acute limb ischemia had a bad impact on patient mortality and quality of life of the survivors after ECMO decannulation [9, 10]. We conducted this retrospective study to report and analyse the vascular complications of peripheral VA-

* Correspondence: mlaimoud@kfshrc.edu.sa; m.laimoud@cu.edu.eg; m.laimoud@hotmail.com

¹Adult Cardiac Surgical Intensive Care Department, King Faisal Specialist Hospital & Research Center, Riyadh, Saudi Arabia

²Critical Care Medicine Department, Cairo University, Cairo, Egypt

Full list of author information is available at the end of the article

ECMO in the adult patients with cardiogenic shock in our tertiary care hospital.

Methods

The study design

The ethics committee board of our institute approved this retrospective study. We included adult patients who were supported with femoral veno-arterial ECMO for cardiogenic shock between 2015 and 2019 at our tertiary care hospital. The enrolled patients were divided according to occurrence of acute lower limb ischemia into 2 groups. The hospital electronic database was used to get the clinical and laboratory variables of studied patients. We assessed the studied patients using SOFA score upon ICU admission and then at the third and fifth days. The $\Delta 1$ SOFA was the difference between SOFA scores at third and admission days. The $\Delta 2$ SOFA was the difference between SOFA scores at the fifth and admission days [11–13].

The femoral cannulation technique

The femoral arterial and venous cannulations were done via either percutaneous or cut-down approaches according to the surgeons preferences. Seldinger technique was used to cannulate the femoral vein and a 19–23-Fr cannula was introduced over a guidewire till the inferior vena cava (IVC). The common femoral artery was similarly cannulated with a 15–19-Fr cannula. Insertion of an additional distal 6-Fr cannula was also performed to preserve lower limb perfusion in most of enrolled patients. The selection of type and size of the arterial cannula was selected according to the patient's body surface area (BSA) and the required ECMO flow which is equivalent to a cardiac index (CI) of 2.2–2.5 L/m²/min [14].

The ECMO management and decannulation protocol

After VA-ECMO initiation, the blood flow was adjusted based on clinical evaluation including mean arterial blood pressure, urine output, clearance of blood hyperlactatemia, and mixed venous oxygen saturation. Titration of oxygen and sweep flows was gradually done to achieve acceptable blood gases. Minimization of the doses of vasopressors intravenous infusions was done to decrease risk of limb ischemia. Anticoagulation was done via intravenous heparin infusion which was adjusted according to heparin assay (target 0.3–0.7 units/ml), antithrombin (AT) III (goal 80–120%), and clinical tolerance. Platelets transfusion to keep count more than 50 (10⁹/L), packed red blood corpuscles transfusion to maintain the haemoglobin level above 80 (gm/L) were done. Monitoring of the lower limbs perfusion was routinely done by clinical and Doppler ultrasound assessments. The clinical assessment includes skin

temperature and appearance to detect any coldness, pallor or mottling compared to contralateral limb, and cannulation site bleeding or haematoma. Doppler ultrasound assessment was used to detect the peak systolic velocity of dorsalis pedis and posterior tibial arteries. Near-infrared spectroscopy (NIRS) monitoring is routinely applied to all patients with femoral VA-ECMO to provide continuous monitoring cerebral oxygenation via bilateral frontal probes. Also, NIRS was used in patients with suspected limb impaired perfusion via limb probes. NIRS was proved to be effective in continuous monitoring of limb regional oxygen saturation even with absence of pulsatile flow [15, 16]. For any suspicion of limb ischemia, complete involvement of vascular surgery team was done. Removal of femoral cannulae was done after exposing the femoral vessels. The femoral vessels were primarily repaired. In case of limb ischemia, vascular surgical interventions were done including thrombectomy and angioplasty. Fasciotomy was done in case of acute leg compartmental syndrome.

The statistical analysis

Data was coded and entered using the Statistical Package for the Social Sciences (SPSS) version 26 (IBM Corp., Armonk, NY, USA). Data was presented using mean (\pm standard deviation) or median (interquartile range) in quantitative data and using frequency (and percentage) for categorical data. Comparisons between quantitative variables were done using the Mann-Whitney test. For comparing categorical data, Chi square (χ^2) test was performed. Graphs were used to illustrate some information. *p* values less than 0.05 were considered statistically significant.

Results

Baseline clinical variables of studied patients

The study included 65 adult patients supported with femoral VA-ECMO for refractory cardiogenic shock. The studied patients had a mean age of 37.9 \pm 14.87 years, mostly males (70.8%), a mean BMI of 26.1 \pm 6.7 kg/m² and a mean BSA of 1.77 \pm 0.27 m². Twenty-one (32.3%) patients developed acute lower limb ischemia. There were no statistically significant differences between the patients with and without limb ischemia regarding demographic data, clinical variables, size of ECMO cannulae, prophylactic distal perfusion cannula (DPC) insertion ultrasound-guided approach, and cut-down approaches. Failed percutaneous cannulae insertion was statistically significant in the patients who developed acute limb ischemia (Table 1).

The vascular complications of studied patients

Femoral thrombectomy and angioplasty were done in 20 (30.8%) patients. Four (6.2%) patients developed limb

Table 1 Baseline clinical variables of the VA-ECMO-supported patients

Studied criteria	All patients (n = 65)	Limb ischemia group (n = 21)	No limb ischemia group (n = 44)	P value
Age (years)	37.9 ± 14.87	34.4 ± 12.3	39.6 ± 15.8	0.19
Sex				
Males	46 (70.8)	18 (85.7)	28 (63.6)	0.06
Females	19 (29.2)	3 (14.3)	16 (36.4)	
Weight (kg)	70.88 ± 20.9	70.6 ± 23.4	71 ± 19.9	0.61
Height (cm)	164.68 ± 8.1	164.57 ± 6.3	164.7 ± 8.9	0.83
BMI (kg/m ²)	26.08 ± 6.7	26.04 ± 7.7	26.11 ± 6.4	0.43
BSA (m ²)	1.77 ± 0.27	1.76 ± 0.29	1.78 ± 0.27	0.54
Diabetes mellitus	13 (20)	5 (23.8)	8 (18.2)	0.74
Hypertension	18 (27.7)	5 (23.8)	13 (29.5)	0.62
Pre-ECMO AF	17 (26.2)	4 (19)	13 (29.5)	0.36
Anticoagulants intake	18 (27.7)	5 (23.8)	13 (29.5)	0.62
Aspirin intake	3 (4.6)	1 (4.8)	2 (4.5)	1
Left ventricle EF	26.75 ± 13.4	26.14 ± 12.1	27.1 ± 14.2	0.81
CKD	10 (15.4)	5 (23.8)	5 (11.4)	0.27
Previous CVS	2 (3.1)	1 (4.8)	1 (2.3)	0.54
Cardiothoracic surgery	17 (26.2)	6 (28.6)	11 (25)	0.75
IABP	13 (20)	4 (19)	9 (20.5)	1
Percutaneous cannula insertion				
Successful	36 (55.4)	8 (38.1)	28 (63.6)	0.039
Failed	19 (29.2)	10 (47.6)	9 (20.5)	
Not tried	10 (15.4)	3 (14.3)	7 (15.9)	
US-guided cannula insertion	32 (49.2)	7 (33.3)	25 (56.8)	0.07
Femoral cut-down	29 (44.6)	13 (61.9)	16 (36.4)	0.053
Insertion at operation room	30 (46.2)	13 (61.9)	17 (38.6)	0.078
Arterial cannula size (Fr)	17.85 ± 1.4	18.05 ± 1.36	17.75 ± 1.43	0.77
Venous cannula size (Fr)	21.72 ± 1.3	21.6 ± 1.59	21.7 ± 1.22	0.82
Distal perfusion cannula	52 (80)	15 (71.4)	37 (84.1)	0.32
Cannulation site bleeding	16 (24.6)	6 (28.6)	10 (22.7)	0.6
Cannulation bleeding required exploration	4 (6.3)	1 (4.8)	3 (6.8)	1

Data are presented as number (%) or mean (± SD)

compartmental syndrome and fasciotomy was done. Amputation of toes was done in one patient. The vascular complications included femoral arteriovenous fistula after ECMO decannulation and required vascular surgical repair in one patient. Femoral large pseudo-aneurysm occurred in one patient and required surgical intervention after ECMO decannulation. Three (4.6%) patients developed chronic limb ischemia manifestations during follow-up. Femoral wound infection occurred in 2 (3.1%) patients and complicated the healing process and required sartolius muscle flapping (Table 2, Fig. 1).

Laboratory criteria of studied VA-ECMO-treated patients

The patients who develop limb ischemia had significantly higher INR (1.9 (1.4–3.2) vs 1.4 (1.1–3.6), $p = 0.004$) and AT III level (69 (27–88) vs 55.5 (42–73), $p = 0.002$) at time of ECMO initiation compared to those

Table 2 The vascular complications of the studied patients

The vascular complications	Number (%)
Acute limb ischemia	21 (32.3)
Thrombectomy	20 (30.8)
Angioplasty	20 (30.8)
Fasciotomy	4 (6.2)
Toes amputation	1 (1.5)
Cannulation site bleeding	16 (24.6)
Cannulation bleeding required exploration	4 (6.3)
Femoral arteriovenous fistula	1 (1.5)
Femoral pseudo-aneurysm	1 (1.5)
Ipsilateral chronic limb ischemia	3 (4.6)
Groin wound grafting	2 (3.1)

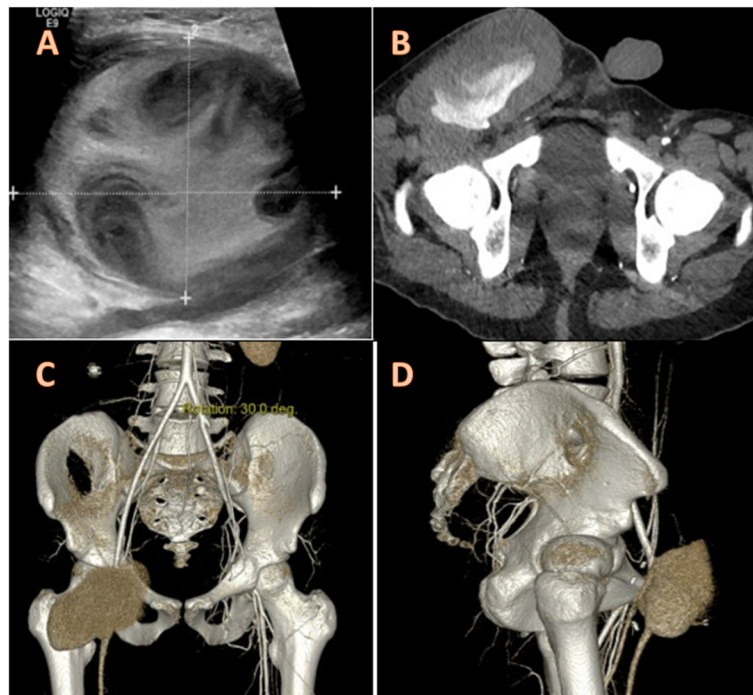


Fig. 1 A 21-year-old male patient developed acute right groin swelling after right femoral ECMO decannulation. Groin US revealed a large swelling (7 × 5 cm) with heterogenous echogenicity in the right groin area arising from right femoral artery with the neck measuring 0.6 cm (a). CT angiography revealed the large pseudo-aneurysm (12 × 6 cm) from the right common femoral artery with active contrast extravasation (b). Multiplanar reconstruction and advanced 3-D postprocessing were performed and revealed the large pseudo-aneurysm with good distal arterial flow (c, d). Vascular surgery was done with evacuation of the pseudo-aneurysm and repair of the femoral artery

Table 3 Laboratory criteria of the studied VA-ECMO-treated patients

Studied criteria	All patients	Limb ischemia group	No limb ischemia group	P value
Haemoglobin (g/L)	111 (88–166)	105 (88–153)	111 (88–166)	0.9
Platelet count (10 ⁹ /L)	181 (38–447)	160 (112–329)	215 (38–447)	0.32
INR	1.6 (1.1–3.6)	1.9 (1.4–3.2)	1.4 (1.1–3.6)	0.004
aPTT (seconds)	42.2 (31.3–150)	48.2 (33.9–150)	41.3 (31.3–74.3)	0.06
PTT ratio	1.2 (0.9–4.4)	1.4 (1–4.4)	1.2 (0.9–2.2)	0.13
Fibrinogen (g/L)	3.16 (0.76–6.87)	2.38 (0.76–6.87)	3.39 (1.37–6.06)	0.28
Antithrombin III	58 (27–88)	69 (27–88)	55.5 (42–73)	0.002
Serum creatinine (μmol/L)	91 (9.5–320)	115 (48–298)	81 (9.5–320)	0.01
Serum albumin (g/L)	32.2 (18.3–44.1)	37.4 (22.2–44.1)	31.1 (18.3–44.1)	0.04
Serum bilirubin (μmol/L)	28.6 (5.8–389)	58.7 (5.8–79.7)	53.5 (7.5–389)	0.71
PH	7.17 (6.9–7.34)	7.12 (6.9–7.34)	7.20 (6.9–7.34)	0.69
Base excess	− 9.3 (− 18.6 to − 4.8)	− 11.2 (− 18.6 to − 5.3)	− 8.25 (− 16.4 to − 4.8)	0.25
Blood lactate (mmol/L)	4.8 (2.4–12.4)	4.8 (3.6–12.4)	5.2 (2.4–10.7)	0.91
Peak blood lactate	13.2 (6.7–20)	13.2 (7.4–20)	11.2 (6.7–20)	0.08
Blood lactate at 24 h	3.1 (1.1–20)	3.1 (1.1–14.3)	2.9 (1.1–20)	0.27

Data are presented as median (IQR)

who did not develop ischemia. The serum creatinine was 115 (48–298) vs 81 (9.5–320) ($p = 0.01$), while the serum albumin was 37.4 (22.2–44.1) vs 31.1 (18.3–44.1) ($p = 0.04$) in the limb ischemia and no limb ischemia groups, respectively. There were no significant differences between both groups regarding other laboratory variables including degree of lactic acidosis and lactate clearance after 24 h of ECMO support (Table 3).

Hospital course of studied VA-ECMO-treated patients

The hospital mortality occurred in 29 (44.6%) patients without significant difference between both groups. The patients who developed acute limb ischemia had significantly frequent acute kidney injury (AKI) (< 0.001) without significant use of haemodialysis ($p = 0.07$) and longer ICU stay ($p = 0.028$) compared to the patients without limb ischemia. The median initial SOFA score was 10 (8–21) vs 14 (8–21) ($p = 0.008$) in the limb ischemia and no limb ischemia groups, respectively, without significant differences in the follow-up Δ SOFA scores at the third and fifth days. There were no significant differences between both groups regarding cerebrovascular strokes, gastrointestinal bleeding, occurrence of new AF, ECMO, and ventilator days (Table 4).

The occurrence of acute limb ischemia was significantly correlated with failed percutaneous femoral cannulation ($p = 0.039$) as failed insertion occurred in 47.6% vs 20.5%, while successful insertion occurred in 38.1% vs 63.6% in the patients with and without limb ischemia, respectively. There was no significant statistical correlation between the cut-down technique and occurrence of limb ischemia ($p = 0.053$). The occurrence of femoral cannulation site bleeding was significantly correlated with failed percutaneous cannulation ($p = 0.001$) and cut-down technique ($p = 0.001$). Failed percutaneous insertion occurred in 62.5% vs 18.4%, while the cut-down technique was done in 81.3% vs 32.7% of the patients with and without cannulation site bleeding, respectively (Tables 1 and 5, Figs. 2 and 3).

Discussion

We retrospectively analysed our adult patients who had femoral VA-ECMO support for refractory cardiogenic shock including post-cardiotomy shock in 26.2% of patients. We observed acute lower limb ischemia in 32.3% of cases and cannulation site bleeding in 24.6% of cases while bleeding required vascular exploration happened in 6.3% of cases. We reviewed the recent literature about

Table 4 Hospital course of the studied VA-ECMO-treated patients

Studied criteria	All patients	Limb ischemia group	No limb ischemia group	P value
Acute Kidney injury	39 (60)	21 (100)	18 (40.9)	< 0.001
Renal replacement therapy	27 (41.5)	12 (57.1)	15 (34.1)	0.07
Cerebrovascular stroke	13 (20)	5 (23.8)	8 (18.2)	0.74
Cerebral ischemic stroke	7 (11.9)	3 (17.6)	4 (9.5)	0.39
Intracerebral haemorrhage	6 (10.2)	2 (11.8)	4 (9.5)	0.9
ICU days	19 (3–191)	19 (10–93)	17 (3–191)	0.028
Ventilator days	10 (2–191)	14 (5–81)	9 (2–191)	0.053
Gastrointestinal bleeding	14 (21.5)	4 (19)	10 (22.7)	0.92
Atrial fibrillation	25 (38.5)	9 (42.9)	16 (36.4)	0.61
Intracardiac thrombi	4 (6.2)	1 (4.8)	3 (6.8)	0.9
ECMO circuits thrombi	4 (6.2)	1 (4.8)	3 (6.8)	0.9
ECMO days before ischemia	6 (1–21)	6 (1–21)	-----	----
ECMO days	8 (3–40)	7 (4–40)	8 (3–32)	0.27
Changing to central VA-ECMO	3 (4.6)	2 (9.5)	1 (2.3)	0.29
Changing to LVAD	11 (16.9)	4 (19)	7 (15.9)	0.34
Decannulation and no MCS	51 (78.5)	15 (71.4)	36 (81.8)	0.41
Hospital mortality	29 (44.6)	9 (42.9)	20 (45.5)	0.84
SOFA score day 1	12 (8–21)	10 (8–21)	14 (8–21)	0.008
SOFA score day 3	13 (6–24)	10 (7–22)	14 (6–24)	0.034
Δ 1 SOFA	–1 (–5 to 6)	1 (–4 to 6)	–2 (–5 to 6)	0.12
SOFA score day 5	10 (5–24)	9 (6–21)	10 (5–24)	0.45
Δ 2 SOFA	–2 (–7 to 9)	0 (–5 to 8)	–3 (–7 to 9)	0.14

Data are presented as number (%) or median (IQR)

Table 5 The correlations between cannulation site bleeding and cannulation techniques

Variables	Cannulation site bleeding	No site bleeding	P value
Percutaneous cannulation			
Successful	3 (18.8%)	33 (67.3%)	0.001
Failed	10 (62.5%)	9 (18.4%)	
Not tried	3 (18.8%)	7 (14.3%)	
Cut-down			
Done	13 (81.3%)	16 (32.7%)	0.001
Not done	3 (18.8%)	33 (67.3%)	

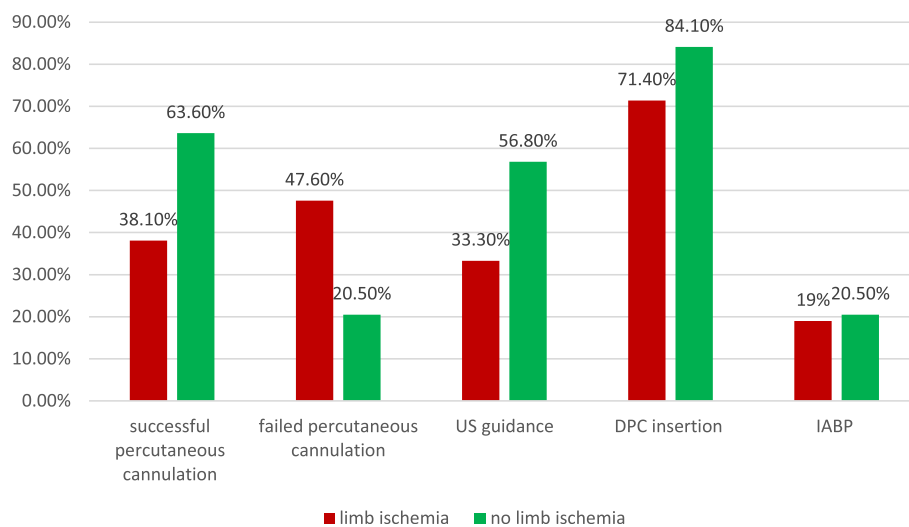
the vascular complications after VA-ECMO and found a wide range of incidence which may be related to different patients' demographic data, indications and cannulation techniques of VA-ECMO and use of distal perfusion cannulae [8, 10, 17–20].

Our incidence of acute limb ischemia was similar to Yen et al.'s study that reported acute limb ischemia in 33% of VA-ECMO-treated patients, even with the use of DPC [8]. Our results were different from Yang et al. [18] study that reported only 8.6% incidence of acute lower limb ischemia. That difference may be related to the difference of studied patients as that study included only patients with post-cardiotomy shock and the ECMO cannulae were inserted by cut-down approach only with concomitant prophylactic DPC insertion. Tanaka et al. reported 20% incidence of acute vascular complications included a 12% incidence of acute limb ischemia with compartmental syndrome requiring fasciotomy, even in the presence of DPC [10]. Gander et al.'s study reported 52% incidence of limb ischemia requiring surgical

interventions and 81% of those patients had prophylactic DPC [21].

The development of acute limb ischemia can occur at ECMO initiation, support, or after decannulation due to multifactorial reduced blood flow to the limb especially in absence of collateral circulation. The use of relatively large-sized arterial cannulae in relation to the arterial femoral artery diameter or BSA was associated with acute limb ischemia in some studies [6, 22]. Few studies reported that younger patients have higher risk of acute limb ischemia due to smaller femoral arteries and lack of collateral circulation compared to the elderly [23]. Also, female patients have higher risks compared to men due to smaller arterial sizes [10, 24]. In our study, we did not find any significant difference between both groups regarding patient age, sex, weight, height, BMI, nor BSA. Yang et al. study reported absence of age or sex differences but the patients who developed vascular complications were significantly obese [18].

Our results revealed that percutaneous approach was tried in 84.6% of patients but was successful in only 55.4% of patients. The occurrence of acute limb ischemia was significantly correlated with failed percutaneous femoral cannulation. The occurrence of femoral cannulation site bleeding was significantly correlated with failed percutaneous cannulation and cut-down technique. The percutaneous approach was the most used technique in many studies evaluating femoral VA-ECMO [8, 10, 25–28]. The percutaneous cannulation is characterized by being rapid easy approach with reduced risk of cannulation site bleeding but its main disadvantages include possibilities of vascular injuries and failed intraluminal catheter placement. Moreover emergent percutaneous cannulation in patients with

**Fig. 2** Cannulation approaches of femoral VA-ECMO support

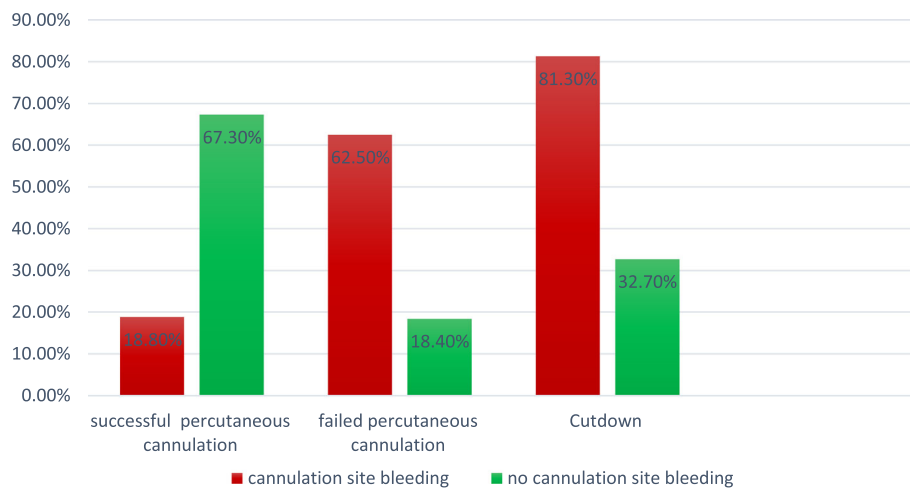


Fig. 3 Cannulation site bleeding of the studied VA-ECMO-treated patients

haemodynamics collapse is a major challenge that may be complicated with vascular complications [29, 30]. The use of ultrasound guidance in getting femoral access with first pass success was reported in many studies comparing it with the landmark techniques [31–33]. Kashiura et al. [34] recommended a combination of ultrasound guidance to get femoral access then fluoroscopy to ensure correct intraluminal guiding wire placement before dilators use and cannulae insertion. That study reported fewer vascular complications with this combination than ultrasound guidance alone without a significant delay of ECMO flow initiation.

The cut-down technique is usually done after cardiotomy with failed weaning off cardiopulmonary bypass. In our study, the cut-down technique was done mainly after failed percutaneous approach, so we could not compare between the 2 approaches regarding the vascular complications and outcomes. Slottosch et al. [35] reported the fewer vascular complications associated with the surgical approach compared with the percutaneous cannulation. However, Danial et al. [36] reported absence of significant difference between both approaches regarding acute limb ischemia in the same centre but the percutaneous approach was associated with significant bleeding requiring surgical intervention after decannulation.

Eighty percent of our studied patients had prophylactic DPC insertion with ECMO initiation and there was no significant difference between both groups. The prophylactic DPC insertion was done as a preventive strategy to avoid significant limb ischemia with variable results in many studies [8, 10, 18, 21, 37, 38]. Few trials were done to identify the patients who need a DPC instead of prophylactic insertion. Huang et al. [39] reported successful use of DPC if invasive mean arterial blood pressure was less than 50 mmHg in femoral artery distal to the arterial cannula of ECMO. Near-infrared

spectroscopy (NIRS) was used to identify the regional limb tissue oxygenation (rSO₂%) and help to detect ischemia even with non-pulsatile blood flow. Schachner et al. [40] used NIRS monitoring and reported a drop of tissue oxygenation from 61 to 38% and going back to normal baseline values after DPC insertion. Wong et al. [41] used NIRS to concomitantly monitor brain and limb regional oxygenation. They reported clinically significant vascular events when rSO₂% decreased below 40% or more than 25% decrease from baseline values.

According to our results and compared to patients without acute limb ischemia, the patients who developed acute ischemia had significant AKI and longer ICU stay but without significant haemodialysis, cerebral strokes, nor hospital mortality. Yang et al. [18] reported similar cerebrovascular strokes and renal replacement therapy but fewer ICU stay and fewer hospital mortality in the patients who developed acute vascular complications compared to the patients without vascular complications after peripheral VA-ECMO for post-cardiotomy shock via femoral cut-down approach. Gander et al. [21] reported absence of mortality difference between the patients with and without acute limb ischemia. Finally according to our study, we think that the emergent femoral percutaneous cannulation in patients with haemodynamics instability and coagulopathy could result in failed cannulation trials which were associated with the acute limb ischemia and cannulation site bleeding. We could recommend a careful approach and using image modalities during the whole process of femoral cannulation, guidewire introduction and cannulae insertion, and then close monitoring of limb perfusion.

Conclusion

Acute vascular complications are frequent after femoral VA-ECMO. Failed percutaneous femoral cannulation

has been, in this study identified as the most important risk factor for acute limb ischemia and cannulation site bleeding. A careful approach during femoral cannulation is recommended to prevent occurrence of acute limb ischemia and femoral cannulation site bleeding.

Limitations

Our work was a single-centre retrospective study with a relatively limited number of patients.

Abbreviations

AKI: Acute kidney injury; AF: Atrial fibrillation; aPTT: Activated partial thromboplastin time; BSA: Body surface area; BMI: Body mass index; CKD: Chronic kidney disease; CI: Cardiac index; CVS: Cerebrovascular stroke; DPC: Distal perfusion cannula; EF: Ejection fraction; LVAD: Left ventricle assist device; MCS: Mechanical circulatory support; NIRS: Near-infrared spectroscopy; IABP: Intra-aortic balloon pump; INR: International normalized ratio; SOFA: Sequential organ failure assessment; US: Ultrasound; VA-ECMO: Veno-arterial extracorporeal membrane oxygenation

Acknowledgements

We would like to thank the Cardiac Surgical Intensive Care Unit (adult CSICU) team of King Faisal Specialist Hospital for their excellent work.

Authors' contributions

All authors contributed to the research. ML has taken part in the conception and design of the study, collection, analysis and interpretation of the data, drafting of the manuscript, and final approval of the manuscript submitted. ES has taken part in the design of the study, analysis and interpretation of the data, and revision of the manuscript. SK has taken part in the design of the study, interpretation of the data, and revision of the manuscript. The authors have read and approved the final manuscript.

Funding

The authors did not receive any funding for this study.

Availability of data and materials

The data used in this study are available from the corresponding author upon a reasonable request.

Ethics approval and consent to participate

The study was approved by the Ethical Committee of King Faisal Specialist Hospital and Research Center with a reference number 2191186 and exempted from a specific consent, being a retrospective analytic study that reveals no identifiable private information.

Consent for publication

Not applicable.

Competing interests

The authors declare no competing interests.

Author details

¹Adult Cardiac Surgical Intensive Care Department, King Faisal Specialist Hospital & Research Center, Riyadh, Saudi Arabia. ²Critical Care Medicine Department, Cairo University, Cairo, Egypt. ³Vascular and Endovascular Surgery Department, King Faisal Specialist Hospital & Research Center, Riyadh, Saudi Arabia. ⁴College of Medicine, Alfaisal University, Riyadh, Saudi Arabia.

Received: 11 January 2021 Accepted: 8 February 2021

Published online: 19 February 2021

References

- Abrams D, Garan AR, Abdelbary A, Bacchetta M, Bartlett RH et al (2018) Position paper for the organization of ECMO programs for cardiac failure in adults. *Intensive Care Med* 44(6):717–729

- Raffa GM, Gelsomino S, Sluijpers N, Meani P, Alenizy K et al (2017) Inhospital outcome of post-cardiotomy extracorporeal life support in adult patients: the 2007–2017 Maastricht experience. *Crit Care Resusc* 19(Suppl 1):53–61
- Lorusso R, Gelsomino S, Parise O, Mendiarrata P, Prodhon P et al (2017) Venoarterial extracorporeal membrane oxygenation for refractory cardiogenic shock in elderly patients: trends in application and outcome from the extracorporeal life support organization (ELSO) registry. *Ann Thorac Surg* 104(1):62–69
- Jayaraman A, Cormican D, Shah P, Ramakrishna H (2017) Cannulation strategies in adult veno-arterial and veno-venous extracorporeal membrane oxygenation: techniques, limitations, and special considerations. *Ann Card Anaesth* 20(5):11
- Roussel A, Al-Attar N, Alkhoder S, Radu C, Raffoul R et al (2012) Outcomes of percutaneous femoral cannulation for venoarterial extracorporeal membrane oxygenation support. *Eur Heart J Acute Cardiovasc Care* 1:111–114
- Banfi C, Pozzi M, Brunner M-E, Rigamonti F, Murith N et al (2016) Veno-arterial extracorporeal membrane oxygenation: an overview of different cannulation techniques. *J Thorac Dis* 8(9):E875–E885
- Yau P, Xia Y, Shariff S, Jakobleff WA, Forest S et al (2019) Factors associated with ipsilateral limb ischemia in patients undergoing femoral cannulation extracorporeal membrane oxygenation (ECMO). *Ann Vasc Surg* 54:60–65
- Yen CC, Kao CH, Tsai CS, Tsai SH (2018) Identifying the risk factor and prevention of limb ischemia in extracorporeal membrane oxygenation with femoral artery cannulation. *Heart Surg Forum* 21(1):E18–E22
- Kaushal M, Schwartz J, Gupta N, Im J, Leff J, Jakobleff WA et al (2019) Patient demographics and extracorporeal membranous oxygenation (ECMO)-related complications associated with survival to discharge or 30-day survival in adult patients receiving venoarterial (VA) and venovenous (VV) ECMO in a quaternary care urban center. *J Cardiothorac Vasc Anesth* 33(4):910–917
- Tanaka D, Hirose H, Cavarocchi N, Entwistle JWC (2016) The impact of vascular complications on survival of patients on Venoarterial extracorporeal membrane oxygenation. *Ann Thorac Surg* 101(5):1729–1734
- Ferreira FL, Bota DP, Bross A, Melot C, Vincent JL (2001) Serial evaluation of the SOFA score to predict outcome in critically ill patients. *JAMA* 286(14):1754–1758
- Laimoud M, Alanazi M (2020) The validity of SOFA score to predict mortality in adult patients with cardiogenic shock on venoarterial extracorporeal membrane oxygenation. *Crit Care Res Pract* 2020:3129864. <https://doi.org/10.1155/2020/3129864>
- Lambden S, Laterre P, Levy M, Francois B (2019) The SOFA score—development, utility and challenges of accurate assessment in clinical trials. *Crit Care* 23:374
- Kohler K, Valchanov K, Nias G, Vuylsteke A (2013) ECMO cannula review. *Perfus (United Kingdom)* 28(2):114–124
- Green MS, Sehgal S, Tariq R (2016) Near-infrared spectroscopy: the new must have tool in the intensive care unit? *Semin Cardiothorac Vasc Anesth* 20(3):213–224
- Moerman A, Wouters P (2010) Near-infrared spectroscopy (NIRS) monitoring in contemporary anesthesia and critical care. *Acta Anaesthesiol Belg* 61(4):185–194
- Lee DS, Chung CR, Jeon K, Park CM, Suh GY, Song Y (2016) Bin, et al. Survival after extracorporeal cardiopulmonary resuscitation on weekends in comparison with weekdays. *Ann Thorac Surg* 101(1):133–140
- Yang F, Hou D, Wang J, Cui Y, Wang X, Xing Z et al (2018) Vascular complications in adult postcardiotomy cardiogenic shock patients receiving venoarterial extracorporeal membrane oxygenation. *Ann Intensive Care* 8(1):72
- Cheng R, Hachamovitch R, Kittleson M, Patel J, Arabia F, Moriguchi J et al (2014) Complications of extracorporeal membrane oxygenation for treatment of cardiogenic shock and cardiac arrest: a meta-analysis of 1,866 adult patients. *Ann Thorac Surg* 97(2):610–616
- Pozzi M, Koffel C, Djaref C, Grinberg D, Fellahi JL, Hugon-Vallet E et al (2017) High rate of arterial complications in patients supported with extracorporeal life support for drug intoxication-induced refractory cardiogenic shock or cardiac arrest. *J Thorac Dis* 9(7):1988–1996
- Gander JW, Fisher JC, Reichstein AR, Gross ER, Aspelund G, Middlesworth W et al (2010) Limb ischemia after common femoral artery cannulation for venoarterial extracorporeal membrane oxygenation: an unresolved problem. *J Pediatr Surg* 45:2136–2140
- Kim J, Cho YH, Sung K, Park TK, Lee GY, Lee JM, Song YB, Hahn JY, Choi JH, Choi SH, Gwon HC, Yang JH (2019) Impact of cannula size on clinical outcomes in peripheral venoarterial extracorporeal membrane oxygenation. *ASAIO J* 65(6):573–579

23. Sandgren T, Sonesson B, Ahlgren R, Länne T (1999) The diameter of the common femoral artery in healthy human: influence of sex, age, and body size. *J Vasc Surg* 29(3):503–510
24. Lamb KM, DiMuzio PJ, Johnson A, Batista P, Moudgill N, McCullough M et al (2017) Arterial protocol including prophylactic distal perfusion catheter decreases limb ischemia complications in patients undergoing extracorporeal membrane oxygenation. *J Vasc Surg* 65(4):1074–1079
25. Johnson NJ, Acker M, Hsu CH, Desai N, Vallabhajosyula P, Lazar S et al (2014) Extracorporeal life support as rescue strategy for out-of-hospital and emergency department cardiac arrest. *Resuscitation* 85:1527–1532
26. Aziz F, Brehm CE, El-Banyosy A, Han DC, Atnip RG, Reed AB (2014) Arterial complications in patients undergoing extracorporeal membrane oxygenation via femoral cannulation. *Ann Vasc Surg* 28:178–183
27. Haneya A, Philipp A, Diez C, Schopka S, Bein T, Zimmermann M et al (2012) A 5-year experience with cardiopulmonary resuscitation using extracorporeal life support in non-postcardiotomy patients with cardiac arrest. *Resuscitation* 83:1331–1337
28. Kim SJ, Jung JS, Park JH, Park JS, Hong YS, Lee SW (2014) An optimal transition time to extracorporeal cardiopulmonary resuscitation for predicting good neurological outcome in patients with out-of-hospital cardiac arrest: a propensity-matched study. *Crit Care* 18:535
29. Swol J, Belohlavek J, Haft JW, Ichiba S, Lorusso R, Peek GJ (2016) Conditions and procedures for in-hospital extracorporeal life support (ECLS) in cardiopulmonary resuscitation (CPR) of adult patients. *Perfusion* 31:182–188
30. Conrad SA, Grier LR, Scott LK, Green R, Jordan M (2015) Percutaneous cannulation for extracorporeal membrane oxygenation by intensivists: a retrospective single-institution case series. *Crit Care Med* 43:1010–1015
31. Kalish J, Eslami M, Gillespie D, Schermerhorn M, Rybin D, Doros G et al (2015) Routine use of ultrasound guidance in femoral arterial access for peripheral vascular intervention decreases groin hematoma rates. *J Vasc Surg* 61(5):1231–1238
32. Laimoud M, Alanazi M (2020) Ultrasound-guided arterial catheterization in critical patients with nonpulsatile continuous circulation conditions on ventricular assist devices or veno-arterial extracorporeal membrane oxygenation support. *Res Opin Anesth Intensive Care* 7:308–312
33. Sobolev M, Slovut DP, Lee Chang A, Shiloh AL, Eisen LA (2015) Ultrasound-guided catheterization of the femoral artery: a systematic review and meta-analysis of randomized controlled trials. *J Invasive Cardiol* 27(7):318–323
34. Kashiura M, Sugiyama K, Tanabe T et al (2017) Effect of ultrasonography and fluoroscopic guidance on the incidence of complications of cannulation in extracorporeal cardiopulmonary resuscitation in out-of-hospital cardiac arrest: a retrospective observational study. *BMC Anesthesiol* 17:4. <https://doi.org/10.1186/s12871-016-0293-z>
35. Slottosch I, Liakopoulos O, Kuhn E, Deppe A-C, Scherner M, Madershahian N et al (2013) Outcomes after peripheral extracorporeal membrane oxygenation therapy for postcardiotomy cardiogenic shock: a single-center experience. *J Surg Res* 181(2):e47–e55
36. Danial P, Hajage D, Nguyen LS, Mastroianni C, Demondion P, Schmidt M et al (2018) Percutaneous versus surgical femoro-femoral veno-arterial ECMO: a propensity score matched study. *Intensive Care Med* 44(12):2153–2161
37. Madershahian N, Nagib R, Wipperman J et al (2006) A simple technique of distal limb perfusion during prolonged femoro-femoral cannulation. *J Card Surg* 21: 168–169
38. Kasirajan V, Simmons I, King J et al (2002) Technique to prevent limb ischemia during peripheral cannulation for extracorporeal membrane oxygenation. *Perfusion* 17:427–428
39. Huang SC, Yu HY, Ko WJ et al (2004) Pressure criterion for placement of distal perfusion catheter to prevent limb ischemia during adult extracorporeal life support. *J Thorac Cardiovas Surg* 128:776–777
40. Schachner T, Bonaros N, Bonatti J et al (2008) Near infrared spectroscopy for controlling the quality of distal leg perfusion in remote access cardiopulmonary bypass. *Eur J Cardiothorac Surg* 34:1253–1254
41. Wong JK, Smith TN, Pitcher HT, Hirose H, Cavarocchi NC (2012) Cerebral and lower limb near-infrared spectroscopy in adults on extracorporeal membrane oxygenation. *Artif Organs* 36(8):659–667

Publisher's Note

Springer Nature remains neutral with regard to jurisdictional claims in published maps and institutional affiliations.

Submit your manuscript to a SpringerOpen® journal and benefit from:

- Convenient online submission
- Rigorous peer review
- Open access: articles freely available online
- High visibility within the field
- Retaining the copyright to your article

Submit your next manuscript at ► [springeropen.com](https://www.springeropen.com)
