

Ultrasonographic features of a urinary bladder leiomyoma in a cat

Nathan R Biedak , Dominique Penninck and Ethan Biswell 

Journal of Feline Medicine and Surgery Open Reports
1–6

© The Author(s) 2023

Article reuse guidelines:

sagepub.com/journals-permissions

DOI: 10.1177/20551169231165247

journals.sagepub.com/home/jfmsopenreports

This paper was handled and processed by the American Editorial Office (AAFP) for publication in *JFMS Open Reports*



Abstract

Case summary Leiomyoma of the urinary bladder in cats is infrequently documented in the literature, and a description of the ultrasonographic appearance has never been reported. A 9-year-old female spayed cat presented with a 6-month history of intermittent hematuria and progressive pollakiuria. On abdominal ultrasound, a large ovoid mass of mixed echogenicity was seen originating from the ventral apical bladder wall. The mass had faint peripheral hyperechoic radiating striations and was mildly vascularized, especially at its 1.5 cm point of origin from the wall. A partial cystectomy was performed to remove the mass that filled the bladder lumen. Microscopically, the well-demarcated mass extended from the inner muscular layer of the wall into the submucosal layer and was diagnosed as a leiomyoma. Surgical excision was curative.

Relevance and novel information This is the first ultrasonographic description of a bladder leiomyoma in a feline patient. Smooth muscle tumors should be included on the differential diagnosis list in future cases with similar ultrasonographic features and chronic lower urinary clinical signs.

Keywords: Ultrasound; leiomyoma; urinary bladder; smooth muscle tumor

Accepted: 6 March 2023

Introduction

Leiomyomas are benign smooth muscle tumors that have been documented in the reproductive tract, gastrointestinal tract and, uncommonly, the urinary bladder of companion animals.^{1–3} Urinary bladder smooth muscle tumors have been described in dogs,^{1,4–7} humans,^{8,9} goats¹⁰ and cats.^{3,11,12} In human medicine, leiomyomas are described as smooth, well-circumscribed, vascularized, homogeneous-to-heterogeneous textured masses of medium echogenicity located along the posterior wall/near the bladder neck.^{8,9} In dogs, the ultrasonographic morphology of smooth muscle urinary bladder tumors has been described as either intraluminal or extraluminal cranial bladder masses with a homogenous hypoechogenic-to-mixed echogenic appearance.^{1,4–7} In those cases, no central Doppler flow was noted, the lesions had well-defined margins and a broad attachment to the bladder wall.^{1,4} To our knowledge, the ultrasonographic appearance of urinary bladder leiomyomas has not been reported in cats.

The aim of this report was to describe the ultrasonographic and clinicopathological findings of a bladder leiomyoma in a cat.

Case description

A 9-year-old indoor-only female spayed domestic short-hair cat presented with a 6-month history of intermittent hematuria and inappropriate urination that was non-responsive to cefovecin sodium injections (Convenia; Zoetis). The referring veterinarian performed an ultrasound of the urinary system and noted a 4 cm mass that occupied roughly 75% of the bladder lumen. A malignant

Tufts Cummings School of Veterinary Medicine, North Grafton, MA, USA

Corresponding author:

Nathan R Biedak MS, DVM, Tufts Cummings School of Veterinary Medicine, 200 Westboro Road, North Grafton, MA 01536, USA
Email: nathan.biedak@tufts.edu



Creative Commons Non Commercial CC BY-NC: This article is distributed under the terms of the Creative Commons

Attribution-NonCommercial 4.0 License (<https://creativecommons.org/licenses/by-nc/4.0/>) which permits non-commercial use, reproduction and distribution of the work without further permission provided the original work is attributed as specified on the SAGE and Open Access pages (<https://us.sagepub.com/en-us/nam/open-access-at-sage>).

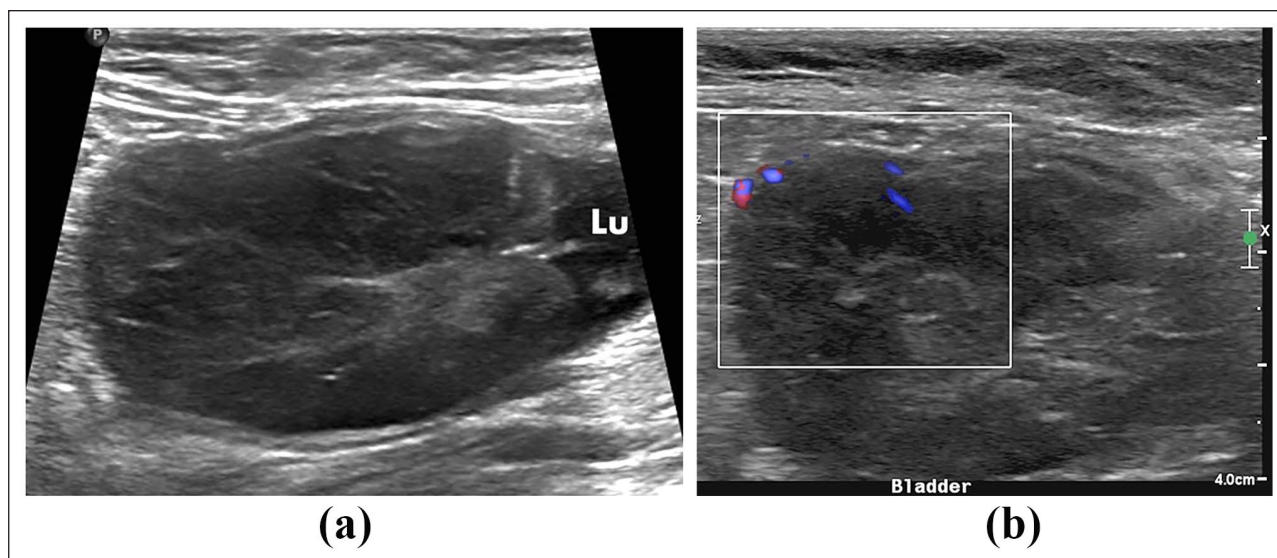


Figure 1 (a) Longitudinal ultrasonograph of the urinary bladder with the large intraluminal bladder mass filling most of the lumen. (b) Longitudinal view of the bladder mass with color flow Doppler centered on the apical region. Several vessels extend from the apical bladder wall in the mass, suggesting that the mass originated from the apex

neoplasia or a hematoma were considered. Fine-needle aspiration of the mass was performed. The cytologic results were deemed inconclusive by a pathologist as only red blood cells with a few mixed leukocytes were present. A urinalysis could not be obtained.

Three months later, the patient presented to the Foster Hospital for Small Animals at Tufts Cummings School of Veterinary Medicine for further diagnostics and surgical excision. The cat's only clinical signs were intermittent hematuria and pollakiuria.

On physical examination, the cat was euhydrated with normal vital signs. A rounded, firm, intra-abdominal mass was palpated in the region of the urinary bladder.

An abdominal ultrasound (Philips EPIQ 7G) with a linear 12-5MHz transducer revealed a moderately distended urinary bladder filled with an ovoid, mixed echogenic mass that occupied approximately 80% of the lumen. The cranioventral apical bladder wall was slightly deformed and ill-defined at the place of attachment. The mass was poorly echogenic with faint linear hyperechoic striations extending from the center of the mass to the periphery (Figure 1a,b). On color flow Doppler, vascularization of the mass was noted at the apex of the bladder, and faint vessels were also present centrally along some of the subtle striations (Figure 1b). The differential diagnoses were leiomyosarcoma, leiomyoma, urothelial cell carcinoma, fibrosarcoma or, less likely, polypoid cystitis. A hematoma was considered unlikely given the presence of vascularity.

A perioperative complete blood count, chemistry and coagulation panel were all within the reference intervals. A urinalysis was unobtainable given the inability to safely perform a cystocentesis. A partial cystectomy was

performed the following day and the 4 × 5 cm ovoid urinary bladder mass was fully excised (Figure 2a). The mass had a 1.5 cm attachment to the apex of the bladder (Figure 2b) and occupied most of the bladder lumen. The patient recovered uneventfully. To control the patient's postoperative pain level, one intravenous injection of 0.01 mg/kg buprenorphine hydrochloride (PAR Pharmaceutical) was administered, and then 6 mg robenicoxib (Onsior; Elanco) was given PO q24h for 3 days.

Gross evaluation of the bladder specimen revealed a smooth, rounded, firm 3.5 × 5.0 cm mass originating from the apex of the bladder. The mass did not extend to the cut margin of the resection (Figure 3). After transecting the mass, the internal texture appeared diffusely homogeneous (Figure 3).

The mass originated from the inner muscular portion of the bladder wall, extended into the submucosa and protruded into the lumen (Figure 4). The mass was composed of neoplastic mesenchymal cells arranged in long interlacing bundles (neoplastic smooth muscle cells) with scant collagenous stroma between the cells (Figure 4). The neoplastic cells had indistinct margins, mild anisokaryosis, wispy vacuolated-to-eosinophilic cytoplasm, a coarse chromatin pattern with 1–2 nucleoli and no mitotic figures. The overlying mucosa was focally ulcerated. The remaining submucosa was necrotic, likely due to pressure necrosis, with scattered hemorrhage and infiltration by neutrophils, and few lymphocytes and histiocytes. The diagnosis was a well-differentiated leiomyoma with no bacterial, fungal or viral inclusions seen microscopically. The mass was fully excised with narrow margins.

The patient was asymptomatic 8 months after the procedure, with no recurrent urinary signs.

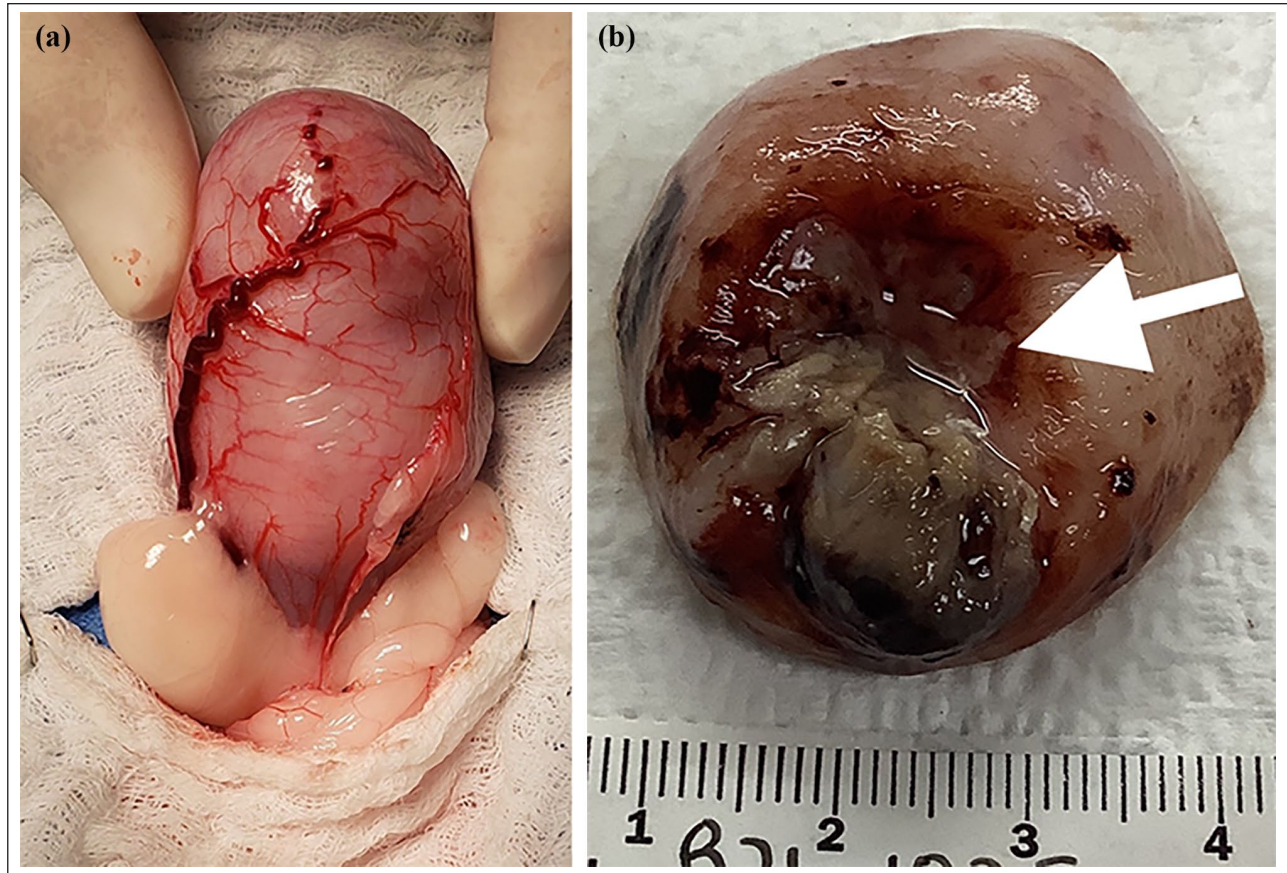


Figure 2 (a) Intraoperative image of the bladder. The bladder was firm and filled by a large intraluminal mass. A large vascular network can be seen on the serosal surface of the bladder wall. (b) Transverse section of the mass that shows ulceration (arrow) near its point of attachment to the urinary bladder

Discussion

Ultrasound of the urinary bladder is useful in evaluating wall thickness, wall integrity and the presence of intraluminal changes such as cystoliths, cellular debris, lipid droplets, blood clots and neoplasms.⁷ Wall layering is not consistently visible, especially in a distended bladder.

Lower urinary tract manifestations such as hematuria, pollakiuria, dysuria, stranguria, tenesmus and sometimes urinary incontinence can occur with urinary bladder neoplasms.^{13–16} Based on few reports in dogs with urinary bladder leiomyoma, lower urinary tract signs,^{1,4–6} tenesmus⁴ and constipation⁵ are listed, but some patients demonstrated no abnormal clinical signs.^{1,6} In our case and in previous reports on cats with smooth muscle bladder tumors, hematuria and pollakiuria were seen.^{3,11,12}

As in this case, physical examination in cats with bladder masses may detect a palpable mass in the mid-to-caudal abdomen. As highlighted in this case and others,¹⁴ if the mass is non-obstructive, the complete blood count and biochemical analyses are often normal. However, if the mass involves the urinary bladder

papillae, a post-renal azotemia, as well as electrolyte derangements, may be present.⁵ Though not performed in this case, urinalysis is likely to show hematuria and proteinuria.

Urinary bladder tumors are rare in veterinary medicine, constituting approximately 1–2% of neoplasia in dogs, and less in cats.^{13,14,17,18} The majority of these neoplasms are malignant, and at least 60% of those are of epithelial origin.^{6,14–16,19} The most documented malignant urinary bladder neoplasm in dogs and cats is a urothelial cell carcinoma.^{13,16,18,20,21} Other reported bladder tumors are leiomyoma, leiomyosarcoma, adenocarcinoma, squamous cell carcinoma, lymphoma, rhabdomyosarcoma, fibrosarcoma, hemangioma and hemangiosarcoma.^{11,14,16,19,21}

Between 0.5% and 10% of canine bladder masses are composed of mesenchymal cells; 5% of those arise from smooth muscle and at least 50% found in the literature are benign.^{14,22} In cats, we found three reports of bladder smooth muscle tumors: two were leiomyosarcomas and one was a leiomyoma.^{3,11,12}

Urinary bladder leiomyomas can be intraluminal or extraluminal, expanding outward from the wall.⁴ In this

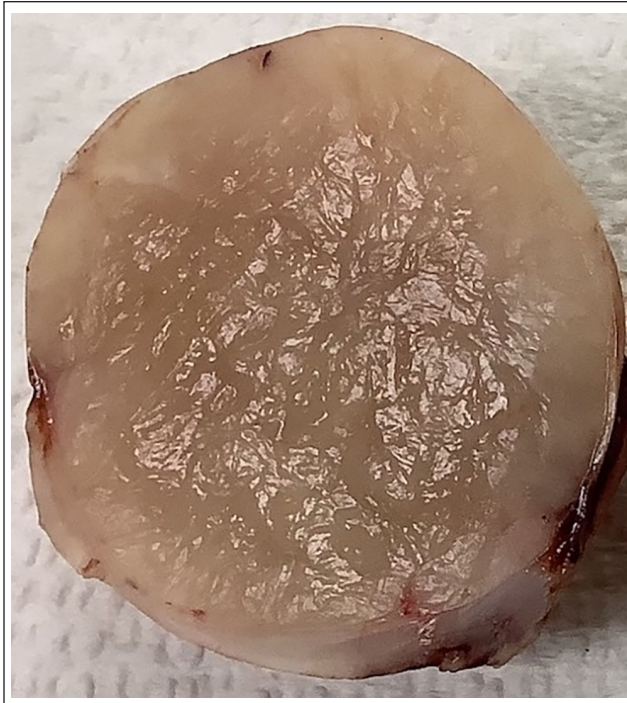


Figure 3 Gross anatomic section of the mass showing its homogeneous consistency

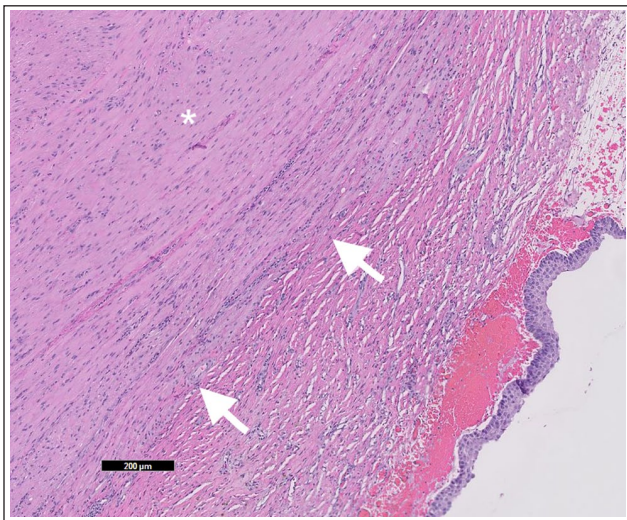


Figure 4 Urinary bladder leiomyoma. Magnification ($\times 5$) of the leiomyoma (*) compressing the adjacent submucosa (white arrows) which contains areas of hemorrhage. Hematoxylin and eosin. Bar = 200 μ m

case, the intraluminal mass originated from the inner longitudinal muscularis layer. The intraluminal vs extraluminal distribution of the tumor is of unclear etiology, though one could speculate that the expansive behavior is dependent on which primary layer of the tunica muscularis it originates from.

The origin of canine smooth muscle bladder tumors is often at the mid-cranial apex;^{1,4,6,7} however, one report

described unilateral hydroureter and hydronephrosis associated with obstruction of the ureteral papilla.⁵ In the limited number of reported feline cases of bladder leiomyosarcoma and leiomyoma, the lesions occurred at the cranial apex of the bladder^{3,11,12} and none of these tumors caused urinary obstruction.

The size of canine bladder leiomyomas in the literature varied from a diameter of 2.5 cm to 12 cm,^{1,6} and the clinical signs did not always correlate with tumor size. Canine leiomyomas have a hypoechoic-to-mixed echogenic appearance, with well-circumscribed, smooth margins.^{1,4-6} Our feline case displayed poor-mixed echogenicity and faint, peripherally radiating hyperechoic striations with a 1.5 cm point of attachment. On color flow Doppler, vessels were seen at the apical attachment. In canine bladder leiomyoma cases that report on vasculature, no Doppler signals were detected in the lesion.¹⁴ The utility of Doppler flow characteristics in the investigation of neoplasia needs to be further investigated, especially as Doppler technology advances.

Differential diagnoses for intraluminal bladder tumors in cats include urothelial cell carcinoma, lymphoma, fibrosarcoma and leiomyosarcoma. Feline urothelial cell carcinoma is the most common cancerous bladder tumor. Their appearance is variable,¹³ though the majority exhibit complex echogenicity and tend to be well-vascularized, solitary, broad-based and locally-invasive masses that disrupt wall layering.^{11,13,20} Urothelial cell carcinoma in cats can originate anywhere in the bladder, but commonly occurs at the mid-body to apex of the bladder,¹³ unlike in dogs where they tend to occur at the trigone.^{13,20} Unlike the leiomyoma in this case, however, urothelial cell carcinomas often contain degrees of internal mineralization that alter the ultrasonographic uniformity.¹³

In cats, bladder lymphoma is rare and has been described as a multilobulated, poorly echogenic mass that deforms the contour of the bladder,⁷ and as a heterogeneous, broad-based, mural mass deriving at the trigone with evidence of serosal invasion.¹⁹ Fibrosarcoma of the feline urinary bladder is also rare and has been described on ultrasound as a vascular, mixed echogenic mass originating from the craniodorsal aspect of the bladder that disrupts the normal bladder wall architecture.^{18,21}

Differentiating leiomyoma from other malignant tumors based on imaging features is not possible and a definitive diagnosis requires histopathology.⁴ Though sampling the mass could help in differentiating between tumor types, it is not recommended because of the reported risk of cancerous cell seeding along a needle tract.^{23,24}

Other differentials for non-tumoral bladder masses include polyploid cystitis and blood clots.²⁰ Polyploid cystitis occurs more in dogs, and the intraluminal projections appear as irregularly marginated, moderately echogenic, pedunculated, cranioventral masses that are seen concurrently with an unevenly diffusely thickened bladder wall.^{7,25} Blood clots can also be confused with

bladder masses as they can appear as rounded-to-ovoid, inhomogeneous, poorly echogenic masses; however, they are easily differentiated by the lack of blood flow and their mobility, unless they are adhered to the epithelial surface.⁷

Conclusions

To the best of our knowledge, this case report is the first to describe the ultrasonographic appearance of a feline urinary bladder leiomyoma. It appeared as an intraluminal, poorly vascularized, semi-broad-based, poor-mixed echogenic, large space-occupying mass originating from the apex of the bladder. It should be added to the differential diagnosis list of urinary bladder masses in cats with chronic lower urinary tract clinical signs. Surgical resection alone can be a curative treatment.

Conflict of interest The authors declared no potential conflicts of interest with respect to the research, authorship, and/or publication of this article.

Funding The authors received no financial support for the research, authorship, and/or publication of this article.

Ethical approval statement The work described in this manuscript involved the use of non-experimental (owned or unowned) animals. Established internationally recognized high standards ('best practice') of veterinary clinical care for the individual patient were always followed and/or this work involved the use of cadavers. Ethical approval from a committee was therefore not specifically required for publication in *JFMS Open Reports*. Although not required, where ethical approval was still obtained, it is stated in the manuscript.

Informed consent statements Informed consent (verbal or written) was obtained from the owner or legal custodian of all animal(s) described in this work (experimental or non-experimental animals, including cadavers) for all procedure(s) undertaken (prospective or retrospective studies). No animals or people are identifiable within this publication, and therefore additional informed consent for publication was not required.

ORCID iD Nathan R Biedak  <https://orcid.org/0000-0001-7652-4810>

Ethan Biswell  <https://orcid.org/0000-0002-8923-561X>

References

- Heng HG, Lowry JE, Boston S, et al. **Smooth muscle neoplasia of the urinary bladder wall in three dogs.** *Vet Radiol Ultrasound* 2006; 47: 83–86.
- Myers NC, III and Penninck DG. **Ultrasonographic diagnosis of gastrointestinal smooth muscle tumors in the dog.** *Vet Radiol Ultrasound* 1994; 35: 391–397.
- Patnaik AK and Greene RW. **Intravenous leiomyoma of the bladder in a cat.** *J Am Vet Med Assoc* 1979; 175: 381–383.
- DeJesus A and Hoyt L. **What is your diagnosis?** *J Am Vet Med Assoc* 2016; 249: 479–481.
- Gokulakrishnan M, Bharathidasan M, Sharma P, et al. **Successful management of bladder leiomyoma through partial cystectomy in a non-descript dog.** *Pharma Innov* 2021; 10: 1351–1353.
- Junior PS, Teixeira ALS and Menezes JL. **Urinary bladder leiomyoma in a bitch (*Canis lupus familiaris*)** [article in Spanish]. *Ars Vet* 2011; 27: 7–10.
- Sutherland-Smith J and Penninck D. **Bladder and urethra.** In: Penninck D and d'Anjou MA (eds). *Atlas of small animal ultrasonography*. 2nd ed. Ames, IA: John Wiley and Sons, 2015, pp 363–385.
- Goluboff ET, O'Toole K and Sawczuk IS. **Leiomyoma of bladder: report of case and review of literature.** *Urology* 1994; 43: 238–241.
- Sherer DM, Gorelick C, Gabbur N, et al. **Color Doppler imaging and 3-dimensional sonographic findings of urinary bladder leiomyoma.** *J Ultrasound Med* 2007; 26: 667–670.
- Timurkaan N, Yener Z and Yüksel H. **Leiomyoma of the urinary bladder in a goat.** *Aust Vet J* 2001; 79: 708–709.
- Buzatto AB, Elias F, Franzoni MS, et al. **Long-term survival of a cat with primary leiomyosarcoma of the urinary bladder.** *Vet Sci* 2019; 6: 60.
- Burk RL, Meierhenry EF and Schaubhut CW, Jr. **Leiomyosarcoma of the urinary bladder in a cat.** *J Am Vet Med Assoc* 1975; 167: 749–751.
- Hamlin AN, Chadwick LE, Fox-Alvarez SA, et al. **Ultrasound characteristics of feline urinary bladder transitional cell carcinoma are similar to canine urinary bladder transitional cell carcinoma.** *Vet Radiol Ultrasound* 2019; 60: 552–559.
- Mok J, Park J, An S, et al. **Leiomyosarcoma of urinary bladder in a Yorkshire terrier dog.** *J Vet Clin* 2020; 37: 91–95.
- Norris AM, Laing EJ, Valli VE, et al. **Canine bladder and urethral tumors: a retrospective study of 115 cases (1980–1985).** *J Vet Intern Med* 1992; 6: 145–153.
- Patnaik AK, Schwarz PD and Greene RW. **A histopathologic study of twenty urinary bladder neoplasms in the cat.** *J Small Anim Pract* 1986; 27: 433–445.
- Knapp D and McMillan S. **Tumors of the urinary system.** In: Withrow SJ and Page RL (eds). *Withrow & MacEwen's small animal clinical oncology*. 5th ed. St Louis, MO: Elsevier, 2013, pp 572–582.
- Capasso A, Raiano V, Sontuoso A, et al. **Fibrosarcoma of the urinary bladder in a cat.** *JFMS Open Rep* 2015; 1. DOI: 10.1177/2055116915585019.
- Benigni L, Lamb C, Corzo-Menendez N, et al. **Lymphoma affecting the urinary bladder in three dogs and a cat.** *Vet Radiol Ultrasound* 2006; 47: 592–596.
- Léveillé R, Biller DS, Partington BP, et al. **Sonographic investigation of transitional cell carcinoma of the urinary bladder in small animals.** *Vet Radiol Ultrasound* 1992; 33: 103–107.
- Greci V, Rocchi PM, Sontuoso AF, et al. **Primary fibrosarcoma of the urinary bladder in a cat: follow-up after incomplete surgical excision.** *JFMS Open Rep* 2017; 3. DOI: 10.1177/2055116917714881.

- 22 Koestner A and Higgins RJ. **Tumors of the urinary system.** In: Meuten DJ (ed). *Tumors in domestic animals.* 4th ed. Ames, IA: Iowa State Press, 2002, pp 509–546.
- 23 Nyland TG, Wallack ST and Wisner ER. **Needle-tract implantation following US-guided fine-needle aspiration biopsy of transitional cell carcinoma of the bladder, urethra, and prostate.** *Vet Radiol Ultrasound* 2002; 43: 50–53.
- 24 Fulkerson CM and Knapp DW. **Management of transitional cell carcinoma of the urinary bladder in dogs: a review.** *Vet J* 2015; 205: 217–225.
- 25 Martinez I, Mattoon JS, Eaton K, et al. **Polypoid cystitis in 17 dogs (1978–2001).** *J Vet Intern Med* 2003; 17: 499–509.