



Research article

Value of ^{18}F -FDG PET/CT in the detection of occult malignancy in patients with dermatomyositis

Xiuming Li, Haibo Tan *

PET Center, Huashan Hospital of Fudan University, Shanghai, 200235, PR China

ARTICLE INFO

Keywords:

Molecular biology
Cancer research
Medical imaging
Nuclear medicine
Radiology
Dermatomyositis
Malignancy
 ^{18}F -FDG PET/CT

ABSTRACT

Aim: Dermatomyositis (DM) is an inflammatory myopathy in adults that is strongly associated with malignancy. The aim of this study was to evaluate whether whole-body ^{18}F -FDG PET/CT imaging can offer a standard option searching for underlying malignancy in DM patients.

Methods: Seventy-five patients diagnosed with DM were referred to our department for whole-body ^{18}F -FDG PET/CT to determine whether the patients suffered from malignant tumor. All PET images were analyzed by two experienced nuclear medicine physicians separately.

Results: According to the ^{18}F -FDG PET/CT results, 19 patients were suspected to suffer from malignant tumor, then biopsy was performed. Of the 19 patients, 17 patients were confirmed to have malignant tumor. The pathological types were: nasopharyngeal carcinoma, rectal cancer, lung cancer, colon cancer, gastric cancer, gallbladder cancer, kidney cancer, ovarian cancer, breast cancer, lymphoma and vertebral metastatic adenocarcinoma of unknown origin. No malignancy was found for the 56 PET-negative patients during follow-up. For the age between 17 patients with malignancy and 58 patients without malignancy, no significant difference was observed.

Conclusion: ^{18}F -FDG PET/CT may be a sensitive and effective method in determining whether the patients with DM suffered from malignant tumor.

1. Introduction

Dermatomyositis (DM) is a form of idiopathic inflammatory myopathy. The morbidity of malignant tumor associated with DM is far higher than that associated with other connective tissue disorders [1, 2, 3]. It is recognized as a paraneoplastic syndrome in adults, and as one of the important causes of mortality in patients with DM [4]. Therefore, early detection of occult malignancies is of great significance for patients with DM.

A comprehensive examination is necessary for determining whether the DM patients would suffer from malignant tumors. However, the detection of occult malignancy in these patients may be either challenging or time consuming, and there is no consensus regarding what tests should be performed [5]. Therefore, it is important to find an effective method for screening occult malignancy in patients with DM.

^{18}F -labeled fluorodeoxyglucose (^{18}F -FDG) positron emission tomography (PET) imaging has been widely used in tumor diagnosis, staging, and making therapeutic plans. It may be a way for detection malignancy in patients with DM.

In this study, clinical data for 75 DM patients who had performed ^{18}F -FDG PET/CT examination and follow up were analyzed to evaluate the value of PET/CT in the detection of occult malignancy in DM patients.

2. Materials and methods

2.1. Subjects

Seventy-five patients (male 36, female 39, age range 24–87 years, mean age 52.89 ± 10.14 years old) have been diagnosed with DM using the criteria proposed by Bohan in 1975¹, underwent ^{18}F -PET/CT scan at PET Center of Huashan Hospital from February 2010 to June 2015. None previous history of malignancy had known in these DM patients. All subjects gave informed consent to participate after a detailed explanation of the procedures involved.

2.2. ^{18}F -FDG PET scanning

Whole body PET scans were performed on a Siemens Biograph 64 PET/CT scanner at the department of the PET center of Huashan Hospital

* Corresponding author.

E-mail address: haibotan@163.com (H. Tan).

of Fudan University, China. All patients were instructed to fast and not consume beverages, except for water, for at least 6h before the PET/CT scan, and should remain seated or recumbent and silent to minimize ^{18}F -FDG uptake in muscles during the injection of ^{18}F -FDG and the subsequent uptake phase. ^{18}F -FDG PET/CT scans were started 60 min after intravenous administration of 275–370 MBq ^{18}F -FDG. Attenuation correction of PET images with CT, image reconstruction and fusion were processed automatically.

2.3. Imaging processing

Images were reconstructed using OSEM (iterative ordered subset expectation maximization weighted attenuation) algorithm. The number of iterations was 6 and number of subsets was 16. PET and CT images were fused. MSV software installed on a Wizard workstation (CTI Medical Systems, Knoxville, TN, USA) was used to view the images.

2.4. Data analysis

All PET images were analyzed by two experienced nuclear radiologists separately to reach a consensus. CT images were visually reviewed by two radiologists.

2.5. Follow-up

The median follow-up period was 36.5 months ranging from 12 months to 52 months, and the rate of follow-up was up to 100%. Results from pathology and follow up were compared with imaging results.

2.6. Statistical analysis

All the data analyses were performed using the statistical software packages SPSS 11.5 (SPSS Inc., Chicago, IL). Sensitivity, specificity, positive predictive value (PPV), negative predictive value (NPV) were estimated by using pathology as 'gold standard'. Comparisons of categorical data were carried out by use of the unpaired two-tailed Student *t* test. Data were presented as means \pm standard deviations (SD). P values of <0.05 were considered statistically significant.

3. Results

According to the ^{18}F -FDG PET/CT results, 19 patients were suspected to suffer from malignant tumors, then biopsy was performed. Of the 19 patients, 17 patients were confirmed to suffer from malignant tumors by pathology detection. The incidence of DM with malignancies was 22.67%

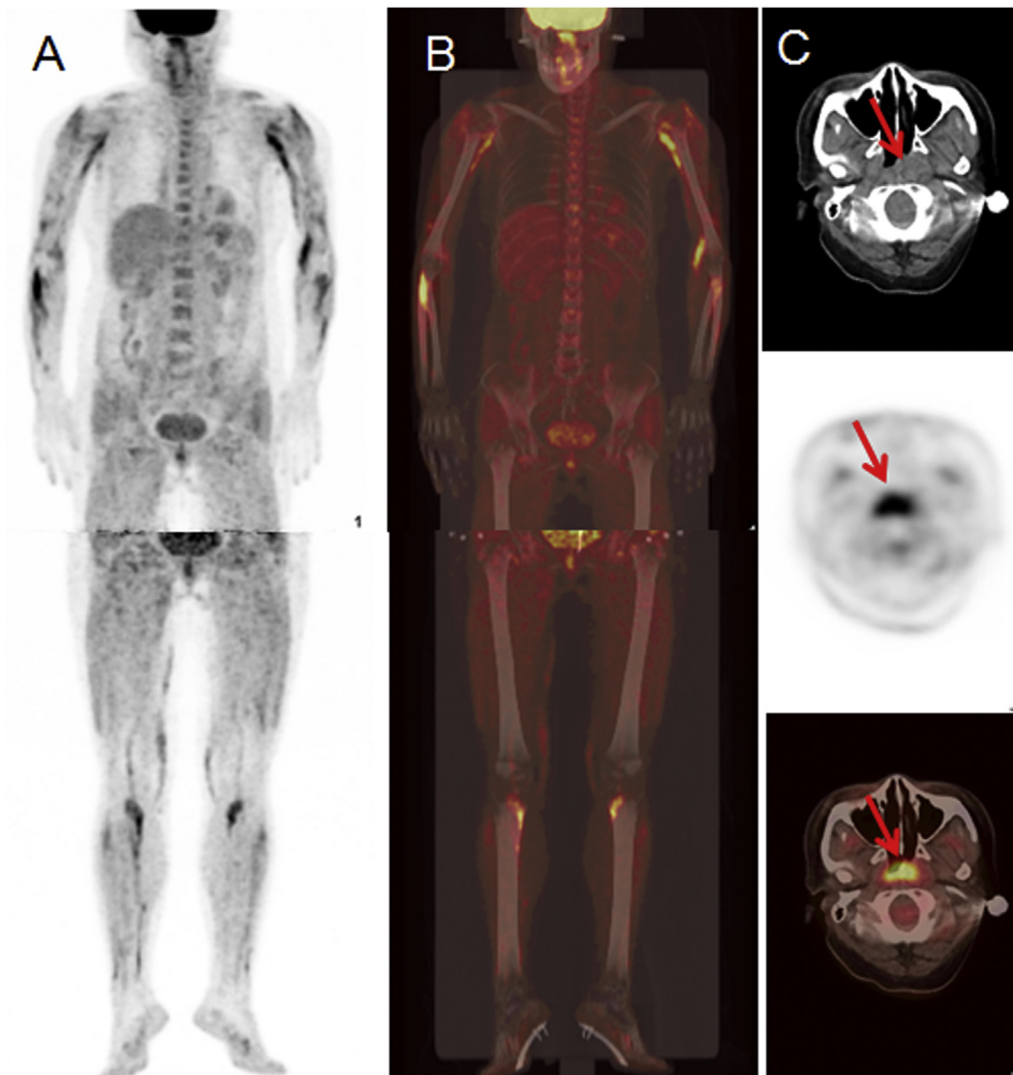


Figure 1. A 41-year-old female was diagnosed with dermatomyositis (Table 1, No 15). A-B, PET/CT images showed increased ^{18}F -FDG uptake in muscles, especially in limb muscles. C, Increased ^{18}F -FDG uptake was seen in the left nasopharynx with nasopharyngeal wall thickening, nasopharyngeal carcinoma was suspected (arrow). The pathological result showed it was nasopharyngeal carcinoma.

in these patients. The pathological types were: nasopharyngeal carcinoma (4/17, 23.53%, [Figure 1](#)), rectal cancer (3/17, 17.65%), lung cancer (2/17, 11.76%), colon cancer, gastric cancer, gallbladder cancer, kidney cancer, ovarian cancer ([Figure 2](#)), breast cancer, lymphoma and vertebral metastatic adenocarcinoma of unknown origin (1/17 each, 5.89%). Of the 17 DM patients suffered from malignant tumors, 8 cases were found metastatic lymph node and distant metastasis by PET scan ([Table 1](#)). There were three cases of false positive or (and) false negative ^{18}F -FDG PET/CT results. One was suspected lymphoma and was later confirmed to be reactive hyperplasia of the lymph node by fine-needle puncture biopsy pathology ([Table 1](#), No 19). Another was suspected sigmoid colon cancer and was later proved to be colonic tubular adenoma by endoscopic biopsy ([Table 1](#), No 17). Interestingly, for the third patient ([Table 1](#), No 18, [Figure 3](#)), a suspected malignant duodenal lesion was confirmed to be chronic inflammation by pathology while ^{18}F -PET/CT missed the left breast cancer lesion (false negative). Diagnostic accuracy showed that there were 16 true positive and 55 true negative. The sensitivity of PET/CT was found to be 94%, specificity 95%, PPV 84%,

NPV 98%. No malignancy was found in the 56 PET-negative patients during follow-up.

The age of the 17 DM patients with malignant tumors ranged from 30 to 87 years. For the age between 17 patients with malignancy and 58 patients without malignancy, no significant difference was observed (56.82 ± 14.11 vs. 58.91 ± 14.63 years, $p = 0.58$).

4. Discussion

In 1916, Stertz reported the comorbidity of DM and malignant tumors for the first time [6]. Since then, increasing number of similar reports appeared which attracted clinical physician attention [7, 8, 9, 10, 11, 12]. The risk of malignant tumors in the DM patients is approximately 1.8–3.6 folds of the general population [13]. The reported rate of malignancy in DM varies markedly, ranging from 6–60%, probably due to substantial differences among studies [8, 9, 10, 11, 12]. In our study, malignancies were found in 22.67% of all patients. Malignancy is regarded as one of the most important complications affecting the

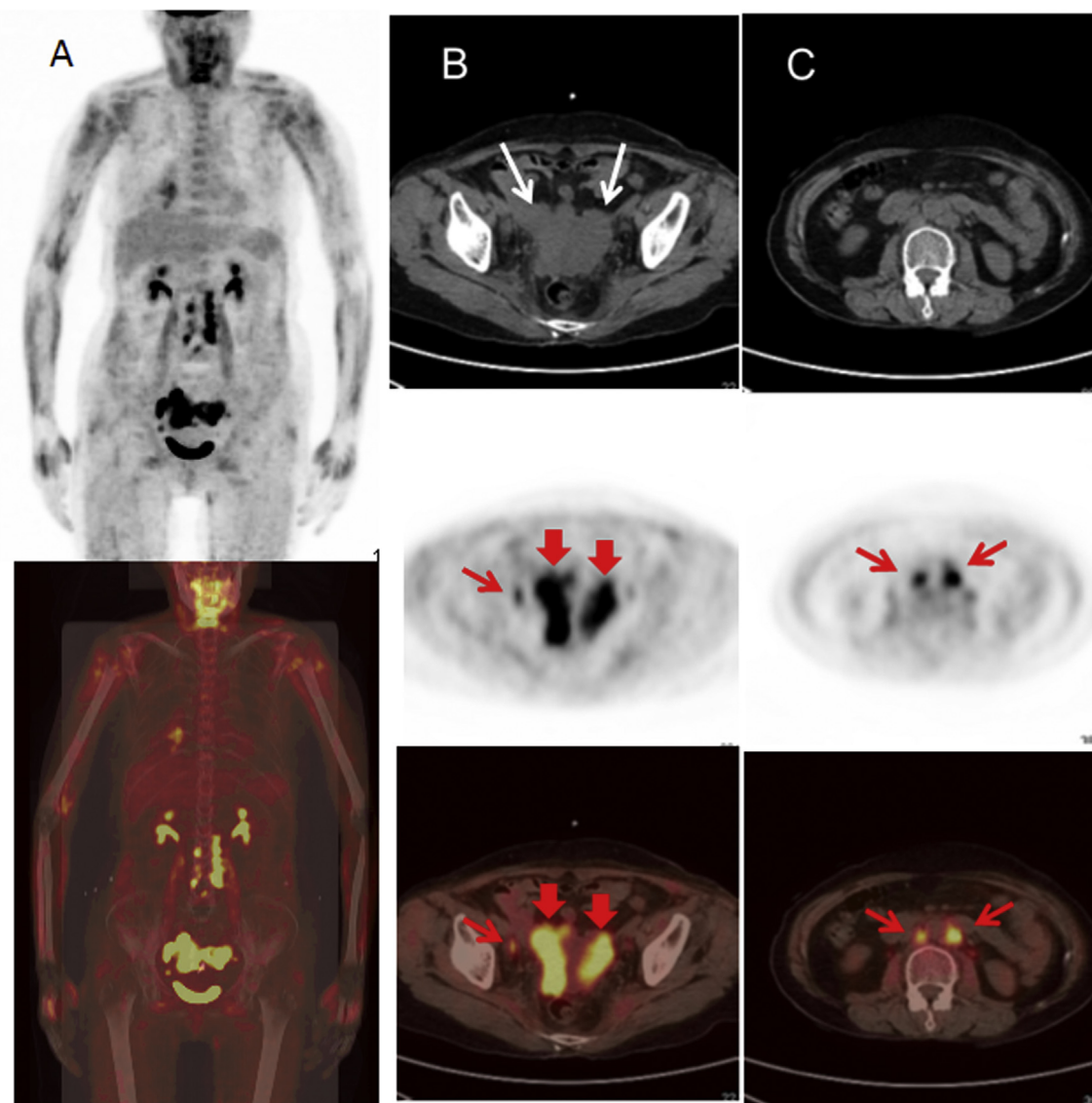


Figure 2. A 61-year-old female was diagnosed with dermatomyositis ([Table 1](#), No 5). A, PET/CT images showed increased ^{18}F -FDG uptake in muscles. B–C, CT images showed bilateral ovarian masses (white arrows). Marked ^{18}F -FDG uptake can be seen in bilateral ovarian masses (red thick arrows), pelvic and post-peritoneal lymph nodes (red thin arrows). Bilateral ovarian cancer with pelvic and post-peritoneal lymph node metastasis was considered. The pathological result showed it was ovarian adenocarcinoma.

Table 1. The follow-up results of the 19 DM patients with suspicious malignant tumor found on ^{18}F -FDG PET/CT.

No	Gender	Age	PET Imaging	Pathologic results
1	M	61	Gallbladder carcinoma with lymph node metastasis	Gallbladder adenocarcinoma
2	M	30	Left nasopharyngeal cancer with skull base invasion and bilateral Cervica lymph node metastasis	Nasopharyngeal poorly differentiated squamous cell carcinoma
3	M	56	Lung cancer of the right middle lobe with mediastinal and left hilar lymph node metastasis	Pulmonary adenocarcinoma
4	F	54	Left nasopharyngeal cancer with neck lymph node metastasis	Nasopharyngeal carcinoma (undifferentiated type)
5	F	61	Bilateral ovarian cancer with pelvic and post-peritoneal lymph node metastasis	Ovarian adenocarcinoma
6	M	51	Rectal cancer	Rectal adenocarcinoma
7	F	49	Rectal cancer with hepatic and mesenteric lymph node metastasis	Rectal adenocarcinoma
8	M	54	Rectal cancer with pelvic lymph node metastasis	Rectal adenocarcinoma
9	M	49	Lymphoma	Diffuse large B-cell lymphoma
10	M	51	malignancy of the gastric body with para-gastric and post-peritoneal lymph node metastasis	Gastric adenocarcinoma
11	M	87	Metastatic vertebral tumor with unknown primary tumor	Metastatic adenocarcinoma
12	M	60	Lung cancer of the left hila	Lung squamous cell carcinoma
13	F	85	Ascending colon cancer	Colon adenocarcinoma
14	F	69	Kidney cancer	Renal adenocarcinoma
15	F	41	Left nasopharyngeal cancer	Nasopharyngeal carcinoma (undifferentiated type)
16	M	61	Righr nasopharyngeal cancer	Nasopharyngeal carcinoma (undifferentiated type)
17	M	57	Sigmoid colon cancer	Colonic tubular adenoma
18	F	47	Duodenal cancer	(1)chronic inflammation of the duodenal mucosa (2) invasive ductal carcinoma of the left breast Reactive hyperplasia
19	F	50	Lymphoma involving lymph nodes and the spleen	Reactive hyperplasia of the lymph nodes, splenic congestion

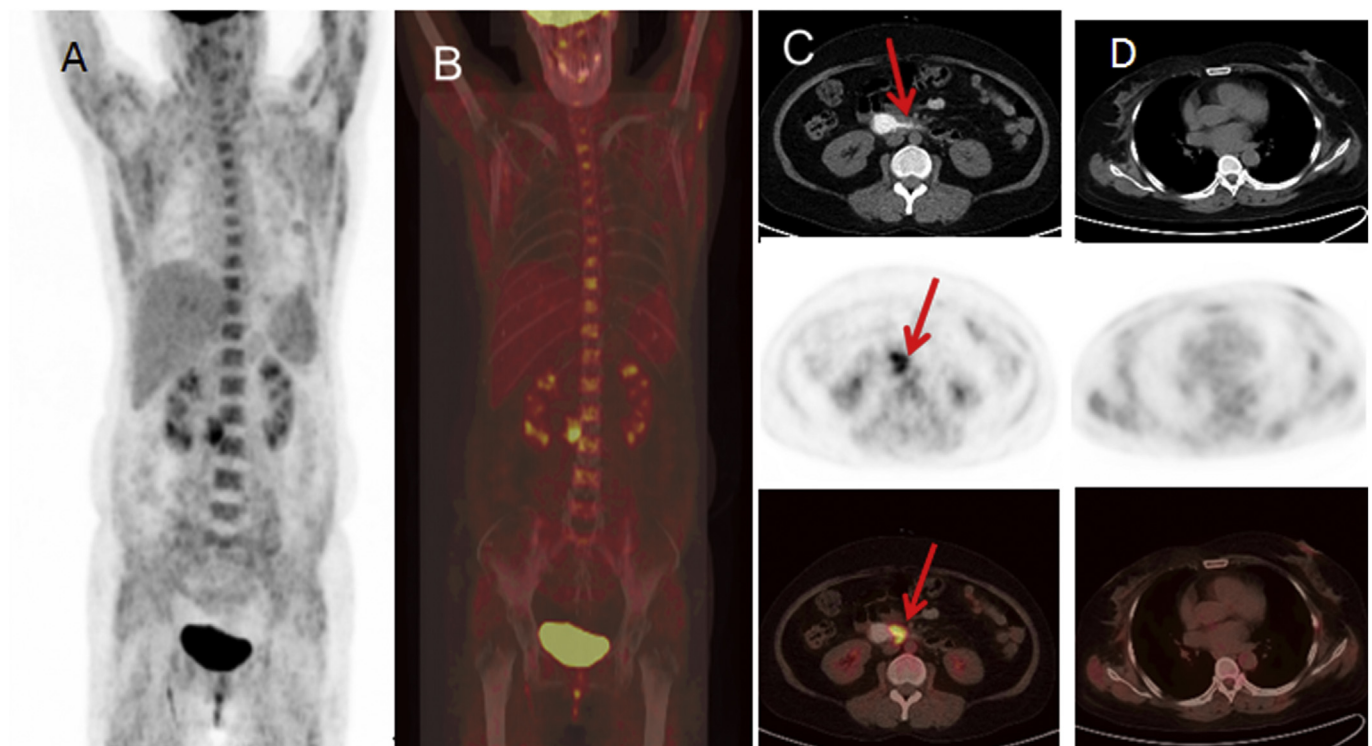


Figure 3. A 47-year-old female was diagnosed with dermatomyositis (Table 1, No 17). A-B, PET/CT maximum intensity projection images showed increased ^{18}F -FDG uptake in muscles. C, Duodenal local bowel wall thickening and luminal stenosis can be seen with marked ^{18}F -FDG uptake (arrow). D, No abnormal density lesions or abnormal ^{18}F -FDG uptake was found in bilateral breast. The pathologic diagnosis revealed that: (1) The lesion in duodenum with marked ^{18}F -FDG uptake was caused by chronic inflammation of the duodenal mucosa; (2) Invasive ductal carcinoma of the left breast was confirmed by surgery.

prognosis of DM patients [4]. Therefore, early detection and treatment of the malignancy in DM patients is beneficial to them.

The detection of occult malignancy in DM patients may be difficult and time consuming, and there is no consensus regarding which investigations should be performed [5]. PET has been widely used in early diagnosis, staging of malignant tumors and differential diagnosis of benign or malignant tumors, thus, PET imaging could be helpful for the

detection of malignant tumors in DM patients, and could reduce unnecessary investigations [14].

The study showed that 17 patients suffered from malignant tumors in 75 DM patients, and ^{18}F -FDG PET/CT found 16 patients suffering from malignant tumor in the 17 patients. Furthermore, PET imaging contributes to tumor stage and provide guidance for further treatment. In the 17 patients, ^{18}F -FDG PET/CT found metastatic lymph node and distant

metastasis in 8 cases (Table 1). But ^{18}F -FDG PET/CT imaging can cause false-positive results. There were false positive cases in this study (Table 1, No 17, 18, 19). ^{18}F -FDG was not the specific imaging agent for cancers. Even with higher sensitivity, there are also false positive cases, especially those caused by inflammation. Inflammatory reaction sites, and even some benign tumors also uptake FDG [15, 16, 17, 18]. Therefore, for DM patients with suspected malignancy on PET imaging, especially those with single lesion or no obvious metastasis, biopsy is necessary to exclude a possible false positive lesion.

Our study showed that there could be false negative results in ^{18}F -FDG PET/CT imaging of the DM patients with malignant tumors (Table 1, No 17). Though we found that there was no significant difference in age between DM patients with malignancy and those without, we found that among these DM patients with malignant tumor, 16 patients were older than 40 years, and only one patient was less than 40 years (Table 1) which is consistent with previous studies. Some studies indicated DM patients over 40 years old were more likely to suffer malignant tumor than those under the age of 40^{10, 19}. We recommend that for those DM patients with negative PET scan but older than 40, follow-ups be necessary.

Nasopharyngeal carcinoma was the most prevalent form of malignancy observed in our patients. This result is not consistent with early reports. The studies carried out in western countries showed that ovarian cancer, colorectal cancer, breast cancer and lung cancer were the most frequent malignancies [2, 19, 20]. A Japanese study showed gastric cancer was the most frequently type of malignancy among Japanese patients with DM [21]. These results suggest that the types and sites of malignancy in patients with DM are consistent with the expected malignant tumors in each ethnic or regional population.

Recently, DM disease specific autoantibody anti-TIF-1 γ has been recognized as a valuable tool to identify the DM patients with high risk of cancer [22, 23]. Our findings indicate that PET/CT examination is useful for diagnosing cancer-associated myositis and guiding disease management. Furthermore, due to the limitation of sample size, follow-up studies would also be carried out in our patient cohort to further clarify the relationships between PET/CT results and eventual clinical outcomes of DM patients.

5. Conclusions

In conclusion, ^{18}F -FDG PET/CT is a sensitive and effective method in determining whether the patients with DM suffer from a malignant tumor. However, ^{18}F -FDG PET/CT imaging also has false positive and false negative, so it is still necessary to combine this technology with clinical assessment.

Declarations

Author contribution statement

Xiuming Li: Performed the experiments; Contributed reagents, materials, analysis tools or data; Wrote the paper.

Haibo Tan: Conceived and designed the experiments; Analyzed and interpreted the data; Wrote the paper.

Funding statement

This work was supported by the Shanghai Committee of Science and Technology Fund (15ZR1405400), the Shanghai Municipal Commission

of Health and Family Planning Fund (201440596), the Traditional Chinese Medicine Research Fund of Shanghai Municipal Commission of Health and Family Planning (2014JP004A).

Competing interest statement

The authors declare no conflict of interest.

Additional information

No additional information is available for this paper.

References

- [1] J.K. Qiang, W.B. Kim, A. Baibergenova, et al., Risk of malignancy in dermatomyositis and polymyositis, *J. Cutan. Med. Surg.* 21 (2017) 131–136.
- [2] O. Szalmás, M. Nagy-Vince, K. Dankó, et al., Clinical features of patients with juvenile and adult dermatomyositis, *Orv. Hetil.* 156 (2015) 1491–1496.
- [3] L. Sun, Y. Dong, N. Zhang, et al., [F]Fluorodeoxyglucose positron emission tomography/computed tomography for diagnosing polymyositis/dermatomyositis, *Exp Ther Med* 15 (2018) 5023–5028.
- [4] H. Yang, Q. Peng, L. Yin, et al., Identification of multiple cancer-associated myositis-specific autoantibodies in idiopathic inflammatory myopathies: a large longitudinal cohort study, *Arthritis Res. Ther.* 19 (2017) 259.
- [5] N. Liao, C. Ooi, C. Reid, et al., F-18 FDG PET/CT detection of mediastinal malignancy in a patient with dermatomyositis, *Clin. Nucl. Med.* 32 (2007) 304–305.
- [6] G. Stertz, Polymyositis, *Berl Klin Wochenschr* 53 (1916) 489.
- [7] M. Shah, N.B. Shah, K.G. Moder, et al., Three cases of dermatomyositis associated with papillary thyroid cancer, *Endocr. Pract.* 19 (2013) 154–157.
- [8] S.Y. Yang, B.K. Cha, G. Kim, et al., Dermatomyositis associated with hepatitis B virus-related hepatocellular carcinoma, *Korean J. Intern. Med.* 29 (2014) 231–235.
- [9] N. Fukuhara, Y. Tanino, S. Sato, et al., Early detection of colon cancer by increased serum level of Krebs von den Lungen-6 in a patient with dermatomyositis-associated interstitial pneumonia, *Sarcoidosis Vasc. Diffuse Lung Dis.* 32 (2015) 265–270.
- [10] J. Udkoff, P.R. Cohen, Amyopathic dermatomyositis: a concise review of clinical manifestations and associated malignancies, *Am. J. Clin. Dermatol.* 17 (2016) 509–518.
- [11] T. Owada, R. Maezawa, K. Kurasawa, et al., Detection of inflammatory lesions by F-18 fluorodeoxyglucose positron emission tomography in patients with polymyositis and dermatomyositis, *J. Rheumatol.* 39 (2012) 1659–1665.
- [12] Y. Li, Y. Zhou, Q. Wang, Multiple values of F-FDG PET/CT in idiopathic inflammatory myopathy, *Clin. Rheumatol.* 36 (2017) 2297–2305.
- [13] Y. Yazici, L.J. Kagen, The association of malignancy with myositis, *Curr. Opin. Rheumatol.* 12 (2000) 498–500.
- [14] S. Mahmood, S. Rodríguez Martínez de Llano, ^{18}F -FDG PET detection of unknown primary malignancy in dermatomyositis, *Clin. Nucl. Med.* 37 (2012) 204–205.
- [15] H. Tan, Y. Guan, J. Zhao, et al., Findings of pulmonary amyloidosis on dual phase FDG PET/CT imaging, *Clin. Nucl. Med.* 35 (2010) 206–207.
- [16] H. Zhuang, M. Pourdehnad, E.S. Lambright, et al., Dual time point ^{18}F -FDG PET imaging for differentiating malignant from inflammatory processes, *J. Nucl. Med.* 42 (2001) 1412–1417.
- [17] H. Tan, L. Chen, Y. Guan, et al., Comparison of MRI, ^{18}F -FDG, and ^{11}C -choline PET/CT for their potentials in differentiating brain tumor recurrence from brain tumor necrosis following radiotherapy, *Clin. Nucl. Med.* 36 (2011) 978–981.
- [18] C.L. Ho, S.C. Yu, D.W. Yeung, ^{11}C -acetate PET imaging in hepatocellular carcinoma and other liver masses, *J. Nucl. Med.* 44 (2003) 213–221.
- [19] C.L. Hill, Y. Zhang, B. Sigurgeirsson, et al., Frequency of specific cancer types in dermatomyositis and polymyositis: a population-based study, *Lancet* 357 (2001) 96–100.
- [20] R. Buchbinder, A. Forbes, S. Hall, et al., Incidence of malignant disease in biopsy-proven inflammatory myopathy. A population-based cohort study, *Ann. Intern. Med.* 134 (2001) 1087–1095.
- [21] K. Azuma, H. Yamada, M. Ohkubo, et al., Incidence and predictive factors for malignancies in 136 Japanese patients with dermatomyositis, polymyositis and clinically amyopathic dermatomyositis, *Mod. Rheumatol.* 21 (2011) 178–183.
- [22] M. Best, N. Molinari, F. Chasset, et al., Use of anti-transcriptional intermediary factor-1 gamma autoantibody in identifying adult dermatomyositis patients with cancer: a systematic review and meta-analysis, *Acta Derm. Venereol.* 99 (3) (2019) 256–262.
- [23] E. Trallero-Araguas, J.A. Rodrigo-Pendas, A. Selva-O'Callaghan, et al., Usefulness of anti-p155 autoantibody for diagnosing cancer-associated dermatomyositis: a systematic review and meta-analysis, *Arthritis Rheum.* 64 (2) (2012) 523–532.