

Case Report

Renal clear cell carcinoma emerging in a transplanted kidney 3 years after return to dialysis. Case report and review of the literature

Ram Elazary¹, Avraham Schlager², Liat Appelbaum³, Gideon Zamir¹ and Itzhak Nir¹

¹Department of Surgery and Transplantation Unit, Hadassah-Hebrew University Medical Center, Ein-Kerem, Jerusalem, Israel, ²Department of Surgery, New York University Hospital, New York, NY, USA and ³Department of Radiology, Hadassah-Hebrew University Medical Center, Ein-Kerem, Jerusalem, Israel

Correspondence and offprint requests to: Ram Elazary; E-mail: ramelazary@hadassah.org.il

Abstract

We present a female patient with end-stage renal disease who was referred to the emergency department with sudden, excruciating pain over the right lower abdomen and flank. Radiologic evaluation following admission revealed a mass, solid in nature, located at the upper pole of the transplanted kidney. The patient was treated with empiric antibiotics and analgesics, and her symptoms subsided over the course of the week. Based on the clinical course and radiological findings, a self-limiting, spontaneous haemorrhage was thought to be the cause of the patient's symptoms. Nevertheless, background malignancy could not be ruled out. Therefore, an interval, elective graft nephrectomy was scheduled. Pathology confirmed the diagnosis of renal clear cell carcinoma.

Keywords: graft; immune suppression; neoplasm; renal cell carcinoma; transplantation

Background

Renal transplantation is the treatment of choice for most patients with end-stage renal failure. Comparing historical to contemporary series, prolonged graft survival coupled with reduction in risk factors, has resulted in better life expectancy. As the patients live longer, late complications become a major challenge. As such, post-transplantation malignancy is a major concern in this respect. Skin cancers are the leading neoplasms encountered in this group population, but other malignancies including renal cell carcinoma in the native kidneys are well reported [1]. The incidence of cancer increases as years pass from the index transplantation.

We describe a case of renal clear carcinoma arising in the kidney allograft 20 years following transplantation. We also review the topic as published in the English medical literature.

Case report

A 66-year-old female was admitted to the emergency department due to severe right flank pain persisting for several hours. The pain was sharp and radiated to the right lower quadrant of the abdomen. The patient graded the pain as 9/10 in severity that was further aggravated by walking or coughing. She denied vomiting, changes in bowel habits or recent trauma to the region. Twenty years prior to admission, she underwent kidney transplantation for chronic glomerulonephritis resulted in ESRD. The allograft was placed at the right iliac fossa. Three years prior to admission, she was placed on haemodialysis due to chronic allograft nephropathy. Other medical problems included: recurrent biliary colic, chronic deep venous insufficiency, osteoporosis, hypothyroidism and a positive serological test for HBV antigen. Her medications included lamivudine, eltroxin, folic acid, omeprazole, low-dose aspirin, calcium and vitamin D supplement. On examination, she appeared to be in distress. Her pulse was 66 b.p.m., temperature 36.7°C and blood pressure 120/60 mmHg. Her physical examination was significant for severe tenderness to palpation over her right lower abdomen and flank. The white blood cell count was 7300 cells/ μ l, with 68% granulocytes. Biochemistry results showed glucose 4.8 mmol/l, urea 12.5 mmol/l and creatinine 470 μ mol/l. Chest X-ray and plain abdominal X-ray were within normal limits. Given the clinical profile, the options of haemorrhage into a renal cyst or infection process were entertained. A contrast enhanced computed tomography (CT) of the abdomen revealed a 3 cm round hypodense mass (22 HU) in the upper pole of the transplanted kidney, with significant surrounding fatty effacement (Figure 1).

The patient was given analgesics and empiric intravenous antibiotics for possible infection. An ultrasound of the lesion demonstrated a complex hypervascular hypoechoic mass (Figure 2). Review of prior studies added significant insight into the case. Abdominal CT, done 2 years back, revealed a subtle, 1 cm hypodense mass in the upper pole of the transplanted kidney. In magnetic resonance

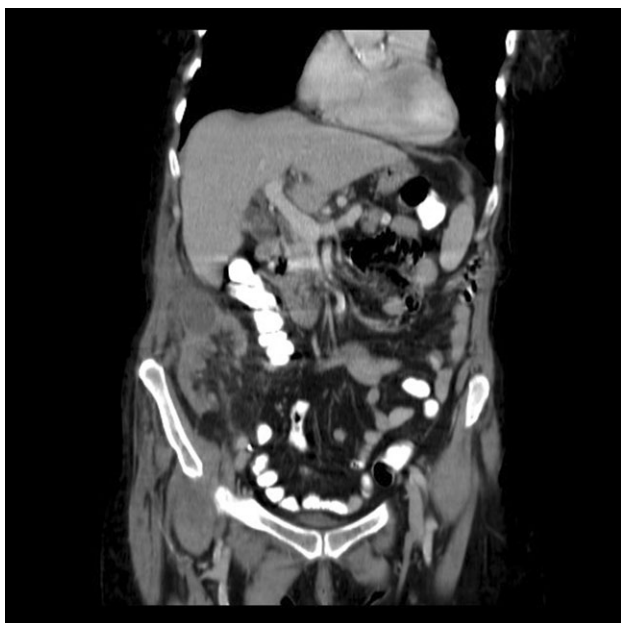


Fig. 1. CT images of the transplanted kidney obtained at admission. Coronal image depicting a 3 cm round hypodense mass at the upper pole of the transplanted kidney.

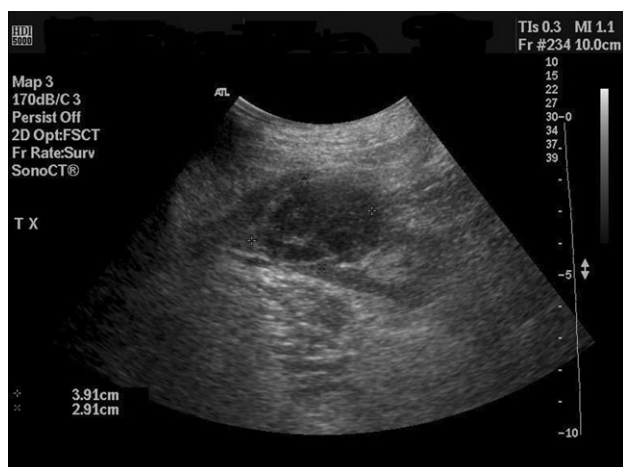

Fig. 2. Transverse US image of the upper pole of the transplanted kidney demonstrating a complex hypoechoic mass with no through transmission.

cholangiopancreatography (MRCP), performed around that time for biliary symptoms, the transplanted kidney was couched incidentally in T2-weighted series. It showed a 2 cm round mass of low T2 signal intensity. The transplanted kidney was not included in further study series and was not evaluated with T1-weighted imaging. These findings on MR alone can be compatible with a solid mass or a complex cyst. The solid appearance on the current ultrasound coupled with the increase in size as demonstrated by retrospective radiological data, made it highly suspicious for renal cell neoplasm.

The patient completed a 7-day course of antibiotics during which time she experienced a complete clinical recovery. Blood cultures taken on admission were negative, and the patient was discharged. However, because the differ-

ential diagnosis included possible malignancy, the decision was made to perform an elective graft nephrectomy. Histopathology findings showed renal clear cell with extensive tumour necrosis and surgical margins free of tumour. She was discharged on the 7th post-operative day and was scheduled for further outpatient oncological treatment and follow-up.

Discussion

The advent of kidney transplantation has changed both quality and life expectancy in patients with end-stage renal disease (ESRD). The introduction of potent immunosuppressive agents in the early 1990s has led to a significant decrease in the incidence of acute and chronic rejection of the allograft kidney. Death with a functioning kidney is now the leading cause for late loss of the allograft, with cardiovascular diseases, infections and neoplasms as the main causes [2]. Compared to an age-matched healthy population, patients who underwent organ transplantation are at an increased risk for developing cancer [1]. London *et al.* showed that after 20 years of immune suppression therapy, 70 out of 918 recipients (7.6%) developed neoplasms. Furthermore, 10 of the 70 patients had developed more than one type of cancer [3]. It was calculated that the risk for developing cancer after 10 and 20 years from transplantation was 14% and 40%, respectively. London *et al.* also noted that more than half of the patients who developed cancer, had skin neoplasm. Birkeland *et al.* showed that 209 patients among 1821 kidney transplant patients, who were enrolled in the Danish Registry, developed neoplasm (11.4%) [4]. Additionally, in a series published by Arichi *et al.* of a cohort of 429 recipients of kidney grafts, the prevalence of neoplasm was 13% [5]. A total of 15% of all patients who had cancer developed skin neoplasm and 13% had renal clear cell carcinoma of the native kidneys. In both groups, patients' age and the time since transplantation were found to be statistically significant risk factors.

Although environmental and genetic factors certainly play a role in cancer development, in this subgroup the main cause for elevated incidence of neoplasm is related to chronic immune suppression therapy [6]. It has been shown that patients on cyclosporine therapy have a dose-dependent risk to develop neoplasm. The associations between Epstein Barr virus (EBV) and lymphoproliferative disorder (PTLD), Human herpes virus 8 (HHV-8) and Kaposi's sarcoma, and Human papilloma virus (HPV) and skin cancer have already been presented in several studies. Immune suppressive agents can induce progression into cancer by pure pharmacologic action. It was demonstrated that cyclosporine promotes cancer progression via growth factor (TGF- β) transformation, an effect that is independent of the recipient's immune system. In contradiction, sirolimus has recently been shown to cause regression of tumours, although significance of this protective effect *in vivo* is still questionable [7].

The incidence of renal cell carcinoma is increased both in kidney transplant and dialysis patients [8]. It has been hypothesized that the high prevalence of polycystic kidney disease and analgesic nephropathy among these patients

could explain the phenomena. In a series published by Penn of 256 patients who developed renal neoplasms after kidney transplantation, 24 of them developed the tumour in their kidney graft (16 of them were renal parenchymal tumours) [9]. Atitavvas *et al.* published a series of 270 kidney recipients in which 18 patients developed cancer [10]. In their series, seven patients had transitional cell carcinoma of the urinary tract and only one patient had renal cell carcinoma that was located at the native kidney. Zani *et al.* published a series of three patients who developed cancer in the transplanted kidney [11]. Two of them were transitional cell carcinoma and one was renal cell carcinoma.

The development neoplasms in a kidney allograft is a relatively rare source of pathology [12,13]. However, it is a treatable one. Although post-operative cancer surveillance for kidney recipients does not routinely include screening for renal neoplasm, several studies have recommended that kidney transplant recipients should undergo annual sonography of both the transplanted and the native kidneys screen for neoplastic changes [14]. In addition to supporting these recommendations, the presented case accentuates additional concerns beyond the role of surveillance. Although this patient has not been receiving immune suppression therapy, she developed a neoplasm that emphasizes two facts: one, a nonfunctional organ is not biologically silent; and second, neoplasms may emerge even without immune suppression. Recurrent pyelonephritis and the need for cessation of immune suppression therapy are the common indications for graft nephrectomy. The decision must be weighed against the unfavourable immunological effect it has on future transplant and significant morbidity entailed by the surgery. *De novo* renal graft malignancy, as presented, raises an additional point to consider. Nevertheless, given the rarity of the phenomena, it is difficult to establish fixed guidelines. One has to rely on good clinical judgment, considering all the above-mentioned 'pro & cons'. Based on our experiences, we believe that annual sonographic surveillance of the transplanted kidney is warranted regardless of the graft functional status.

Conflict of interest statement. None declared.

References

1. Kasiske BL, Snyder JJ, Gilbertson DT *et al.* Cancer after kidney transplantation in the United States. *Am J Transplant* 2004; 4: 905–913
2. Pascual M, Theruvath T, Kawai T *et al.* Strategies to improve long-term outcomes after renal transplantation. *N Engl J Med* 2002; 346: 580–590
3. London NJ, Farmery SM, Will EJ *et al.* Risk of neoplasia in renal transplant patients. *Lancet* 1995; 346: 403–406
4. Birkeland SA, Lokkegaard H, Storm JJ. Cancer risk inpatients on dialysis and after renal transplantation. *Lancet* 2000; 355: 1886–1887
5. Arichi N, Kishikawa H, Nishimura K *et al.* Malignancy following kidney transplantation. *Transplant Proc* 2008; 40: 2400–2402
6. Dantal J, Souillou JP. Immunosuppressive drugs and the risk of cancer after organ transplantation. *N Engl J Med* 2005; 352: 1371–1373
7. Wang SM, Tai HC, Chueh SC *et al.* Sirolimus does not absolutely abolish the occurrence/recurrence of urothelial carcinoma in renal transplant recipients. *Transplant Proc* 2008; 40: 2395–2396
8. McHayleh W, Morcos JP, Wu T *et al.* Renal cell carcinoma from a transplanted allograft: two case reports and a review of the literature. *Clin Genitourin Cancer* 2008; 6: 53–55
9. Penn I. Primary kidney tumors before and after transplantation. *Transplantation* 1995; 59: 480–485
10. Atitavvas T, Jirasiritham S, Ngorsakun P *et al.* Malignancies in renal transplant patients: 15 years experience in Thailand. *Transplant Proc* 2008; 40: 2403–2404
11. Zani D, Simeone C, Antonelli A *et al.* Cancer in kidney transplantation. *Urol Int* 2008; 80: 329–331
12. Rouprêt M, Peraldi MN, Thauinat O *et al.* Renal cell carcinoma of the grafted kidney: how to improve screening and graft tracking. *Transplantation* 2004; 77: 146–148
13. Schwarz A, Vatandaslar S, Merkel S *et al.* Renal cell carcinoma in transplant recipients with acquired cystic kidney disease. *Clin J Am Soc Nephrol* 2007; 2: 750–756
14. Neuzillet Y, Lay F, Luccioni A *et al.* *De novo* renal cell carcinoma of native kidney in renal transplant recipients. *Cancer* 2005; 103: 251–257

Received for publication: 5.5.09; Accepted in revised form: 16.7.09