

Case report

Korean J Pediatr 2013;56(6):265-268
http://dx.doi.org/10.3345/kjp.2013.56.6.265
pISSN 1738-1061 • eISSN 2092-7258



Korean J Pediatr

A case of familial X-linked thrombocytopenia with a novel *WAS* gene mutation

Eu Kyoung Lee, MD¹, Yeun-Joo Eem, MD¹, Nack-Gyun Chung, MD¹, Myung Shin Kim, MD², Dae Chul Jeong, MD¹

Departments of ¹Pediatrics and ²Clinical Laboratory, The Catholic University of Korea College of Medicine, Seoul, Korea

Wiskott-Aldrich syndrome (WAS) is an inherited X-linked disorder. The *WAS* gene is located on the X chromosome and undergoes mutations, which affect various domains of the *WAS* protein, resulting in recurrent infection, eczema, and thrombocytopenia. However, the clinical features and severity of the disease vary according to the type of mutations in the *WAS* gene. Here, we describe the case of a 4-year-old boy with a history of marked thrombocytopenia since birth, who presented with recurrent herpes simplex infection and late onset of eczema. Examination of his family history revealed that older brother, who died from intracranial hemorrhage, had chronic idiopathic thrombocytopenia. Therefore, we proceeded with genetic analysis and found a new deletion mutation in the *WAS* gene: c.858delC (p.ser287Leufs*21) as a hemizygous form.

Corresponding author: Dae Chul Jeong, MD
Department of Pediatrics, Seoul St. Mary's Hospital,
The Catholic University of Korea College of Medicine,
222 Banpo-daero, Seocho-gu, Seoul 137-701, Korea
Tel: +82-2-2258-2828
Fax: +82-2-537-4544
E-mail: dcjeong@catholic.ac.kr

Received: 17 August 2012

Revised: 8 October 2012

Accepted: 25 October 2012

Key words: Wiskott-Aldrich syndrome, Mutation, Sequence deletion

Introduction

Wiskott-Aldrich syndrome (WAS) is an X-linked recessive syndrome characterized by thrombocytopenia with small defective platelets, atopic dermatitis, recurrent infections with immunodeficiency, and early death of the affected males^{1,2}. Numerous studies have revealed a strong association between genotype and phenotype for the *WAS* gene³. The various mutations in the *WAS* gene lead to the presentation of 3 distinct clinical phenotypes: the classic WAS; the milder X-linked thrombocytopenia (XLT) variant; and congenital X-linked neutropenia (XLN)^{2,4}. Whether the clinical phenotype of WAS or XLT is severe or mild is strongly influenced by the effect of the mutation on protein expression^{1,4,5}. Thus, genotype-phenotype correlation in WAS/XLT is not absolute^{2,4}. Only one-third of WAS patients represent the triad, recurrent infection, eczema, and thrombocytopenia particularly during infancy¹. In the present case, we report a patient with WAS caused by a novel deletion mutation presenting as familial XLT, for which the clinical course of disease was mild in infant and toddler period, but rapidly worsened afterward.

Case report

A 4-year-old boy had frequently visited the outpatient clinic for the past year with refractory thrombocytopenia since birth and recurrent herpes simplex infections. He had been treated with intravenous immunoglobulin and steroid since birth; however, refractory thrombocytopenia had persisted. Bone marrow aspiration and biopsy showed slightly increased megakaryocyte counts without the presence of any abnormal cells. The atopic skin manifestations did not appear until 3 years of age. Regarding family history,

Copyright © 2013 by The Korean Pediatric Society

This is an open-access article distributed under the terms of the Creative Commons Attribution Non-Commercial License (<http://creativecommons.org/licenses/by-nc/3.0/>) which permits unrestricted non-commercial use, distribution, and reproduction in any medium, provided the original work is properly cited.

his older brother who was diagnosed as chronic thrombocytopenia died due to intracranial hemorrhage at the age of 10 years, but his 14-year-old sister was healthy.

Until the age of 4, complete blood count showed only thrombocytopenia, hemoglobin (Hb) 11.9 g/dL, white blood cells (WBC) 6,900/ μ L with 65.0% segment neutrophils, and platelets 7,000/ μ L. After developing recurrent infection and eczema, his laboratory findings revealed neutropenia state such as Hb 8.8 g/dL, WBC 1,690/ μ L with 27.0% segment neutrophils, platelets 2,000/ μ L, and reticulocyte count 3.13%. Serum immunoglobulin levels were within normal ranges for immunoglobulin IgG, IgA, and IgM although the level of IgE was slightly increased. Lymphocyte subset analysis showed CD4⁺ at 21.1% and CD8⁺ at 44.4%, with a CD4⁺/CD8⁺ ratio of 2.1. Blood chemistry data was within normal ranges. Single donor platelet and pure red cell transfusion were performed with methylprednisolone pulse therapy for 3 days. However, the platelet counts did not recover. Based on the findings of recurrent infection, refractory thrombocytopenia, and a family history of an elder brother with chronic thrombocytopenia, we decided to perform genetic analysis for WAS after informed consent was obtained. After diagnosis, we evaluated human leukocyte antigen (HLA) typing within the family for hematopoietic stem cell transplantation and performed genetic analysis of the family with genetic counseling. The results showed that his sister was not matched, and we therefore searched for an unrelated HLA-matched donor. While awaiting the HLA-matched donor, his condition rapidly deteriorated with dehydration, petechia, and recurrent epistaxis.

One month later, he was readmitted with fever, subconjunctival

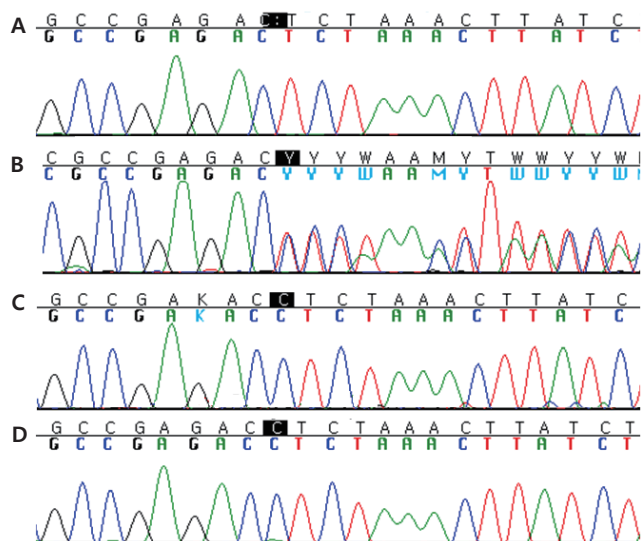


Fig. 1. Direct sequencing analysis of the Wiskott-Aldrich syndrome (*WAS*) gene. Hemizygous deletion in patient (A), heterozygous deletion in mother (B), and normal gene in father and sister (C, D).

hemorrhage, oral mucosal hemorrhage, a pale appearance, and >10 episodes of dark brown-colored vomiting. On the next day, he showed decreased mental status. Because of a strong suspicion of intracranial hemorrhage, emergency brain CT was performed. The CT findings revealed an intracranial hemorrhage in the left frontal lobe and a small intraventricular hemorrhage in the caudate nucleus. Despite aggressive medical and surgical intervention to control the intracranial hemorrhage, he died after three days.

The results of genetic sequence analysis revealed a novel pathogenic deletion mutation in exon 9 of the *WAS* gene: c.858delC (p.ser287Leufs*21) (Fig. 1). This novel pathogenic variant causes the early termination of protein translation. This mutation in the *WAS* gene was identified in his mother later while neither his father nor sister. This result suggested that his brother, who earlier died from chronic thrombocytopenia, also had an inherited *WAS* (Fig. 2).

Discussion

The *WAS* gene encodes a 502-amino acid protein expressed exclusively in the cytoplasm of hematopoietic cells. It possesses 5 distinct domains: an N-terminal WAS protein (WASp)-homology domain 1, a guanosinetriphosphatase binding domain, a proline-rich region with SH3 binding motifs, a verprolin and a cofilin homology domain, and a C-terminal acidic region that interferes with Arp2/3 complex-mediated actin polymerization^{1,2,4-6}. WASp is a regulator of actin polymerization in hematopoietic cells and controls the assembly of actin filaments required for microvesicle formation downstream of protein kinase C and tyrosine kinase signaling^{1,6}. WASp plays critical roles in signal transduction and in the regulation of cytoskeletal reorganization⁷. Approximately 300 different mutations in WASp have been reported thus far, most of which cluster in the first 4 exons and exons 7 and 10^{1,8,9}. The different mutations in WASp lead to the presentation of 3 distinct clinical phenotypes: the classic WAS triad of thrombocytopenia / small platelets, recurrent infections, and eczema; the milder XLT

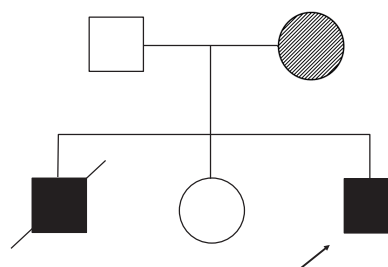


Fig. 2. Pedigree of the patient with Wiskott-Aldrich syndrome (WAS). His mother was a carrier with a mutation in the *WAS* gene, and elder brother expired because of chronic thrombocytopenia with suspected WAS mutation.

variant, characterized predominantly by thrombocytopenia/small platelets; and X-linked congenital neutropenia without the clinical findings characteristic of WAS/XLT intermittent thrombocytopenia^{1,4,6}. Each phenotype is caused by different molecular mechanisms. First, the classic WAS completely averts WASp expression^{1,4,5}. Second, the XLT phenotype is the product of missense mutations that result in expression of defective WASp^{2,4}. Lastly, XLN is caused by gain-of-function mutations that produce constitutively activated WASp^{2,4}. However, the most consistent phenotype-genotype correlation is observed by dividing the patients into 2 categories: WASp-positive (WASp+) if the mutated protein is expressed and of normal size, and WASp-negative (WASp-) if the protein is absent or truncated^{2,4,6}.

The common mutations for XLT are missense mutations in exons 1 and 2 or splice site mutations¹. In cohort studies reported in 2004 and 2010, the missense mutation was the most common type followed by splice site mutations and deletions, but only 1 case of a deletion mutation was found in exon 9^{4,6}. The type of mutation also showed a correlation with the expression of WASp; WASp+ was correlated more highly with missense and splice mutations, while WASp- was correlated more highly with deletion/insertion and nonsense mutations⁶. The deletion genotypes prevent the expression of WASp in most cases, due to a premature termination codon that causes the failure of protein translation⁶. The presence or absence of WASp according to WAS gene mutations had no influence on survival in patients with the XLT phenotype⁴. These patients showed a rare type of deletion mutation in XLT.

Because of the mild clinical characteristics of XLT, some adult XLT patients can be falsely diagnosed with chronic immune thrombocytopenia, which may result in loss of optimal treatment, such as a hematopoietic stem cell transplantation^{2,10}. In this case, the patient's older brother was mis-diagnosed with chronic thrombocytopenia due to a mild clinical presentation, but later he died due to a life-threatening event of intracranial hemorrhage at the age of 10 years. In this case, the late clinical presentations of eczema and recurrent infection delayed the diagnosis of our patient. The boy only presented with refractory thrombocytopenia until 3 years old. His condition was also considered mild according to the scoring system¹¹. Upon presenting with recurrent herpes simplex infection and controllable atopic dermatitis, his WAS score of 2 was still mild¹¹. Classic WAS patients with a high score were reported to be aged <1 year old, while XLT patients with scores of ≤ 2 were reported as being over toddler period, the age between 1 to 3 years¹².

Our novel pathogenic deletion mutation in XLT initially presented with mild clinical symptoms but eventually led to a rapid and severe course of the disease with a high risk of life-threatening intracranial bleeding. Initially, the patient presented only with neonatal refractory thrombocytopenia until 3 years of age, post-

infected neutropenia, and late presentation of eczema, but his disease progressed rapidly with a life-threatening event of intracranial hemorrhage. Due to the phenotypic variability, clinicians should consider the WAS in male patients who present an atypical bleeding tendency, bruising, congenital or early onset of thrombocytopenia¹³. Especially, XLT should not be assumed to follow a mild clinical progression because phenotypes and genotypes do not always correlate. The clinical features and severity of WAS patients are highly varied. Unfortunately, we did not perform the detection of WAS protein in this boy. For this novel mutation, a scoring system, genotype/phenotype correlation, and laboratory findings provided an ineffective prediction.

In conclusion, we report a Korean boy with XLT with a rapid and severe form of disease after toddler age due to a novel deletion mutation in the *WAS* gene.

Conflict of interest

No potential conflict of interest relevant to this article was reported.

References

1. Ariga T. Wiskott-Aldrich syndrome; an x-linked primary immunodeficiency disease with unique and characteristic features. *Allergol Int* 2012;61:183-9.
2. Thrasher AJ. New insights into the biology of Wiskott-Aldrich syndrome (WAS). *Hematology Am Soc Hematol Educ Program* 2009:132-8.
3. Notarangelo LD, Miao CH, Ochs HD. Wiskott-Aldrich syndrome. *Curr Opin Hematol* 2008;15:30-6.
4. Albert MH, Bittner TC, Nonoyama S, Notarangelo LD, Burns S, Imai K, et al. X-linked thrombocytopenia (XLT) due to WAS mutations: clinical characteristics, long-term outcome, and treatment options. *Blood* 2010;115:3231-8.
5. Ochs HD. Mutations of the Wiskott-Aldrich Syndrome protein affect protein expression and dictate the clinical phenotypes. *Immunol Res* 2009;44:84-8.
6. Jin Y, Mazza C, Christie JR, Giliani S, Fiorini M, Mella P, et al. Mutations of the Wiskott-Aldrich Syndrome protein (WASP): hotspots, effect on transcription, and translation and phenotype/genotype correlation. *Blood* 2004;104:4010-9.
7. Blundell MP, Worth A, Bouma G, Thrasher AJ. The Wiskott-Aldrich syndrome: the actin cytoskeleton and immune cell function. *Dis Markers* 2010;29:157-75.
8. Itoh S, Nonoyama S, Morio T, Imai K, Okawa H, Ochs HD, et al. Mutations of the WASP gene in 10 Japanese patients with Wiskott-Aldrich syndrome and X-linked thrombocytopenia. *Int J Hematol* 2000;71:79-83.
9. Kim HJ, Yoo EH, Ki CS, Yoo GH, Koo HH, Kim JW, et al. A novel mutation W252X in the WAS gene in a Korean patient with Wiskott-Aldrich syndrome. *Int J Hematol* 2006;83:426-8.
10. Albert MH, Notarangelo LD, Ochs HD. Clinical spectrum, pathophysiology and treatment of the Wiskott-Aldrich syndrome. *Curr Opin Hema-*

- tol 2010 Nov 11 [Epub]. <http://dx.doi.org/10.1097/MOH.0b013e32834114bc>.
11. Ochs HD. The Wiskott-Aldrich syndrome. *Isr Med Assoc J* 2002;4: 379-84.
 12. Lee WI, Huang JL, Jaing TH, Wu KH, Chien YH, Chang KW. Clinical aspects and genetic analysis of taiwanese patients with wiskott-Aldrich syndrome protein mutation: the first identification of x-linked thrombocytopenia in the chinese with novel mutations. *J Clin Immunol* 2010;30:593-601.
 13. Yoon SH, Cho T, Kim HJ, Kim SY, Ko JH, Baek HS, et al. IVS6+5G>A found in Wiskott-Aldrich syndrome and X-linked thrombocytopenia in a Korean family. *Pediatr Blood Cancer* 2012;58:297-9.