

Case report

Open Access

When is a GIST not a GIST? A case report of synchronous metastatic gastrointestinal stromal tumor and fibromatosis

Chee Khoon Lee*¹, Alison Hadley², Keshani Desilva³, Gareth Smith⁴ and David Goldstein¹

Address: ¹Department of Medical Oncology, Prince of Wales Hospital, NSW, Australia, ²Department of Medical Oncology, St George Hospital, NSW, Australia, ³Department of Anatomical Pathology, Pacific Laboratory Medicine Services, NSW, Australia and ⁴Department of Surgery, Royal North Shore Hospital, NSW, Australia

Email: Chee Khoon Lee* - ckle1976@yahoo.com; Alison Hadley - Alison.Hadley@SEIAHS.HEALTH.NSW.GOV.AU; Keshani Desilva - KDesilva@nscchs.health.nsw.gov.au; Gareth Smith - garetts@med.usyd.edu.au; David Goldstein - d.goldstein@unsw.edu.au

* Corresponding author

Published: 21 January 2009

Received: 17 October 2008

World Journal of Surgical Oncology 2009, 7:8 doi:10.1186/1477-7819-7-8

Accepted: 21 January 2009

This article is available from: <http://www.wjso.com/content/7/1/8>

© 2009 Lee et al; licensee BioMed Central Ltd.

This is an Open Access article distributed under the terms of the Creative Commons Attribution License (<http://creativecommons.org/licenses/by/2.0>), which permits unrestricted use, distribution, and reproduction in any medium, provided the original work is properly cited.

Abstract

Background: A number of non-malignant diseases that share similar morphological features as gastrointestinal stromal tumor (GIST) have been reported. Co-existence of GIST with these other diseases is rarely recognized or reported.

Case presentation: We report a case of a 62 year-old man with long-term stable control of metastatic GIST with systemic therapy, presented with an apparent intra-abdominal progression but not supported by imaging with positron emission tomography. Subsequent resection of the intra-abdominal tumor identified a non-malignant fibroid.

Conclusion: Differentiating localized progression of GIST from other diseases has important prognostic and therapeutic implications. The potential for co-existence of non-malignant soft tissue neoplasm should always be considered.

Background

The finding of gain-of-function mutation of KIT has revolutionized the treatment of advanced gastrointestinal stromal tumor (GIST). This has subsequently led to development of effective systemic therapy utilizing tyrosine kinase inhibitors (TKI). Imatinib is the prototype TKI that was initially reported to achieve a partial response rate of 53.7% and stable disease rate of 27.9%[1]. With the increasing use of TKI in the treatment of advanced GIST, the pattern of disease evolutions are changing which will ultimately impact on the approach to management.

A number of soft tissue neoplasm share many similarities in the morphological and immunophenotypic profiles with GIST. Aggressive fibromatosis (AF) and keloid type fibromatosis scar tissues are distinct soft tissue tumors. AF is a fibroproliferative disease with a propensity for intra-abdominal presentation[2]; it may be locally aggressive but generally lacks metastatic potential. Keloid and hypertrophic scars are closely related entities that are non-malignant and characterized histologically by increased connective tissue deposition, increased blood vessel density and increased cellular deposition[3,4].

In this report, we present a case of a man who had been treated with imatinib and achieved long-term stable

advanced GIST, but presented with localized proliferation of soft-tissue neoplasm mimicking GIST.

Case presentation

A previously healthy, 62 year old man was diagnosed with a gastric antral tumor after investigations for symptomatic anemia. A barium swallow confirmed the presence of tumor causing subacute gastric outlet obstruction. Laparoscopy identified a gastroduodenal tumor and synchronous bilobar liver metastases. No peritoneal disease was identified. The primary tumor was completely excised and a liver biopsy was performed intra-operatively. Histopathology was consistent with metastatic malignant gastrointestinal stromal tumor, with typical spindle cell features on light microscopy. C-KIT was positive and the mitotic rate was 60/50 per high power fields (Figure 1). Subsequent analysis of the tumor revealed an in-frame deletion of Exon 11 in the C-KIT gene.

Post-operatively, this man recovered well from his surgery and was commenced on imatinib 600 mg daily; he subsequently required dose-reduction to 400 mg daily due to grade 3 neutropenia. He still had residual hepatic metastatic disease which was visible on computerized tomography [CT] scan, and was FDG-avid on positron emission tomography [PET] evaluation. For a period of eighteen months after surgery, imatinib was tolerated well and achieved good disease control. CT and PET imaging during this period revealed regression of size of the liver metastases. After two years of therapy, however, a CT scan revealed an increase in size of a dominant segment VI hepatic metastasis which was treated with radiofrequency ablation. He was then maintained on imatinib at 600 mg daily with subsequent disease control.

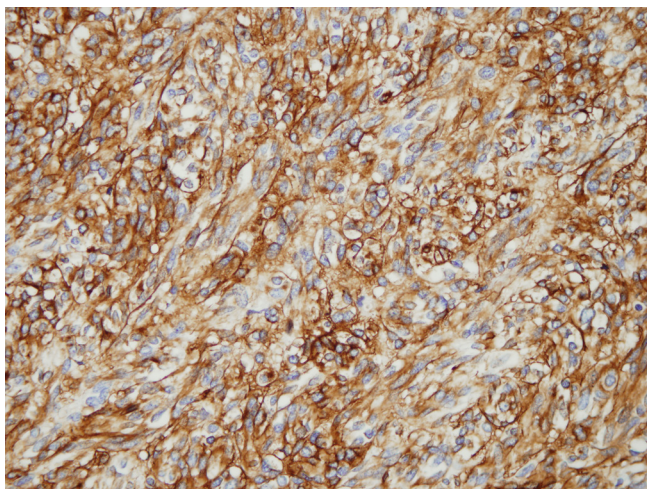


Figure 1
A representative immunohistochemical section of the resected primary tumor – diffuse c-KIT staining.

At four and half years from diagnosis, an asymptomatic infrapyloric mesenteric mass was identified on a surveillance CT which progressively increase in size over the next two months (Figure 2). A PET scan paradoxically revealed no glucose avidity of this mesenteric tumor (Figure 3).

At subsequent laparotomy, the tumor was found to be lying within the peritoneal leaves of the mesocolon extending from the origin of the superior mesenteric vessels to the inferior pancreatico-duodenal vessels. Histopathology showed a tumour mass composed of spindle shaped fibrocytic/fibroblastic like cells amongst intervening collagen (Figure 4) with low mitotic rate (less than 1 per 50 hpf). Immunoperoxidase staining was positive for C-KIT but negative for CD34 and S100. Genetic analyses did not identify the previous C-KIT Exon 11 in-frame dele-

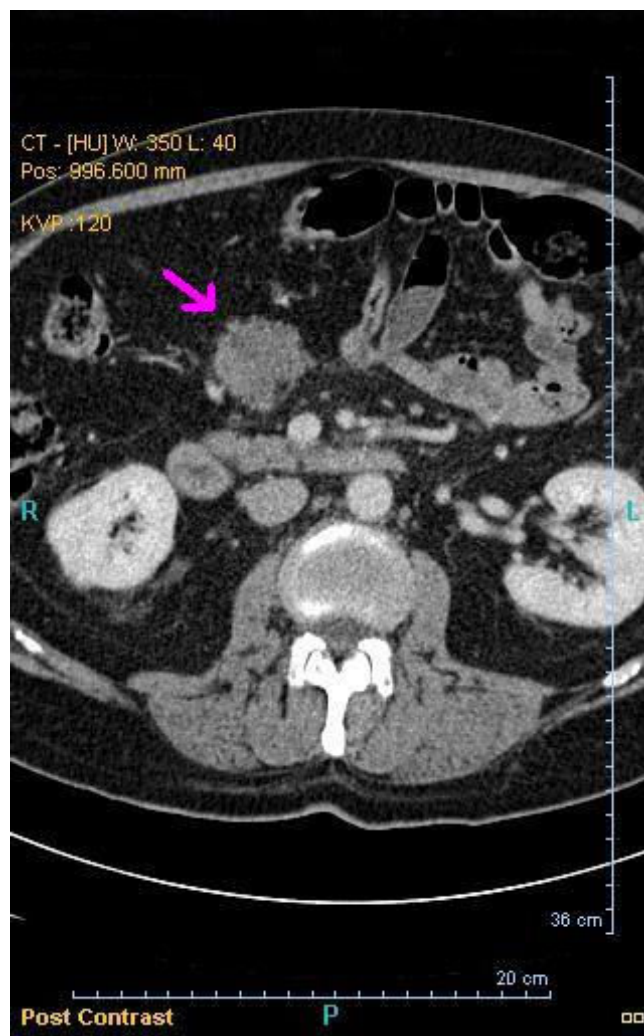


Figure 2
A section of computerized tomography [CT] scan. Arrow identifies the infrapyloric mesenteric mass.

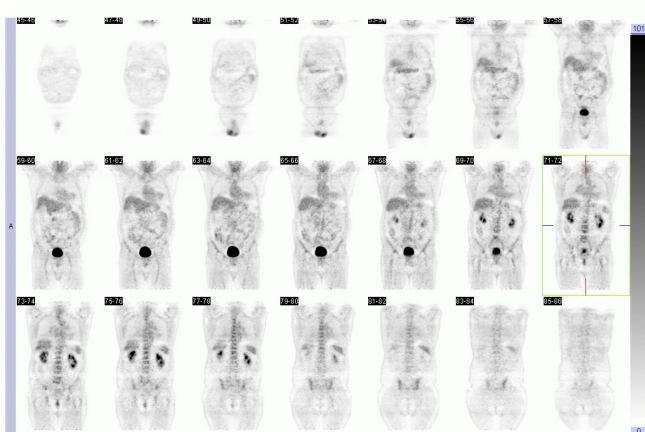


Figure 3
Whole body positron emission tomography [PET].
 No abnormal foci of increased metabolism of FDG can be identified.

tion or mutations of other Exons 11, 9, 13 and 17 and PDGFRA Exon 18.

Imatinib was continued 600 mg daily, with brief cessation during the peri-operative period, as metastatic GIST remained radiologically stable. No specific adjuvant therapy for the soft-tissue tumor was employed post-operatively.

Discussion

In this patient with metastatic GIST, the development of the mesenteric tumor four years after the institution of

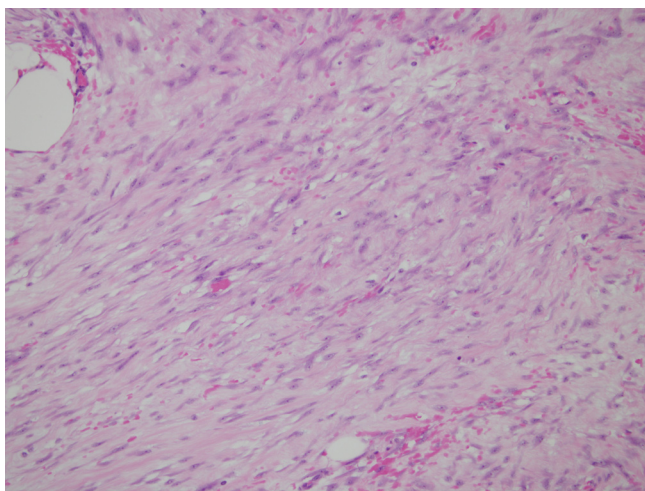


Figure 4
Hematoxylin & eosin stained section of intrapapillary mesenteric mass. Spindle shaped fibrocytic/fibroblastic like cells amongst intervening collagen.

imatinib initially suggested disease relapse. Debulking surgery remains a recognized standard practice in the case of local progression where such procedure is associated with prolonged survival with the elimination of imatinib resistance clones[5]. However, in rare instances as illustrated in this case, consideration for co-existence of another disease will need to be considered.

This patient underwent surgery with the pre-surgical diagnosis of a localized progression; surgery was aimed to achieve disease control with the elimination of a presumably localized imatinib resistance tumor. Post-surgery, the histopathologic findings revealed a tumor with reduced cellularity and low mitotic activity consistent with the pre-operative non-glucose avid PET findings. Collaborative pathologic review was obtained and excluded diagnosis of a recurrent GIST. However, a definitive uniform diagnosis could not be made. The possible differential diagnoses of this soft-tissue tumor include aggressive fibromatosis (AF) or intra-abdominal keloid type fibrocollagenous scar.

Immunohistochemistry was positive for C-KIT, which is unusual in AF or intra-abdominal keloid type fibrocollagenous scar. Mutation analysis that was performed on the mesenteric tumor further clarify that this mass, which was absent of Exon 11 C-KIT mutation, was different from the Exon 11 C-KIT mutation positive of the original resected antral GIST.

Histologically, AF lies on a spectrum of disorders characterized by excess proliferation of fibroblast-like spindle cells[6]. These cells are monoclonal neoplasms[7] with low cellularity and rare mitoses. Most are associated with germline or somatic mutations of WNT pathway (*APC* or *CTNNB1*). Some studies [8-11] have demonstrated clinical and radiological benefits of imatinib in treatment of AF.

There is very limited literature on intra-abdominal keloid type fibrocollagenous scar. The scar in this patient was presumably formed from previous surgical laparotomy. There is growing evidence to suggest that Transforming Growth Factor β [12] is implicated in keloids and other benign fibroproliferative diseases as well as formation of adhesions after abdominal operations[13]. Although such clinical entities are well-described in literature when they are manifested cutaneously, there is no information on intra-abdominal manifestation.

The immunophenotypic profiles of GIST, AF and keloid may overlap. Fibromatoses may stain for vimentin, smooth muscle actin, and desmin. In some series, fibromatosis did not stain for CD34 or S-100 protein, while CD34 staining and occasional S-100 protein positivity were seen in GIST[2,14]. It has been suggested that

differences in CD34 immunostainin might be helpful in distinguishing between them[14]. C-KIT staining in AF is controversial. Up to 75% of cases in one series were C-KIT positive[2] but other reports have concluded that most AF's do not express demonstrable levels of this imatinib target. In cutaneous fibrocollagenous scar, smooth muscle actin is stained more commonly in hypertrophic scar and to the lesser extent on keloid scars[12,15]. More importantly, there is no report of C-KIT staining in fibrocollagenous scars.

Conclusion

The long stable disease control, the absence of glucose avidity of pre-operative PET and the absence of the C-KIT mutation in the mesenteric tumor were all features that might have suggested the possibility of an alternative diagnosis to GIST recurrence. Although surgical resection of this mesenteric mass may remain necessary, a correct diagnosis has important implication for his future systemic therapy. This case report highlights the importance of recognizing the coexistence of other diseases in patients with chronic GIST.

Consent

Written informed consent was obtained from the patient for publication of this case report and accompanying images. A copy of the written consent is available for review by the Editor-in-Chief of this journal.

Competing interests

The authors declare that they have no competing interests.

Authors' contributions

CL and AH drafted the original manuscript, with subsequent further contributions from KD, GS and DG. KD reported the histopathological findings and supplied the photomicrographs used in this manuscript. GS reported the surgical findings

All authors read and approved the final manuscript.

References

- Demetri G, von Mehren M, Blanke C, Abbeele A Van den, Eisenberg B, Roberts P, Heinrich M, Tuveson D, Singer S, Janicek M, Fletcher J, Silverman S, Silberman S, Capdeville R, Kiese B, Peng B, Dimitrijevic S, Druker B, Corless C, Fletcher C, Joensuu H: **Efficacy and safety of imatinib mesylate in advanced gastrointestinal stromal tumors.** *New England Journal of Medicine* 2002, **347**:472-480.
- Yantiss R, Spiro I, Compton C, Rosenberg A: **Gastrointestinal stromal tumor versus intra-abdominal fibromatosis of the bowel wall: A clinically important differential diagnosis.** *American Journal of Surgical Pathology* 2000, **24**:947-957.
- Ehrlich H, Desmouliere A, Diegelmann R, Cohen I, Compton C, Garner W, Kapanci Y, Gabbiani G: **Morphological and immunohistochemical differences between keloid and hypertrophic scar.** *American Journal of Pathology* 1994, **145**:105-113.
- Al-Attar A, Mess S, Tommassen J, Kauffman L, Davidson S: **Keloid pathogenesis and treatment.** *Plastic Reconstruction Surgery* 2006, **117**:286-300.
- Desai J, Shankar S, Heinrich M, Fletcher J, Fletcher C, Manola J, Morgan J, Corless C, George S, Tuncali K, Silverman S, Abbeele A Van den, van Sonnenberg E, Demetri G: **Clonal Evolution of Resistance to Imatinib in Patients with Metastatic Gastrointestinal Stromal Tumors.** *Clinical Cancer Research* 2007, **13**:5398-5405.
- Cheon S, Cheah A, Turley S, Nadesan P, Poon R, Clevers H, Alman B: **Beta-Catenin stabilization dysregulates mesenchymal cell proliferation, motility, and invasiveness and causes aggressive fibromatosis and hyperplastic cutaneous wounds.** *Proceedings of the National Academy of Sciences* 2002, **99**:6973-6978.
- Li M, Cordon-Cardo C, Gerald W, Rosai J: **Desmoid fibromatosis is a clonal process.** *Human Pathology* 1996, **27**:939-943.
- Heinrich M, McArthur G, Demetri G, Joensuu H, Bono P, Herrmann R, Hirte H, Cresta S, Koslin D, Corless C, Dirnhofer S, van Oosterom A, Nikolova Z, Dimitrijevic S, Fletcher J: **Clinical and molecular studies of the effect of imatinib on advanced aggressive fibromatosis (desmoid tumor).** *Journal of Clinical Oncology* 2006, **24**:1195-1203.
- Mace J, Sybil B, Sondak V, McGinn C, Hayes C, Thomas D, Baker L: **Response of extraabdominal desmoid tumors to therapy with imatinib mesylate.** *Cancer* 2002, **95**:2373-2379.
- Chugh R, Maki R, Thomas D, Reinke D, Wathen J, Patel S, Priebat D, Meyers P, Benjamin R, Baker L: **A SARC phase II multicenter trial of imatinib mesylate (IM) in patients with aggressive fibromatosis.** *Journal of Clinical Oncology 2006 ASCO Annual Meeting Proceedings Part 1* 2006, **24**:9515.
- Penel M, Le Cesne A, Bui B, Tubiana-Hulin M, Guillemet C, Cupissol D, Berthaud P, Mahier C, Pérol D, Blay J: **Imatinib for the treatment of aggressive fibromatosis (desmoid tumors) failing local treatment. A phase II trial of the French Sarcoma Group.** *Journal of Clinical Oncology, 2006 ASCO Annual Meeting Proceedings Part 1* 2006, **24**:9516.
- Jagadeesan J, Bayat A: **Transforming growth factor beta (TGF-beta) and keloid disease.** *International Journal of Surgery* 2007, **5**:278-285.
- Hobson K, DeWing M, Ho H, Bruce M, Wolfe B, Cho K, Greenhalgh D: **Expression of transforming growth factor beta 1 in patients with and without previous abdominal surgery.** *Archives of Surgery* 2003, **138**:1249-1252.
- Monihan J, Carr N, Sobin L: **CD34 immunoreactivity in stromal tumors of the gastrointestinal tract and in mesenteric fibromatosis.** *Histopathology* 1994, **25**:469-473.
- Lee J, Yang C, Chao S: **Histopathological differential diagnosis of keloid and hypertrophic scar.** *American Journal of Dermatopathology* 2004, **26**:379-384.

Publish with **BioMed Central** and every scientist can read your work free of charge

"BioMed Central will be the most significant development for disseminating the results of biomedical research in our lifetime."

Sir Paul Nurse, Cancer Research UK

Your research papers will be:

- available free of charge to the entire biomedical community
- peer reviewed and published immediately upon acceptance
- cited in PubMed and archived on PubMed Central
- yours — you keep the copyright

Submit your manuscript here:
http://www.biomedcentral.com/info/publishing_adv.asp

