



A rare event of perioperative spinal subarachnoid hemorrhage in mixed connective tissue disease: a case report

Stefano Andreoli, Francesca Porta, Adrian Wäckerlin

Intensive Care Unit, Cantonal Hospital of Graubünden, Chur, Switzerland

Contributions: (I) Conception and design: S Andreoli; (II) Administrative support: S Andreoli; (III) Provision of study materials or patients: S Andreoli; (IV) Collection and assembly of data: S Andreoli; (V) Data analysis and interpretation: S Andreoli, F Porta; (VI) Manuscript writing: All authors; (VII) Final approval of manuscript: All authors.

Correspondence to: Dr. med. Stefano Andreoli, MD. Intensive Care Unit, Cantonal Hospital of Graubünden, Via Belvedere 9, 6948 Porza, CH-7000 Chur, Switzerland. Email: stefano.andreoli@hotmail.com.

Background: Spinal subarachnoid hemorrhage (SSH) is an extremely rare event and its causes include trauma, vascular malformation, anticoagulant therapy, and autoimmune disease. Although connective disorders are associated with an increased risk of cerebral subarachnoid hemorrhage (SAH), to our knowledge, the occurrence of SSH associated with mixed connective tissue disease (MCTD) have not been addressed in the literature. We report the unique occurrence of SSH in a patient with anti-U1 ribonucleoprotein (U1-RNP) and anti-nuclear antibodies (ANA) positive MCTD triggered by abdominal surgery.

Case Description: A 69-year-old woman with MCTD was admitted to our hospital because of vomiting and abdominal pain. Surgical treatment of adhesion ileus with small bowel resection was followed on the second postoperative day by sudden back pain radiating to the legs and abdominal belt-shaped lumbar exanthema. A spinal anesthesia was not performed. Neurological examination revealed loss of sensation and muscle strength in both legs. Magnetic resonance imaging (MRI) showed an SSH beyond T6 and the lumbosacral junction with ventral displacement of the spinal cord without myelopathy. Rapid improvement in motor function and sensitivity allowed a conservative management. The patient recovered successfully and was discharged without neurological deficits.

Conclusions: We postulate that vascular rupture causing SSH was triggered by perioperative increased intraluminal abdominal pressure combined with fragility of the spinal arachnoid mater due to MCTD. The decision to undergo a conservative treatment of the SSH was triggered by the rapid improvement of the neurological presentation and the disappearance of symptoms in a few days. We recommend caution in patients with connective tissue diseases who undergo thoracic or abdominal surgery and be aware for neurosurgeons that SSH is possible although rare and that conservative treatment may be considered.

Keywords: Mixed connective tissue disease (MCTD); spinal subarachnoid hemorrhage (SSH); spine; case report; neurological complications

Submitted Apr 22, 2023. Accepted for publication Sep 08, 2023. Published online Oct 10, 2023.

doi: 10.21037/jss-23-59

View this article at: <https://dx.doi.org/10.21037/jss-23-59>

Introduction

Spinal subarachnoid hemorrhage (SSH) represents a rarity with only 0.05–1.5% of all cases of subarachnoid hemorrhage (SAH) (1). Causative factors can vary from trauma (including

lumbar puncture), vascular malformation, neoplastic lesion, defective coagulation or systemic such as autoimmune or connective disease, the first two being the most common ones (2-11). Instead, the occurrence of idiopathic spontaneous SSH is extremely rare (12). As described in

some case reports, intra-abdominal pressure (IAP) may have an impact in the occurrence of the event (12-14).

Mixed connective tissue disease (MCTD) plays a non-marginal role in the development of neurological complications, being responsible for some of the following conditions: lacunar infarctions, mononeuritis, transverse myelitis (15). MCTD refers to an overlapping condition of different autoimmune diseases such as lupus erythematosus, systemic sclerosis, rheumatoid arthritis, polymyositis and dermatomyositis. The disease is related to the expression of anti U1 ribonucleoprotein (U1-RNP) antibodies (16,17). Although connective disorders are associated with an increased risk of cerebral SAH (4), a case of SSH associated with MCTD has not yet been described.

The aim of this case report is to describe the unique occurrence of SSH in a patient with MCTD, its first manifestations, symptoms and clinical signs, treatment and its evolution in order to contribute to the knowledge of this neurological complication in the literature. This case is written following the CARE reporting checklist (available at <https://jss.amegroups.com/article/view/10.21037/jss-23-59/rc>).

Case presentation

A 69-year-old white woman presented to the emergency room in the evening with lower abdominal pain, vomiting since the afternoon with elevated inflammatory parameters

and signs of peritonism on clinical examination. *Figure 1* shows the chronological timeline of the events. The abdominal computed tomography (CT) scan showed no abnormalities. Diagnostic laparoscopy was performed and then converted to laparotomy based on the evidence of small bowel ileus. One meter necrotic small bowel was removed. At the end of surgery, the patient received a transverse abdominis plane block for pain control of the anterior abdominal wall. Surgery lasted 165 minutes, while the pneumoperitoneum was maintained for 5 minutes.

The patient revealed a history of hypothyroidism and MCTD since three years prior to presentation with positive U1-RNP and anti-nuclear antibodies (ANA). MCTD was under therapy with prednisolone and rituximab for a short time in the first year due to polyarthritis and joint pain. The therapy was then stopped in the absence of symptoms. At the time of hospital admission, MCTD was quiescent.

The first postoperative day ran uncomplicated. During the second postoperative day, at midday the patient developed abdominal belt-shaped lumbar exanthema, and 2 hours later complained of sudden severe back pain radiating to both legs. Physical exam revealed the patient to be afebrile, alert, oriented and normotensive. Neurological examination revealed diminished lower extremity strength (M0-1/5) and absence of bilateral sensation, the examination was difficult to perform due to patient non-compliance. A CT-scan showed spinal canal hyperdensity. The patient was intubated and sedated because of uncontrolled pain despite high dose analgesics and to perform a magnetic resonance imaging (MRI). MRI revealed an SSH from T6 to the sacrum without signs of myelopathy (*Figures 2-5*). An additional subdural component could not be ruled out with certainty. There was no evidence of vascular malformations or dural fistula.

Neurosurgery was consulted and decided against surgical intervention due to low probability of cord compression, but an urgent neurological examination was mandatory. At the completion of the diagnostic assessment, the patient was rapidly extubated and complained of pain and loss of sensitivity below the T11 dermatome bilaterally. Muscle strength showed distally left M2/5, right M3/5, and proximally M4/5, bilaterally. Sphincter tonus showed to be normal and meningismus signs were present. Conservative therapy was continued given the slight neurological improvement. During the first hours in the intensive care unit (ICU), we observed a progressive hypotension with signs and symptoms of poor perfusion. Lactate levels increased up to 6.5 mmol/L with normal hemoglobin levels.

Highlight box

Key findings

- Spinal subarachnoid hemorrhage (SSH) is a rare event and can be triggered by abdominal procedures in patients with mixed connective tissue disease, an event not yet described in the literature.

What is known and what is new?

- Mixed connective tissue disease (MCTD) is associated with many neurological complications including cerebral subarachnoid hemorrhages.
- However, spinal SSH has never been described in the literature as neurological complications in MCTD.

What is the implication, and what should change now?

- Patients with MCTD should be considered at risk for SSH if undergoing abdominal or thoracic surgery. Neurosurgeons should be aware that SSH is a possible scenario in patients with MCTD and his therapy can be conservative if the neurological evolution and imaging criteria allows it.

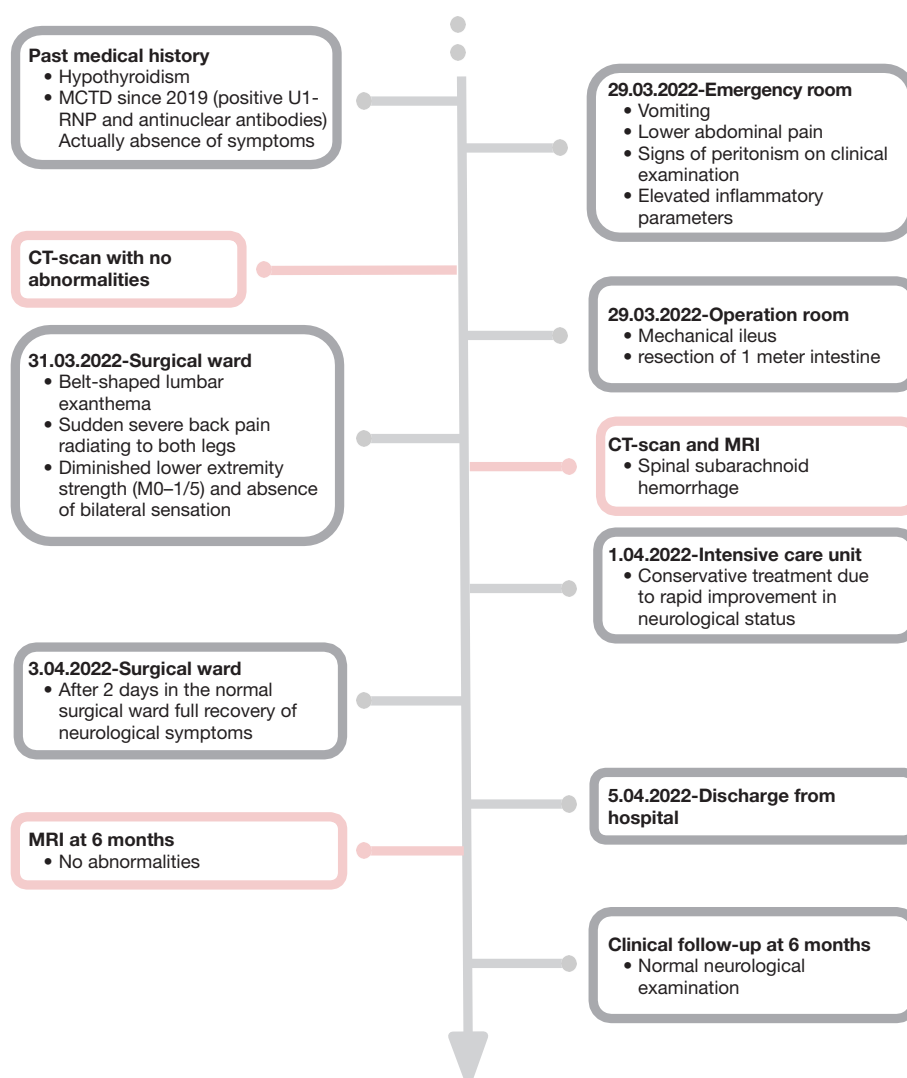


Figure 1 Timeline of interventions and outcomes. MCTD, mixed connective tissue disease; U1-RNP, anti-U1 ribonucleoprotein; CT, computer tomography; MRI, magnetic resonance imaging.

After volume resuscitation with 1,500 mL crystalloids the shock-like state slowly recovered. The next day, the strength improved, and the sensation fully recovered. Surprisingly, creatine kinase increased until a peak of 4,000 U/L. Inflammation markers (C-reactive protein) increased slightly during the first 24 hours but recovered spontaneously. The coagulation parameters were normal, and a spinal anesthesia or therapeutic anticoagulation was not performed. A follow-up MRI was not performed during the following days due to the rapid improvement in the neurological examination. After 4 days of hospital care, the

patient was discharged with full recovered muscle strength and sensation with recovery of ambulation. Six months after discharge, the clinical follow-up revealed a normal neurological status and MRI showed no abnormalities.

All procedures performed in this study were in accordance with the ethical standards of the institutional and/or national research committee(s) and with the Helsinki Declaration (as revised in 2013). Written informed consent was obtained from the patient for publication of this case report and accompanying images. A copy of the written consent is available for review by the editorial office of this journal.

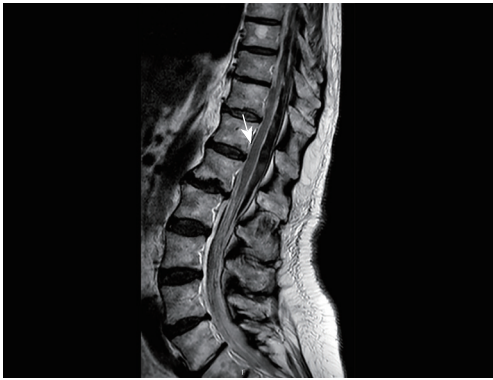

Figure 2 MRI (T2 sequence, sagittal) showing a spinal subarachnoid hemorrhage, with blood from the level of thoracic vertebrae 6 to the sacral and with ventral displacement of the spinal cord without signs of myelopathy. An additional subdural component cannot be ruled out with certainty. No evidence of a vascular malformation or dural fistula as the cause. The arrow indicates the spinal subarachnoid hemorrhage with ventral displacement of the spinal cord. MRI, magnetic resonance imaging.

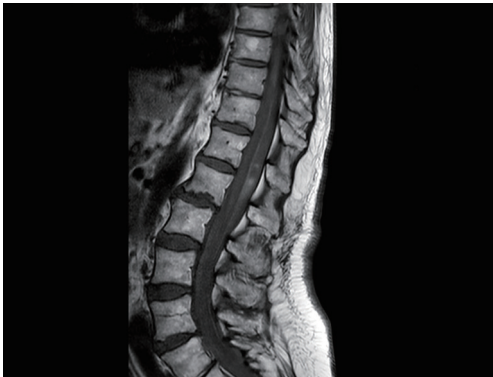

Figure 3 MRI (T1 sequence, sagittal) showing a spinal subarachnoid hemorrhage, with blood from the level of thoracic vertebrae 6 to the sacral and with ventral displacement of the spinal cord without signs of myelopathy. MRI, magnetic resonance imaging.

Discussion

We report a case of spontaneous SSH occurred after abdominal surgery in the context of MCTD. Only approximately 20 cases of spontaneous SSH have been described (12-14,18-22). Severe back pain and headaches are frequently observed. Some of these cases experienced stress situations or higher IAP (coughing, defecation and scuba diving). Maiti *et al.* [2017] (6) hypothesized that minor trauma as an increased IAP can trigger SSH, causing

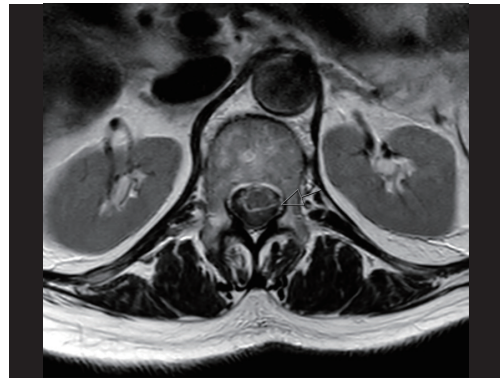


Figure 4 MRI (T2 sequence, axial), the arrow shows the spinal subarachnoid hemorrhage compressing the spinal cord at thoracic vertebrae 12 level. MRI, magnetic resonance imaging.

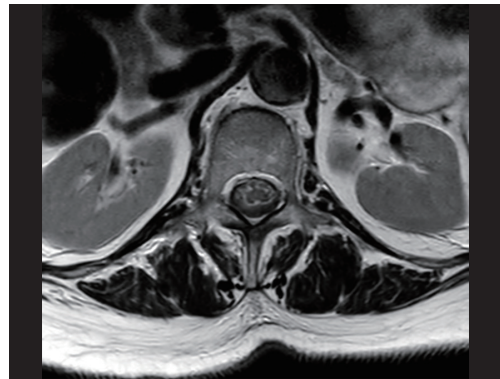


Figure 5 MRI (T2 sequence, axial) showing a spinal subarachnoid hemorrhage that compress the spinal cord at lumbar vertebrae 2 level. MRI, magnetic resonance imaging.

tearing of vessels within the subarachnoid space and their rupture. In our patient, the event manifested two days after surgery, probably caused by: first, the increased IAP through the initial pathology, the small bowel ileus; second, the minor trauma through the abdominal surgery; and third, the postoperative increased IAP due to the inflammatory edematous intra-abdominal environment.

MCTD includes connective tissue fragility, susceptible to traumatic events. This is also true for the spinal arachnoid mater. Masdeu *et al.* [1979] (23) postulated that an increase in IAP such as abdominal intervention, could be responsible for the rupture of the radiculomedullary vessels that cross the subdural and subarachnoid space. The fragility of the arachnoid mater together with increased IAP in our patient caused the vessels rupture within the subarachnoid space

of the lumbar spine, resulting in SSH. The occurrence of a prodromal cutaneous rash, a lumbar exanthema belt-shaped, was likely due to irritation of the radicular nerves in their specific dermatomes.

Spontaneous SSH is a challenging event that may be associated with neurological deficits. The decision to perform decompressive surgery is based on neurological deterioration and myelopathy.

Komiyama *et al.* [1997] (1) postulated that the location of the SSH (ventral versus dorsal type) plays a role in the decision to perform surgical decompression, being the ventral-type less associated with neurological deficits and therefore, conservative treatment is favored. In our case (ventral displacement of spinal cord with dorsal SSH), a conservative management was made due to the rapid improvement of neurological functions.

MRI choice for radiological examination was essential in this case to exclude vascular malformations and other neurological complications associated with MCTD such as transverse myelitis.

A limitation of this case report is the difficulty in collecting data on the patient's MCTD, given that the diagnosis took place outside our institution as well as the therapy, as well as its follow-up. Taking the patient's subjective data shows another limitation of this case report, the patient was not questioned about how she experienced the event and its result.

Considering that the event and its therapy as well as the follow-up took place within the same institution shows a strength of this case report, where the information was not fragmented.

Our patient, after being diagnosed with SSH after abdominal surgery and with a positive past medical history for MCTD, was successfully treated conservatively. The diagnostics was effective and the results showed a total recovery of neurological functions over the long-term. The decision not to perform surgery was correct. For this reason, every surgeon, especially neurosurgeons must be aware that this neurological complication exists and is probably more relevant in patients with connective disorders.

Patient perspective

From patient perspective, this neurological complication was difficult to handle because after the abdominal operation and the marked improvement of the symptoms, this second event occurred, which paralyzed the patient causing her immense pain. In addition to this, the conservative therapy

did not initially convince the patient given the symptoms she presented, but she trusted the physicians' opinion and fully recovered.

Conclusions

The patient experienced an SSH triggered by the fragility of the spinal arachnoid mater, resulting in the breakdown of the radiculomedullary veins in the context of MCTD and a perioperative increase in IAP. In this report, we describe the first case of spontaneous SSH associated with MCTD.

Two main criteria are considered for intervention: neurological evolution and signs of myelopathy on MRI. A conservative treatment is recommended for patients with improving neurological status.

We recommend caution in patients with connective tissue diseases who undergo thoracic or abdominal surgery and be aware for neurosurgeons that SSH is possible although rare and that conservative treatment may be considered.

Acknowledgments

Funding: None.

Footnote

Reporting Checklist: The authors have completed the CARE reporting checklist. Available at <https://jss.amegroups.com/article/view/10.21037/jss-23-59/rc>

Peer Review File: Available at <https://jss.amegroups.com/article/view/10.21037/jss-23-59/prf>

Conflicts of Interest: All authors have completed the ICMJE uniform disclosure form (available at <https://jss.amegroups.com/article/view/10.21037/jss-23-59/coif>). The authors have no conflicts of interest to declare.

Ethical Statement: The authors are accountable for all aspects of the work in ensuring that questions related to the accuracy or integrity of any part of the work are appropriately investigated and resolved. All procedures performed in this study were in accordance with the ethical standards of the institutional and/or national research committee(s) and with the Helsinki Declaration (as revised in 2013). Written informed consent was obtained from the patient for publication of this case report and accompanying images. A copy of the written consent is available for review

by the editorial office of this journal.

Open Access Statement: This is an Open Access article distributed in accordance with the Creative Commons Attribution-NonCommercial-NoDerivs 4.0 International License (CC BY-NC-ND 4.0), which permits the non-commercial replication and distribution of the article with the strict proviso that no changes or edits are made and the original work is properly cited (including links to both the formal publication through the relevant DOI and the license). See: <https://creativecommons.org/licenses/by-nc-nd/4.0/>.

References

1. Komiyama M, Yasui T, Sumimoto T, et al. Spontaneous spinal subarachnoid hematoma of unknown pathogenesis: case reports. *Neurosurgery* 1997;41:691-3; discussion 693-4.
2. Nakamura H, Kim P, Kanaya H, et al. Spinal Subarachnoid Hemorrhage Caused by a Mycotic Aneurysm of the Radiculomedullary Artery: A Case Report and Review of Literature. *NMC Case Rep J* 2015;2:49-52.
3. Ramagopalan SV, Pakpoor J, Seminog O, et al. Risk of subarachnoid haemorrhage in people admitted to hospital with selected immune-mediated diseases: record-linkage studies. *BMC Neurol* 2013;13:176.
4. Kim ST, Brinjikji W, Lanzino G, et al. Neurovascular manifestations of connective-tissue diseases: A review. *Interv Neuroradiol* 2016;22:624-37.
5. Glynn RM, Garza MR, Campanella FM. Evaluation and Management of Spinal Subarachnoid Hemorrhage in a Patient with Lupus Vasculitis. *Am J Case Rep* 2018;19:114-7.
6. Maiti TK, Bir SC, Nanda A. Spinal subarachnoid hemorrhage and aneurysms. *Handb Clin Neurol* 2017;143:215-23.
7. Sánchez Gutiérrez C, Alemán Martín A, Coronado Hijón V, et al. Spontaneous resolution of a paraparesis due to a dorsolumbar epidural haematoma associated with subarachnoid anaesthesia and postoperative analgesia using an epidural catheter. *Rev Esp Anesthesiol Reanim* 2012;59:503-6.
8. Shaban A, Moritani T, Al Kasab S, et al. Spinal Cord Hemorrhage. *J Stroke Cerebrovasc Dis* 2018;27:1435-46.
9. Nogami R, Matsuoka H, Ohashi S, et al. Spinal subarachnoid hemorrhage after percutaneous kyphoplasty: a case report and literature review. *J Spine Surg* 2022;8:491-6.
10. Zhao J, Jiang H, Jiang H, et al. Analysis of Risk Factors Related to Acute Subarachnoid Hemorrhage After Spinal Surgery. *World Neurosurg* 2022;160:e111-7.
11. Alomari S, Xu R, Huang J, et al. Isolated aneurysms of the spinal circulation: a systematic review of the literature. *Neurosurg Rev* 2022;45:989-1008.
12. Oji Y, Noda K, Tokugawa J, et al. Spontaneous spinal subarachnoid hemorrhage after severe coughing: a case report. *J Med Case Rep* 2013;7:274.
13. Hiyama H, Shimizu T, Yato S, et al. Wide-spread spontaneous spinal subarachnoid hematoma. Case report. *Neurol Med Chir (Tokyo)* 1990;30:842-7.
14. Mashiko R, Noguchi S, Uemura K, et al. Lumbosacral subdural hematoma. Case report. *Neurol Med Chir (Tokyo)* 2006;46:258-61.
15. Hao Y, Feng L, Teng Y, et al. Management of multiple neurological complications in mixed connective tissue disease: A case report. *Medicine (Baltimore)* 2018;97:e11360.
16. Ciang NC, Pereira N, Isenberg DA. Mixed connective tissue disease-enigma variations? *Rheumatology (Oxford)* 2017;56:326-33.
17. Paradowska-Gorycka A. U1-RNP and Toll-like receptors in the pathogenesis of mixed connective tissue disease Part II. Endosomal TLRs and their biological significance in the pathogenesis of mixed connective tissue disease. *Reumatologia* 2015;53:143-51.
18. Ruelle A, Zerbi D, Andrioli G. Spinal subarachnoid bleeding of unknown etiology. Case reports. *J Neurosurg Sci* 2001;45:53-7.
19. Plotkin R, Ronthal M, Froman C. Spontaneous spinal subarachnoid haemorrhage. Report of 3 cases. *J Neurosurg* 1966;25:443-6.
20. Gambacorta D, Reale F, De Falco D. Spontaneous chronic spinal subarachnoid hematoma. Report of a case and review of the literature. *Spine (Phila Pa 1976)* 1987;12:716-8.
21. Pau A, Brambilla M, Cossu M, et al. Spinal subarachnoid hematoma of unknown etiology. A case report. *Neurochirurgia (Stuttg)* 1991;34:151-3.
22. Kang HS, Chung CK, Kim HJ. Spontaneous spinal subdural hematoma with spontaneous resolution. *Spinal Cord* 2000;38:192-6.
23. Masdeu JC, Breuer AC, Schoene WC. Spinal subarachnoid hematomas: clue to a source of bleeding in traumatic lumbar puncture. *Neurology* 1979;29:872-6.

Cite this article as: Andreoli S, Porta F, Wäckerlin A. A rare event of perioperative spinal subarachnoid hemorrhage in mixed connective tissue disease: a case report. *J Spine Surg* 2023;9(4):487-492. doi: 10.21037/jss-23-59