

Editor's Choice

Sequential Facial Skin Rejuvenation with Intense Pulsed Light and Non-ablative Fractionated Laser Resurfacing in Fitzpatrick Skin Type II–IV Patients: A Prospective Multicenter Analysis

J. Matthew Knight, MD^{1*} and Gerd Kautz, MD^{2**}

¹*Knight Dermatology Institute—Laser Center, Orlando, Florida*

²*Dermatological Practice—Laser Center, Konz, Germany*

Background: While skin aging is triggered by multiple factors and typically presents with multiple manifestations, conventional treatment regimens deploy a single treatment modality. Typical approaches exploit ablative techniques, which involve considerable patient discomfort and downtime and can induce adverse events. Non-ablative fractionated laser (NAFL) resurfacing promotes neocollagenesis, with significantly fewer complications and discomfort. At the same time, intense pulsed light (IPL) therapies have a marked impact on skin tone, with an effect on collagen deposition. This study evaluated the combined effect of same-day, sequential IPL-NAFL treatment on photoaging of the face.

Design: In this prospective study, 30 patients presenting Fitzpatrick skin types II–IV, elastosis scores 3–6 and mild to moderate pigmentation, underwent three sessions, of full-face IPL therapy, followed immediately by NAFL treatment, conducted at 4–6 weeks intervals. Wrinkle/elastosis and skin qualities were scored at 1, 3, and 6 months after the last treatment session. Immediate responses were evaluated up to 30 min following treatment and adverse events were monitored throughout the study period.

Results: Wrinkle/elastosis scores gradually improved over the treatment period, with 59% of patients presenting a ≥ 1 -point improvement in FES scores by the 1-month follow-up session, which persisted also at the 6 months follow-up visit. Good to excellent pigmentation responses were recorded for $\geq 63\%$ and improvements in texture, brightness, and tightness were recorded for $\geq 80\%$ of patients throughout the follow-up period. Over 90% of the treated patients exhibited improved or much improved overall appearance. Patient scorings and satisfaction level reflected physician assessments. Treatments were well tolerated and the social downtime observed was of 1.5 ± 0.25 days.

Conclusion: The same-day combined IPL-NAFL regimen proved safe and elicited a significant skin rejuvenating effect, in a similar manner to that shown in other same-day combined therapies, without prolonging downtime of each

individual modality. *Lasers Surg. Med.* 51:141–149, 2019. © 2018 The Authors. *Lasers in Surgery and Medicine* Published by Wiley Periodicals, Inc.

Key words: skin rejuvenation; laser; cosmetic; resurfacing; pigmentation; wrinkles; IPL; non ablative; fractionated laser; intense pulsed light

INTRODUCTION

Skin aging is influenced by multiple genetic and environmental factors that can manifest in the form of wrinkles, abnormal pigmentation, skin laxity, and telangiectasia. Advanced skin aging has been treated primarily *via* ablative procedures that lead to replacement of the epidermis and superficial dermis, but at the price of marked patient discomfort, prolonged social downtime and, potentially, serious adverse events [1].

Alternative treatments using non-ablative fractionated laser (NAFL) facial resurfacing regimens are increasingly preferred despite their lower efficacy per session and the need for repeated treatment sessions. With this approach, selective dermal insult is caused by infrared light, leading to the production of new collagen, while the overlying

This is an open access article under the terms of the Creative Commons Attribution-NonCommercial-NoDerivs License, which permits use and distribution in any medium, provided the original work is properly cited, the use is non-commercial and no modifications or adaptations are made.

Conflict of Interest Disclosures: Dr. Knight and Dr. Kautz speak on behalf of, and perform research for Lumenis Ltd.

ClinicalTrials.gov Identifier: NCT02032771

Contract grant sponsor: Lumenis.

*Correspondence to: J. Matthew Knight, MD, Knight Dermatology Institute – Laser Center, 801 N. Orange Ave. Suite 520, Orlando, Florida 32801. E-mail: info@knightdermatology.com

**Correspondence to: Gerd Kautz, MD, dermatological Practice – Laser Center, Am Markt 3, 54329 Konz, Germany. E-mail: info@dr-kautz.com

Accepted 15 July 2018

Published online 8 August 2018 in Wiley Online Library (wileyonlinelibrary.com).

DOI 10.1002/lsm.23007

epidermis remains intact [2,3]. NAFL techniques are associated with reduced downtime and a lower incidence of complications, which seem to be the main reasons for their growing popularity.

In parallel, popular non-ablative intense pulsed light (IPL) procedures have a significantly marked impact on skin tone and skin texture [4,5]. In light of the more recent appreciation for the multifactorial nature of facial aging, repeated combination energy-based treatment regimens, which target the multiple clinical manifestations of photoaging, have received increasing attention. Kearney et al. [6] reported a series of 29 patients who underwent full-face IPL immediately followed by NAFL. In tandem, 14 patients underwent split-face therapy comparing sequential IPL and NAFL treatments, performed independently at 4-week intervals, while on the contralateral side, the patients underwent same-day combined treatment. The same-day combination therapy elicited significantly improved global pigmentation and telangiectasia when compared to combination therapy performed with a 4-week interval period. Patient discomfort, immediate response, and downtime were similar in both groups.

Friedmann et al. [7] proposed the use of IPL, micro-focused ultrasound (MFUS), and a volumizing filler to simultaneously address superficial cutaneous irregularities, skin laxity, and deep-tissue volume loss. In a prospective, split-face, five-series analysis of the impact of IPL, near-infrared pulsed light, and fractional laser combination therapy applied for skin rejuvenation in 113 Asian patients, Tao et al. [8] described a dramatic effect of combined therapy at the 1- and 3-month follow-up visits; safety levels were similar when compared to patients who received monotherapy. Trelles et al. [9] reported enhanced epidermal thickening, collagen organization, and improved patient satisfaction following combined IPL and ablative Er:YAG laser therapy versus IPL monotherapy. While comparative studies are still lacking, combined treatment regimens seem to augment, and potentiate, the effect of each individual modality.

Despite extensive literature regarding the safety and efficacy of minimally invasive photorejuvenation modalities, few published reports are available regarding their combined use. This study aimed to explore the safety and synergistic potential of sequential IPL and NAFL treatments with particular focus on skin texture, skin tone, and mean downtime.

METHODS

In this prospective study, a total of 33 patients from two independent clinics underwent in immediate sequence, full-face IPL followed by NAFL treatment, in an effort to assess the impact on wrinkles/elastosis and pigmentation continuing for the 6 months following completion of the treatment course. The study protocol was approved by the Schulman Associates Institutional Review Board for the U.S. site and the Landesärztekammer Rheinland-Pfalz for the German site. All patients signed an approved version of an informed consent form.

Study Subjects

Healthy male or female patients with Fitzpatrick [10] skin type I–IV, within the age range of 30–65 years, with baseline elastosis scores of 3–6 and mild to moderate facial pigmentation, were considered eligible to participate in this study. Heavy smokers, pregnant, and breastfeeding women, women within 3 months of delivery or 6 weeks of discontinuing breastfeeding, individuals unlikely to refrain from tanning, and those receiving photoactive medication or who had recently received oral isotretinoin were not considered eligible to participate in the study. Similarly, the presence of active acne and other dermal/epidermal abnormalities or disorders was a contraindication to this study. Facial treatments within 3 months of study, facial skin laser/light or Botox treatment within 6 months of the study, facial ablative resurfacing treatment within 12 months of the study, facial surgery within 9 months of the study, and a history of keloids and/or allergy to anesthetics were also exclusion criteria.

Study Design

The treatment regimen included three combined procedures that began with IPL (Lumenis[®] M22[™] IPL module [Yokneam, Israel], 560 nm filter, fluence: 12–17 J/cm², 2–3 sub-pulses, with pulse duration of 3–4 ms and delay of 15–30 ms), followed by NAFL (Lumenis[®] M22[™] ResurFX[™] 1,565 nm module [Yokneam, Israel], 20–35 mJ, 200–350 spots/cm² and up to 12 mm spot). Before all treatment sessions, prophylactic treatment was administered to patients with a history of herpes simplex. Facial skin was cleansed and frontal, right, and left side digital photographs were taken in controlled lighting conditions using standard photography equipment (Canfield Omnia using a canon EOS Rebel T5i or FotoFinder with digital SLR camera and PolFlash). A topical anesthetic (Plagiis or BLT [Betacaine/Lidocaine/Tetracaine compound]) was applied at least 1 h before treatment. Immediately following treatment, cold air or cold, but not frozen, wet gauze pads were applied when necessary to cool the treated area. A bland emollient was applied shortly after treatment without any dressing. Patients were discharged within no less than 30 min and were asked to refrain from using skin products containing any of the drugs and ingredients contraindicated in this study. Additionally, the patients were instructed to avoid sun exposure and refrain from using tanning booths, sprays, or creams throughout the study period. Sunscreens with at least SPF 30 were to be used on a daily basis. Intervals of 4–6 weeks were enforced between treatment sessions. Follow-up visits were performed 1, 3, and 6 months after the last treatment session.

Evaluations

Adverse events and post-treatment complications were recorded throughout the study period. Skin wrinkles and elastosis were evaluated by each physician, using the Fitzpatrick Wrinkle and Elastosis Scale (FES) [11] while change in skin tone was categorized using the percentage

category scale (0%, no improvement; 75–100%, excellent response—most or all lesions much lighter or gone). The 5-point Global Aesthetic Improvement (GAI) [12] scale served to score changes in fine lines/wrinkles, texture, tone, mottled pigmentation, and overall improvement (0, worse; 4, very much improved). Treatment success was defined as a mean improvement from baseline of at least one on the FES or a $\geq 50\%$ improvement in at least one category on the GAI scale by the 3-month follow-up visit.

Patients rated pain and discomfort immediately after treatments using the visual analogue scale (VAS) (0, no pain; 10, intolerable pain). Skin response to treatment was assessed within 30 min after each treatment session and was described by severity and duration. Patient social downtime was recorded at the following treatment session. The 5-point Likert scale was used to rate patient satisfaction (0, no satisfaction; 4, very good satisfaction).

Statistical Analyses

All statistical analyses were performed using SAS[®], version 9 software (SAS Institute, Cary, NC). All statistical tests were two-sided, and statistical significance was set at $P \leq 0.05$. Changes from baseline were modeled as a function of baseline value and visit number using a repeated measure analysis of variance model. The LS-means of the change from baseline for the different visits were estimated using the model. Downtime, comfort, satisfaction, and improvement ratings were modeled as a function of visit number using repeated measure analysis of variance models. The LS-means of inter-visit differences were estimated from the model. Means and standard errors (SE) are presented.

RESULTS

A total of 33 Fitzpatrick type II–IV patients, with a mean age of 46.1 ± 1.3 years, were recruited for full-face IPL-NAFL combination treatment performed at the two clinics (Table 1). A single patient exhibited an intense response to the test spots, and two patients were lost to follow-up after completing the 1-month follow-up visit. All three of these patients were excluded from the analysis.

TABLE 1. Patient demographics and baseline characteristics

	<i>N</i> = 33
Age (years)	
Mean (SD)	46.1 (7.16)
Min, Max	32, 58
Female, <i>n</i> (%)	29 (87.9)
Male, <i>n</i> (%)	4 (12.1)
Caucasian, <i>n</i> (%)	31 (93.9)
Hispanic/Latino, <i>n</i> (%)	2 (6.1)
Skin type, <i>n</i> (%)	
II	12 (36.4)
III	19 (57.6)
IV	2 (6)
Wrinkle/elastosis score	
Mean (SD)	4.0 (1.0)

Wrinkle/elastosis scores improved over the follow-up period, with significant clinical improvement being evident as from the 1st-month follow-up visit, when 59% of patients showed a ≥ 1 -point improvement in FES scores. This improvement remained relatively steady until the end of the monitoring period ($P < 0.001$). In parallel, a significant improvement in fine lines and wrinkles was observed throughout the 6-month follow-up period in $\geq 76.6\%$ of the patients ($P < 0.001$). Pigmentation grading reflected a good to excellent response in most patients (63.3–68.8%) throughout the follow-up period, with only ≤ 2 patients showing mild to trace changes at the three follow-up visits (Fig. 1). At all follow-up visits, physicians graded the overall improvement as “improved” to “much improved” in over 90% of the patient population (Fig. 1). When considering specific GAI subscales, the evaluating physicians noted improvements in texture, tightness, and brightness in $\geq 90\%$ of the patients at both the 1- and 3-month follow-up sessions, which were maintained until the 6-month follow-up visit in $\geq 80\%$ of the patients (Fig. 1). Improvements in mottled pigmentation were observed in 86.6–94.0% of the patients, with the incidence slightly declining over time after the treatment.

At all follow-up visits, overall improvement was noted by 90% of the patients (Fig. 2). When considering the specific skin parameters evaluated, the vast majority of patients ($>83\%$) saw their condition as “improved” to “much improved,” with 60% of patients noting improvements in all evaluated categories. No patients reported worsening of skin texture, brightness, and tightness; and improvements were noted by 93%, $>80\%$, and $\geq 80\%$ of patients, respectively, throughout the follow-up period (Fig. 2). In free-text evaluations provided by 17 patients, 82% included mention of improvements in skin color, pigmentation and/or tone, while 53% reported improved skin texture and improvements noticed by their colleagues and friends. Following the completion of the treatment sessions and throughout the 6-month follow-up period, 65.6–70% of patients rated their overall satisfaction with the therapy as “good” or “very good” (Fig. 3–8).

Mean treatment-associated facial pain was tolerable across the treatment sessions, with all mean per-session scores being ≤ 4.4 . The majority of patients reported none to moderate erythema and edema. Onset of post-treatment dryness and flaking typically occurred within 2 days and persisted for up to 2 days. Nonetheless, patient-reported downtime was up to 2.2 ± 0.4 days due to swelling and 3.3 ± 0.4 days due to redness, which were similar across treatment sessions. Mean social downtime was 1.5 ± 0.25 days.

No severe nor serious events were reported throughout the study period. Adverse events (Table 2) considered definitely related to treatment included a single event of severe pruritus that began the day of treatment and resolved spontaneously without sequela within 7 days. Additionally, three cases of pinpoint bleeding mainly appeared over telangiectasia of the nose immediately after treatment and lasted from several seconds

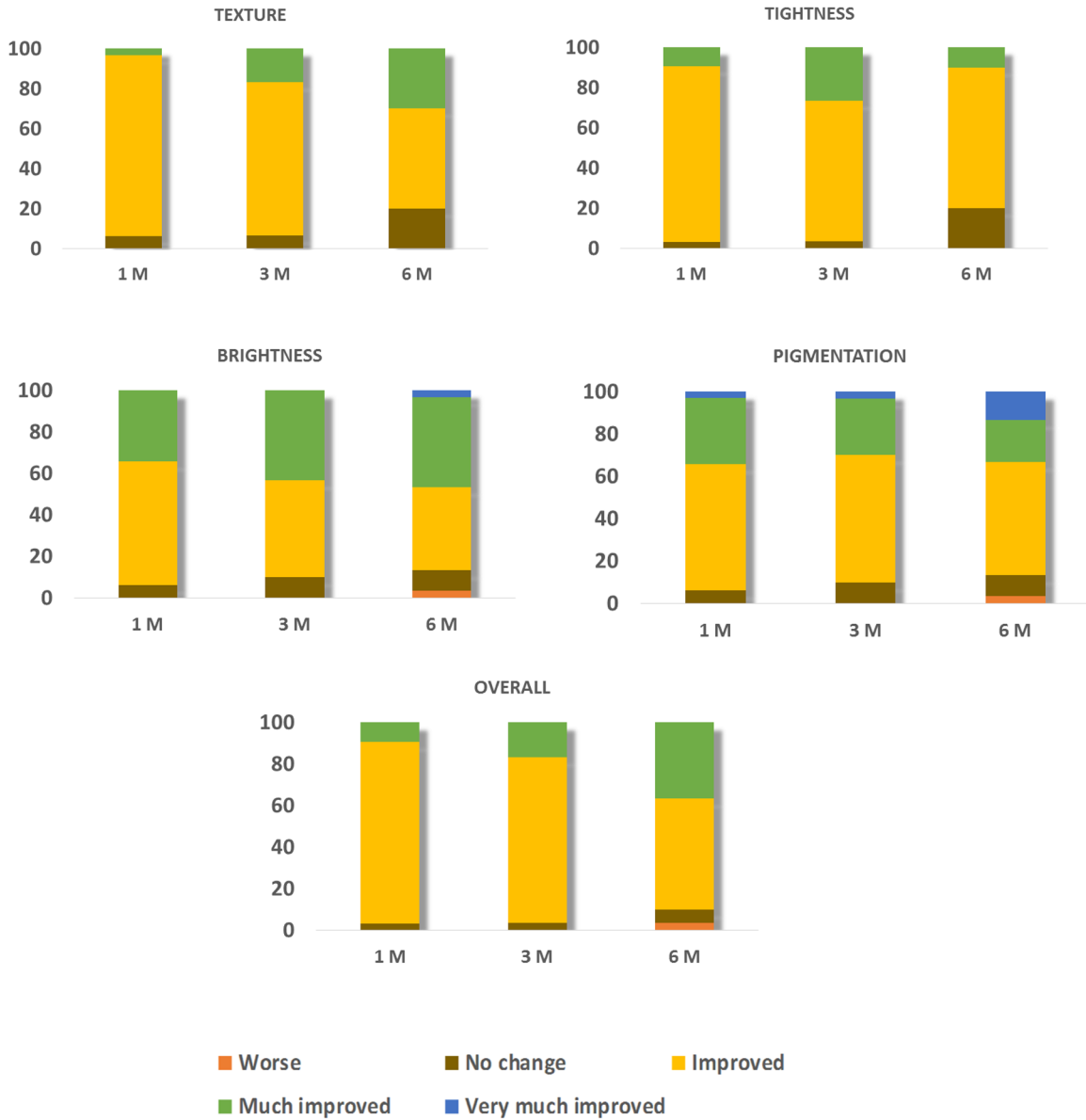


Fig. 1. Investigator-assessed improvement in various parameters (texture, tightness, brightness, pigmentation) and overall improvement (0, worse; 1, no change; 2, improved; 3, much improved; 4, very much improved) at 1, 3, and 6 months following three treatments with IPL followed by NAFL treatment. At 1 month, 3 months, and 6 months following last treatment, overall improvement was “improved” or “much improved” in majority of the subjects.

to 3 days before resolving with no residual effects. Another patient reported nasal redness and bruising, which self-resolved without residual effects within 7 days. Finally, a single case of herpes simplex outbreak was reported one week following treatment, which resolved within 5 days.

DISCUSSION

A better understanding of the multifactorial nature of skin aging and its underlying cellular mechanisms has led dermatologists to begin implementing multiple treatment methods to address the cutaneous signs of photoaging. While

combined treatments are gaining in popularity, they are mostly non-standardized and few works have reported same-day sequential treatment protocols. This prospective study was initiated to assess the hypothesized synergistic impact of combined IPL and NAFL treatment on photoaged skin.

IPL is commonly deployed to address vascular and pigment changes, and to a lesser extent, to achieve skin smoothing. This technology is particularly associated with short downtimes and a high safety profile [13–15]. Tanaka et al. [16] described the effect of a single IPL treatment in 40 Japanese patients with facial solar lentigines resulting in significant improvement in all patients. Bitter et al. [13]

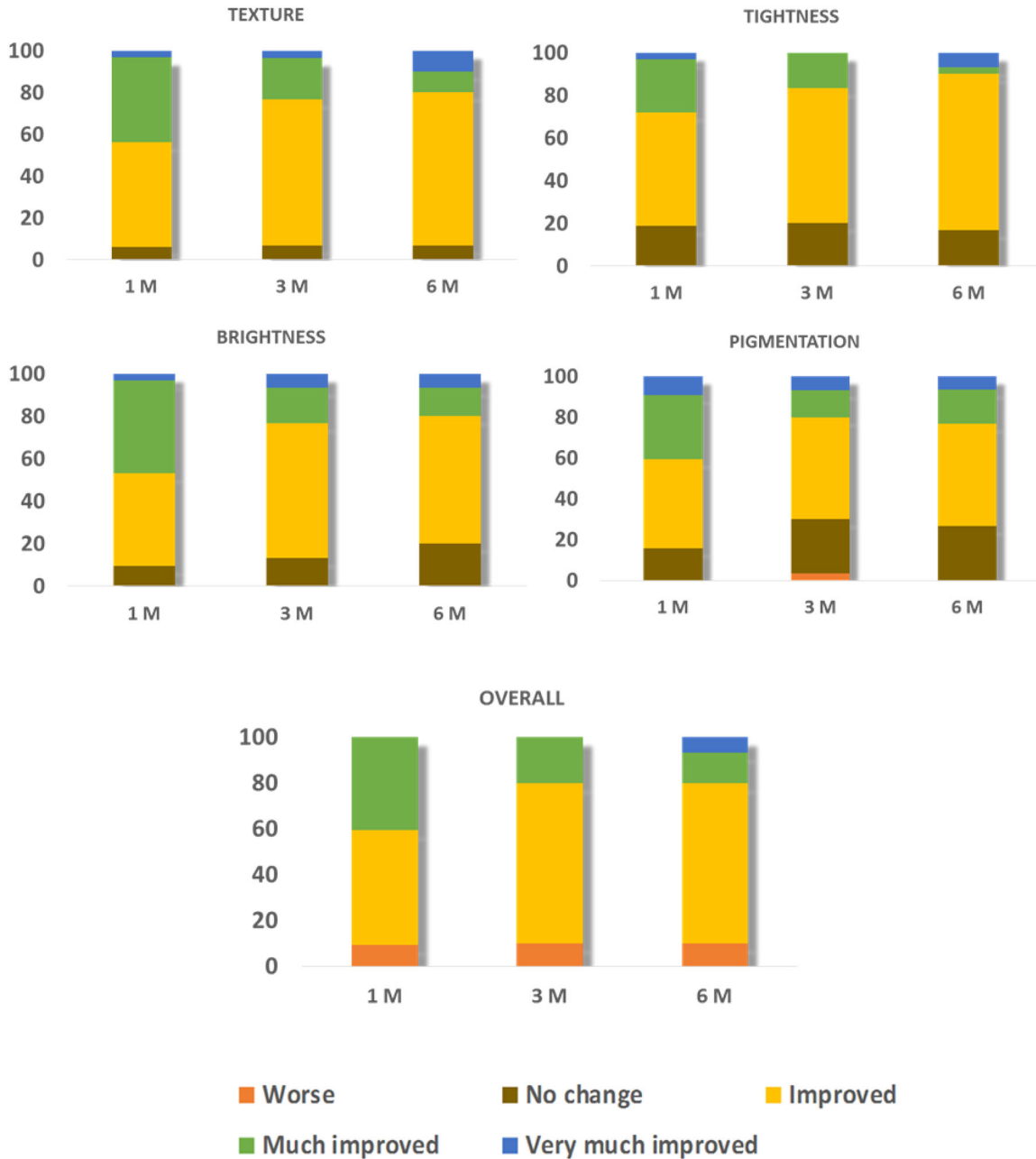


Fig. 2. Patient-assessed improvement in various parameters (texture, tightness, brightness, pigmentation) and overall improvement (0, worse; 1, no change; 2, improved; 3, much improved; 4, very much improved) at 1, 3, and 6 months following three treatments with IPL followed by NAFL treatment. At 1 month, 3 months, and 6 months following last treatment, overall improvement was “improved” or “much improved” in majority of the patients.

showed visible improvement in photodamage following five IPL treatments at 3 week intervals, resulting in over 50% improvement in facial wrinkles, pores, and telangiectasia in 49.5%, 67%, and 70% of patients, respectively. Negishi et al. [17] described IPL treatment delivered in 3–6 sessions, spaced at 2–3-week intervals, to 97 Asian patients with signs of photoaging resulted in a >56% improvement in pigmented lesions in 92.7% of patients, while only 54.7% showed similar improvements in skin

texture. Similarly, Brazil and Owens [4] reported >50% clearance in abnormal pigmentation among 62% IPL-treated patients 6 weeks following their last treatment session. This clearance rate progressively increased to include 72% of patients by 6 months post-treatment, at which point 64% of patients also showed >50% clearance of abnormal vascularity. However, improvements in solar elastosis scores were modest at the 6-week and 6-month follow-up visits. NAFL treatment creates microscopic

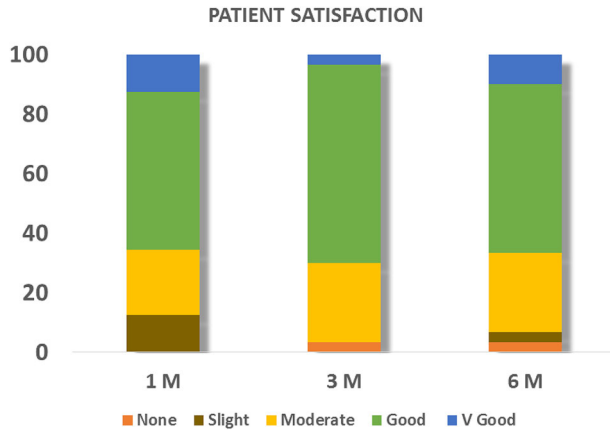


Fig. 3. Patient-assessed satisfaction (0 = none, 1 = slight, 2 = moderate, 3 = good, 4 = very good) at 1, 3, and 6-month follow-up visits. At the 6 months follow up, most patients rated their improvement and satisfaction as “good” or “very good.”

thermally damaged zones, while the surrounding unaffected tissue serves as an immediate source of viable cells for rapid repair and recovery [18,19]. This technology is primarily associated with improved skin texture and reduced wrinkles, with minimal downtime when compared to fully-ablative resurfacing. In a randomized, controlled study performed with a fractional non-ablative 1,540-nm laser, 10 patients undergoing three monthly treatment sessions to treat acne scarring displayed even and smooth scar texture following therapy, manifested by a 2-point mean reduction in texture scores within 4 weeks of the last treatment session. This improvement was sustained over the ensuing 8 weeks, while no change from baseline in skin

redness and pigmentation was noted [20]. In a similar trial with a 1,550-nm laser, all 10 patients displayed some level of improvement in acne scarring at a 6-month follow-up visit [21]. When implementing a six-session 1,440-nm NAFL regimen to improve skin appearance in 20 patients, Saedi et al. [22] noted a mean overall improvement score of 2.75 ± 0.2 measured on a 4-point scale.

Our findings demonstrate that our multi-modality approach enabled patients to benefit from the strengths of both IPL and NAFL with significant improvements in both wrinkle and pigmentation scores. Enhancement in overall appearance was noted among >90% of patients, with particularly impressive impacts on skin texture, tightness, brightness, and pigmentation. Treatment success exceeded 80%, with the vast majority of patients demonstrating improvements in all GAI-evaluated parameters (e.g., fine lines/wrinkles, texture, tightness, brightness, mottled pigmentation, and overall improvement). The slight decline over time in improvements in mottled pigmentation appearance could be attributed to the overlap between the follow-up period and the summer season, along with a protocol that prohibited skin-lightening creams and retinoids. Thus, we suggest that the same-day sequential IPL-NAFL regimen enhances the skin rejuvenation effect achieved with each individual modality.

As expected, our combination approach was found to be safe, tolerable, and associated with minimal downtime and side effects (Table 2). In a retrospective single-center analysis of the incidence of side effects and complications associated with 961 consecutive NAFL skin rejuvenation treatment sessions, 74% of which were performed on the face, only 7.6% of patients developed complications, with

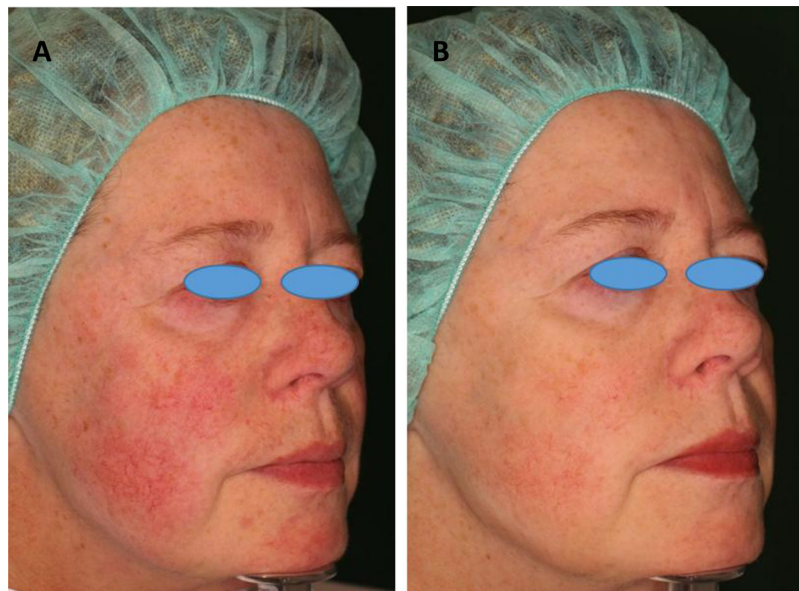

Fig. 4. Clinical results of the combination therapy. Patient's face before (A) and 1 month after (B) the third combined treatment session. Treatment settings for IPL: filter 560 nm, fluence 11–12 J/cm², 2–3 pulses, pulse duration of 3 and 20 ms pulse delay. Treatment settings for NAFL treatment: Energy 20 mJ and Density 250–350 spots/cm².

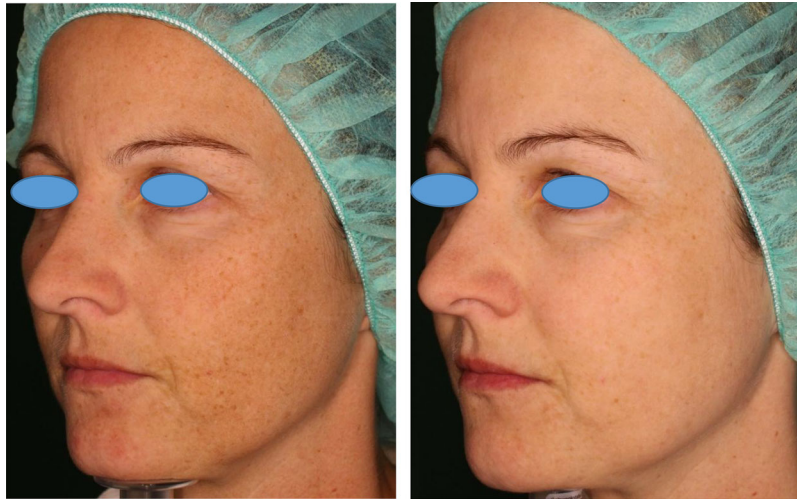

Fig. 5. Clinical results of the combination therapy. Patient's face before and 1 month after the third combined treatment session. Treatment settings for IPL: filter 560 nm, fluence 13 J/cm², 3 pulses, pulse duration of 3 and 20 ms pulse delay. Treatment settings for NAFL treatment: Energy 30 mJ and Density 300 spots/cm².

acneiform eruptions, herpes simplex outbreaks and erosions being the most common (1.9%, 1.8%, and 1.4%, respectively) [23]. Post-inflammatory hyperpigmentation was noted in only 0.73% of cases, most commonly among patients with darker skin phototypes, and prolonged erythema or edema was only noted in 0.83% and 0.62% of cases, respectively. Wanner et al. [24] reported erythema and edema in 100% and 68% of their 50-patient cohort undergoing facial and non-facial 1,550-nm Erbium-doped fiber NAFL, respectively. All of these effects resolved within <3 days. Acneiform eruptions were observed in two patients (4%), which persisted for <14 days. An identical

incidence of acneiform eruptions, all mild, was reported by Bencini et al. [25] following a six-session NAFL regimen (1,540-nm erbium glass fiber laser) for moderate to severe acne scars. Only one of the 87 treated patients experienced hyperpigmentation, which cleared within 1 month. Clark et al. [26] reported a 4% incidence of post-inflammatory hyperpigmentation documented in 115 retrospectively assessed charts of patients treated with a 1,550-nm erbium-doped fractional non-ablative laser. Two of the five events were transient (≤ 7 days), and only one persisted for 2 months. Mean treatment-associated facial pain was tolerable across the treatment sessions in our

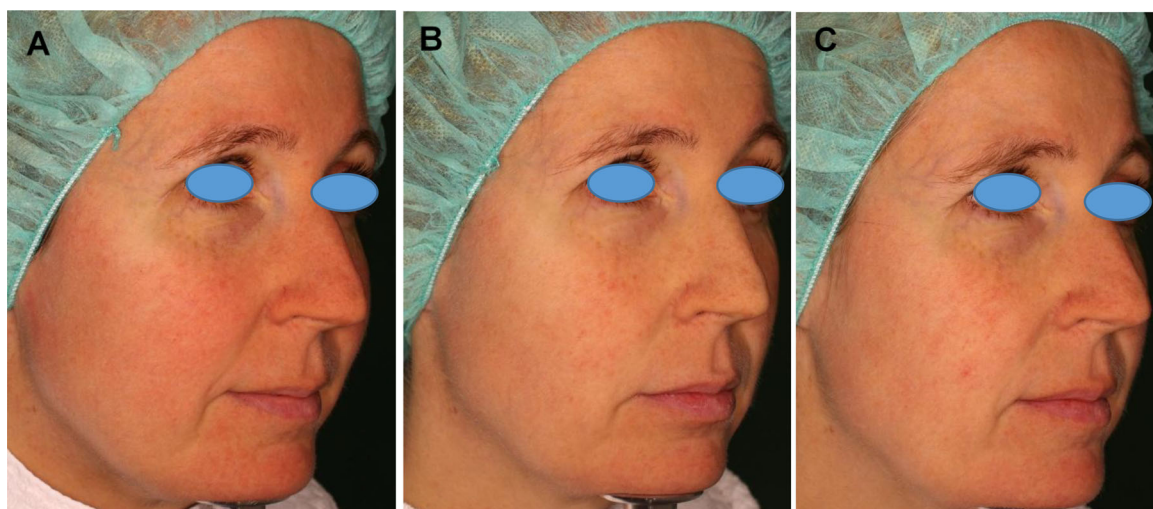


Fig. 6. Clinical results of the combination therapy. Patient's face before (A), 3 months (B), and 6 months (C) after the third combined treatment session. Treatment settings for IPL: filter 560 nm, fluence 12–13 J/cm², 3 pulses, pulse duration of 3 and 20 ms pulse delay. Treatment settings for NAFL treatment: Energy 25–30 mJ and Density 250–300 spots/cm².

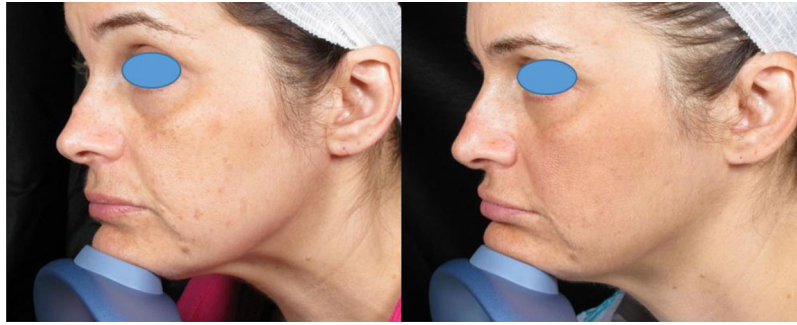

Fig. 7. Clinical results of the combination therapy. Patient's face before (A), and 3 months (B) after the third combined treatment session. Treatment settings for IPL: filter 560 nm, fluence 15–16 J/cm², 2 pulses, pulse duration of 4 and 30 ms pulse delay. Treatment settings for NAFL treatment: Energy 15–35 mJ and Density 250–350 spots/cm².

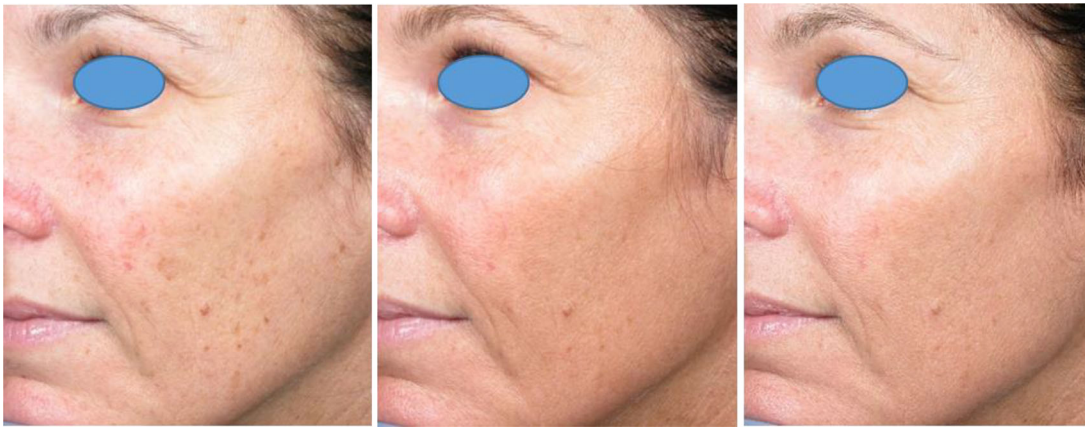

Fig. 8. Clinical results of the combination therapy. Patient's face before (A), 3 months (B), and 6 months (C) after the third combined treatment session. Treatment settings for IPL: filter 560 nm, fluence 14–15 J/cm², 2 pulses, pulse duration of 4 and 20 ms pulse delay. Treatment settings for NAFL treatment: Energy 20–35 mJ and Density 200–350 spots/cm².

study, with mean per-session scores ≤ 4.4 , similar to those reported by other patient cohorts treated with NAFL [21,22,27].

In Negishi's 97-subject cohort of Asian patients treated for photoaging using 3–6 IPL treatment sessions, no downtime was reported and only four complications were recorded, all of which resolved within 5 days, with no clinical sequela [17]. When combining full-face IPL and NAFL to treat actinic damage, Kearney et al. [6] reported

herpes simplex outbreak in 3.5%, pustule formation in 10%, and pruritus in 14%. Additionally, these authors noted a 10% incidence of prolonged, yet mild, erythema, which they attributed to the choice of fluence and density applied in the treatment protocol, noting that these parameters can be easily adjusted. The mean fluence and density range applied in our study (26.82 ± 5.3 mJ/spot and 200–350 spots/cm², respectively) and the 0.073% incidence of prolonged erythema (>1 week) were closer to results reported by Graber et al. [23], who reported a $<1.0\%$ incidence of prolonged erythema. Taken together, the downtime and immediate post-treatment sequela reported in our study were comparable to those typical of each individual treatment component, without cumulative effect. We postulate that this is due to the dissimilar target chromophores of each regimen along with continuous contact-cooling by the devices used in our study.

The limitations of this study relate to the lack of available studies for comparison. Split-face studies will be required to confirm the enhanced efficacy of sequential rejuvenation strategies compared to each modality alone.

TABLE 2. Summary of Adverse Events

	Resolved (max # of days)	N = 90 (treatments %)
Pruritus	7	1 (1.1)
Pinpoint bleeding	3	3 (3.3)
Redness and bruising	7	1 (1.1)
Herpes simplex	5	1 (1.1)

CONCLUSION

The combination of IPL with NAFL in a single-session treatment protocol proved safe and led to a synergistic and long-lasting effect on the various manifestations of photoaged skin, as consistently echoed by patient satisfaction scores. The effectiveness of our dual-modality protocol in skin type II–IV patients, who are highly susceptible to sun damage and pigmentation, was encouraging. Performing both treatments back to back on the same day simplifies care for both patients and providers, reduces expenses, increases patient satisfaction, and shortens overall downtime. We suggest that our combined treatment approach extends the applicable utilization of light- and laser-based platforms, while still achieving satisfying outcomes. Ongoing fine-tuning of treatment parameters and intervals are expected to keep on enhancing clinical outcomes and longevity.

ACKNOWLEDGMENT

Lumenis sponsored this study.

REFERENCES

- Preissig J, Hamilton K, Markus R. Current laser resurfacing technologies: a review that delves beneath the surface. *Semin Plast Surg* 2012;26:109–116.
- Alam M, Hsu TS, Dover JS, et al. Nonablative laser and light treatments: histology and tissue effects? A review. *Lasers Surg Med* 2003;33:30–39.
- Khan MH, Sink RK, Manstein D, et al. Intradermally focused infrared laser pulses: thermal effects at defined tissue depths. *Lasers Surg Med* 2005;36:270–280.
- Brazil J, Owens P. Long-term clinical results of IPL photorejuvenation. *J Cosmet Laser Ther* 2003;5:168–174.
- Sadick NS. Update on non-ablative light therapy for rejuvenation: a review. *Lasers Surg Med* 2003;32:120–128.
- Kearney C, Brew D. Single-session combination treatment with intense pulsed light and nonablative fractional photothermolysis: a split-face study. *Dermatol Surg* 2012;38:1002–1009.
- Friedmann DP, Fabi SG, Goldman MP. Combination of intense pulsed light, Sculptra, and Ultherapy for treatment of the aging face. *J Cosmet Dermatol* 2014;13:109–118.
- Tao L, Wu J, Qian H, et al. Intense pulsed light, near infrared pulsed light, and fractional laser combination therapy for skin rejuvenation in Asian subjects: a prospective multi-center study in China. *Lasers Med Sci* 2015;30:1977–1983.
- Trelles MA, Allones I, Vélez M, et al. Nd:YAG laser combined with IPL treatment improves clinical results in non-ablative photorejuvenation. *J Cosmet Laser Ther* 2004;6:69–78.
- Fitzpatrick TB. The validity and practicality of sun-reactive skin types I through VI. *Arch Dermatol* 1988;124(6):869–871.
- Lemperle G, Holmes RE, Cohen SR, Lemperle SM. A classification of facial wrinkles. *Plast Reconstr Surg* 2001;108(6):1735–1750.
- Carruthers A, Carruthers J. A validated facial grading scale: the future of facial ageing measurement tools? *J Cosmet Laser Ther* 2010;12(5):235–241.
- Bitter PH. Noninvasive rejuvenation of photodamaged skin using serial, full-face intense pulsed light treatments. *Dermatol Surg* 2000;26:835–843.
- Sadick NS, Weiss RA, Shea CR, et al. Long-term photorejuvenation using a broad-spectrum intense pulsed light source. *Arch Dermatol* 2000;136:1336–1340.
- Goldberg DJ, Cutler KB. Nonablative treatment of rhytids with intense pulsed light. *Lasers Surg Med* 2000;26:196–200.
- Tanaka Y, Tsunemi Y, Kawashima M. Objective assessment of intensive targeted treatment for solar lentigines using intense pulsed light with wavelengths between 500 and 635nm. *Lasers Surg Med* 2016;48(1):30–35.
- Negishi K, Tezuka Y, Kushikata N, et al. Photorejuvenation for asian skin by intense pulsed light. *Dermatol Surg* 2001;27:627–632.
- Manstein D, Herron GS, Sink RK, et al. Fractional photothermolysis: a new concept for cutaneous remodeling using microscopic patterns of thermal injury. *Lasers Surg Med* 2004;34:426–438.
- Bogdan AI, Kaufman J. Fractional photothermolysis—an update. *Lasers Med Sci* 2010;25:137–144.
- Hedelund L, Moreau KER, Beyer DM, et al. Fractional nonablative 1,540-nm laser resurfacing of atrophic acne scars. A randomized controlled trial with blinded response evaluation. *Lasers Med Sci* 2010;25:749–754.
- Saluja SS, Walker ML, Summers EM, Tristani-Firouzi P, Smart DR. Safety of non-ablative fractional laser for acne scars within 1 month after treatment with oral isotretinoin: A randomized split-face controlled trial. *Lasers Surg Med* 2017;49(10):886–890.
- Saedi N, Petrell K, Arndt K, et al. Evaluating facial pores and skin texture after low-energy nonablative fractional 1440-nm laser treatments. *J Am Acad Dermatol* 2013;68:113–118.
- Graber EM, Tanzi EL, Alster TS. Side effects and complications of fractional laser photothermolysis: experience with 961 treatments. *Dermatol Surg* 2008;34:301–307.
- Wanner M, Tanzi EL, Alster TS. Fractional photothermolysis: treatment of facial and nonfacial cutaneous photodamage with a 1,550-nm erbium-doped fiber laser. *Dermatol Surg* 2007;33:23–28.
- Bencini PL, Tournalaki A, Galimberti M, et al. Nonablative fractional photothermolysis for acne scars: clinical and *in vivo* microscopic documentation of treatment efficacy. *Dermatol Ther* 2012;25:463–467.
- Clark CM, Silverberg JI, Alexis AF. A retrospective chart review to assess the safety of nonablative fractional laser resurfacing in Fitzpatrick skin types IV to VI. *J Drugs Dermatol* 2013;12:428–431.
- Brauer JA, McDaniel DH, Bloom BS, et al. Nonablative 1927 nm fractional resurfacing for the treatment of facial photopigmentation. *J Drugs Dermatol* 2014;13:1317–1322.