

An uncommon case of dual ventricular response in dual atrioventricular nodal non-reentrant tachycardia

A case report

Meiwei Zhang, MD, Yeling Wang, MD, Dongmei Chen, MD, Hang Li, MD, Zhiguo Zhang, MD*

Abstract

Rationale: Dual atrioventricular nodal non-reentrant tachycardia (DAVNNT) is an uncommon arrhythmia. Because of the different refractory periods of fast and slow pathways, a single atrial depolarization gives rise to 2 ventricular activations through fast and slow pathways separately.

Patient concerns: A 45-year-old woman was referred to our Cardiology Center with symptoms of recurrent palpitations and fatigue persisting for the previous 3 years. On echocardiography, the ejection fraction of the left ventricle was 45%.

Diagnoses: Electrophysiological study findings and 12-lead electrocardiogram led to a diagnosis of DAVNNT.

Interventions: Our case responded very well to the ablation of the slow pathway, and her tachycardia completely disappeared.

Outcome: Her left ventricle ejection fraction also improved to 52% after 3 months of follow-up. The patient remained asymptomatic throughout the follow-up period of 1 year, without any recurrence or complications.

Lessons: DAVNNT is a rare arrhythmia which can induce tachycardia-induced cardiomyopathy. Ablation of the slow pathway is considered a curative treatment.

Abbreviations: AF = atrial fibrillation, AV = atrioventricular, DAVNNT = dual atrioventricular nodal non-reentrant tachycardia, ECG = electrocardiogram, EPS = electrophysiological study.

Keywords: dual atrioventricular nodal non-reentrant tachycardia, slow pathway, tachycardiomyopathy

1. Introduction

Dual atrioventricular nodal non-reentrant tachycardia (DAVNNT) is an uncommon arrhythmia, with only about 60 cases of DAVNNT resulting from 1:2 AV conduction in an atrioventricular node described in the literature till date.^[1] Because of the different refractory periods of fast and slow pathways, a single atrial depolarization gives rise to 2 ventricular activations through fast and slow pathways separately. We, hereby, report a unique case of 1:2 atrioventricular conduction in DAVNNT.

Editor: N/A.

The work was supported in part by grants from the National Natural Science Foundation of China (81570338 to ZZ).

The authors declare that they have no conflict of interest.

Department of Cardiology, the First Hospital of Jilin University, Changchun, Jilin Province, China.

* Correspondence: Zhiguo Zhang, Department of Cardiology, the First Hospital of Jilin University, Changchun, Jilin Province 130021, China (e-mail: zhangzhig@jlu.edu.cn).

Copyright © 2018 the Author(s). Published by Wolters Kluwer Health, Inc. This is an open access article distributed under the terms of the Creative Commons Attribution-Non Commercial-No Derivatives License 4.0 (CCBY-NC-ND), where it is permissible to download and share the work provided it is properly cited. The work cannot be changed in any way or used commercially without permission from the journal.

Medicine (2018) 97:23(e10938)

Received: 31 January 2018 / Accepted: 8 May 2018

<http://dx.doi.org/10.1097/MD.00000000000010938>

2. Case report

The case report was approved by the Institutional Review Board of the Hospital of Jilin University. The informed consent has been obtained from the patient.

A 45-year-old woman was referred to our Cardiology Center with symptoms of recurrent palpitations and fatigue persisting for the previous 3 years. On admission, she had dyspnea on exertion. On examination, she had edema in both legs, and pulmonary rales were heard on auscultation. On echocardiography, the ejection fraction of the left ventricle was 45%. A 12-channel electrocardiogram (ECG; Fig. 1) showed that each Q-wave, R-wave and S-wave (QRS) complex was followed by 1 P-wave, and after an interval, narrow QRS complex tachycardia was observed. The P-wave was captured and led to narrow QRS complex tachycardia. The P-wave and P-wave interval was regular, at about 680 to 740 ms. The P-wave and R-wave interval also was regular, at about 620 to 680 ms, and the morphology of the p-wave was suggestive of sinus node origin. The narrow QRS complex and sinus rhythm QRS complex were the same. During her hospital stay, the patient again had complained of palpitation, and her 12-lead ECG (Fig. 2) revealed irregular tachycardia with an average heart rate of 140 beats/min. In addition, 2 QRS complexes followed each p-wave out of these, with 1 being shorter and the other being larger.

To confirm the diagnosis, an electrophysiological study (EPS) was conducted which showed the absence of retrograde VA conduction on ventricular pacing. As shown in Fig. 3, the conduction of every atrial impulse was through the slow pathways, which helps us to understand the results shown in Fig. 1. Figure 4 shows us that there was a 1:2 AV relationship in

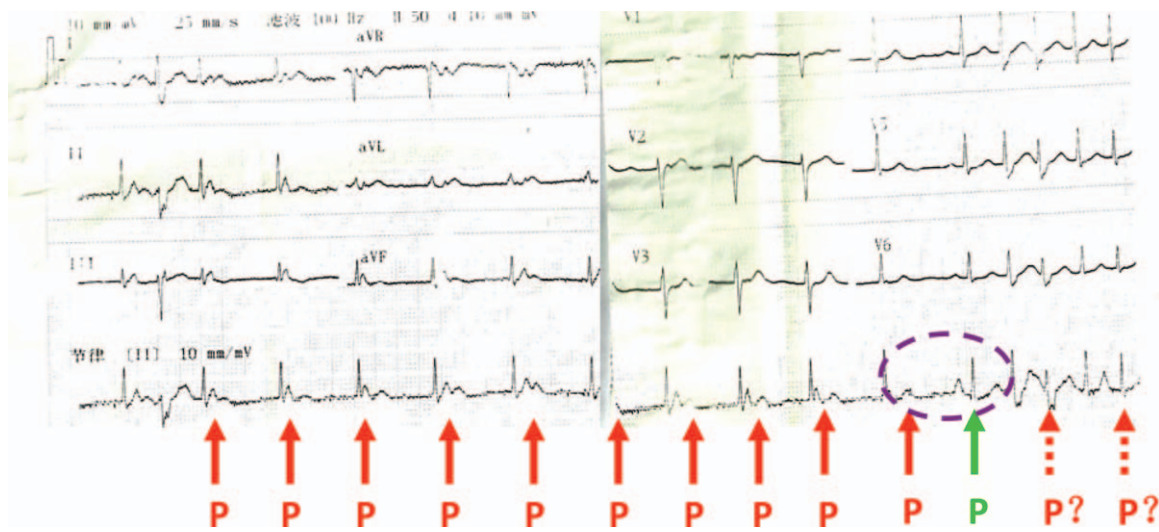


Figure 1. Each QRS complex was followed by 1 P-wave. After an interval, the P-wave captured ventricular and the resulting narrow QRS complex tachycardia. P= p wave, P?=may be p wave, R=QRS complex.

intracardiac recordings at the time of tachycardia. The His-ventricular intervals for the first and second complexes were the same. This fixed 1:2 relationship between atrial and ventricular activation suggested that every atrial activation evoked 2 ventricular contractions. The mechanism of this electrophysio-

logical phenomenon is shown in the ladder diagram of Fig. 2. There was non-inducibility of paroxysmal supraventricular tachycardia during the electrophysiological study. Thus, from the above EPS findings and 12-lead ECG, a diagnosis of DAVNNT was made based on the 1:2 AV conduction.

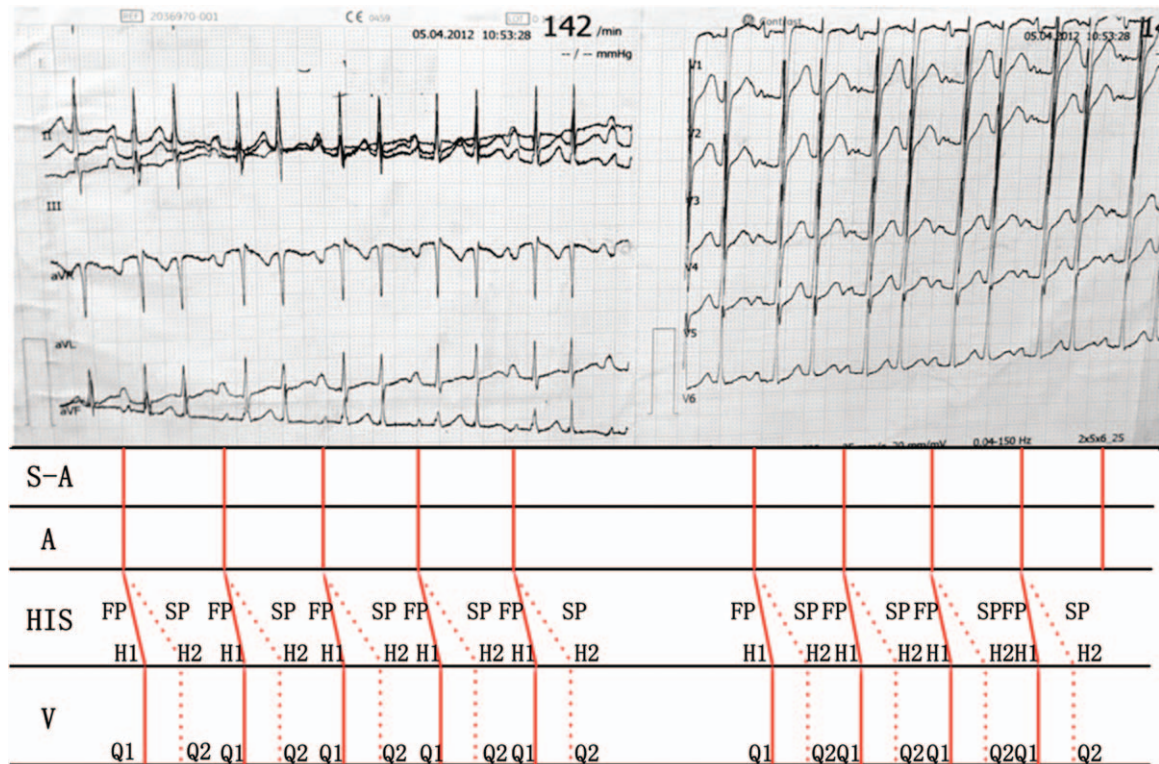


Figure 2. Twelve-channel surface ECG revealed that each p-wave was followed by 2 narrow QRS-complexes resulting in narrow QRS complex tachycardia. Ladder diagram showing each atrial impulse that evoked a double ventricular response through fast and slow pathways. ECG=electrocardiogram, FP=fast pathway, H1=His 1, H2=His 2, Q1=QRS complex 1, Q2=QRS complex 2, SP=slow pathway.

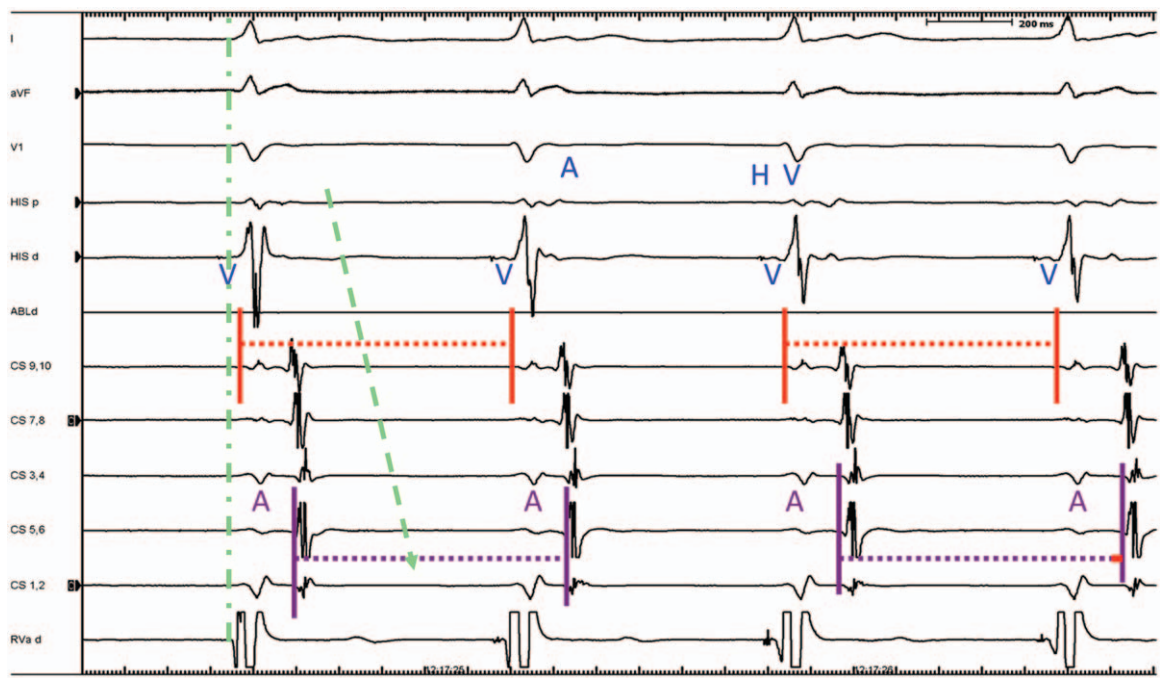


Figure 3. Excitement of His is earliest and excitement order of coronary sinus from the nearest point to the most distant point, which demonstrated that the impulse originated from the sinus node. The excitement for the right ventricular apex was earliest, which was followed by a confirmation of the normal ventricular excited order. CS=coronary sinus, His p=His bundle proximal, His d=His bundle distal, , Rva=right ventricular.

2.1. Treatment

Our case responded very well to the ablation of the slow pathway, and her tachycardia completely disappeared. The patient had no tachyarrhythmia on programmed atrial stimulation and intravenous infusion with orciprenaline. In

addition, there was no “jumping phenomenon.” Her left ventricle ejection fraction also improved to 52% after 3 months of follow-up. The patient remained asymptomatic throughout the follow-up period of 1 year, without any recurrence or complications.

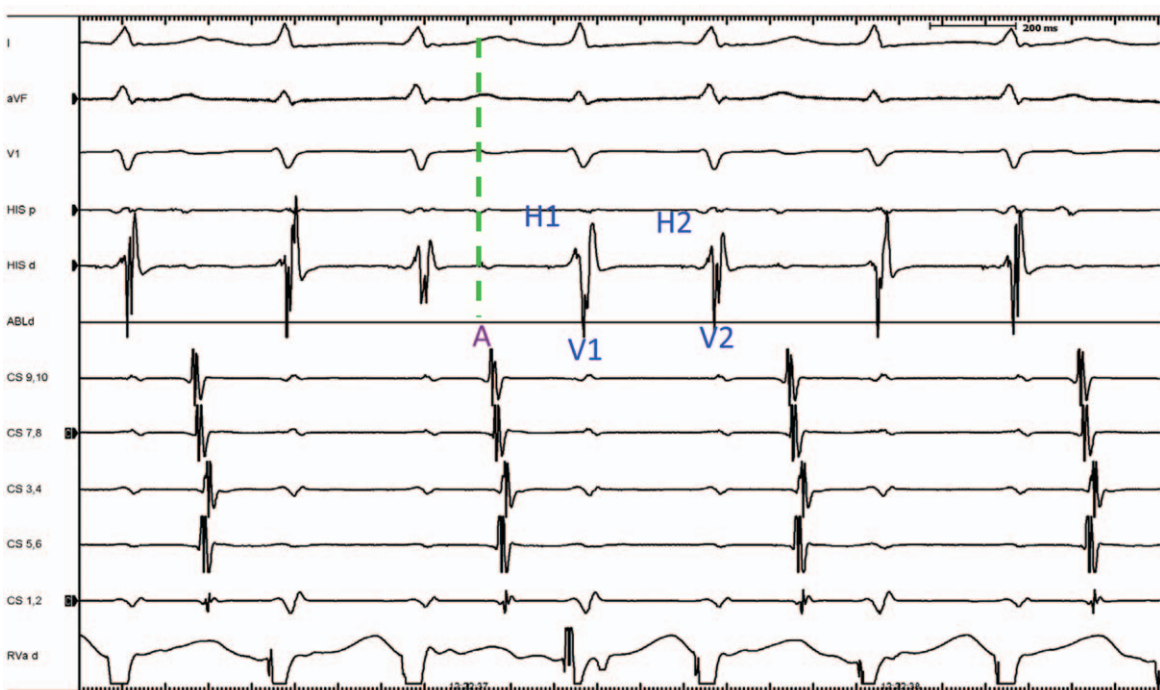


Figure 4. DAVNNT in the form of simultaneous atrioventricular nodal conduction through fast and slow pathways in a 1:2 pattern as revealed by a characteristic A-H1-V1-H2-V2 sequence. DAVNNT=dual atrioventricular nodal non-reentrant tachycardia.

3. Discussion

This particular form of atrioventricular nodal conduction was first reported by Wu et al^[2] in 1975. DAVNNT is a very rare condition and frequently misdiagnosed as a cause of tachyarrhythmia. A supraventricular impulse triggers a double ventricular response due to the simultaneous activation of slow and fast pathways. This induces a narrow QRS tachycardia with irregular R-WAVE and R-wave intervals. A body surface electrocardiogram shows a P-QRS1-QRS2 pattern. The heart cavity ECG shows A-H1-V1-H2-V2 pattern, which is characteristic of DAVNNT. The essential conditions for evoking this electrophysiological phenomenon are as follows: double pathways in the atrioventricular nodal, and both should have the functionality of antegrade conduction. Otherwise, there will not be 2 QRS complexes after each atrial impulse. The refractory period of the distal common pathway must be shorter than the difference in the conduction times over the fast and slow pathways, so that the impulses of these pathways reach the His bundle and ventricles after the refractoriness of previous impulses.^[3] The slow pathway should not have retrograde conduction. This arrhythmia is sometimes misinterpreted as junctional bigeminal extrasystole,^[4] which is difficult to diagnose on body surface ECG. This can be clarified only if electrophysiological examination is available. Atrial fibrillation (AF). Incorrect diagnosis of AF can be established if the double ventricular response is intermittent. AF is the most commonly mistaken diagnosis. Some patients were only correctly diagnosed after suffering from pulmonary vein isolation.^[5] There is a low incidence of this disease, but its definitive diagnosis remains challenging due to lack of diagnostic skills available to the treating physician.

Tachycardia-induced cardiomyopathy (i.e., tachycardiomyopathy) secondary to non-reentrant atrioventricular nodal tachycardia has been reported previously.^[3,6] Until recently, very few cases of tachycardiomyopathy resulting from DAVNNT had been reported, and such cases were completely cured by slow pathway ablation as in our patient.^[7] In our case, treatment with slow pathway ablation resulted in complete recovery of left ventricular functions. Therefore, early identification by EPS is of vital importance. Doctors should keep this disease in mind while treating such cases. Once this disease is suspected, EPS should be done as early as possible. The effect of medicinal treatment is less than satisfactory.^[4] Ablation of the slow pathway is believed to be a curative and secure treatment if the diagnosis is established.^[8-10]

4. Conclusion

DAVNNT is a rare arrhythmia which can induce tachycardia-induced cardiomyopathy. Ablation of the slow pathway is considered a curative treatment.

Acknowledgments

The trust and agreement of the patient are appreciated.

Author contributions

Data curation: Yeling Wang.

Writing – original draft: Meiwei Zhang, Hang Li, Zhiguo Zhang.

Writing – review & editing: Dongmei Chen, Zhiguo Zhang.

References

- [1] Wang NC. Dual atrioventricular nodal nonreentrant tachycardia: a systematic review. *Pacing Clin Electrophysiol* 2011;34:1671–81.
- [2] Wu D, Denes P, Dhingra R, et al. New manifestations of dual A-V nodal pathways. *Eur J Cardiol* 1975;2:459–66.
- [3] Akbarzadeh MA, Fazelifar AF, Bafraee NB. A case of dual atrioventricular nodal nonreentrant tachycardia: an unusual cause of tachycardia-induced cardiomyopathy. *J Arrhythm* 2015;31:328–30.
- [4] Di Biase M, Tritto M, Sabato G, et al. Electrocardiographic patterns during Holter monitoring in patients with first and second degree A-V block due to 'dual A-V nodal pathways'. *Eur Heart J* 1991;12:368–77.
- [5] Dixit S, Callans DJ, Gerstenfeld EP, et al. Reentrant and nonreentrant forms of atrio-ventricular nodal tachycardia mimicking atrial fibrillation. *J Cardiovasc Electrophysiol* 2006;17:312–6.
- [6] Clementy N, Casset-Senon D, Giraudeau C, et al. Tachycardiomyopathy secondary to nonreentrant atrioventricular nodal tachycardia: recovery after slow pathway ablation. *Pacing Clin Electrophysiol* 2007;30:925–8.
- [7] Fraticelli A, Saccomanno G, Pappone C, et al. Paroxysmal supraventricular tachycardia caused by 1:2 atrioventricular conduction in the presence of dual atrioventricular nodal pathways. *J Electrocardiol* 1999;32:347–54.
- [8] Kirchhof P, Loh P, Ribbing M, et al. Incessant supraventricular tachycardia with constant 1:2 atrioventricular ratio: a longitudinally dissociated atrioventricular node? *J Cardiovasc Electrophysiol* 2003;14:316–9.
- [9] Pott C, Wegner FK, Bogeholz N, et al. A patient series of dual atrioventricular nodal nonreentrant tachycardia (DAVNNT) - an often overlooked diagnosis? *Int J Cardiol* 2014;172:e9–11.
- [10] Francis J, Krishnan M. Dual ventricular response or 1:2 atrioventricular conduction in dual atrioventricular nodal physiology. *Indian Pacing Electrophysiol J* 2008;8:77–9.