

Laparoscopic Repair for Vesicoperitoneal Fistula with Vesicouterine Abscess

Tamaki Yahata^{1*}, Eiji Boshi², Kazuhiko Ino¹, Takenori Nishi²

¹Department of Obstetrics and Gynecology, Wakayama Medical University, Wakayama, ²Department of Obstetrics and Gynecology, Naga Municipal Hospital, Kinokawa-Shi, Wakayama, Japan

Abstract

Vesicoperitoneal fistula (VPF) is a rare form of urogenital fistulas. It is usually associated with an accidental trauma or iatrogenic injury including postoperative complications. Although it is difficult to heal the fistula conservatively, a laparoscopic repair is one of the effective methods. We report a case of VPF with vesicouterine abscess and repaired it laparoscopically. The transvaginal sonography showed the vesicouterine abscess, and a cystoscopy revealed a fistula between the vesicouterine abscess and the bladder. The abovementioned condition was confirmed at the time of laparoscopic surgery, and the fistula tract was closed laparoscopically.

Keywords: Laparoscopic repair, vesicoperitoneal fistula, vesicouterine abscess

INTRODUCTION

Although vesicoperitoneal fistula (VPF) is very rare, it is usually associated with postoperative complications. VPF has no specific symptoms, and it is difficult to diagnose.^[1] In general, the management of urogenital fistulae is performed: conservative treatment and surgical repair, but the timing of surgical repair of a fistula is controversial. We report the first case of successful treatment of VPF communicated with the abscess formation at the vesicouterine pouch by laparoscopically.

CASE REPORT

A 79-year-old woman, gravida 2, para 2, with normal vaginal deliveries, was admitted to a neighboring hospital with a chief complaint of diarrhea. Abdominal computed tomography (CT) revealed tumor-like masses in both the vesicouterine and Douglas' pouch. She was transferred to our hospital for a further examination of masses in detail. Physical examination

revealed a body temperature of 36.8°C, heart rate of 91/min, and blood pressure of 108/78 mmHg. Hematological and biochemical testing showed a red blood cell count of $342 \times 10^4/\mu\text{L}$ (normal range, 376–500 $\times 10^4/\mu\text{L}$), hemoglobin level of 10.9 g/dL (11.3–15.2 g/dL), white blood cell (WBC) count of $17.6 \times 10^3/\mu\text{L}$ (3.5–9.1 $\times 10^3/\mu\text{L}$), platelet count of $513 \times 10^3/\mu\text{L}$ (130–369 $\times 10^3/\mu\text{L}$), and C-reactive protein level (CRP) of 4.18 mg/dL (<0.4 mg/dL). Other laboratory tests, carcinoembryonic antigen, carbohydrate 19-9, and carbohydrate antigen 125 were normal. The transvaginal sonography (TVS) revealed the hypoechoic lesion of 38 mm \times 21mm in diameter at vesicouterine pouch and the lesion of 23 mm \times 11mm in diameter at the cul-de-sac of Douglas, respectively [Figure 1a]. Magnetic resonance imaging (MRI) showed the masses of high signal intensity on T1-weighted images (WI) [Figure 1b] and low signal intensity on T2-WI in those compatible lesions [Figure 1c]. Urinalysis revealed over 100 WBC per high-power field (HPF). Large

Address for correspondence: Dr. Tamaki Yahata,
Department of Obstetrics and Gynecology, Wakayama Medical University,
Wakayama, Japan.
E-mail: t-yahata@wakayama-med.ac.jp

Article History:

Received 24 August 2018
Received in revised form 16 June 2019
Accepted 25 September 2019
Available online 24 October 2019

Access this article online

Quick Response Code:



Website:
www.e-gmit.com

DOI:
10.4103/GMIT.GMIT_82_18

This is an open access journal, and articles are distributed under the terms of the Creative Commons Attribution-NonCommercial-ShareAlike 4.0 License, which allows others to remix, tweak, and build upon the work non-commercially, as long as appropriate credit is given and the new creations are licensed under the identical terms.

For reprints contact: reprints@medknow.com

How to cite this article: Yahata T, Boshi E, Ino K, Nishi T. Laparoscopic repair for vesicoperitoneal fistula with vesicouterine abscess. Gynecol Minim Invas Ther 2019;8:172-5.

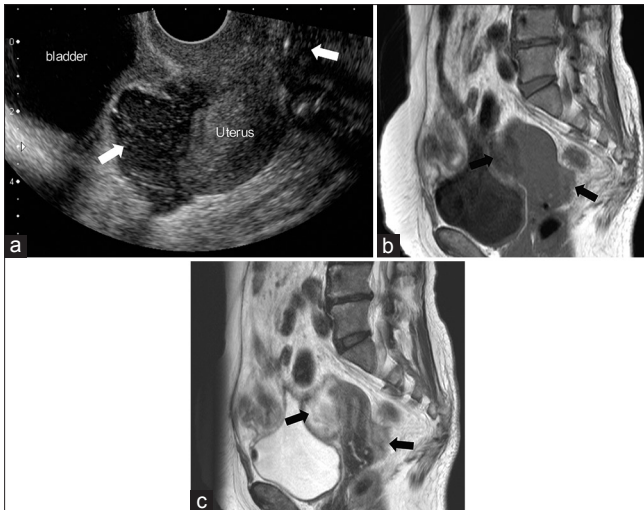


Figure 1: (a) Ultrasound image showed abscess of vesicouterine pouch and the Douglas' pouch (white arrow). (b) Axial T1-weighted magnetic resonance imaging showed abscess of vesicouterine pouch and the Douglas' pouch (black arrows). (c) Axial T2-weighted magnetic resonance imaging showed abscess of vesicouterine pouch and the Douglas' pouch (black arrows)

intestinal endoscopy showed normal findings. The laboratory and imaging findings suggested a diagnosis of pelvic abscess. Cefotiam hydrochloride was administered for 7 days, and pelvic infection was controlled. The laboratory data of WBC count decreased to $4.80 \times 10^3/\mu\text{L}$, CRP level decreased to 0.19 mg/dL, and urinalysis revealed 4 WBC/HPF. However, the tumor size reduction was not observed by conservative treatment. Therefore, cystoscopy was performed and revealed mucosal reddening with a leakage of the pus from the left posterior wall of the bladder [Figure 2a]. Pathological examination of the biopsied tissue confirmed the presence of acute inflammatory change. We diagnosed VPF, and we decided the operation at 3 months after conservative treatment. The laparoscopic approach was chosen to treat the fistula. After placement of 4 ports (a 12-mm intraumbilical port, two 5-mm pararectal ports on either side, and a suprapubic port), laparoscopy showed the adhesion between the bladder, sigmoid colon, and left adnexa of the uterus with abscess formation. The bladder was freed from the surrounding organs, and the fistula tract of bladder was identified [Figure 2b]. The adhesion surrounding the fistula orifice was dissected, and the orifice was closed in 2 layers. The first layer was performed intracorporeal interrupted stitches using 3-0 prolene sutures attached to a 22 mm needle of 1/2 circle (8762H, Ethicon, NJ, USA), and the second layer was performed intracorporeal nonlocking continuous running stitches using 3-0 vicryl sutures attached to a 36 mm needle of 1/2 circle (J322H, Ethicon, NJ, USA) by needle holder Durogrip 5 mm straight (PL407R, Aesculap, Inc. PA, USA). The postoperative period was uneventful, and a Foley urethral

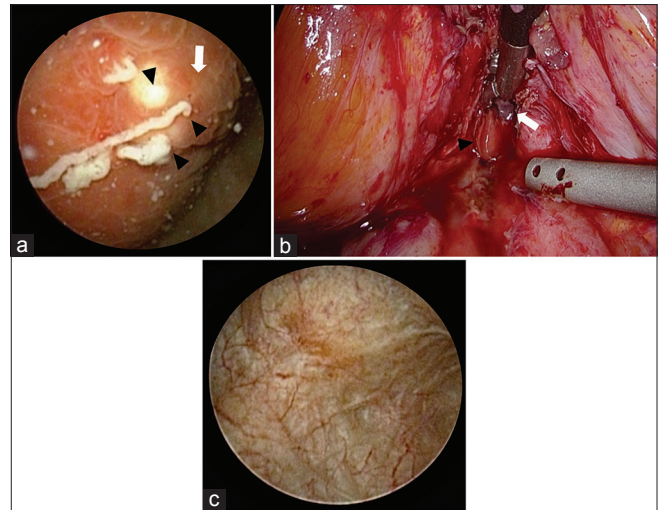


Figure 2: (a) The cystoscopic view of the mucosal reddening (white arrow) and a leakage of the pus (black arrowheads) at the left posterior wall of the bladder. (b) Laparoscopic image of the urine leakage (black arrowhead) from the bladder to peritoneal cavity after excision of the fistula tract (white arrow). (c) The cystoscopic view of postoperative revealed well-healed scar tissue at the left posterior wall of the bladder

catheter was removed at the 7th postoperative days. She was discharged from the hospital on the 16th postoperative day. The cystoscopy at 6 weeks after the operation revealed that the fistula tract was closed and healed well [Figure 2c]. Written informed consent was obtained from the patient regarding the publication of this case report and associated images and other clinical information.

DISCUSSION

The type of urogenital fistula is classified according to the anatomic location of the connecting tract. The etiology of fistula can be classified as infection, trauma, cancer, developmental anomalies, diverticulum, and so on. Vesicovaginal fistulas (VVF) are approximately three times more common than ureterovaginal fistulas. While, VPF rarely encounter.^[2] In a Belgian review, VPF was only one case (0.03%) of the 3190 laparohysterectomies.^[3] In the first case, a patient with both VVF and VPF after a laparoscopic hysterectomy presented with abdominal pain and anuria. Cystogram revealed fistulae. In this case, sutures from the cuff closure through the inferior aspect of the bladder dome were removed, and these fistulas were closed with transurethral Foley catheter. The authors suggested that the VPF can be more challenging to diagnose because of the vague symptoms of abdominal pain and bloating. Furthermore, they said that given the limited use of cystoscopy after surgery, many VPF may be unrecognized and resolve spontaneously without formal diagnosis.^[1] In the second case, the transurethral resectoscopic excision of bladder endometriosis was performed before few years, and this procedure might have

been a factor. TVS confirmed the presence of free fluid in the abdomen but also indicated the presence of a small nodule in the bladder wall and showed an interruption of a few millimeters of the wall near the vesicouterine pouch. An operative laparoscopy was performed to excise the endometriotic nodule and repair the VPF. Follow-up at 6 months indicated no recurrence.^[4] In most cases, several imaging modalities such as intravenous urography, cystography, hystero-graphy, colposcopy, cystoscopy, ultrasound, CT, and MRI might be useful to establish the diagnosis of urogenital fistulas.^[2] There have been no reports comparing which tools are useful for the diagnosis of VPF, but in the 15 patients with VVFs, the fistula was identified on TVS in all 15 cases (100% sensitivity), in 9 cases on intravenous pyelogram/cystogram (sensitivity 60%), and in 14 cases on cystoscopy (93% sensitivity).^[5] Guerriero *et al.* reported that TVS was useful for the diagnosis of bladder wall fistula in VPF.^[4] Wong *et al.* reported that the use of cystoscopy increased the rates of intraoperative detection of bladder injury from 84% to 94% in gynecologic laparoscopy for benign indication.^[6] Tai *et al.* reported the accuracy of retrograde cystography 85%–100% in bladder injury.^[7] In addition, the biochemical abnormalities of elevated blood urea nitrogen and serum creatinine level and the present of urinary ascites are helpful in the diagnosis of VPF.^[8] The management of urogenital fistulae are conservative treatment and surgical repair. The transurethral catheter drainage is useful for the healing of uncomplicated urogenital fistulae. If these conservative treatments are not successful, urogenital fistulas are managed with surgical repair.^[2,9,10] In some cases of VPFs, surgical repair was finally performed following transurethral catheter drainage.^[1,8] The conservative treatment should be attempted only in a small, clean, and nonmalignant case, and a prolonged catheter drainage for 3–5 weeks is suggested.^[9,10] On the other hand, when surgical repair is selected, the timing of fistula repair depends on the condition of the surrounding tissue. Healthy tissues allow for early repair. While, unhealthy tissues need to delay for 2–3 months to allow recovery from inflammation, infection, or tissue necrosis. This delay increases the opportunity for repair to success.^[9,10] Conversely, radiotherapy- or obstetric surgery-related fistula requires time for proper tissue regeneration of 3–6 months of aid before attempting repair.^[9,10] There have been no reports of the success rates of surgical repair in VPF, but in VVF of 197 patients, the success rate of surgical repair was 92% for fistulae of 1–2 cm compared with 50% for fistulae of over 4 cm. While, fistulae without fibrosis had 100% successful closure compared with 16.7% with marked fibrosis. The success rate of surgical repair was 70%–100% for nonradiated fistulae compared with 40%–100% for radiated fistulae.^[6] The success rates of

surgical techniques were no significant differences between one layer vaginal closure and two layers vaginal closure (91% vs. 93%) in a case series of 1045 VVF repairs.^[6] The reported case is a first one of VPF communicated with the abscess formation at the vesicouterine pouch and the fistula tract has been repaired laparoscopically. In our case, the traumatic or iatrogenic factors were not confirmed from the medical history and cystoscopic findings. Moreover, there were no factors causing fistula tract from the abdominal cavity to the bladder wall, such as past abdominal surgery, gastrointestinal disease, and malignancy. From the above, the cause of the fistula could not be identified, but there might be a possibility that the inflammation of the vesicouterine abscess spread to the bladder and formed a fistula. In this case, the conservative treatment was not effective, thus the laparoscopic approach was performed to repair the fistula.

CONCLUSION

We performed laparoscopic repair of VPF communicating with a vesicouterine abscess. When there is no response to conservative treatment, minimally invasive surgery such as laparoscopic repair is strongly recommended for VPF associated with a vesicouterine abscess.

Ethical statement

This study was approved by the institute academic committee of Naga Municipal Hospital, reference no. Letter dated 27/08/2019 obtained on August 29th, 2019.

Declaration of patient consent

The authors certify that they have obtained all appropriate patient consent forms. In the form, the patient has given her consent for her images and other clinical information to be reported in the journal. The patient understands that her name and initials will not be published and due efforts will be made to conceal her identity, but anonymity cannot be guaranteed.

Financial support and sponsorship

Nil.

Conflicts of interest

There are no conflicts of interest.

REFERENCES

1. James R, Mahajan ST. Concurrent vesicoperitoneal and vesicovaginal fistulae. *Int Urogynecol J* 2013;24:173-4.
2. Garely AD, Mann WJ. Urogenital tract fistulas in women. In: Up To Date. Post TW, editor. Waltham, MA: Up to Date; 20 January, 2018. Available from: <https://www.uptodate.com/contents/urogenital-tract-fistulas-in-women>. [Last accessed on 2019 Jun 16].
3. Donnez O, Jadoul P, Squifflet J, Donnez J. A series of 3190 laparoscopic hysterectomies for benign disease from 1990 to 2006: Evaluation of complications compared with vaginal and abdominal procedures. *BJOG* 2009;116:492-500.
4. Guerriero S, Piras B, Peddes C, Paladino E. Transvaginal sonography

- in diagnosis of vesicoperitoneal fistula due to deep infiltrating endometriosis as a cause of uroperitoneum. *Ultrasound Obstet Gynecol* 2012;40:727-9.
5. Sohail S, Siddiqui KJ. Trans-vaginal sonographic evaluation of vesicovaginal fistula. *J Pak Med Assoc* 2005;55:292-4.
 6. Wong MJ, Wong K, Rezvan A, Tate A, Bhatia NN, Yazdany T. Urogenital fistula. *Female Pelvic Med Reconstr Surg* 2012;18:71-8.
 7. Tai CK, Li SK, Hou SM, Fan CW. Bladder injury mimicking acute renal failure after Cesarean section: A diagnostic challenge and minimally invasive management. *Surg Laparosc Endosc Percutan Tech* 2008;18:301-3.
 8. Dawkins JC, Lewis GK, Christensen B, Wortman M. Urinary ascites in late onset of bladder injury post laparoscopic hysterectomy. *Case Rep Womens Health* 2017;16:8-10.
 9. Ghoniem GM, Warda HA. The management of genitourinary fistula in the third millennium. *Arab J Urol* 2014;12:97-105.
 10. Rogers RG, Jeppson PC. Current diagnosis and management of pelvic fistulae in women. *Obstet Gynecol* 2016;128:635-50.