

# Capsule Contraction Syndrome with a Microincision Foldable Hydrophilic Acrylic Intraocular Lens: Two Case Reports and Review of the Literature

Angelo Balestrazzi Alex Malandrini Gianluca Martone  
Davide Marigliani Tomaso Caporossi Gian Marco Tosi

Department of Ophthalmology, University of Siena, Siena, Italy

## Key Words

Cataract surgery · Capsulorhexis · Capsule contraction syndrome

## Abstract

Here we present 2 cases of capsule contraction syndrome (CCS). In both cases, a hydrophilic acrylic Akreos MI60 (Bausch and Lomb) intraocular lens (IOL) was implanted in the capsular bag through microincision cataract surgery, and the literature on the subject is reviewed. Since CCS has been described after the implantation of every IOL type, it is unlikely that the Akreos MI60 chemical and physical properties may cause CCS. When CCS occurs with IOLs composed of increasingly flexible materials that are inserted through incisions of decreasing size, a severe dislocation and deformation of IOL optics and haptics may develop. In both cases illustrated here, Nd:YAG laser anterior capsulotomy was highly effective. Hence, also based on the literature, which reports severe complications as a result of surgical intervention, it is suggested that Nd:YAG laser anterior capsulotomy be the first line of CCS treatment when the luxation of an IOL capsular bag is absent.

© 2014 S. Karger AG, Basel

## Introduction

The goal of modern cataract surgery is the rapid restoration of vision, which explains the tendency towards microincision phacoemulsification. However, serious postoperative complications may occur. Capsule contraction syndrome (CCS) is a well-recognized postoperative complication of cataract surgery, which has been mainly observed in conditions of zonular weakness and chronic intraocular inflammation [1–2]. The material

Gian Marco Tosi  
Department of Ophthalmology, University of Siena  
Viale Bracci 1  
IT-53100 Siena (Italy)  
E-Mail [gmtosi@tin.it](mailto:gmtosi@tin.it)

and design of intraocular lenses (IOLs) have been hypothesized to play a role in anterior capsule opacification, the milder form of the disease [2]. However, CCS has been reported to occur with different types of IOLs, including polymethylmethacrylate, silicone and acrylic [2–24]. Herein, we illustrate 2 cases of CCS following microincision cataract surgery without any associated ocular or systemic disease and we also review the literature on the subject (table 1).

## Case Reports

### Case 1

A 72-year-old female was referred to our center due to visual acuity reduction in her left eye (LE). Her general medical history was unremarkable. Her ocular history was positive for cataract surgery involving microincision phacoemulsification and an in-the-bag implantation of an Akreos MI60 (Bausch and Lomb) IOL in her LE 4 months previously. She did not report having had any ocular pathologies in the past. It was not possible to review her old records. Best-corrected visual acuity (BCVA) was 20/60 in her right eye (RE) and 20/100 in her LE. Dilated slit-lamp examination revealed a corticonuclear cataract in her RE, while her LE showed phimosis and a complete occlusion of the capsulorhexis incision by anterior capsule shrinkage, together with folding of the haptics as well as tilting and decentration of the IOL (fig. 1a, b). Her intraocular pressure was within normal limits in both eyes. A fundus examination showed normal results in both eyes, although CCS impaired her vision in the LE. No signs of past or current ocular inflammation or pseudoexfoliation were observed. Ultrabiomicroscopy analysis revealed a partial ciliary body detachment (fig. 1e, f). In her LE, a neodymium:YAG (Nd:YAG) laser was used to create a radial opening in the capsular phimosis, then to perform a circular enlargement and resolve the capsular synechiae of the haptics (fig. 1c, d). One week after Nd:YAG treatment, the visual acuity in her LE was 20/20 and the ciliary body detachment had been resolved (fig. 1g, h). Three months later, phacoemulsification and an in-the-bag implantation of an AcrySof SA60AT (Alcon) hydrophobic acrylic IOL was performed in her RE. Six months later, her BCVA was 20/20 in both eyes, without any CCS in her RE.

### Case 2

A 68-year-old female was referred to our center because of a visual acuity reduction in her LE. Her general medical history was unremarkable, while her ocular history was positive for cataract surgery involving microincision phacoemulsification and an in-the-bag implantation of an Akreos MI60 (Bausch and Lomb) IOL in her LE 3 months previously. She did not report having had any ocular pathologies in her past. It was not possible to review her old records. BCVA was 20/60 in her RE and 20/30 in her LE. Her LE showed a hypermetropic refraction of +2 +0.50 ×175. The patient reported that her LE visual acuity had been excellent, without spectacle correction, for the first 1.5 months after surgery. Dilated slit-lamp examination revealed a corticonuclear cataract in her RE and phimosis of the anterior capsule with capsulorhexis reduced to 2 mm in her LE, together with anterior folding of the haptics and a posterior dislocation of the IOL optic. Her intraocular pressure was within normal limits in both eyes. A fundus examination showed normal results in both eyes, although CCS impaired her vision in the LE. No signs of past or current ocular inflammation or pseudoexfoliation were observed. In her LE, an Nd:YAG laser was used to create a radial opening in the capsular phimosis, then to perform a circular enlargement and resolve the capsular synechiae of the haptics (fig. 1i). One week after Nd:YAG treatment, the visual

acuity in her LE was 20/20 without correction. Three months later, phacoemulsification and an in-the-bag implantation of an AcrySof SA60AT (Alcon) hydrophobic acrylic IOL was performed in her RE. Six months later, BCVA was 20/20 in both eyes, without any CCS in her RE.

## Discussion

While most patients who have cataract surgery with posterior-chamber IOL placement have excellent long-term results, IOL-related complications may occur even when the IOL is placed in the capsular bag. CCS is a postoperative complication occurring after in-the-bag IOL placement. The degree of anterior capsule contraction is believed to be related to many predictors, including the state of the patients' lens capsules and zonules, concurrent ocular pathology, and surgical complications [1–2].

We reported 2 patients with CCS after microincision cataract surgery hydrophilic acrylic Akreos MI60 IOLs were implanted in the capsular bag, without any associated ocular or systemic diseases. Both patients developed CCS, which caused ciliary body detachment in the first patient (as reported by Lanzl [7], Salzman et al. [8], and Srinivasan et al. [10]) and posterior dislocation of the IOL optic in the latter (as reported by Sanders et al. [14], Ozturk et al. [16], Qatarneh et al. [21], and Zaugg et al. [23]) (table 1). Notwithstanding the fact that no ocular risk factors were apparently present (since surgery had been performed elsewhere), we cannot exclude a weakness of the zonular apparatus, even in the absence of pseudoexfoliation or a small capsulorhexis as intraoperative causative factors of CCS.

We do not believe that Akreos MI60 chemical properties or its plate-haptic design played a role in causing CCS. In a series of 135 eyes, Can et al. [24] compared standard coaxial, microcoaxial and biaxial microincision cataract surgery in 2010, implanting 20 Akreos MI60 IOLs without reporting any cases of CCS at the respective 3-month follow-ups.

Notwithstanding the fact that the composition and design of IOLs might also influence the degree of anterior capsule contraction, CCS has been reported to occur with different types of IOLs including PMMA, silicone and acrylic, both hydrophobic and hydrophilic [2–24].

The literature data shows that CCS has occurred in eyes with and without risk factors after the implantation of every IOL type (PMMA, silicone and acrylic); however, looking at the most recent reports, CCS has mainly developed after hydrophilic acrylic IOL implantation (in 1 case after implanting Akreos MI60 [18], in 1 case after Raysoft 574 R, Rayner Intraocular lenses, Ltd. [23], in 1 case after Bioacryl, Biotech [23], in 5 cases after Quatrix IOL, Croma Pharma GmbH [22], and in 6 cases after implanting an Akreos IOL lens [19–21]) (table 1).

Nd:YAG laser anterior capsulotomy was effective in clearing the visual axis in both our patients and in resolving the ciliary body detachment in the first patient and the refractive error induced by the posterior dislocation of the IOL optic in the second. In the past, numerous successes with Nd:YAG laser anterior capsulotomy have been reported without any associated complications (table 1). We believe that the first treatment should always be performed with Nd:YAG laser anterior capsulotomy, unless an evident luxation of the complex IOL capsular bag is present. In fact, as reported by Ozturk et al. [16] and by Michael et al. [22], surgical treatment may lead to severe complications, notwithstanding a well-conducted original phacoemulsification, which is mainly the result of the capsular bag removal. In these cases, the authors [16, 22] did not report any previous attempts of treatment with Nd:YAG laser anterior capsulotomy (table 1).

As the interest in microincision cataract surgery continues to grow, there is a tendency to find increasingly flexible materials to insert or inject through smaller incisions [16]. However, as stressed by Zaugg et al. [23], Qatarneh et al. [21] and by Caravella [20], we believe that, when CCS occurs with IOLs such as the Akreos MI60, which has to be particularly soft to enter the eye through a microincision, it easily causes compression stretching of the IOL, resulting in a significant dislocation and deformation of both the optics and the haptics.

## Disclosure Statement

The authors declare no conflict of interest.

## References

- 1 Davison JA: Capsule contraction syndrome. *J Cataract Refract Surg* 1993;19:582–589.
- 2 Werner L, Pandey SK, Escobar-Gomez M, Visessook N, Peng Q, Apple DJ: Anterior capsule opacification; a histopathological study comparing different IOL styles. *Ophthalmology* 2000;107:463–471.
- 3 Scorolli L, Martini E, Scalinci SZ, Scorolli LG, Meduri R: Capsule contraction after continuous curvilinear capsulorhexis. *J Cataract Refract Surg* 1996;22:1245–1246.
- 4 Hayashi K, Hayashi H, Matsuo K, Nakao F, Hayashi F: Anterior capsule contraction and intraocular lens dislocation after implant surgery in eyes with retinitis pigmentosa. *Ophthalmology* 1998;105:1239–1243.
- 5 Spang KM, Rohrbach JM, Weidle EG: Complete occlusion of the anterior capsular opening after intact capsulorhexis: clinicopathologic correlation. *Am J Ophthalmol* 1999;127:343–345.
- 6 Chawla JS, Shaikh MH: Neodymium: Neodymium: YAG laser parabolic anterior capsulotomy in extreme capsule contraction syndrome. *J Cataract Refract Surg* 1999;25:1415–1417.
- 7 Lanzl IM, Kopp C: Ciliary body detachment caused by capsule contraction. *J Cataract Refract Surg* 1999;25:1412–1414.
- 8 Salzmann J, Khaw PT, Laidlaw A: Choroidal effusions and hypotony caused by severe anterior lens capsule contraction after cataract surgery. *Am J Ophthalmol* 2000;129:253–254.
- 9 Sudhir RR, Rao SK: Capsulorhexis phimosis in retinitis pigmentosa despite capsular tension ring implantation. *J Cataract Refract Surg* 2001;27:1691–1694.
- 10 Srinivasan S, van der Hoek J, Green F, Atta HR: Tractional ciliary body detachment, choroidal effusion, and hypotony caused by severe anterior lens capsule contraction following cataract surgery. *Br J Ophthalmol* 2001;85:1261–1262.
- 11 Moreno-Montañés J, Sánchez-Tocino H, Rodriguez-Conde R: Complete anterior capsule contraction after phacoemulsification with acrylic intraocular lens and endocapsular ring implantation. *J Cataract Refract Surg* 2002;28:717–719.
- 12 Ueno S, Kimura A, Hirata A, Tanihara H: Surgical treatment of complete anterior capsule contraction after cataract surgery. *Acta Ophthalmol Scand* 2004;82:461–462.
- 13 Musa F, Aralikatti AK, Prasad S: Choroidal effusion and hypotony caused by severe anterior lens capsule contraction following cataract surgery. *Eur J Ophthalmol* 2004;14:153–155.
- 14 Sanders DR, Higginbotham RW, Opatowsky IE, Confino J: Hyperopic shift in refraction associated with implantation of the single-piece Collamer intraocular lens. *J Cataract Refract Surg* 2006;32:2110–2112.
- 15 Prakash P, Kasaby HE, Aggarwal RK, Humfrey S: Microincision bimanual phacoemulsification and Thioptex implantation through a 1.70 mm incision. *Eye (Lond)* 2007;21:177–182.
- 16 Ozturk F, Snyder ME, Osher RH, Bishop JR 3rd: Hyperopic shift with posterior bowing of a Collamer posterior chamber intraocular lens. *J Cataract Refract Surg* 2007;33:159–161.
- 17 Venkatesh R, Tan CS, Veena K, Ravindran RD: Severe anterior capsular phimosis following acrylic intraocular lens implantation in a patient with pseudoexfoliation. *Ophthalmic Surg Lasers Imaging* 2008;39:228–229.
- 18 Cavallini GM, Masini C, Campi L, Pelloni S: Capsulorhexis phimosis after bimanual microphacoemulsification and in-the-bag implantation of the Akreos MI60 intraocular lens. *J Cataract Refract Surg* 2008;34:1598–1600.
- 19 Dubois VDJP, Ainsworth G, Liu CSC: Unilateral capsular phimosis with an acrylic IOL and two capsular tension rings in pseudoexfoliation. *Clin Experiment Ophthalmol* 2009;37:631–633.
- 20 Caravella LP: Laser treatment alternative to IOL exchange for capsulorhexis phimosis with anterior flexing of single-piece hydrophilic acrylic IOL haptics. *J Cataract Refract Surg* 2010;36:2222–2223.
- 21 Qatarneh D, Hau S, Tuft S: Hyperopic shift from posterior migration of hydrophilic acrylic intraocular lens optic. *J Cataract Refract Surg* 2010;36:161–163.

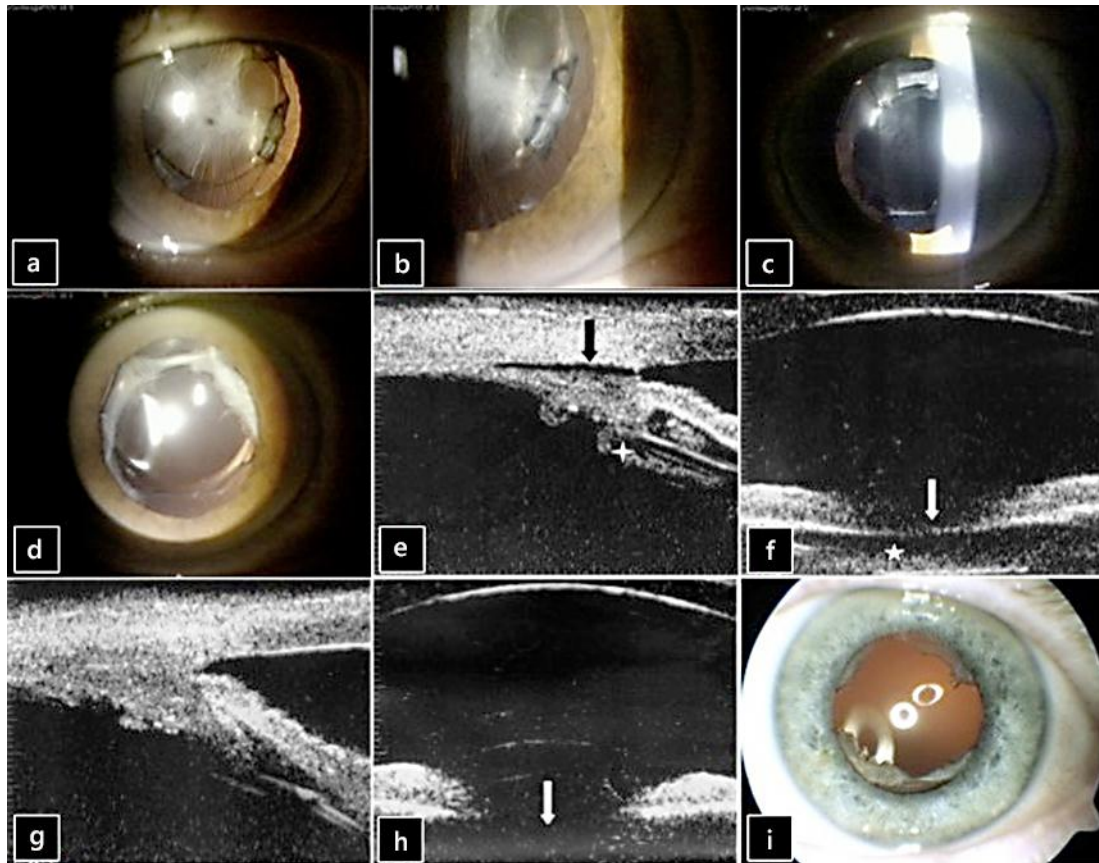
- 22 Michael K, O'Colmain U, Vallance JH, Cormack TGM: Capsule contraction syndrome with haptic deformation and flexion. *J Cataract Refract Surg* 2010;36:686–689.
- 23 Zaugg B, Werner L, Neuhann T, Burrow M, Davis D, Mamalis N, Tetz M: Clinicopathologic correlation of capsulorhexis phimosis with anterior flexing of single-piece hydrophilic acrylic intraocular lens haptics. *J Cataract Refract Surg* 2010;36:1605–1609.
- 24 Can I, Takmaz T, Yildiz Y, Ali Bayhan H, Soyugelen G, Bostanci B: Coaxial, microcoaxial, and biaxial microincision cataract surgery: prospective comparative study. *J Cataract Refract Surg* 2010;36:740–746.

**Table 1.** CCS after cataract surgery

Study	IOL type	Eyes implanted with this IOL type, n	Eyes with CCS, n	Age of patients with CCS, years	Predisposing ocular conditions	CCC size, mm	CTR implantation at the time of surgery	Time between surgery and CCS	Clinical manifestations	Treatment	Complications
Scorliti [3], 1996	PMMA (NBS)	NR	2	28, 68	M (1)	4.5	NI	1 month	NR	L (2)	NR
Hayashi [4], 1998	PMMA MZ60BD (Alcon)	47	14	NR	RP (47)	5.5	NI	within 12 months	VAR	L (14)	NR
Spang [5], 1999	PMMA (NBS)	NR	1	81	NAG	4–5	NI	2 months	VAR	SC	NR
Chawla [6], 1999	Allergan SI30 NB	NR	1	80	NR	5	NI	1.5 months	VAR	L	NR
Lanzl [7], 1999	3-piece PMMA, Pharmacia 155A	NR	1	74	None	5	NI	18 months	VAR, CBD with hypotony	L	NR
Salzmann [8], 2000	Foldable silicone (NBS), one-piece PMMA (NBS)	NR	2	72, 70	OAG (2)	NR	NI	2 months (2)	VAR (2), CBD with hypotony (2)	L and SC (1), L (1)	L ineffective in 1
Sudhir [9], 2001	PMMA, Universal Model	NR	1	56	RP, zonular laxity	6	I	4 months		L	NR
Srinivasan [10], 2001	Allergan SI40 NB	NR	1	72	OAG, previous trabeculectomy	5	NI	2.5 months	CBD, hypotony, VAR	L	NR
Montanes [11], 2002	AcrySof MA30BA (Alcon)	NR	2	69	PXE phakodonesis	NR	I (2)	2 months	VAR (1)	L (1)	NR
Ueno [12], 2004	AcrySof MA60BM (Alcon)	NR	1	80	PXE, OAG, phacodonesis	4–5	NI	1 month	VAR	IOL, CBR, Vx, scleral fixation IOL	NR
Musa [13], 2004	Soflex 2 (Bausch and Lomb)	NR	1	81	OAG, previous trabeculectomy	5	NI	2 months	VAR, hypotony, choroidal effusion	L	NR
Sanders [14], 2006	Collamer CC4204BF (Staar Surgical)	160,000	40	NR	NR	Less than 5.5 in several eyes	NR	1 week, 11 months	HS (40)	L (14)	NR
Prakash [15], 2007	ThinOptX (ThinOptX, Inc)	50	1	NR	NR	NR	NI	NR	NR	IOL	NR
Ozturk [16], 2007	Collamer CC420BF (Staar Surgical)	NR	2	69, 72	None	4.5 (1) NR (1)	NI	1 month (1), 7 weeks (1)	HS (1), HS-VAR (1)	IOL (1), IOL-CBR-IOLAC (1)	CE in 1
Venkatesh [17], 2008	Sensar AR40e (AMO)	NR	1	65	PXE	5–5.5	NI	2 months	VAR	L	NR
Cavallini [18], 2008	Akreos MI60 (Bausch and Lomb)	NR	1	80	None	5	NI	6 months	VAR	SC	NR
Dubois [19], 2009	Akreos Adapt (Bausch and Lomb)	NR	1	90	PXE	4	I	1.5 months	VAR	L	NR
Caravella [20], 2010	Akreos (Bausch and Lomb)	Large series NBS	2	NR	None	5.5	NI	3 months (1), NR (1)	none	L	NR
Qatarneh [21], 2010	Akreos Adapt (Bausch and Lomb)	NR	3	55, 48, 59	M (2), RP (2)	NR	NI	9 months, 11 months, 6 months	HS (2), VAR (1)	no (1), L (1), SC (1)	L (1) and SC (1) not effective
Michael [22], 2010	Quatrix (Croma-Pharma GmbH)	NR	5	56, 46, 81, 84	RP (1), U (1)	6–8 NBS	NI	2 months (1), 2 weeks (1), 1.5 months (1), 3 months (1), 6 m (1)	VAR (5)	IOL-IOLAC (1), SC-IOL-CBRVx-IOLAC (2), no (2)	GRT (1)
Zaugg [23], 2010	Raysoft (Rayner Intraocular Lenses, Ltd), Bioacryl (Biotech)	NR	2	60, NR (1)	None (1), PXE (1)	NR	NI (1) I (1)	1 month (1), NR (1)	VAR-HS (1), VAR (1)	IOL-CBR-Vx-IOLIF (1), IOL-CBR (1)	NR
Present report	Akreos MI60 (Bausch and Lomb)	NR	2	72, 68	None	NR	NI	4 months, 3 months	VAR (2), CBD (1), HS (1)	L (2)	NR

CBD = Ciliary body detachment; CBR = capsular bag removal; CCC = continuous curvilinear capsulorhexis; CE = corneal edema; CTR = capsular tension ring; GRT = giant retinal tear; HS = hyperopic shift; I = implanted; IOLAC IOL = in anterior chamber; IOL IOL = exchange; IOLIF = iris-fixated IOL; L Nd:YAG = laser anterior capsulotomy; M = myopia; NAG = narrow angle glaucoma; NBS = not better specified; NED = no evidence of disease; NI = not implanted; NR = not reported; OAG = open-angle glaucoma; PXE = pseudoexfoliation; RP = retinitis pigmentosa; SC = surgical anterior capsulotomy; U = uveitis; VAR = visual acuity reduction; Vx = vitrectomy.





**Fig. 1.** **a, b** CCS syndrome with severe IOL deformation and dislocation. **c, d** Anterior segment after Nd:YAG laser treatment of the phimosis. **e** Preoperative ultrabiomicroscopy analysis showing a partial ciliary body detachment (black arrow) and stretched and thickened zonular fibers (white cross). **f** Preoperative ultrabiomicroscopy showing a capsulorhexis phimosis as a highly reflective line in the pupillary space (white arrow) and a subcapsular fibrosis as not homogeneous echoes inside the capsular bag (white star). **g** Ultrabiomicroscopy analysis after Nd:YAG laser treatment of the phimosis showing a resolution of the ciliary body detachment and of the zonular traction. **h** Ultrabiomicroscopy analysis after Nd:YAG laser treatment of the phimosis showing the disappearance of the high reflective line together with a deepening of the posterior chamber (white arrow). **i** Anterior segment after Nd:YAG laser treatment of the phimosis.