

Midterm Clinical Outcomes after Modified High Ligation and Segmental Stripping of Incompetent Small Saphenous Veins

Ki Pyo Hong, M.D., Ph.D.

Background: The aim of this study was to evaluate the midterm clinical outcomes after modified high ligation and segmental stripping of small saphenous vein (SSV) varicosities. **Methods:** Between January 2010 and March 2013, 62 patients (69 legs) with isolated primary small saphenous varicose veins were enrolled in this study. The outcomes measured were reflux in the remaining distal SSV, the recurrence of varicose veins, the improvement of preoperative symptoms, and the rate of postoperative complications. **Results:** No major complications occurred. No instances of the recurrence of varicose veins at previous stripping sites were noted. Three legs (4.3%) showed reflux in the remaining distal small saphenous veins. The preoperative symptoms were found to have improved in 96.4% of the cases. **Conclusion:** In the absence of flush ligation of the saphenopopliteal junction, modified high ligation and segmental stripping of small saphenous vein varicosities with preoperative duplex marking is an effective treatment method for reducing postoperative complications and the recurrence of SSV incompetence.

Key words: 1. High ligation
2. Stripping
3. Varicose veins
4. Saphenous vein

INTRODUCTION

Recently, the popularity of minimally invasive endoluminal treatments, such as endovenous laser ablation (EVLA) and radiofrequency ablation (RFA), for small saphenous vein (SSV) varicosities has increased due to their high success rates and cosmetic benefits. However, endoluminal treatments may require multiple concomitant phlebectomies, which can lead to poor cosmetic results in patients with extensive varicosities. Additionally, the catheter insertion and advancement involved in EVLA or RFA are very difficult in patients with a small-diameter SSV. EVLA and RFA may also be costly for the patient, since these procedures are not covered by the Korean

national health insurance program. Thus, patients may not enjoy the cosmetic benefits of EVLA and RFA despite their high cost. With this in mind, we attempted to develop a surgical treatment for small saphenous varicose veins that would result in less morbidity and a lower recurrence rate than conventional saphenopopliteal surgery.

Although saphenopopliteal junction (SPJ) ligation and stripping of the SSV have been the standard treatment for varicose veins associated with saphenopopliteal reflux [1], the clinical outcomes of this procedure are worse than those of great saphenous vein (GSV) surgery [2-5]. As a result, the surgical approach for SSV varicosities remains controversial and is technically challenging due to anatomical variation, high re-

Department of Thoracic and Cardiovascular Surgery, National Health Insurance Service Ilsan Hospital

Received: November 17, 2014, Revised: December 12, 2014, Accepted: December 12, 2014, Published online: December 5, 2015

Corresponding author: Ki Pyo Hong, Department of Thoracic and Cardiovascular Surgery, National Health Insurance Service Ilsan Hospital, 100 Ilsan-ro, Ilsandong-gu, Goyang 10444, Korea
(Tel) 82-31-900-0254 (Fax) 82-31-900-0343 (E-mail) kipyoh@yahoo.co.kr

© The Korean Society for Thoracic and Cardiovascular Surgery. 2015. All right reserved.

© This is an open access article distributed under the terms of the Creative Commons Attribution Non-Commercial License (<http://creativecommons.org/licenses/by-nc/4.0>) which permits unrestricted non-commercial use, distribution, and reproduction in any medium, provided the original work is properly cited.

currence rates, and high rates of complications involving nerve injuries [2-5]. The role of ligation of the SPJ via formal exposure and the optimal extent of SSV stripping have also been debated. In the current literature, SPJ ligation with extensive stripping of the SSV has been associated with an increased incidence of nerve injury [6], while SPJ ligation without stripping has been reported to increase the recurrence of varicose veins [7].

We describe a modified surgical technique for SSV varicosities that minimizes neurologic complications and recurrence. The aim of this study was to explore the clinical outcomes of our modified surgical technique, as reflected by improvement in reflux, the recurrence rate, the complication rate, and improvement in preoperative symptoms.

METHODS

This study was approved by the institutional review board of the National Health Insurance Service Ilsan Hospital (suyon-2014-055).

1) Patients

Between January 2010 and March 2013, a total of 651 patients underwent treatment for varicose veins at National Health Insurance Service Ilsan Hospital. Among them, 74 patients (111 legs) with SSV reflux in the absence of reflux elsewhere in the superficial veins of the ipsilateral leg underwent modified high ligation and segmental stripping of the SSV by a single surgeon. Follow-up data for 62 of these patients (83.7%) were available for analysis.

Each patient was clinically assessed and underwent venous duplex ultrasound scanning (DUS) using a LOGIQ5 PRO probe (5-12 MHz linear probe; GE HealthCare, Sungnam, Korea) by the operating surgeon in an outpatient setting to determine the sites of venous reflux. Clinical severity was objectively categorized according to the clinical, etiological, anatomic, and pathophysiological (CEAP) aspects of each case. DUS was performed with the patient in the standing position, and reflux was defined as reversed venous flow for greater than 0.5 seconds after a distal augmentation maneuver. All patients with isolated small saphenous varicose veins and DUS-proven reflux underwent modified high ligation and segmental

stripping with the avulsion of varicose tributaries. The exclusion criteria for this study were: (1) patients who had previously undergone surgical intervention (surgery, EVLA, or RFA) or sclerotherapy for varicose veins of the ipsilateral leg, and (2) GSV reflux and deep venous incompetence of the ipsilateral leg on DUS examination.

After the presence of SSV reflux was confirmed, the patients were scheduled for modified high ligation and segmental stripping of the SSV varicosities. All patients were treated in the hospital according to the established schedule of the Diagnosis-Related Group of the Korean National Health Insurance Service.

2) Procedure

Prior to the operation, the range of the visible tributary varicosities was meticulously outlined with the patient in the standing position. All operations were performed under spinal anesthesia with the patient in the prone position with a support pad under the ankle. The course of the SSV from the mid-calf to the point where the SSV bends anteriorly to join with the popliteal vein was marked under ultrasound guidance by the surgeon. All patients received routine intravenous antibiotics upon induction. Thromboprophylaxis was not administered in any cases. A transverse skin incision approximately 1 cm in length was made at the site that was preoperatively marked. The SSV was identified underneath the fascia, and exteriorized until 1-2 cm of the terminal portion was freed from its perivenous adhesions with a Varady retractor (AESCULAP, Tuttlingen, Germany). The vessel was then ligated at the highest point possible with #5 silk and divided. If a competent gastrocnemius vein terminated into the SSV, the SSV was ligated below this termination point to avoid the interruption of physiologic drainage. Non-absorbable suture material was placed around the distal SSV and pulled downward to control any bleeding. A pin stripper was inserted into the free end of the distal SSV in the popliteal space and pushed downward. Once the pin stripper was inside, the SSV and stripper were easily localized and grasped with mosquito forceps through a 5-mm longitudinal skin incision at the mid-calf. The pin stripper was then pulled upward by 2-3 cm to exteriorize the SSV, and the distal portion was clamped with mosquito forceps. The pin stripper

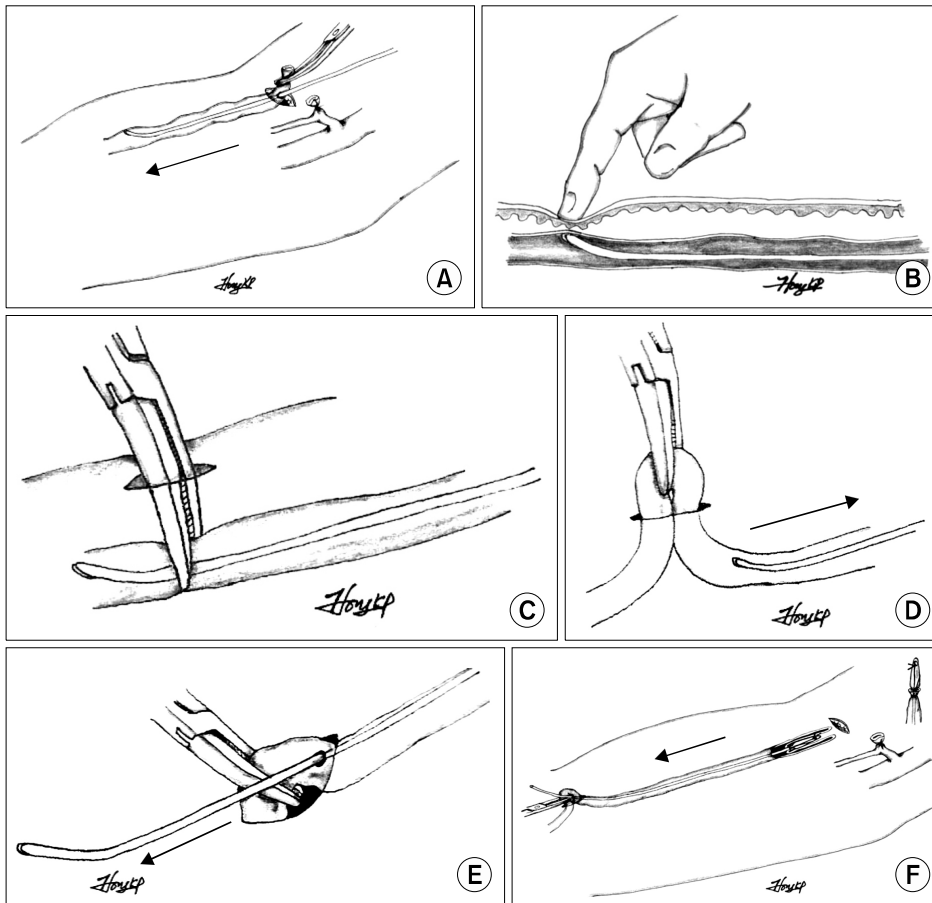


Fig. 1. Schematic illustration of the operative procedure. (A) Small saphenous vein was ligated with silk#5 below the termination of a competent gastrocnemius vein and divided. A pin stripper was inserted into the free end of the distal SSV and pushed downward. (B, C) The SSV and stripper were easily localized and grasped with mosquito forceps through a incision at the mid-calf. (D) The pin stripper was then pulled upward 2–3 cm to exteriorize the SSV and the distal portion was clamped with mosquito forceps. (E) The pin stripper was then pushed through the SSV. (F) The pin stripper was delivered along with the inverted vein through the incision at the mid-calf. SSV, small saphenous vein.

was then pushed through the SSV. The free end of the SSV at the popliteal space was secured to the head of the pin stripper with non-absorbable sutures. Prior to stripping, tumescent solution (1:100,000 epinephrine in a 500 mL of 0.9% normal saline) was instilled along the SSV under high pressure using a Trivex illuminator (Smith & Nephew, Oklahoma City, OK, USA) to facilitate stripping and prevent hematoma formation. After instillation of this solution, the pin stripper was delivered along with the inverted vein through the incision at the mid-calf (Fig. 1). In all patients, 10 cm of the proximal SSV was stripped. Avulsions of varicose tributaries of the SSV were performed using a Varady retractor (AESCULAP) through multiple 2–3 mm incisions and were closed with 3M Steri-strips (3M Healthcare, St. Paul, MN, USA). The two incisions made for stripping the SSV segment were closed with Vicryl #5-0 sutures (Johnson & Johnson, New Brunswick, NJ, USA) and 3M Steri-strips (3M Healthcare). Compression dressings composed of cotton gauze and adhe-

sive elastic bandages were applied to all wounds. The day after surgery, this dressing was changed to a class I (20–30 mmHg) knee-length graduated support stocking that was worn for approximately 10 days. All of the patients were discharged the day after surgery with a seven-day prescription for non-steroidal anti-inflammatory medication.

Clinical examination and duplex imaging were performed as part of each patient's postoperative follow-up evaluation. The recurrence of varicose veins was defined as the appearance of new varicose veins following surgical treatment. The following DUS criteria were used for defining successful treatment: (1) no reflux at the remaining distal SSV and (2) no neovascularization at the SPJ. Neovascularization was defined as connections between the SPJ and SSV consisting of numerous small, thin-walled serpentine venous tributaries (less than 5 mm in diameter).

Table 1. Preoperative symptoms

Symptoms	No. of patients (%)
Numbness	33 (47.8)
Pain	27 (39.1)
Heaviness	26 (37.7)
Swelling	12 (21.7)
Itching	4 (7.2)

RESULTS

A total of 69 legs (62 patients) were included in this study. The patients included 24 men and 38 women, with a median age of 53 years (range, 23 to 77 years). All patients had uncomplicated varicose veins (CEAP clinical class 2). In terms of etiology and pathophysiologic conditions, all patients had primary varicose veins and all showed evidence of reflux in the absence of obstruction. Preoperative subjective symptoms were present in 56 legs (81.2%), as shown in Table 1. As measured during the preoperative DUS evaluation, the mean diameter of the SSV was 5.0 mm (range, 1.1 to 10.6 mm) and the mean duration of reflux was 2.29 seconds (range, 0.58 to 4.0 seconds). Postoperative complications included paresthesia in five cases (7.2%), which completely resolved without further intervention. No other significant complications, such as deep vein thrombosis, phlebitis, hematoma, or popliteal vein injury, occurred.

The median follow-up period was 35 months (range, 19 to 58 months). No recurrence of varicose veins following surgical treatment was noted. The preoperative symptoms improved in 54 legs (96.4%).

On DUS imaging, three legs (4.3%) exhibited reflux at the remaining distal SSV. One of these patients showed neovascularization at the proximal stump. Two of the three patients (2.9% of all patients) who exhibited reflux at the distal remaining SSV complained of persistent preoperative symptoms such as heaviness, numbness, and swelling, and were treated with ultrasound-guided foam sclerotherapy. One patient with reflux at the distal remaining SSV had no symptoms and refused further treatment.

DISCUSSION

The popliteal fossa has been considered a dangerous area for open dissection due to the risk of injury to the popliteal vein and tibial nerve. The SPJ is located deep, and failure to identify this structure, necessitating extensive dissection, can increase the incidence of major neurovascular injuries. As ligation of the SPJ plays a key role in preventing recurrence in surgery performed for SSV varicosities, failures in the localization and flush ligation of the SPJ are considered to be a chief cause of recurrence of varicose veins [1,4,8-10]. Tong and Royle [4] previously reported that recurrence was attributed to an intact incompetent SPJ in 28% of 70 cases of recurrent varicose veins following SSV surgery. However, other studies have shown that flush ligation of the SPJ by formal exploration of the popliteal fossa did not appear to affect outcomes [7] and was associated with major complications [11,12]. Rashid et al. [12] reported a low technical success rate (59%) after formal SPJ dissection, with three major complications occurring, including DVT and tearing of the popliteal vein. O'Hare et al. [7] found that the type of procedure performed in the popliteal fossa had no effect on the postoperative rate of SSV incompetence. Therefore, contrary to previous beliefs, flush ligation of the SPJ does not seem to be the optimal procedure for the treatment of SSV varicosities, and other surgical approaches to SSV varicosities are therefore needed.

In this study, modified high ligation of the SSV was performed instead of flush ligation of the SPJ. Modified high ligation of the SSV means that ligation of the SSV is performed approximately 2 cm from the SPJ. Typically, the SSV deepens its course as it approaches its union with the popliteal vein. This often appears as a 45-degree bend approximately 2 cm in length. This bend of the SSV at the popliteal fossa was marked under ultrasound guidance prior to surgery. In this study, the 2-cm angled segment was left untreated for two reasons: (1) preservation of the gastrocnemius veins that enter into this segment, and (2) because the tibial nerve enters into close proximity with the SSV at this deeper level. In the literature, clinical recurrence of SSV varicose veins after surgical treatment has been reported to range from 8.6% to 30% [7,11,13,14]. The most common cause of recurrence after surgical treatment of the SSV is neovascularization

[15,16]. A prospective long-term clinical study of 127 legs showed that neovascularization was observed in more than half of the legs that exhibited clinical recurrence [15]. Neovascularization accounts for 85% of cases of recurrence at the SFJ and 62% of cases of recurrence at the SPJ. In this study, no recurrent varicose veins were observed in any of the patients, and neovascularization at the proximal stump was observed in only one leg (1.4%). The low rate of neovascularization in this study might have been due to preservation of physiologic drainage to the popliteal vein.

Although the benefits of GSV stripping have been demonstrated [17], the effect of stripping the SSV remains controversial. A prospective study of 234 legs showed that rates of postoperative numbness were similar whether or not stripping was performed, and that extending SSV stripping to the lower calf significantly reduced the rate of SPJ incompetence on duplex imaging after one year [7]. However, the rates of neurologic complications after extended stripping of the SSV ranged from 14.8% to 27.0% [7,11,18], which is much higher than the range of 4.2% to 7.5% observed in cases where EVLA was performed [13,18]. In this study, stripping was extended to the mid-calf to prevent sural nerve injury. Short-segment stripping (about 10 cm) of the SSV leaves the distal SSV, which otherwise might cause incompetence in the distal calf. Although extending the stripping to the low calf might reduce the rate of incompetence in the distal calf, it may also increase the likelihood of damage to the sural nerve. It is not known whether the remaining incompetent distal SSV increases the risk of recurrent varicose veins in the future. In this study, three legs (4.3%) showed incompetence in the distal SSV, although no evidence of recurrent varicose veins was found. Incompetence in the distal calf was treated by ultrasound-guided foam sclerotherapy in the two symptomatic cases.

Neurologic complications only occurred in five patients (5/69, 7.5%), each of whom experienced paresthesia, which can develop due to multiple phlebectomies or stripping. These symptoms improved in all five patients without further intervention. The rate of neurologic complications in this study was significantly lower than that of previous studies that have utilized surgical treatment [7,11,18], and is comparable to the results seen with the use of EVLA [13,18]. This may have been due to minimal dissection resulting from the precise lo-

calization of the SSV, as well as short segment stripping to the mid-calf.

In conclusion, without flush ligation of the SPJ, modified high ligation and segment stripping of the SSV with preoperative duplex marking is a safe and effective treatment for SSV varicosities and reduces postoperative complications and recurrent SSV incompetence. Although a relatively small number of cases were included in this study, the results are promising. Further evaluation of this technique in the form of a randomized controlled trial is needed.

CONFLICT OF INTEREST

No potential conflict of interest relevant to this article was reported.

ACKNOWLEDGMENTS

This study was supported by a Grant of the Samsung Vein Clinic Network (Daejeon, Anyang, Cheongju, Cheonan; Fund No. KTCS04-038). And this work was supported by National Health Insurance Service Ilsan Hospital Research Grant, 2013.

REFERENCES

1. Winterborn RJ, Campbell WB, Heather BP, Earnshaw JJ. *The management of short saphenous varicose veins: a survey of the members of the vascular surgical society of Great Britain and Ireland.* Eur J Vasc Endovasc Surg 2004;28:400-3.
2. McMullin GM, Coleridge Smith PD, Scurr JH. *Objective assessment of high ligation without stripping the long saphenous vein.* Br J Surg 1991;78:1139-42.
3. Sarin S, Scurr JH, Coleridge Smith PD. *Assessment of stripping the long saphenous vein in the treatment of primary varicose veins.* Br J Surg 1992;79:889-93.
4. Tong Y, Royle J. *Recurrent varicose veins after short saphenous vein surgery: a duplex ultrasound study.* Cardiovasc Surg 1996;4:364-7.
5. Critchley G, Handa A, Maw A, Harvey A, Harvey MR, Corbett CR. *Complications of varicose vein surgery.* Ann R Coll Surg Engl 1997;79:105-10.
6. O'Donnell TF Jr, Iafrati MD. *The small saphenous vein and other 'neglected' veins of the popliteal fossa: a review.* Phlebology 2007;22:148-55.
7. O'Hare JL, Vandenbroeck CP, Whitman B, et al. *A prospective evaluation of the outcome after small saphenous vari-*

- cose vein surgery with one-year follow-up. *J Vasc Surg* 2008; 48:669-73.
8. Doran FS, Barkat S. *The management of recurrent varicose veins*. *Ann R Coll Surg Engl* 1981;63:432-6.
 9. Mitchell DC, Darke SG. *The assessment of primary varicose veins by Doppler ultrasound: the role of sapheno-popliteal incompetence and the short saphenous systems in calf varicosities*. *Eur J Vasc Surg* 1987;1:113-5.
 10. Perrin MR, Guex JJ, Ruckley CV, et al. *Recurrent varices after surgery (REVAS), a consensus document. REVAS group*. *Cardiovasc Surg* 2000;8:233-45.
 11. Samuel N, Carradice D, Wallace T, Smith GE, Mazari FA, Chetter I. *Saphenopopliteal ligation and stripping of small saphenous vein: does extended stripping provide better results?* *Phlebology* 2012;27:390-7.
 12. Rashid HI, Ajeel A, Tyrrell MR. *Persistent popliteal fossa reflux following saphenopopliteal disconnection*. *Br J Surg* 2002; 89:748-51.
 13. Samuel N, Carradice D, Wallace T, Mekako A, Hatfield J, Chetter I. *Randomized clinical trial of endovenous laser ablation versus conventional surgery for small saphenous varicose veins*. *Ann Surg* 2013;257:419-26.
 14. Vin F, Chleir F. *Ultrasonography of postoperatively recurrent varicose veins in the area of the short saphenous vein*. *Ann Chir* 2001;126:320-4.
 15. Van Rij AM, Jiang P, Solomon C, Christie RA, Hill GB. *Recurrence after varicose vein surgery: a prospective long-term clinical study with duplex ultrasound scanning and air plethysmography*. *J Vasc Surg* 2003;38:935-43.
 16. Allegra C, Antignani PL, Carlizza A. *Recurrent varicose veins following surgical treatment: our experience with five years follow-up*. *Eur J Vasc Endovasc Surg* 2007;33:751-6.
 17. Dwerryhouse S, Davies B, Harradine K, Earnshaw JJ. *Stripping the long saphenous vein reduces the rate of reoperation for recurrent varicose veins: five-year results of a randomized trial*. *J Vasc Surg* 1999;29:589-92.
 18. Park SW, Hwang JJ, Yun IJ, et al. *Endovenous laser ablation of the incompetent small saphenous vein with a 980-nm diode laser: our experience with 3 years follow-up*. *Eur J Vasc Endovasc Surg* 2008;36:738-42.