

This article is licensed under the Creative Commons Attribution-NonCommercial 4.0 International License (CC BY-NC) (<http://www.karger.com/Services/OpenAccessLicense>). Usage and distribution for commercial purposes requires written permission.

Single Case

Neurofibroma of the Colon: A Diagnostic Mimicker of Gastrointestinal Stromal Tumor

Soomin Ahn^a Choon Sik Chung^b Kyoung-Mee Kim^c

^aDepartment of Pathology, Ewha Womans University School of Medicine, Seoul, South Korea; ^bDivision of Colorectal Surgery, Hansol Hospital, Seoul, South Korea;

^cDepartment of Pathology and Translational Genomics, Samsung Medical Center, Sungkyunkwan University School of Medicine, Seoul, South Korea

Keywords

Neurofibroma · CD34 · Gastrointestinal stromal tumor · Differential diagnosis

Abstract

Gastrointestinal neurofibroma usually develops as diffuse gastrointestinal involvement in neurofibromatosis type 1 patients. Only 4 cases of sporadic colonic neurofibroma in a patient without neurofibromatosis type 1 have been reported in the English literature. A 26-year-old female patient underwent colonoscopy, and a 4-cm-sized polypoid mass was identified in the sigmoid colon. Wedge resection of the mass showed a yellowish, hard submucosal tumor. Microscopically, the tumor was composed of wavy spindle cells, fibroblasts, and strands of collagen; the stroma showed scattered myxoid areas. The differential diagnoses included gastrointestinal stromal tumor, schwannoma, and neurofibroma. Immunohistochemistry for c-Kit, DOG (discovered on gastrointestinal stromal tumors)-1, smooth muscle actin, S-100 protein, and CD34 was performed. The tumor cells were diffusely positive for CD34 and S-100 protein, while they were completely negative for c-Kit, DOG-1, and smooth muscle actin. The final diagnosis was neurofibroma. Sporadic colonic neurofibroma is very rare. Given the diffuse positivity for CD34 and its rarity, colonic neurofibroma can be easily misdiagnosed as gastrointestinal stromal tumor. Recognition of this entity would be beneficial for pathologists to avoid misdiagnosis and unnecessary treatment.

© 2016 The Author(s)
Published by S. Karger AG, Basel

Introduction

Neurofibroma is a benign nerve sheath tumor of the peripheral nervous system, consisting of a mixture of cell types including Schwann cells, perineural-like cells, and fibroblasts. It is classically associated with neurofibromatosis type 1 (NF1; von Recklinghausen disease). NF1 is a common neurocutaneous disorder occurring in 1 of 3,000 births, and is caused by a mutation in chromosome 17q11.2 affecting neurofibromin of the RAS GTPase activating protein family, a tumor suppressor gene [1]. Schwann cells were discovered to be the cells of origin for neurofibromas, but understanding the more complicated interplay of multiple cell types in tumorigenesis – specifically of recruited heterogeneous cell types such as mast cells and fibroblasts – has important implications for surgical therapy of these tumors [2]. Two of the following diagnostic criteria should be fulfilled to make a diagnosis of NF1: ≥ 6 café au lait macules; ≥ 2 neurofibromas of any type or 1 plexiform neurofibroma; freckling in the axillary or inguinal region; optic glioma; ≥ 2 iris hamartomas (Lisch nodules); bony lesions (pseudoarthrosis); or a 1st-degree relative with NF1 [3, 4]. It is an autosomal dominant disorder; however, sporadic inheritance has been noted as well. Gastrointestinal neurofibroma usually develops as diffuse gastrointestinal involvement in NF1 patients. Gastrointestinal involvement has been documented in 25% of patients with NF1, and most of the neurofibromas are located in the stomach and small intestine [1, 5].

Sporadic neurofibroma is a tumor of the periphery of the peripheral nervous system and occurs most commonly in the extremities. Most of the localized, isolated neurofibromas occur sporadically, and approximately 10% of cases occur in the setting of NF1 [6]. They are relatively common – particularly at superficial cutaneous sites, where they present as localized, pedunculated growths [7]. In the colon, only 4 cases of sporadic neurofibroma have been reported in the English literature in a patient without NF1 [1, 3, 8, 9].

We report a case of sporadic neurofibroma positive for CD34, one of the diagnostic markers of gastrointestinal stromal tumor (GIST). This rare case reminds us that CD34 is also positive in mesenchymal tumors other than GIST.

Case Report

A 26-year-old female patient underwent colonoscopy for a routine health checkup. She denied any past medical history or family history. She did not have any significant history or symptom of abdominal pain, diarrhea, constipation, melena, or hematochezia. Laboratory test results were within normal limits. In colonoscopy, a 4-cm-sized polypoid mass was identified in the sigmoid colon (Fig. 1a). The endoscopic impression was that of a submucosal tumor with an intact mucosa of the lesion. There was no additional abnormal endoscopic finding for the rest of the colorectum. Subsequently, wedge resection of the mass was performed. Under gross examination, the cut surface of the mass was yellowish-white and hard (Fig. 1b). The tumor had its epicenter in the submucosa (Fig. 2a) and was composed of wavy spindle cells, fibroblasts, and strands of collagen (Fig. 2b). The stroma showed scattered myxoid areas. Based on these pathologic findings, the differential diagnoses included GIST, schwannoma, and neurofibroma. Immunohistochemistry for c-Kit, DOG (discovered on GIST)-1, smooth muscle actin, S-100 protein, and CD34 was performed. The tumor cells were diffusely positive for CD34 (Fig. 2c) and S-100 protein (Fig. 2d), but totally negative for c-Kit, DOG-1, and smooth muscle actin. Therefore, the final diagnosis of the tumor was neurofibroma. The physician performed a thorough physical examination of the patient, with in-

quiries about her family history, after the pathologic diagnosis of colonic neurofibroma. She had no café au lait spots, axillary freckling, other cutaneous lesion, or pigmented hamartoma of the iris. In addition, there was no family history suggesting NF1. Based on these observations, our case can be categorized as an isolated neurofibroma outside the setting of NF1.

Discussion

Neurofibroma of the digestive system is usually identified as part of NF1. Gastrointestinal involvement has been documented in 25% of patients with NF1, and most of the neurofibromas involve the stomach and small intestine, presenting as ganglioneuromas or neurofibromas [3]. Here we report a rare CD34-positive sporadic colonic neurofibroma, which may be misdiagnosed as GIST.

A pathologic diagnosis of neurofibroma presenting as a solitary colonic mass could be difficult, because of its rarity and features overlapping with those of other spindle cell neoplasms. However, an accurate diagnosis is clinically important, since it would be an initial manifestation of NF1 in patients without any other clinical manifestations of the disease [3]. In that case, a small but non-negligible potential for malignant transformation exists. Thus, an accurate diagnosis can lead to a proper clinical evaluation and management of patients with NF1.

Intestinal neurofibroma usually presents as colonic involvement in patients with NF1. As sporadic neurofibroma in the colon is extremely rare, it is important to exclude the possibility of a colonic manifestation of NF1. In this case, there was no physical sign or family history suggesting NF1. Based on these observations, our case can be categorized as an isolated neurofibroma outside the setting of NF1.

In the pathologic diagnosis of this rare tumor, immunohistochemistry is helpful in differentiating neurofibroma from the most common mesenchymal neoplasm (i.e., GIST) based on their morphologic similarity. In GIST, CD34 is expressed in 83% of cases [10]. According to a recent study conducted by Park et al. [11], CD34 is positive in 42.5% of schwannomas and 80.2% of neurofibromas. Although CD34 is also expressed in schwannoma and neurofibroma, pathologic diagnoses of the less frequent schwannoma or neurofibroma can be missed and, instead, can be misdiagnosed as GIST. In this context, our case reminds us that CD34 is also positive in mesenchymal tumors other than GIST – and, although rare, the possibility of neurofibroma should be included in any differential diagnoses. In conclusion, we report a rare case of isolated CD34-positive neurofibroma without a history of NF1.

Acknowledgement

This study was supported by a grant from the 20 by 20 Project of Samsung Medical Center (GF01140111).

Statement of Ethics

Written informed consent was obtained from the patient for the publication of this report and of the accompanying images.

Disclosure Statement

The authors declare that they have no competing interests.

References

- 1 Wiesen A, Davidoff S, Sideridis K, Greenberg R, Bank S, Falkowski O: Neurofibroma in the colon. *J Clin Gastroenterol* 2006;40:85–86.
- 2 Gottfried ON, Viskochil DH, Fults DW, Couldwell WT: Molecular, genetic, and cellular pathogenesis of neurofibromas and surgical implications. *Neurosurgery* 2006;58:1–16; discussion 1–16.
- 3 Hindy P, Parvin R, Hanna K, Andrawes S, Gress F, Goodman A: An isolated neurofibromal polyp of the colon. *Case Rep Gastroenterol* 2012;6:58–62.
- 4 Neurofibromatosis. Conference statement. National Institutes of Health Consensus Development Conference. *Arch Neurol* 1988;45:575–578.
- 5 Kim HR, Kim YJ: Neurofibromatosis of the colon and rectum combined with other manifestations of von Recklinghausen's disease: report of a case. *Dis Colon Rectum* 1998;41:1187–1192.
- 6 Beert E, Brems H, Renard M, Ferreira JF, Melotte C, Thoelen R, De Wever I, Sciot R, Legius E, Debicq-Rychter M: Biallelic inactivation of NF1 in a sporadic plexiform neurofibroma. *Genes Chromosomes Cancer* 2012;51:852–857.
- 7 Rodriguez FJ, Folpe AL, Giannini C, Perry A: Pathology of peripheral nerve sheath tumors: diagnostic overview and update on selected diagnostic problems. *Acta Neuropathol* 2012;123:295–319.
- 8 Panteris V, Vassilakaki T, Vaitsis N, Elemenoglou I, Mylonakou I, Karamanolis DG: Solitary colonic neurofibroma in a patient with transient segmental colitis: case report. *World J Gastroenterol* 2005;11:5573–5576.
- 9 Abramson LP, Orkin BA, Schwartz AM: Isolated colonic neurofibroma manifested by massive lower gastrointestinal bleeding and intussusception. *South Med J* 1997;90:952–954.
- 10 van de Rijn M, Hendrickson MR, Rouse RV: CD34 expression by gastrointestinal tract stromal tumors. *Hum Pathol* 1994;25:766–771.
- 11 Park JY, Park H, Park NJ, Park JS, Sung HJ, Lee SS: Use of calretinin, CD56, and CD34 for differential diagnosis of schwannoma and neurofibroma. *Korean J Pathol* 2011;45:30–35.

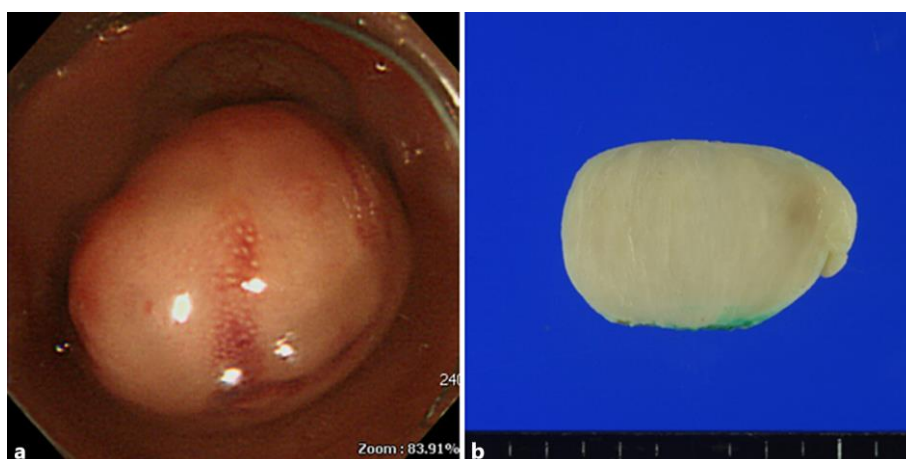


Fig. 1. **a** A 4-cm-sized polypoid mass was identified in the sigmoid colon during colonoscopy. **b** The cut section of the mass was yellowish-white and somewhat fibrotic.

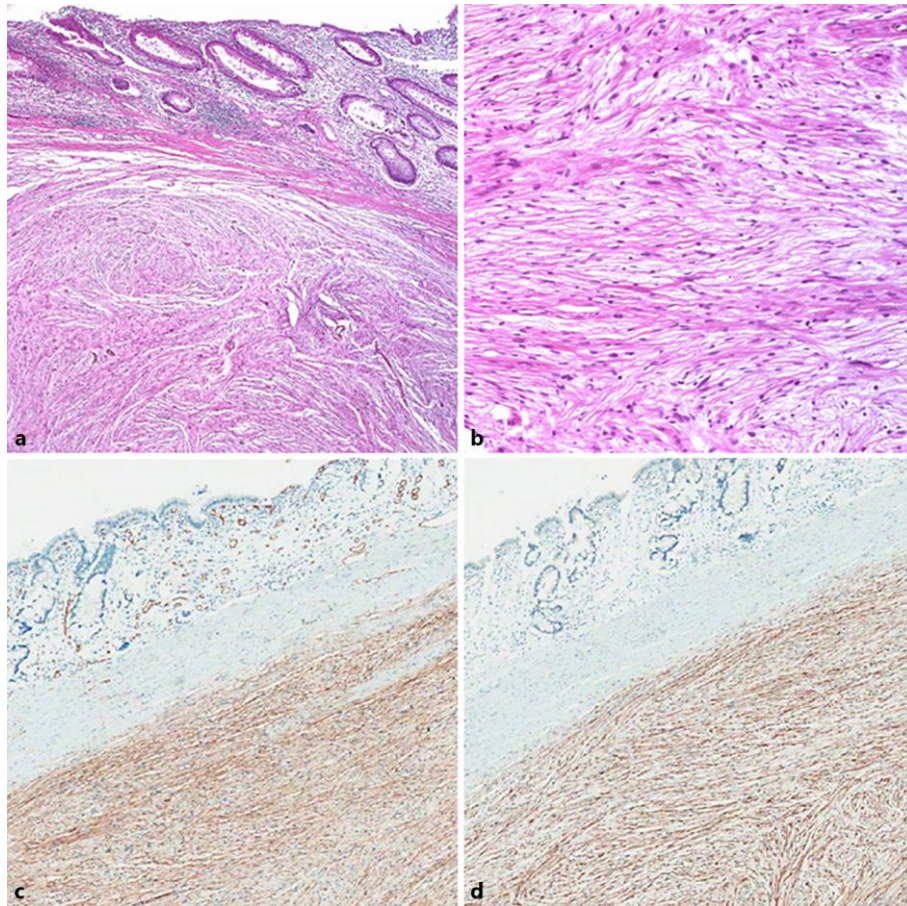


Fig. 2. The tumor had its epicenter in the submucosa (**a**, HE, $\times 40$) and was composed mainly of wavy spindle cells (**b**, HE, $\times 100$). On immunohistochemistry, the tumor cells were positive for CD34 (**c**, $\times 40$; please see the internal positive staining in the capillaries located in the mucosa and the internal negative staining in the smooth muscle fibers of the muscularis mucosa) and S-100 protein (**d**, $\times 40$; please see the internal negative staining in the muscularis mucosa).