

# Acute Gastrointestinal Hemorrhage due to Epstein-Barr Virus Colitis

Richard P. Denicola, MD<sup>1</sup>, Robert Coben, MD<sup>1</sup>, Leo Katz, MD<sup>1</sup>, and Peter A. McCue, MD<sup>2</sup>

<sup>1</sup>Department of Gastroenterology and Hepatology, Thomas Jefferson University Hospital, Philadelphia, PA

<sup>2</sup>Department of Pathology, Thomas Jefferson University Hospital, Philadelphia, PA

## ABSTRACT

Epstein-Barr virus (EBV) is a member of the herpesvirus family that is associated with various disease manifestations, including EBV-associated colitis. There are few case reports describing hemorrhage associated with EBV colitis. We report a 61-year-old woman with acute gastrointestinal bleeding due to EBV colitis after initiation of methylprednisolone and enoxaparin for spinal cord infarction. To our knowledge, there are only a few case reports of hemorrhagic EBV colitis. Perhaps we need to have a higher suspicion for EBV in cases of colitis associated with hemorrhage even in relatively immunocompetent patients.

## INTRODUCTION

Epstein-Barr virus (EBV) is a member of the herpesvirus family that is associated with various disease manifestations such as infectious mononucleosis, chronic active EBV infection, x-linked lymphoproliferative disease, nasopharyngeal carcinoma, Burkitt's lymphoma, Hodgkin's disease, and acquired immunodeficiency syndrome or posttransplantation-associated lymphoproliferative disease.<sup>1,2</sup> The virus spreads through oral secretions where it replicates and sheds, leading to a primary infection that is controlled by the host's natural killer cells and CD4+ and CD8+ cytotoxic T-cells.<sup>1</sup> The initial infection is largely asymptomatic or nonspecific with sore throat and malaise. However, patients may have typical infectious mononucleosis symptoms, including pharyngitis, fever, and lymphadenopathy.<sup>3</sup> HLA-restricted cytotoxic T-cells and CD8+ T-cells are important in controlling EBV in the latency phase in which case the virus infects the host's B cells.<sup>1</sup> Disruption to these host immune responses can lead to reactivation. The physiologic stimuli that trigger this reactivation are not well described in humans although humanized mice models have been developed to better model EBV disease in vivo.<sup>2,4</sup> This reactivation can manifest as infectious mononucleosis or as other rarer complications including, but not limited to, hematologic derangements (hemolytic anemia, thrombocytopenia, aplastic anemia, etc.), neurologic complications (Guillain-Barré syndrome, facial nerve palsy, aseptic meningitis, transverse myelitis, etc.), splenic rupture, and upper airway obstruction.<sup>3,5</sup> However, only a few case reports have described hemorrhagic EBV colitis.

## CASE REPORT

A 61-year-old woman with a history of tobacco abuse, cervical cancer, diabetes mellitus, obstructive sleep apnea, hyperlipidemia, and a new diagnosis of spinal cord infarction complicated by paraparesis and dysesthesias presented to a university medical center with painless, bright red blood per rectum. The patient had recently been treated for spinal cord infarction with 5 days of methylprednisolone at a dose of 1,000 mg intravenous daily, followed by a 5-day prednisone taper starting at 40 mg daily and therapeutic enoxaparin. Her symptoms rapidly improved from paraparesis to ambulating in a matter of days. She was discharged to a short-term rehabilitation center. While at the rehabilitation center, the patient developed a significant gastrointestinal hemorrhage with hemodynamic instability and a decrease in serum hemoglobin levels from 12 to 7 g/dL upon admission to a community hospital. She was noted to have maroon-colored stools and required 2 units of packed red blood cells. She underwent upper endoscopy revealing a normal esophagus, stomach, and duodenum. Colonoscopy revealed nonbleeding diverticula and normal mucosa. The patient experienced no further bleeding and was transferred back to the university medical center for workup of worsening lower extremity weakness that developed after the gastrointestinal hemorrhage.

One week into her hospitalization, she began to have maroon-colored stools with a hemoglobin trend from 9.0 to 7.0 g/dL, but not requiring red blood cell transfusion. She had no abdominal pain at this time. As part of her neurologic workup, she underwent a computed tomography angiogram study of the chest, abdomen, and pelvis, which demonstrated air-fluid levels on the left side of the colon, but normal abdominopelvic vasculature. She underwent repeat colonoscopy revealing multiple areas of patchy discontinuous ulceration with friability and bleeding on contact throughout the whole colon (Figure 1). These findings were compatible with colitis and appeared to be ischemic. Cold forceps biopsies were performed for histology. In situ hybridization stain demonstrated the presence of intracellular EBV consistent with EBV-associated colitis (Figure 2). This diagnosis was confirmed by a second pathologist. Infectious disease was consulted, and therapeutic intravenous ganciclovir was started. Neurology and infectious disease consults recommended outpatient repeat MRI of the spine to evaluate for EBV myelitis as a cause of spinal cord findings. The patient was transitioned to oral valganciclovir and discharged to a short-term rehabilitation center.

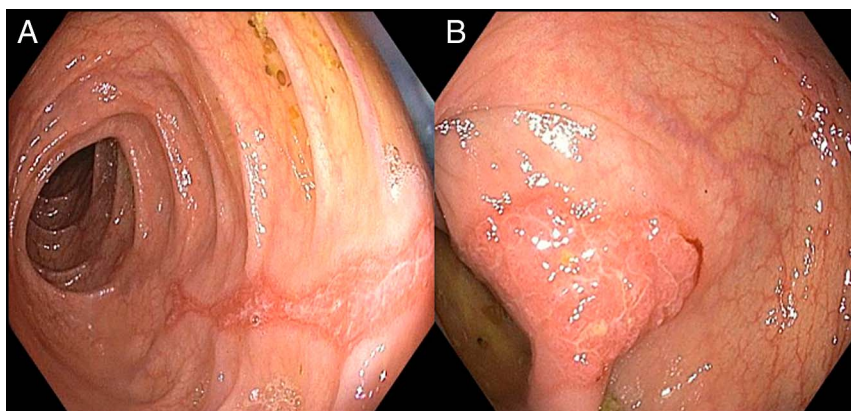
## DISCUSSION

We describe a case of hemorrhagic EBV colitis in a presumed immunocompetent patient that strongly mimicked ischemic colitis by history and colonoscopy. It is conceivable that this presentation was multifactorial, including elements of both EBV and ischemic colitis. The patient's diabetes and recent presumed spinal cord infarction suggestive of the hypercoagulable state are risk factors for intestinal ischemia. Her previous colonoscopy could have been a risk factor for intestinal ischemia. However, her symptoms preceded the initial colonoscopy at the community hospital. It was our clinical impression that ischemic colitis was not the driving factor, given the prolonged course with the absence of abdominal symptoms, lack of documented hypotension with normal abdominopelvic vasculature on imaging, and

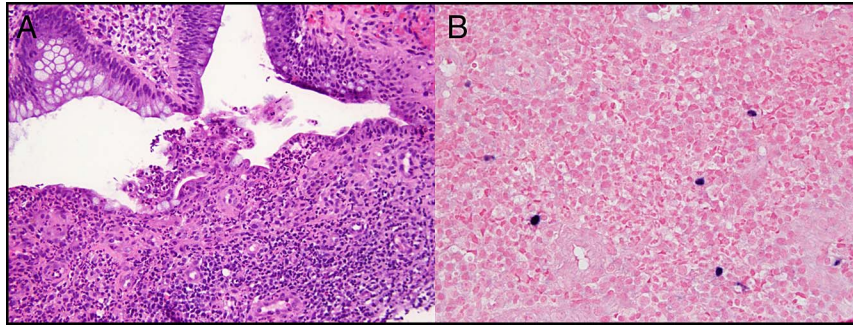
absence of clear ischemic colitis on histology. Because of the undetectable serum EBV DNA polymerase chain reaction at the time of diagnosis, the infectious disease consultant felt that it was likely reactivation rather than primary infection. Other than the short course of methylprednisolone, the patient had not received any other immunocompromising medications.

To our knowledge, there are only a few case reports of hemorrhagic EBV colitis; however, these cases are associated with much higher levels of immunosuppression. Matsumoto et al reported a case of a 56-year-old man who experienced hemorrhage colitis from reactivation of EBV and cytomegalovirus (CMV) while undergoing antithymocyte globulin and cyclosporine therapy for severe aplastic anemia.<sup>6</sup> The initial colonoscopy demonstrated severe colitis, but on biopsy, only nonspecific inflammation was seen on histology. A second colonoscopy on the same patient demonstrated the positive immunohistochemical presence of both EBV and CMV as well as positive serum CMV antigen and EBV DNA. After completion of the immunosuppressive therapy and treatment of CMV/EBV, there was resolution of the bloody diarrhea. Interestingly, after an increase in cyclosporine dose 6 months later, the same patient had recurrence of severe bloody diarrhea and positive EBV on biopsy and in the serum.<sup>6</sup>

Rarely, we may see superimposed EBV infection in our inflammatory bowel disease-afflicted patients such as was seen in Afzal's 21-year-old patient with ulcerative colitis who presented with mixed bloody diarrhea and colonoscopy images and histology consistent with ulcerative colitis that failed to improve with standard medical therapy. The diagnosis of EBV was made only after revisiting the pathology slides and testing for EBV DNA after inflammatory bowel disease treatment failure. The patient was then treated with ganciclovir with a significant improvement in symptoms.<sup>7</sup> These 2 case reports describe immunocompromised patients in whom a high suspicion of EBV was required to make the diagnosis. Despite the short course of steroids in our patient, there were no other



**Figure 1.** Colonoscopy showing (A) a linear streak of erythema and friable mucosa in the distal transverse colon and (B) an area of erythema and friability with contact oozing of blood in the proximal descending colon.



**Figure 2.** Hematoxylin and eosin stain showing (A) acute colitis (20 $\times$ ) and (B) the presence of intracellular Epstein-Barr virus (40 $\times$ ).

obvious immunosuppressive factors involved. Moreover, the pattern of injury in our patient closely mimicked ischemic colitis which seemed unlikely to be the driving factor in her clinical course. Perhaps, we need to have a higher suspicion for EBV in cases of colitis even in immunocompetent patients.

## DISCLOSURES

Author contributions: RP Denicola wrote the manuscript. R. Cohen revised the manuscript, approved the final version, and is the article guarantor. L. Katz and PA McCue analyzed and interpreted the data.

Financial disclosure: None to report.

Informed consent was obtained for this case report.

Received June 13, 2019; Accepted August 28, 2019

## REFERENCES

1. Cohen JI. Epstein-Barr virus infection. *N Engl J Med.* 2000;343(7):481-92.
2. Murata T. Regulation of Epstein-Barr virus reactivation from latency. *Microbiol Immunol.* 2014;58(6):307-17.
3. Luzuriaga K, Sullivan JL. Infectious mononucleosis. *N Engl J Med.* 2010;362:1993-2000.
4. Stanfield BA, Luftig MA. Recent advances in understanding Epstein-Barr virus. *F1000Res.* 2017;6:386.
5. Eligio P, Delia R, Valeria G. EBV chronic infections. *Mediterr J Hematol Infect Dis.* 2010;2(1):e2010022.
6. Matsumoto H, Kimura Y, Murao T, et al. Severe colitis associated with both Epstein-Barr virus and cytomegalovirus reactivation in a patient with severe aplastic anemia. *Case Rep Gastroenterol.* 2014;8:240-4.
7. Afzal M, Nigam GB. EBV colitis with ulcerative colitis: A double whammy. *BMJ Case Rep.* 2018;2018:bcr-2018.

**Copyright:** © 2019 The Author(s). Published by Wolters Kluwer Health, Inc. on behalf of The American College of Gastroenterology. This is an open-access article distributed under the terms of the Creative Commons Attribution-Non Commercial-No Derivatives License 4.0 (CCBY-NC-ND), where it is permissible to download and share the work provided it is properly cited. The work cannot be changed in any way or used commercially without permission from the journal.