




Investigating the Effects of Hydro-alcoholic *Urtica Dioica* Extract and Retinoic Acid on Follicular Development: An Animal Study

Saade Abdalkareem Jasim¹, Sana Abdul-Jabbar Ali², Osama Q. Fadhil^{2*}, Muqaddas Kh. Rakhmatova³, Hamzah H. Kzar⁴, Ria Margiana^{5,6,7}, Moaed E. Al-Gazally⁸, Abduladheem Turki Jalil⁹, Zaid Hameed Mahmood¹⁰, Surendar Aravindhan¹¹, Yasser Fakri Mustafa¹², Mohammed Q. Sultan¹³

Received: 7 Sep 2022

Published: 1 Feb 2023

Abstract

Background: *Urtica dioica* (UD), as a natural antioxidant, has positive effects on oocyte maturation. This study aimed to investigate the effects of hydro-alcoholic UD extract and retinoic acid on follicular development in an in vitro fertilization (IVF) condition.

Methods: A total of 40 female Wistar rats were randomly divided into 5 groups: group 1 received normal saline, group 2 was given 25 mg/kg retinoic acid, group 3 was administered with 100 mg/kg UD extract, group 4 was treated with retinoic acid plus UD extract, and group 5 received 10 mg/kg olive oil. The histomorphometric parameters were analyzed, including the number of follicles, follicular atrophy, fertilized oocytes, 2-cell embryos, dead embryos, and blastocysts.

Results: Retinoic acid caused a significant increase in the primary, preantral, and atretic follicles and a substantial decrease in the corpus luteum compared with the control group ($p < 0.001$). The number of preantral, antral follicles, and corpus luteum was significantly higher in group 3 compared with group 1 ($p < 0.001$). Moreover, coadministration of UD plus retinoic acid (group 4) significantly reduced the atretic follicles ($p < 0.05$).

Conclusion: Based on the results, UD herbal extract, as a natural antioxidant agent, could reduce the adverse effects of retinoic acid on oocyte maturation in an IVF condition.

Keywords: Histology, *Urtica Dioica*, Retinoic Acid, Fertilization, Phytomedicine

Conflicts of Interest: None declared

Funding: None

*This work has been published under CC BY-NC-SA 1.0 license.

Copyright © Iran University of Medical Sciences

Cite this article as: Abdalkareem Jasim S, Abdul-Jabbar Ali S, Fadhil OQ, Rakhmatova MKh, Kzar HH, Margiana R, Al-Gazally ME, Turki Jalil A, Hameed Mahmood Z, Aravindhan S, Fakri Mustafa Y, Sultan MQ. Investigating the Effects of Hydro-alcoholic *Urtica Dioica* Extract and Retinoic Acid on Follicular Development: An Animal Study. *Med J Islam Repub Iran*. 2023 (1 Feb);37:1. <https://doi.org/10.47176/mjiri.37.1>

Corresponding author: Dr Osama Q. Fadhil, osamah.qays@alsafwa.edu.iq

1. Al-Maarif University College, Medical Laboratory Techniques Department, Al-anbar-Ramadi, Iraq
2. Pharmacy Department, Al-Safwa University College, Karbalaa, Iraq
3. Department of Histology and Medical Biology, Tashkent State Dental Institute, Makhtumkuli Street 103, Tashkent, Uzbekistan
4. Veterinary Medicine College, Al-Qasim Green University, Al-Qasim, Iraq
5. Department of Anatomy, Faculty of Medicine, Universitas Indonesia, Jakarta, Indonesia
6. Master's Programme Biomedical Sciences, Faculty of Medicine, Universitas Indonesia, Jakarta, Indonesia
7. Dr. Soetomo General Academic Hospital, Surabaya, Indonesia
8. College of Medicine, University of Al-Ameed, Karbala, Iraq
9. Medical Laboratories Techniques Department, Al-Mustaqbal University College, Babylon, Hilla, 51001, Iraq
10. Diyala University, College of Science, Department of Chemistry, Iraq
11. Department of Pharmacology, Saveetha Dental College and Hospital, Saveetha Institute of Medical and Technical Sciences, Chennai, India
12. Department of Pharmaceutical Chemistry, College of Pharmacy, University of Mosul, Mosul-41001, Iraq
13. College of Dentistry, Al-Ayen University, Thi-Qar, Iraq

↑What is “already known” in this topic:

Low dosages of retinoic acid cause oocyte maturity and embryonic evolution. Conversely, higher dosages (above 5 mg/kg) of retinoic acid can lead to morphological, genetic, and biological damage in the cells and tissues. *Urtica dioica*, or Nettle, as a natural antioxidant agent, has been known for a long time as a medicinal plant and used in traditional medicine with broad aspects of biological activity.

→What this article adds:

In this animal investigation, the combination/alone effects of UD hydroalcoholic extract and retinoic acid (in high dosage) on the histology of the ovary, in vitro maturation, fertilization, and developmental rates were assessed. Based on the findings, UD herbal extract as a natural antioxidant agent could reduce the high dosage adverse effects of retinoic acid on oocyte maturation in an IVF condition.

Introduction

Fertility is defined as the ability to bear children and success in reproduction. In contrast, infertility means malfunctioning and disordering of reproduction, and problems related to that are the most important problems in the couples' lives (1). The most common reason for infertility in women is the immaturity of a sufficient number of healthy and active oocytes (2, 3). Women who would lose their reproductive glands in invasive medical treatments like radiotherapy or chemotherapy or, due to environmental-occupational damages, will be presented with a decreased chance of becoming mothers (4). Generally, 2 fundamental problems regarding ovary biology have remained unknown—the factors controlling the initiation of primordial follicles' development, and the quality of the dominant follicle selection process (5).

The development of the technologies required for the in vitro growth and maturity of the ovarian follicle has been an important issue because of the factors controlling the primordial follicles' development initiation (6); however, selecting the culture medium for follicle development is difficult (7). Many growth factors and inducers play important roles in ovarian follicles development. In addition, the balance between producing and entrapment of free oxygen radicals is important for acquiring impregnation ability in the laboratory. Therefore, adding antioxidants to the culture medium is important for the in vitro maturation of the oocytes (8, 9). Antioxidative agents have exhibited free radical scavenging activities to prevent oxidative damage to cellular DNA (10-12).

Herbal remedies have a long medicinal history spanning thousands of years as safe, useful substances. Medicinal plants not only have an antioxidant function but also have the potential for detoxification properties (13). Several studies reported that chemical and herbal medicinal compounds could affect reproductive function in either separate or combined doses (14-16). *Urtica dioica* (UD), or Nettle, has been known as a medicinal plant and used in traditional medicine with broad aspects of biological activity (17). UD is rich in minerals (calcium, sulfur, silicon, potassium, iron, copper, phosphorus, chromium, magnesium, cobalt, and zinc) and vitamins (A, B1, B2, C, D, E and K) (18). The commonly found ingredients in the leaves of the plant are fatty acids like α -linoleic acid, which is an essential fatty acid belonging to the Omega3 family (ω -3); carotenoids like lutein isomers, beta-carotene isomers, and lycopene; phenols like ferulic acid, gallic acid, syringic acid; and flavonoids like catechin hydrate and epicatechin and other ingredients like neoxanthin and violanthin (19).

The in-vivo and in vitro results of several studies in various species indicate that retinoic acid exerts dual effects in such a manner that it plays a key role in vital processes like oocyte maturity and embryonic evolution in very low dosages. However, it leads to morphological, genetic, and biological damage in the cells and tissues, especially in the reproductive system, in higher dosages (above 5 mg/kg) (20). Damdimopoulou et al stated that retinoids need attention as possible targets of endocrine disruption by environmental chemicals and as regulators of adult ovarian physiology

(21). In a review article, they summarized the current knowledge related to retinoids in steroidogenesis and folliculogenesis in postpubertal mammalian ovaries. In another study, Vahedi et al investigated the effect of all-trans retinoic acid administration during in vitro maturation on bovine oocytes (20). They reported that 1 μ M retinoic acid significantly increased the bovine oocyte maturation.

Although the positive effects of retinoic acid on the maturation of oocytes have been shown previously, there are no data related to the effects of UD alone or combined with retinoic acid on oocyte maturation. This is the first study focused on the effects of UD hydroalcoholic extract and retinoic acid, alone and in combination, on the histology of the ovary, in vitro maturation, fertilization, and developmental rates in an animal study.

Methods

Animals' Grouping and Drug Administration

In this study, 40 mature female Wistar rats and 10 mature male rats (for sperm extraction and performing in vitro fertilization, IVF) in an age range of 6 to 8 weeks, and approximate weight of 30 ± 5 g were used. The rats were divided into 5 groups (8 rats in each group)—Group 1 (the control group) was administered only with normal saline; group 2 was administered 25 mg/kg retinoic acid; group 3 was administered 100 mg/kg UD extract; group 4 was simultaneously administered 25 mg/kg retinoic acid and 100 mg/kg UD extract; and group 5 was administered 10 mg/kg olive oil.

Retinoic acid (ATRA; Sigma-Aldrich Co) was dissolved in 100 mg/mL ethanol and diluted using 10 mg/mL olive oil, and finally used in the study in either of the following 2 methods: injected intraperitoneally (in vivo method) for 7 consecutive days to the rats and added in a single dosage to the culture medium (in vitro method) for growing the infertile oocytes to perform IVM (in vitro maturation) in the corresponding groups. UD was administered in 2 different ways: intraperitoneal injection for 7 days in a row, and IVM in the corresponding group was performed using a single dosage of the immature oocytes culture media (22).

In the present study, all procedures were performed according to the protocols approved by the EU Directive 2010/63/EU and NIH Office of laboratory animal welfare (OLAW) guidelines. The study protocol and animal use were reviewed and approved by the local ethics committee on animal experimentation (approval no. H12REA183).

Extract Preparation of UD

To prepare the UD extract, a maceration method was utilized. After cleaning and isolating the waste, the plant parts were placed inside a glass container. The water and alcohol mixture was added for a ratio of 80% ethanol alcohol and 20% distilled water. After 72 hours, the mixture was passed through the Buchner funnel, filtered using Whatman filter paper no.1, and collected in a flask. The solution was condensed using a rotary device at a water temperature of 38 °C and a flask spinning at 75 rpm (23).

Determination of Total Phenol and Flavonoid Amounts

We calculated the portions of the phenolic ingredients according to the Folin-Ciocalteu chromatography method in milligram equivalent of gallic acid (24). Then, we prepared the standard solutions with gallic acid concentrations of 12.5, 25, 50, 62.5, 100, and 125 ppm in a 60% methanol solution. The light absorptions were measured using a spectrophotometer in 765 nm, drawing standard diagrams. Flavonoid amounts were measured based on aluminum chloride chromatography in mg. The light absorptions were read in 415 nm for flavonoid standard, and the standard diagrams were drawn (24).

Assessing the Antioxidant Activities

The antioxidant activity rates of the extract were measured using the DPPH (1, 1-diphenyl-2-picrylhydrazyl) method. This method was implemented, as recounted in previous studies (25). To do the calculations, each extract stock and butylated hydroxytoluene (BHT) were separately dissolved in 1mg/mL and 0.1mM methanol, respectively. Then, 8 concentrations ranging between 10 µg/mL and 100 µg/mL were obtained for the extract, and 8 concentrations were also prepared for BHT. Their light absorptions were read in 517 nm, and IC₅₀ was calculated with the following formula:

$$IC_{50} (\%) = [(A \text{ control} - A \text{ sample}) / A \text{ control}] \times 100.$$

Histological Investigations

After the last injection day, the ovaries were removed for histological examinations and IVF investigations. The ovaries were soaked for 72 hours in a 10% fixative formaldehyde buffer at ambient temperature to safeguard tissue stability. After the fixation and ensuring the tissue stability, the specimens were observed under a photomicroscope. To perform microscopy of the tissue specimens, ethanol in ascending degrees and xylene and paraffin were used. Histological sections were evaluated using hematoxylin (C.I. 75290; Merck) and eosin (C.I. 45380; Sigma) staining. Also, the thicknesses of the theca interna and granulosa layer in antral follicles were measured. To investigate the ovary tissue variations, the structures extant in the ovary were classified based on the morphology into 5 groups: (1) primary follicles (PF); (2) preantral follicles (PAF); (3) antral follicles (AnF); (4) corpus luteum (CL), and (5) atretic follicles (AtF), and their changes were evaluated in the ovary.

Oocyte, Sperm Collection, and IVF

Spermatozoa and oocytes were seeded for the in vitro investigations. The PMSG hormone for 5 international units (IU) was injected intraperitoneally to induce the proliferation and development of oocytes in each rat. Female animals (that did not receive an injection) were killed by cervical vertebrae dislocation, their skin and peritoneum were removed, and the abdominal cavity was observed. Then, the oocytes and cumulus cells (cumulus-oocyte complex-COC) were collected from the ampulla region of the uterine tubes on both sides and transferred to Petri dishes containing human tubal fluid (HTF) culture medium. Different

numbers of immature germinal vesicle (GV) oocytes were obtained from the female rats. Then, we used a pipetting method to remove their peripheral cumulus cells, and, in total, 625 oocytes were obtained in the entire repetition times of the experiments.

The obtained oocytes were randomly assigned into 5 groups (similar to the study groups), including group 1: administered only with normal saline; group 2: administered with 25 mg/kg retinoic acid; group 3: administered with 100 mg/kg UD extract; group 4: administered simultaneously with 25 mg/kg retinoic acid and 100 mg/kg UD extract, and group 5: administered with 10 mg/kg olive oil. In this method, retinoic acid, UD extract, and olive oil were added in single doses to the culture medium of the immature oocytes for the IVM to be accomplished in the corresponding groups. The IVM stages and meiosis resumption were investigated in all groups using inverse microscopy in such a manner that the oocytes maturity rates were calculated after 24 hours: the oocytes with the first polar body were considered as oocytes in metaphase-II (MII) stage, selected for IVF. To collect sperm for IVF, healthy male rats were killed by cervical dislocation. Their epididymis tails and vas deferens were removed and transferred to Petri dishes containing HTF culture medium. The culture medium was incubated at a temperature of 37 °C and a CO₂ concentration of 5%. Next, 5 µL of semen was added to the oocytes. About 5 hours after the addition of sperm, the embryos were cleaned in the droplets of KSOM culture medium and subsequently transferred to the fifth droplet in the middle of the petri dish. To perform a quantitative investigation of the IVF process, the numbers of 2-cell embryos and blastocyst embryos were counted and recorded using a stereomicroscope 1 day and 4 days after fertilization, respectively.

Statistical Analysis

All data were represented as mean ± standard deviation. SPSS software version 20 (SPSS Inc) was used for analysis. For the comparison of data, 1-way analysis of variance with Tukey tests was used. Statistical tests were considered significant at $P \leq 0.05$.

Results

Antioxidant Activity of the UD Extract

The results of the UD extract's contents of total flavonoid, total phenol, and antioxidant activity (IC₅₀) are presented in Table 1. The results indicated that the antioxidant activity of UD extract was increased linearly with the concentration increase.

Histological Findings

Different follicles, including Graafian follicles with thick layers of granulosa cells, and a considerable number of corpus luteum, were observed in the morphological investigation of the transverse tissue sections prepared from the ovaries of the control rats. A varying number of follicles in various developmental stages and atretic follicles with weak layers of granulosa cells were observed in the ovaries of the other groups (Figures 1 and 2).

Table 1. Total flavonoid, total phenol and antioxidant activity (IC_{50}) of the *Urtica dioica* extract

Total flavonoids mg Gallic acid/gDw extract	Total phenol mg rutin/gDw extract	IC_{50} of DPPH radical (mg/mL)
20.30	106.77	92.128

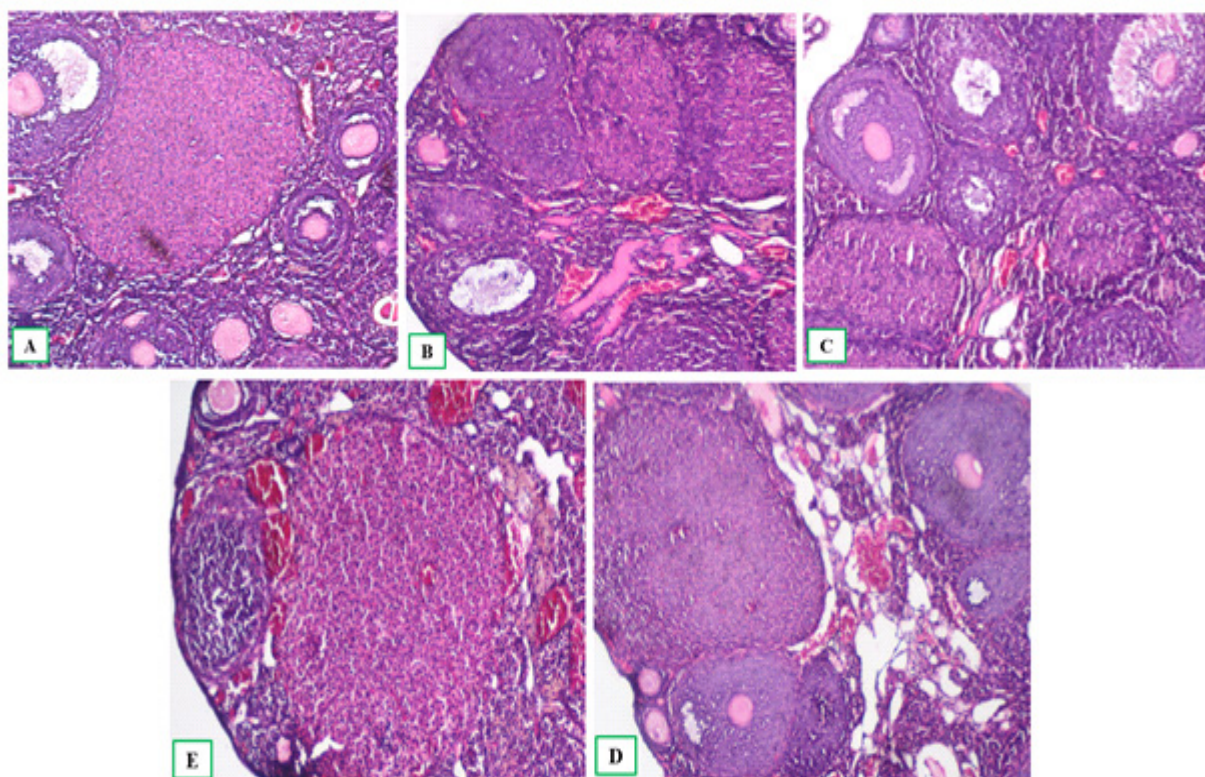


Figure 1. Histology of the ovaries in various studied groups (Hematoxylin & Eosin staining; magnification 40X). 1A and 1B are images pertaining to groups 1 and 5: ovary transverse sections in the control group along with the corpus luteum. Epithelial tissue of the ovary surface of the pavement to simple cubic forms wherein various types of follicles, including resting follicles, and growing follicles including primary, preantral (secondary) and antral follicles can be observed. Image 1C growing follicles including primary, preantral (secondary) and antral follicles can be observed and they are mostly found with atresia. Image 1D group 3: all types of follicles, including primary, preantral, antral and corpus luteum, were observed. Also, the number of mature oocytes, in contrast to groups 1 and 5, was found increased; image 1E group 4: various kinds of developing and healthy follicles along with a number of follicles undergo atresia (8 mice in each group).

No significant difference was observed between the studied groups regarding primordial follicles ($p>0.05$). Injection of 25 mg/kg retinoic acid for 7 consecutive days (group 2) caused an increase in the primary follicles (5.75 ± 1.28 and 12.50 ± 1.69 ; $p<0.001$), preantral (18.62 ± 1.59 and 29.50 ± 2.67 ; $p<0.001$), and atretic follicles (3.12 ± 1.35 and 9.62 ± 2.26 ; $p<0.001$), and reduction in the corpus luteum (9.0 ± 1.51 and 3.0 ± 1.51 ; $p<0.001$), as compared with the control group (group 1).

Injection of 100 mg/kg UD extract (group 3) caused an increase in the preantral (18.62 ± 1.59 and 23.0 ± 1.92 ; $p<0.001$), antral (5.25 ± 0.7 and 9.12 ± 1.12 ; $p<0.001$), and corpus luteum (9.0 ± 1.51 and 12.25 ± 1.98 ; $p<0.001$) as well as insignificant reduction in the atretic follicles compared with the group 1 ($p=0.332$). Also, the extract injection to the group that had been administered with retinoic acid and UD extract (group 4) caused a reduction in the atretic follicles (9.62 ± 2.26 and 7.37 ± 1.99 ; $p=0.043$) and an increase in the number of corpus luteum (3.0 ± 1.51 and 6.50 ± 0.92 ; $p<0.001$) compared with group 2, and this is indicative of ovulation. Moreover, it caused an insignificant

decrease in the antral follicles (6.50 ± 1.30 and 6.0 ± 0.92 ; $p=0.674$). Generally, the corpus luteum was at its lowest in group 2 and highest in group 3.

The Results of Laboratory Impregnation

The results indicated no significant difference in the number of GV oocytes between the studied groups ($p>0.05$). However, the oocytes' maturation and reaching the stage of MII were variable in the groups in such a manner that the number of MII oocytes was significantly different from that of group 2 ($p=0.005$) and group 4 ($p=0.051$). After adding sperm to the oocyte in various groups, the 2-pronucleus embryo formation was found to be different in that group 3 (received only 100 mg/kg UD extract) significantly differed from group 2 in terms of the number of 2PN embryos ($p=0.002$). The results of statistical analysis indicated that group 3 was significantly different from groups 2 ($p<0.001$) and 5 ($p=0.018$) in terms of the number of 2-cell embryos. This shows the adverse effects of high doses of retinoic acid on the embryo's survival.

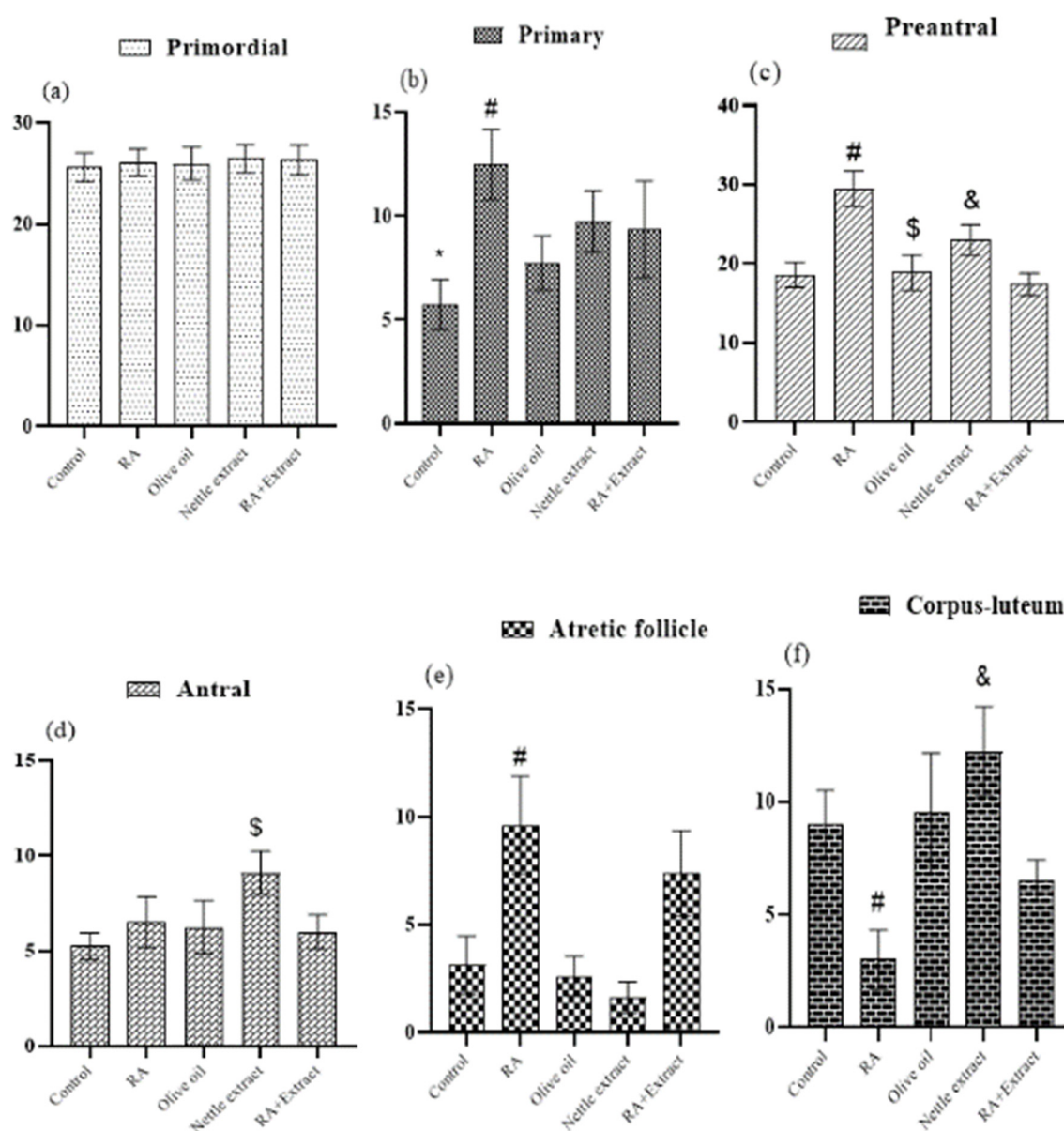


Figure 2. Comparison of the follicle development stages in ovary tissues of the studied groups (n=8). To compare the groups, one-way variance analysis along with the Tukey test was used. (a) Number of Primordial follicles; (b) Number of Primary follicles; (c) Number of Preantral; (d) Number of Antral follicles; (e) Number of Atretic follicles; (f) Number of Corpus-luteum. Control: injected only by normal saline, RA: injected by 25 mg/kg retinoic acid, Olive oil: injected by 10 mg/kg olive oil, Nettle extract: injected by 100mg/kg UD extract, RA+extract: simultaneously injected by 25 mg/kg retinoic acid and 100 mg/kg UD extract. *: significantly differs with groups 2, 3 and 4 ($P<0.05$); #: differs significantly with groups 1, 3, 4 and 5 ($P<0.05$); \$: significantly differs from groups 1, 2, 4 and 5 ($P<0.05$); &: significantly differs from groups 1, 3 and 5 ($P<0.01$).

The results also showed that blastocyst formation (embryo grows until reaching the 32-cell stage) was at its lowest in group 2 and the highest in group 3. Therefore, group 2 was significantly different from groups 1 ($p=0.003$), 3 ($p=0.001$), and 4 ($p=0.012$) in terms of blastocyst number. In line with this, a significant difference was also observed between group 3 with groups 2 ($p<0.001$), 4 ($p=0.049$), and 5 ($p=0.004$) (Table 2).

Discussion

Low dosages of retinoic acid cause oocyte maturity and

embryonic evolution; however, higher dosages (above 5 mg/kg) can lead to morphological, genetic, and biological damage in the cells and tissues (20). We assessed the combination/alone effects of UD hydroalcoholic extract and retinoic acid (in high dosage) on the histology of the ovary, in vitro maturation, fertilization, and developmental rates in an animal study.

Based on the histological results of the ovaries, injection of a high dosage of retinoic acid led to the creation of atretic follicles, reduction in the number of antral follicles and corpus luteum, very few oocytes—due to the decrease in the

Table 2. Comparison of the in vitro maturation and fertilization results of the studied groups

Groups	Total COCs	Developmental stages of IVM&IVF processes						
		After 4 hours- GV	After 16-18 hours- MII	Total MII oocytes fertilization	4-6 hours after IVF-2PN embryo	20-26 hours after IVF-2-cell embryo	30 hours after IVF- Dead Cell	96 hours after IVF- Blastocyst
1	105	11.00±0.68	9.00±0.85	72	7.25±0.59	5.62±0.71	1.12±0.23	4.75±0.45
2	121	9.38±0.63	7.12±0.72	57	5.12±0.69	3.50±0.54	1.88±0.30	1.62±0.42 ^{&}
3	116	11.75±0.62	10.75±0.62 [*]	86	9.12±0.67 [#]	7.50±0.46 [§]	0.88±0.30	6.62±0.71 ⁺
4	96	9.88±0.81	8.00±0.46	64	6.75±0.73	5.25±0.80	1.25±0.25	4.38±0.57
5	118	11.50±0.82	8.62±0.68	69	6.50±0.78	4.62±0.53	1.25±0.37	3.62±0.57

To compare the groups, one-way variance analysis along with Tukey follow-up test was used. *: has significant difference from groups 2 and 4 ($p<0.05$). #: has significant difference from group 2 ($p<0.01$). §: has significant difference from group 5 ($p<0.05$). &: has significant difference from groups 1, 3 and 4 ($p<0.01$). +: has significant difference from groups 2, 4 and 5 ($p<0.05$). COC: cumulus oocyte complex; GV: germinal vesicle; MII: Metaphase II.

number of corpus luteum. It also reduced the number of 2-cell embryos and increased fetal deaths. The disorder of embryonic development was observed as a reduction in blastocyst embryos in the present study. Kenter et al showed that the injection of UD extract moderates and improves the effects of CCL4 administration, which causes an increase in the peroxidation of lipids and hepatic enzymes as well as a reduction in the antioxidant levels (26).

In our study, injection of retinoic acid in a dosage of 25 mg/kg for 7 consecutive days caused an increase in the number of atretic follicles, a reduction in the number of corpus luteum, and a decrease in the number of 2-cell embryos and blastocysts, which are consistent with a previous study (26). The increase in the percentage of antral follicles in the present study originated from vitamins and flavonoids in UD extract, preventing the destruction of oocytes and reducing oocyte death (24). Therefore, the number of available oocytes ready for growth and development increases. Every factor disrupting the hypothalamus-pituitary-gonadal axis causes malfunctioning of the axis, resulting in the disordering of the gametes' production (27). There is no receptor for the FSH hormone when the primary follicle possesses 4 layers of granulosa cells. However, as mentioned earlier, the receptors appear on the follicular cell surface (28).

A controlled hormonal and physiological process called follicular atresia is used to describe the failure and reabsorption of the gametes. (29). Although the process is defined as a natural and physiological mechanism, it has been reported that the atresia inhibition mechanism might be simulated by several factors, including pituitary gland surgery, dietary regime disorders, environmental stressors, and chemical substance (30). reactive oxygen species participates in a vast spectrum of fertilization physiological functions, including oocyte maturity, ovary steroidogenesis, ovulation, implantation, blastocyst formation, and corpus luteum function (31). Increasing the number of follicles in the groups administered with UD hydroalcoholic extract, compared with retinoic acid, can be attributed to a high level of antioxidants like flavonoids in the plant. Due to the ovary's cycles of tissue changes, steroid and peptide secretion, and steroid and peptide synthesis, which are related to vitamin C, the presence of vitamins A and C in UD extract can have protective effects on ovulation. Ovary is the main storage place of vitamin C with the highest concentration in the theca interna, and granulosa cells (32). UD contains

such compounds as sterols, flavonoids, and polysaccharides, which may have antiandrogenic effects and prevent the formation of active forms of testosterone by inhibiting 5-alpha reductase activity. Thus, stromal cells and follicular cell orders are preserved through normal functioning levels, thereby enhancing fertility power (33). Aktas et al showed that the structural disorders were reduced in the group administered with 2 mg/kg UD during spermatogenesis (34). The data obtained from the present study comply with the results obtained by the data from the present study comply with the results of Aktas et al that support the positive effect of UD extract on fertility. Akondi et al showed that 10 mg/kg Naringin and Rutin caused improvement of all the sperm-related parameters, reduced malondialdehyde levels and increased superoxide dismutase and catalase levels (35).

In summary, retinoic acid and UD increase oocyte maturation, fertilization, and embryo developmental rates in rats with different effects at high doses. UD extract contains active ingredients such as Naringin and Rutin; hence, it can be considered a factor giving rise to the increase in the number of 2-cell embryos. The possible mechanisms of the positive effects of UD can be due to oocyte cytoplasmic maturation promotion through direct or indirect modulatory effects on the gene expression pattern of gonadotropin receptors.

Our study has several limitations that could be considered in future studies. We only assessed the concentration of 100 mg/kg UD extract; In light of this, combining a plant-based diet and maturation medium with UD herbal extract as a natural antioxidant agent is recommended. In addition, other natural antioxidant agents like Chinese yam polysaccharide can be assessed along with UD herbal extract.

Conclusion

We investigated the effects of UD hydroalcoholic extract and retinoic acid alone and in combination on the histology of the ovary, in vitro maturation, fertilization, and developmental rates in the rats. The results demonstrated that UD herbal extract as a natural antioxidant agent could reduce the adverse effects of (high doses of) retinoic acid on oocyte maturation in an IVF condition.

Acknowledgment

N/A.

Ethical Consideration

The study protocol and animal use were reviewed and approved by the local ethics committee on animal experimentation (approval no. H12REA183).

Authors' Contribution

O.Q.F. is responsible for the study conception, design, acquisition of data, and finalizing the manuscript. All the authors contributed to data analysis and writing the manuscript draft. Furthermore, all the authors read and approved the final manuscript.

Abbreviations

UD: *Urtica dioica*, IVF: in vitro fertilization, OLAW: office of laboratory animal welfare, IVM: in vitro maturation, BHT: Butylated hydroxytoluene, PAF: preantral follicles, AnF: antral follicles, CL: corpus luteum, ATF: atretic follicles, IU: international units, HTF: human tubal fluid, GV: germinal vesicle, COC: cumulus-oocyte complex.

Conflict of Interests

The authors declare that they have no competing interests.

References

- Iordachescu DA, Gica C, Vladislav EO, Panaitescu AM, Peltecu G, Furtuna ME, et al. Emotional disorders, marital adaptation and the moderating role of social support for couples under treatment for infertility. *Ginekol Pol.* 2021;92(2):98–104.
- Maddirevula S, Coskun S, Alhassan S, Elnour A, Alsaif HS, Ibrahim N, et al. Female infertility caused by mutations in the oocyte-specific translational repressor PATL2. *Am J Hum Genet.* 2017;101(4):603–608.
- Mobarak H, Heidarpour M, Tsai PSJ, Rezabakhsh A, Rahbarghazi R, Nouri M, et al. Autologous mitochondrial microinjection; a strategy to improve the oocyte quality and subsequent reproductive outcome during aging. *Cell Biosci.* 2019;9(1):1–15.
- Yang H, Kuhn C, Kolben T, Ma Z, Lin P, Mahner S, et al. Early life oxidative stress and long-lasting cardiovascular effects on offspring conceived by assisted reproductive technologies: A review. *Int J Mol Sci.* 2020;21(15):5175.
- Yu Y, Yan J, Liu ZC, Yan LY, Li M, Zhou Q, et al. Optimal timing of oocyte maturation and its relationship with the spindle assembly and developmental competence of in vitro matured human oocytes. *Fertil Steril.* 2011;96(1):73–78.
- Telfer EE, Andersen CY. In vitro growth and maturation of primordial follicles and immature oocytes. *Fertil Steril.* 2021;115(5):1116–1125.
- Xiao S, Duncan FE, Bai L, Nguyen CT, Shea LD, Woodruff TK. Size-specific follicle selection improves mouse oocyte reproductive outcomes. *Reprod Camb Engl.* 2015;150(3):183.
- Khazaei M, Aghaz F. Reactive oxygen species generation and use of antioxidants during in vitro maturation of oocytes. *Int J Fertil Steril.* 2017;11(2):63.
- Sovernigo TC, Adona PR, Monzani PS, Guemra S, Barros FDA, Lopes FG, et al. Effects of supplementation of medium with different antioxidants during in vitro maturation of bovine oocytes on subsequent embryo production. *Reprod Domest Anim.* 2017;52(4):561–569.
- Majdaeen M, Banaei A, Abedi-Firouzjah R, Gorji KE, Ataei G, Momeni F, et al. Investigating the radioprotective effect of sesame oil consumption against gamma irradiation in mice by micronucleus and alkaline comet assays. *Appl Radiat Isot.* 2020;159:109091.
- Nadi S, Banaei A, Mozdarani H, Monfared AS, Ataei GR, Abedi-Firouzjah R. Evaluating the radioprotective effect of arbutin on mice exposed to megavoltage X-rays based on hematological parameters and lymphocytes micronucleus assay. *Int J Radiat Res.* 2020;18(2):275–282.
- Rahgoshai S, Mehnati P, Aghamiri MR, Borujeini MH, Banaei A, Tarighatnia A, et al. Evaluating the radioprotective effect of Cimetidine, IMOD, and hybrid radioprotectors agents: An in vitro study. *Appl Radiat Isot.* 2021;174:109760.
- Cox-Georgian D, Ramadoss N, Dona C, Basu C. Therapeutic and medicinal uses of terpenes. In: *Medicinal Plants.* Springer; 2019. p. 333–359.
- Abasian Z, Rostamzadeh A, Mohammadi M, Hosseini M, Raffieian-Kopaei M. A review on role of medicinal plants in polycystic ovarian syndrome: pathophysiology, neuroendocrine signaling, therapeutic status and future prospects. *Middle East Fertil Soc J.* 2018;23(4):255–262.
- Ahmadi M, Rostamzadeh A, Fathi F, Mohammadi M, Rezaie MJ. The effect of Melatonin on histological changes of ovary in induced polycystic ovary syndrome model in mice. *Middle East Fertil Soc J.* 2017;22(4):255–259.
- Fatehi D, Mohammadi M, Shekarchi B, Shabani A, Seify M, Rostamzadeh A. Radioprotective effects of Silymarin on the sperm parameters of NMRI mice irradiated with γ -rays. *J Photochem Photobiol B.* 2018;178:489–495.
- Moayeri A, Ahmadi R, Rostamzadeh A, Salehi N, Mohammadi M, Fatehi D. Preventive efficacy evaluation of *Urtica dioica* on in vitro fertilization and embryo development in exposed mice. *Med Sci.* 2018.
- Atanassova M, Georgieva S, Ivancheva K. Total phenolic and total flavonoid contents, antioxidant capacity and biological contaminants in medicinal herbs. *J Univ Chem Technol Metall.* 2011;46(1).
- Upton R. Stinging nettles leaf (*Urtica dioica* L.): Extraordinary vegetable medicine. *J Herb Med.* 2013;3(1):9–38.
- Vahedi V, Zeinoaldini S, Kohram H, Farahavar A. Retinoic acid effects on nuclear maturation of bovine oocytes in vitro. *Afr J Biotechnol.* 2009;8(16).
- Damdimpoulou P, Chiang C, Flaws JA. Retinoic acid signaling in ovarian folliculogenesis and steroidogenesis. *Reprod Toxicol.* 2019;87:32–41.
- Raverdeau M, Gely-Pernot A, Féret B, Dennefeld C, Benoit G, Davidson I, et al. Retinoic acid induces Sertoli cell paracrine signals for spermatogonia differentiation but cell autonomously drives spermatocyte meiosis. *Proc Natl Acad Sci.* 2012;109(41):16582–16587.
- Ahangarpour A, Mohammadian M, Dianat M. Antidiabetic effect of hydroalcoholic *Urtica dioica* leaf extract in male rats with fructose-induced insulin resistance. *Iran J Med Sci.* 2012;37(3):181.
- Pinelli P, Ieri F, Vignolini P, Bacci L, Baronti S, Romani A. Extraction and HPLC analysis of phenolic compounds in leaves, stalks, and textile fibers of *Urtica dioica* L. *J Agric Food Chem.* 2008;56(19):9127–9132.
- Ogasawara M, Matsunaga T, Suzuki H. Differential effects of antioxidants on the in vitro invasion, growth and lung metastasis of murine colon cancer cells. *Biol Pharm Bull.* 2007;30(1):200–204.
- Kanter M, Coskun O, Budancamanak M. Hepatoprotective effects of *Nigella sativa* L and *Urtica dioica* L on lipid peroxidation, antioxidant enzyme systems and liver enzymes in carbon tetrachloride-treated rats. *World J Gastroenterol WJG.* 2005;11(42):6684.
- Rey F, González M, Zayas MA, Stoker C, Durando M, Luque EH, et al. Prenatal exposure to pesticides disrupts testicular histoarchitecture and alters testosterone levels in male *Caiman latirostris*. *Gen Comp Endocrinol.* 2009;162(3):286–292.
- Shibayama H, Kotera T, Shinoda Y, Hanada T, Kajihara T, Ueda M, et al. Collaborative work on evaluation of ovarian toxicity 14) Two-or four-week repeated-dose studies and fertility study of atrazine in female rats. *J Toxicol Sci.* 2009;34(Special):SP147–SP155.
- González-Kother P, Oliva ME, Tanguy A, Moraga D. A review of the potential genes implicated in follicular atresia in teleost fish. *Mar Genomics.* 2020;50:100704.
- Zama AM, Uzumcu M. Epigenetic effects of endocrine-disrupting chemicals on female reproduction: an ovarian perspective. *Front Neuroendocrinol.* 2010;31(4):420–439.
- Zhang X, Sharma RK, Agarwal A, Falcone T. Effect of pentoxifylline in reducing oxidative stress-induced embryotoxicity. *J Assist Reprod Genet.* 2005;22(11):415–417.
- Otles S, Yalcin B. Phenolic compounds analysis of root, stalk, and leaves of nettle. *Sci World J.* 2012.
- Nahata A, Dixit VK. Ameliorative effects of stinging nettle (*Urtica dioica*) on testosterone-induced prostatic hyperplasia in rats. *Andrologia.* 2012;44:396–409.
- Aktas C, Erbogga M, Fidanol Erbogga Z, Bozdemir Donmez Y, Topcu B, Gurel A. Protective effects of *Urtica dioica* L. on experimental testicular ischaemia reperfusion injury in rats. *Andrologia.* 2017;49(4):e12636.

35. Akondi RB, Kumar P, Annapurna A, Pujari M. Protective Effect of rutin and naringin on sperm quality in streptozotocin (STZ) induced type 1 diabetic rats. *Iran J Pharm Res IJPR*. 2011;10(3):585.