

# Direct Comparison of Adjacent Endocardial and Epicardial Electrograms: Implications for Substrate Mapping

Michifumi Tokuda, MD; Usha B. Tedrow, MSc, MD; Keiichi Inada, MD; Tobias Reichlin, MD; Gregory F. Michaud, MD; Roy M. John, MD, PhD; Laurence M. Epstein, MD; William G. Stevenson, MD

**Background**—Analysis of unipolar voltage maps has been used to detect epicardial scar, but data to define optimal parameters to identify scar remote from the recording site is limited. This study compares the characteristics of electrograms at endocardial sites adjacent to abnormal epicardial sites.

**Methods and Results**—Data obtained from endocardial and epicardial electroanatomical maps of 31 patients with scar-related ventricular tachycardia were reviewed. Five hundred twenty-three pairs of endo- and epicardial points were selected according to predefined criteria. The endocardial points adjacent to epicardial scar (bipolar voltage <1.5 mV) had smaller unipolar voltage than those distant from epicardial scar ( $P<0.001$ ). In multivariable analysis, unipolar voltage was the only endocardial electrogram predictor of epicardial scar ( $P<0.001$ , OR 0.94, 95% CI 0.93 to 0.97). An endocardial unipolar amplitude <4.4 mV in the right ventricular (RV) (sensitivity 93%, specificity 76%) and <5.1 mV in the left ventricular (LV) (sensitivity 91%, specificity 75%) was the optimal cutoff predicting epicardial scar. Applying these thresholds to electroanatomical maps, revealed a good match between endocardial unipolar abnormality and epicardial scar for 67% of LV and 75% of RV maps, respectively, but notably poor matches occurred in 8 (29%) maps (7 with nonischemic cardiomyopathy). Site-by-site correlations were better for ischemic than nonischemic cardiomyopathy.

**Conclusions**—This study supports the contention that unipolar electrograms are capable of indicating overlying epicardial scar during endocardial mapping, but illustrates limitations that appear to differ with nonischemic as compared to ischemic cardiomyopathy. The presence of epicardial arrhythmia substrate cannot be excluded by analysis of unipolar endocardial maps in some patients. (*J Am Heart Assoc.* 2013;2:e000215 doi: 10.1161/JAHA.113.000215)

**Key Words:** catheter ablation • electroanatomical mapping • epicardial • nonischemic heart disease • ventricular tachycardia

The location of ventricular scars supporting reentrant ventricular tachycardia (VT) is a major determinant of the ablation approach. Scars can be subendocardial, subepicardial, intramural, or transmural, in location.<sup>1,2</sup> The recognition of potential reentry substrate deep to the endocardium, during endocardial mapping, is potentially helpful in guiding approaches to VT ablation. Minimally filtered unipolar recordings have a wider “field of view” than bipolar recordings. Recently, Polin et al<sup>3</sup> and Hutchinson et al<sup>4</sup>

found that endocardial low voltage unipolar electrogram areas can be markers for epicardial low voltage areas, consistent with scar. They selected a voltage threshold for identifying scar based on the 95th percentile for voltage in a small group of normal subjects. Direct comparison between endo- and epicardial electrogram characteristics has not been well studied. The aim of this study is to gain more detailed insight into endo- and epicardial electrogram characteristics using point-by-point comparisons of electrograms obtained from adjacent sites on either side of the ventricular wall.

From the Cardiovascular Division, Brigham and Women's Hospital, Harvard Medical School, Boston, MA.

An accompanying Table S1 is available at <http://jaha.ahajournals.org/content/2/5/e000215/suppl/DC1>

**Correspondence to:** Michifumi Tokuda, MD, Cardiovascular Division, Brigham and Women's Hospital, 75 Francis St., Boston, MA 02115. E-mail: tokudam@gmail.com

Received March 25, 2013; accepted August 31, 2013.

© 2013 The Authors. Published on behalf of the American Heart Association, Inc., by Wiley Blackwell. This is an open access article under the terms of the Creative Commons Attribution-NonCommercial License, which permits use, distribution and reproduction in any medium, provided the original work is properly cited and is not used for commercial purposes.

## Methods

Data from 31 patients with structural heart disease (26 male, 56±15 years) and recurrent VT who underwent endocardial (left ventricular [LV] in 17, and right ventricular [RV] in 21) and epicardial substrate mapping at the same procedure during sinus rhythm were retrospectively reviewed. A total of 7397 points (4673 in epicardium and 2724 in endocardium) were acquired on an electroanatomical mapping system (below). The mapping density in the scar was 1.00 point/cm<sup>2</sup> in

endocardium and 0.99 point/cm<sup>2</sup> in epicardium, respectively. Underlying heart disease was classified as previously described.<sup>5</sup> Studies and data collection were performed according to protocols approved by the Human Research Committee of Brigham and Women's Hospital. Each patient gave written informed consent.

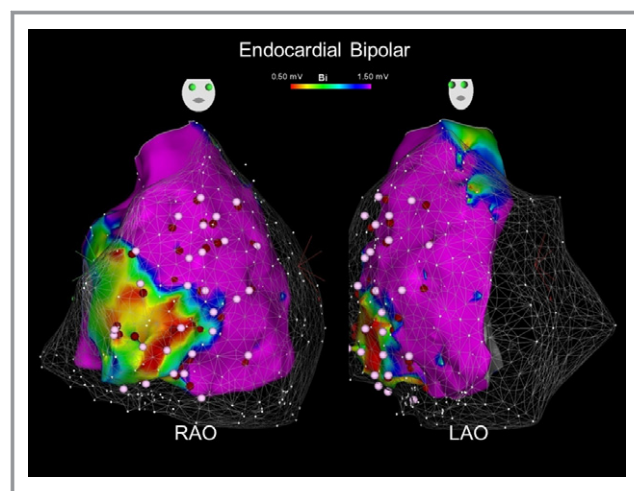
## Electroanatomical Mapping

All antiarrhythmic drugs except amiodarone were stopped for more than 5 half-lives unless incessant VT was present. Electroanatomical mapping was performed with the CARTO mapping system (Biosense Webster) using respiratory gating, and intracardiac ultrasound imaging (Soundstar, Biosense Webster). The system allows measurement of the distance between 2 points and is accurate to within 1 mm.<sup>6</sup> Mapping was performed with an open-irrigation ablation catheter (NaviStar ThermoCool, Biosense Webster). This catheter consists of a 3.5-mm-tip electrode, separated by 1 mm spacing from a 2-mm ring electrode. The location of valve annuli was identified from intracardiac echo imaging. Electrograms were band pass filtered from 16 to 500 Hz for bipolar and 1 to 240 Hz for unipolar recordings. The peak-to-peak amplitude was automatically measured and displayed. Bipolar electrogram amplitudes <1.5 mV were defined as scar.<sup>7</sup> A split potential was defined as an electrogram with a long isoelectric period (>20 ms) between 2 spikes. A late potential was defined as isolated potentials occurring >10 ms after the end of the QRS. The anatomical distance was calculated using the distance measurement tool on the CARTO software. Percutaneous epicardial access was performed as previously described.<sup>8</sup>

## Selection of Mapping Points for Comparison

Endo- and epicardial pairs of points were selected according to strict criteria: for each epicardial point, an endocardial point within distance of 15 mm in LV or 10 mm in RV was selected. Each point was used only once. If there were multiple points in the range, the nearest point was selected. To minimize the impact of the adjacent tissue on unipolar electrogram amplitude, RV sites within 10 mm of the septum and sites within 10 mm of the valve annuli were excluded (Figure 1). If any radiofrequency ablation had been performed during the procedure before a point was collected, points within 10 mm of the ablation site were excluded. To avoid selecting points overlying epicardial fat, epicardial low-voltage points also had to demonstrate at least one additional feature indicative of scar: late potentials, a broad potential ( $\geq 80$  ms), split potentials, or multicomponent (deflections  $\geq 8$ ) as suggested previously.<sup>9</sup>

Low voltage areas were measured using the algorithm included in the CARTO system. The extent of overlap of low

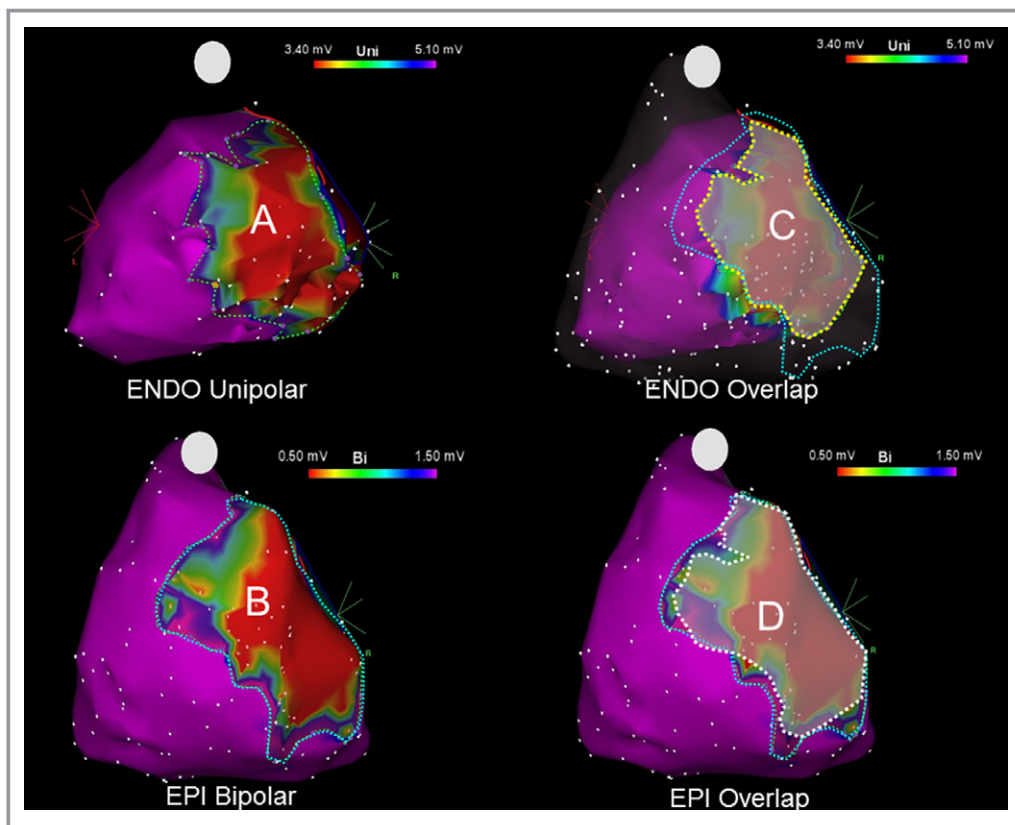


**Figure 1.** RV endocardial bipolar voltage map and mesh overlay of the epicardial map in a patient with arrhythmogenic right ventricular cardiomyopathy. Right anterior oblique (RAO) view in left and left anterior oblique (LAO) view in right panel. A bipolar amplitude of  $\geq 1.5$  mV was categorized as normal and was represented by the color purple. Abnormal endocardium (<1.5 mV) was represented by the nonpurple range of colors, with the most abnormal signal amplitude, arbitrarily defined as “dense scar” (consistent with signal amplitude <0.5 mV), represented by the color red. For each epicardial point (white dot), a nearest endocardial point (red dot) within distance of 10 mm was selected. Sites within 10 mm of the septum and sites within 10 mm of the valve annuli were not used. Corresponding mapping points were connected by yellow line. RV indicates right ventricle.

voltage between the endocardium and epicardium was determined as follows. First, we manually traced the border of the low voltage area on each map using CARTO area measurement soft (Figure 2). Then we superimposed endo- and epicardial surface on one map. Then the overlap area was redrawn on both endocardial and epicardial map surface, again using the CARTO area measurement software. The overlap area was calculated as the average of the endocardial and epicardial overlap area. The “overlap ratio” was defined as “[endocardial overlap area (C)+epicardial overlap area (D)]/[endocardial unipolar low voltage area (A)+epicardial bipolar low voltage area (B)]” (Figure 2). For this analysis an overlap ratio of >0.60 was defined as a good match between 2 maps.

## Statistical Analysis

Continuous variables are expressed as mean $\pm$ standard deviation. Categorical variables are expressed as numbers or percentages. To account for clustering of points within patient, a mixed model was used. To assess predictors of epicardial scar by endocardial electrogram characteristics, a generalized estimating equation approach with exchangeable working correlation matrix for fitting generalized linear models to clustered data was used. A 0.10 level of significance was



**Figure 2.** Calculation of “overlap ratio.” Voltage maps of a patient with idiopathic dilated cardiomyopathy. Left upper panel shows endocardial unipolar low-voltage area (<4.4 mV, framed by green dotted line) (A) and left lower panel shows epicardial bipolar scar area (<1.5 mV, blue dotted line) (B). Endo- and epicardial overlap area was traced by yellow (C) and white (D) dotted line in right panel, respectively. The “overlap ratio” was defined as “[endocardial overlap area (C)+epicardial overlap area (D)]/[endocardial unipolar low voltage area (A)+epicardial bipolar low voltage area (B)].” In this case, the overlap ratio was 0.82. ENDO indicates endocardial; EPI, epicardial; LV, left ventricle.

used for variable entry and removal from the stepwise models. The following 6 variables were included as candidates for entry into the stepwise models: bipolar and unipolar amplitude, electrogram duration, number of deflection, split potentials, and late potentials. The correlation between endocardial and epicardial voltage was assessed by Spearman’s rank correlation coefficient. The receiver-operator characteristic (ROC) curve was constructed to assess the sensitivity and specificity of endocardial unipolar voltage to predict the epicardial scar. The optimal cutoff point was chosen as the combination with the highest sensitivity and specificity. Significance was defined as  $P<0.05$ . Statistical analyses were performed using SPSS, version 20.0 (IBM). The authors had full access to the data, and take full responsibility for the integrity of the data.

## Results

### Study Population

Of 31 patients, underlying heart disease was ischemic cardiomyopathy (ICM) in 7, idiopathic dilated cardiomyopathy

in 12, arrhythmogenic right ventricular cardiomyopathy in 9, and cardiac sarcoidosis in 3 patients, respectively. Endocardial electroanatomical mapping was performed in both LV and RV in 7, only RV in 14, and only LV in 10. Of 2724 endocardial points, 523 points (249 in RV, 274 in LV) met inclusion criteria. The mean distance between the endo- and epicardial point was  $9.0\pm 2.7$  mm in the LV and  $7.7\pm 3.1$  mm in the RV.

### Electrogram Characteristics

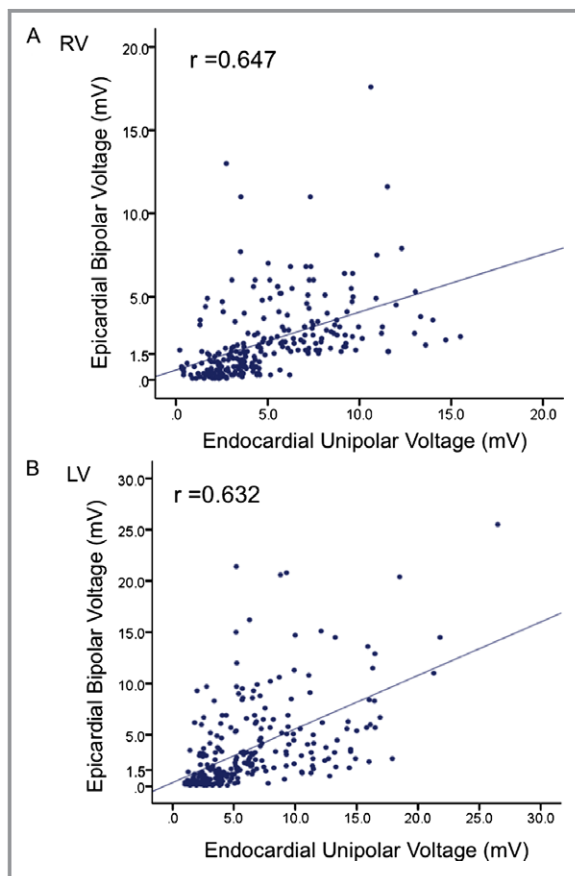
Electrogram characteristics between endocardial and epicardial points are shown in Table 1. Electrogram duration was longer ( $P=0.001$ ) and, consistent with the study design, split potentials were more frequently seen ( $P<0.001$ ) in the epicardium than endocardium. There were modest but significant correlations between the endocardial unipolar amplitude and epicardial bipolar amplitude for the RV ( $R=0.647$ ,  $P<0.001$ ) (Figure 3A) and LV ( $R=0.632$ ,  $P<0.001$ ) (Figure 3B).

Further analysis was performed using commonly employed definitions for epicardial scar of 1.5 mV or less

**Table 1.** Electrogram Characteristics

	Endocardial (N=523)	Epicardial (N=523)	P Value
Bipolar amplitude, mV	2.9±2.6	3.0±3.5	0.12
Unipolar amplitude, mV	5.6±3.9	5.7±4.9	0.20
Electrogram duration, ms	82±27	87±31	0.001
Number of deflection	6.2±2.8	6.2±2.8	0.51
Split potential	27 (5.1%)	58 (11%)	<0.001
Late potential	40 (7.6%)	52 (9.9%)	0.23

Data are presented as mean±SD or n (%).



**Figure 3.** The correlation plot of endocardial unipolar and epicardial bipolar amplitude in RV (A) and LV (B) is shown. LV indicates left ventricle; RV, right ventricle.

than 1.0 mV. Among 523 pairs, 307 (59%) points had epicardial bipolar voltage <1.5 mV. Endocardial sites adjacent to epicardial scar (bipolar amplitude <1.5 mV) had significantly smaller endocardial bipolar and unipolar voltage, longer electrogram duration, a larger number of deflections, and more frequently demonstrated late potentials compared with those not adjacent to epicardial scar (Table 2). Using multivariable analysis, only the endocardial

unipolar voltage was an independent predictor of epicardial scar ( $P<0.001$ , OR 0.94, 95% CI 0.93 to 0.97) (Table 3). The ROC curve for the endocardial unipolar amplitude as a predictor of the epicardial scar showed an area under the curve of 0.885 in RV and 0.856 in LV (Figure 4). An optimal cutoff point of <4.4 mV of the RV endocardial unipolar amplitude had a sensitivity of 93% and a specificity of 76% and that of <5.1 mV in LV had a sensitivity of 91% and a specificity of 75% (Figure 4, arrow) in predicting epicardial scar. The optimal cutoff point predicting epicardial bipolar amplitude of <1.0 mV was 3.8 mV (sensitivity 83%, specificity 71%) in RV and 4.5 mV (sensitivity 89%, specificity 70%) in LV. That of <0.5 mV was 3.2 mV (sensitivity 77%, specificity 74%) in RV and 3.4 mV in LV (sensitivity 80%, specificity 77%).

### Epicardial or Intramural Scar Overlying Normal Voltage Endocardium

The presence of endocardial scar may alter the unipolar voltage. Excluding 186 pairs of points with endocardial bipolar amplitude <1.5 mV left 337 points for analysis of epicardial abnormal areas overlying endocardial normal voltage. Endocardial unipolar voltage (OR=0.90, 95% CI 0.93 to 0.96,  $P<0.001$ ) remained an independent predictor of epicardial scar. The optimal cutoff point for predicting epicardial scar was 4.4 mV (sensitivity 93%, specificity 74%) in the RV, and 5.1 mV (sensitivity 90%, specificity 76%) in the LV. Areas with normal endocardial and epicardial electrograms, but low voltage unipolar electrograms might indicate the presence of intramural scar. Using a unipolar electrogram threshold of less than 4.4 mV for the RV and 5.1 mV for the LV and bipolar epicardial and endocardial amplitude  $\geq 1.5$  mV, there were 40 such sites. These sites were more frequent in nonischemic (NICM) than ICM (10% versus 0.7%,  $P=0.001$ ). As we did not have magnetic resonance imaging (MRI) to compare for these sites, we do not have definitive evidence as to whether these are associated with intramural scar.

**Table 2.** Endocardial Electrogram Characteristics

	Adjacent to Epicardial Scar (N=307)	Not Adjacent to Epicardial Scar (N=216)	P Value
Bipolar amplitude, mV	1.5±1.6	3.9±2.7	<0.001
Unipolar amplitude, mV	3.1±1.7	7.4±4.0	<0.001
Electrogram duration, ms	88±31	78±23	<0.001
Number of deflection	6.9±3.3	5.8±2.3	<0.001
Split potential	16 (7)	11 (4)	0.052
Late potential	25 (12)	15 (5)	0.005

Data are presented as mean±SD or n (%).

### Epicardial Fat

In this study, 103 pairs of points were excluded due to suspected epicardial fat based on a low-amplitude electrogram without other abnormal characteristics, such as fractionation. The electrogram duration was shorter and the number of deflection was smaller in 103 points excluded due to suspected epicardial fat than those included, as expected from the exclusion criteria (Table S1). The average endocardial unipolar amplitude (5.7±3.3 mV) at these 103 points was greater than that at the 217 points beneath low-voltage abnormal epicardial electrograms (3.1±1.7 mV,  $P<0.001$ ). When these 103 points were included, the correlation of endocardial unipolar and epicardial bipolar amplitude decreased to  $r=0.453$ . Moreover, the sensitivity of the RV endocardial unipolar cutoff amplitude of 4.4 mV to predict epicardial scar (bipolar voltage <1.5 mV) decreased from 93% to 66%.

### Influence of Heart Disease

Since most patients with ischemic heart disease did not undergo RV endocardial mapping, this sub-analysis comparing ICM with NICM was performed only for the LV. The correlation between LV endocardial unipolar and epicardial bipolar

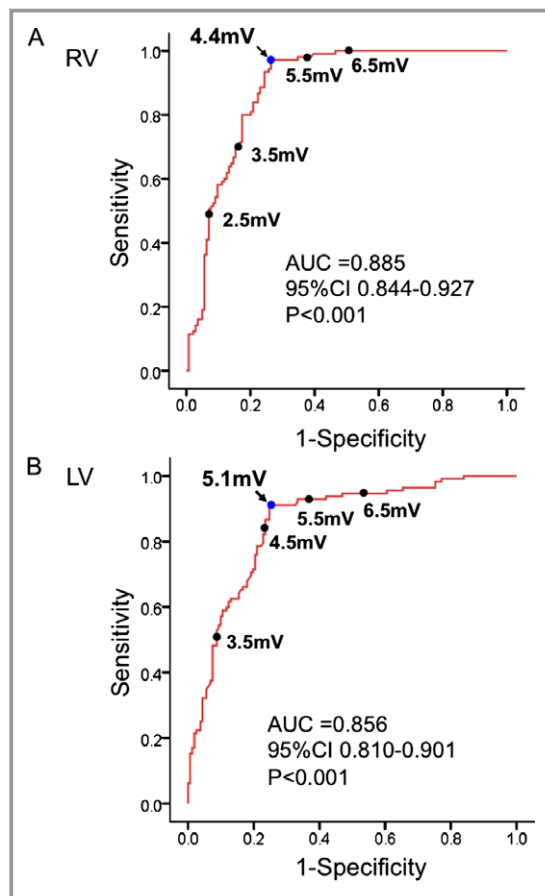
amplitude was stronger in ICM compared to those with NICM ( $r=0.619$  and  $r=0.410$ , respectively) (Figure 5). An LV endocardial unipolar voltage of 5.1 mV was the optimal cutoff point to predict epicardial scar in the patients with ICM (sensitivity 94%, specificity 69%) as well as NICM (sensitivity 85%, specificity 78%).

### Electroanatomical Map

Point-by-point comparisons ignore the contribution of adjacent myocardium to the signal amplitude, which is relevant in voltage maps. Therefore, a comparison of electroanatomical maps was performed. At least one epicardial scar lesion was detected in 12 of 17 LV maps and 16 of 21 in RV maps. Using an endocardial unipolar voltage threshold of <4.4 mV in RV and <5.1 mV in LV, a good match between endocardial unipolar low-voltage area and epicardial scar, defined as overlap ratio >0.60, was seen in 67% (8/12) for the LV and 75% (12/16) for the RV. Of the 8 cases with a poor overlap, 88% (7/8) had NICM. In 4 cases the endocardial unipolar low-voltage area was much larger than the epicardial scar (Figure 6A). Whether this might be due to intramural scar could not be determined with certainty in this study. In contrast, extensive epicardial scar was found, despite a relatively small area of endocardial unipolar abnormality in the

**Table 3.** Multivariable Analysis of Endocardial Electrogram Characteristics for Predicting Epicardial Scar

	P Value	Odds Ratio	95% Confidence Interval
Bipolar amplitude	0.13	0.99	0.97 to 1.004
Unipolar amplitude	<0.001	0.94	0.93 to 0.97
Electrogram duration	0.07	1.01	0.999 to 1.02
Number of deflection	0.54	0.97	0.97 to 1.07
Split potential	0.61	1.35	0.43 to 4.24
Late potential	0.64	1.22	0.53 to 2.82

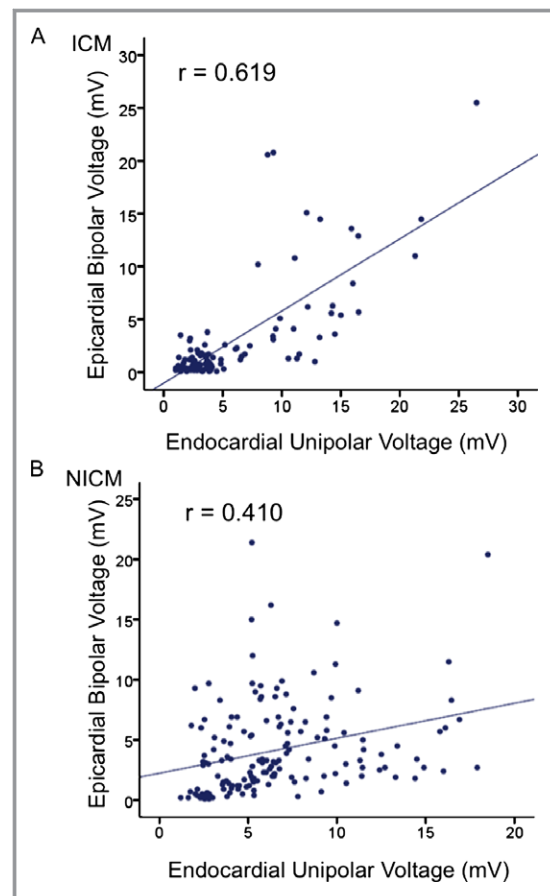


**Figure 4.** ROC curve analysis of RV (A) and LV (B) endocardial unipolar amplitude according to the epicardial scar. Arrow indicates optimal cutoff point for sensitivity and specificity. AUC indicates area under the curve; CI, confidence interval; LV, left ventricle; ROC, receiver-operator characteristic; RV, right ventricle.

other 4 cases; LV in 2, RV in 2 (Figure 6B). In these 2 RV maps, points that were excluded as possible epicardial fat were also present in the unmatched area, suggesting a combination of epicardial fat and scar (Figure 7).

## Discussion

The present study gives detailed insight into the relation between endo- and epicardial electrogram characteristics in patients with ventricular tachycardia. In agreement with prior studies, endocardial unipolar amplitude was the only endocardial electrogram predictor of epicardial scar. In contrast to prior studies, the best endocardial unipolar voltage predictors for scar were lower: 4.4 mV in the RV and 5.1 mV in the LV. Despite our attempt to optimize prediction, a good match with epicardial low-voltage regions was achieved in only 67% of LV and 75% of RV. Additional analyses suggested that epicardial fat and the nature of the cardiomyopathy may affect these correlations.



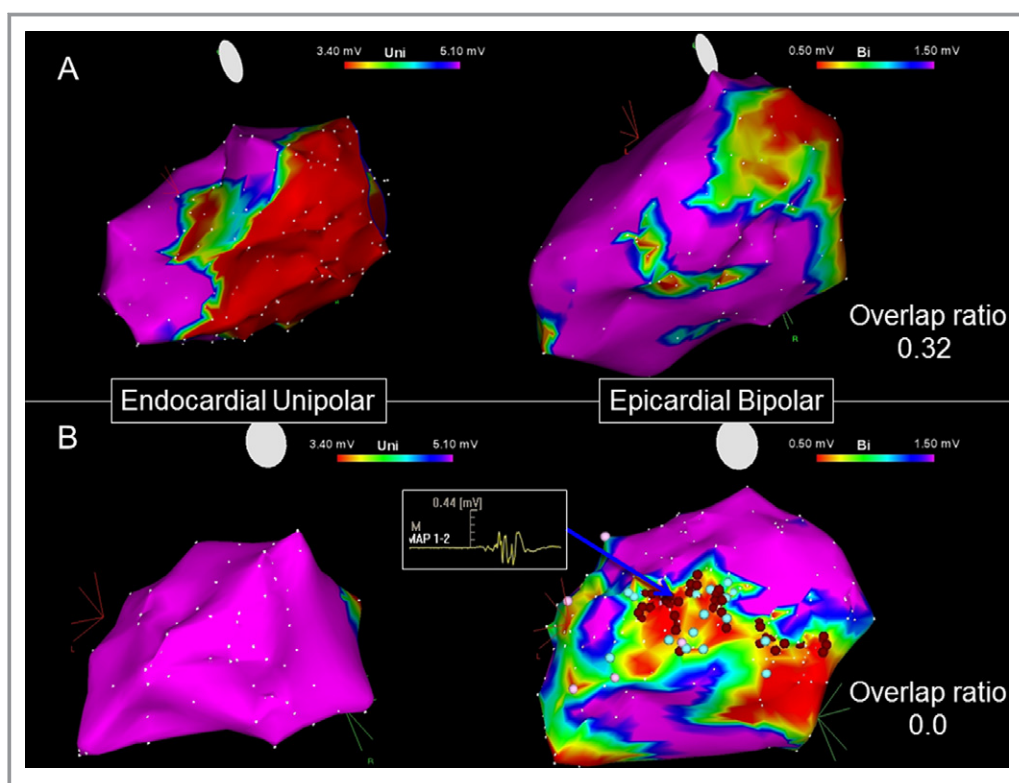
**Figure 5.** Correlation plot between left ventricle (LV) endocardial unipolar and epicardial bipolar amplitude in the patients with (A) ICM and (B) NICM.

## Unipolar and Bipolar Mapping

Since the rejection of far-field signal facilitates identification of local potentials in bipolar recordings, these are standard in most laboratories. On the other hand, minimally filtered unipolar recordings can be useful for mapping focal arrhythmia sources, but contain greater far-field signal generated by depolarization of tissue remote from the recording electrode.<sup>10</sup> Previous studies found that normal myocardium could be distinguished from regions with subendocardial or transmural infarcts on the basis of unipolar voltage.<sup>11</sup> The scar areas as assessed by unipolar and bipolar voltages in the electroanatomical map correlated well with the scar as defined by delayed enhanced MRI (DE-MRI).<sup>12–14</sup>

## Use of Unipolar Amplitude to Predict Epicardial Scar

Previous studies used an endocardial unipolar voltage cutoff of 5.5 mV in RV and 8.27 mV in LV to predict epicardial low voltage.<sup>3,4</sup> These cut points were based on the 95th percentile



**Figure 6.** Examples of unmatched cases. A, LV endo- and epicardial voltage map in a patient with dilated cardiomyopathy. Endocardial unipolar low-voltage area ( $<5.1$  mV) was relatively larger than epicardial scar ( $<1.5$  mV). The overlap ratio was 0.32. B, LV endo- and epicardial voltage map in a patient with dilated cardiomyopathy. Extensive epicardial scar was found despite the absence of LV unipolar abnormality ( $<5.1$  mV). The overlap ratio was 0.00. Fractionated potential (arrow) indicates that the epicardial scar contains the VT substrate. Red dots indicate radiofrequency ablation sites. LV indicates left ventricle; VT, ventricular tachycardia.

for electrogram amplitude in patients without structural heart disease. Our analysis suggests that these cut points are sensitive, but lacking specificity in some patients. In the present study we tried to further optimize the cut point by direct comparison of electrograms at adjacent endo- and epicardial sites. A lower threshold, 4.4 mV for the RV and 5.1 mV for the LV were identified. Despite this effort, application to electroanatomical maps found that  $\approx 30\%$  of patients had mismatches between endocardial unipolar map and epicardial scar.

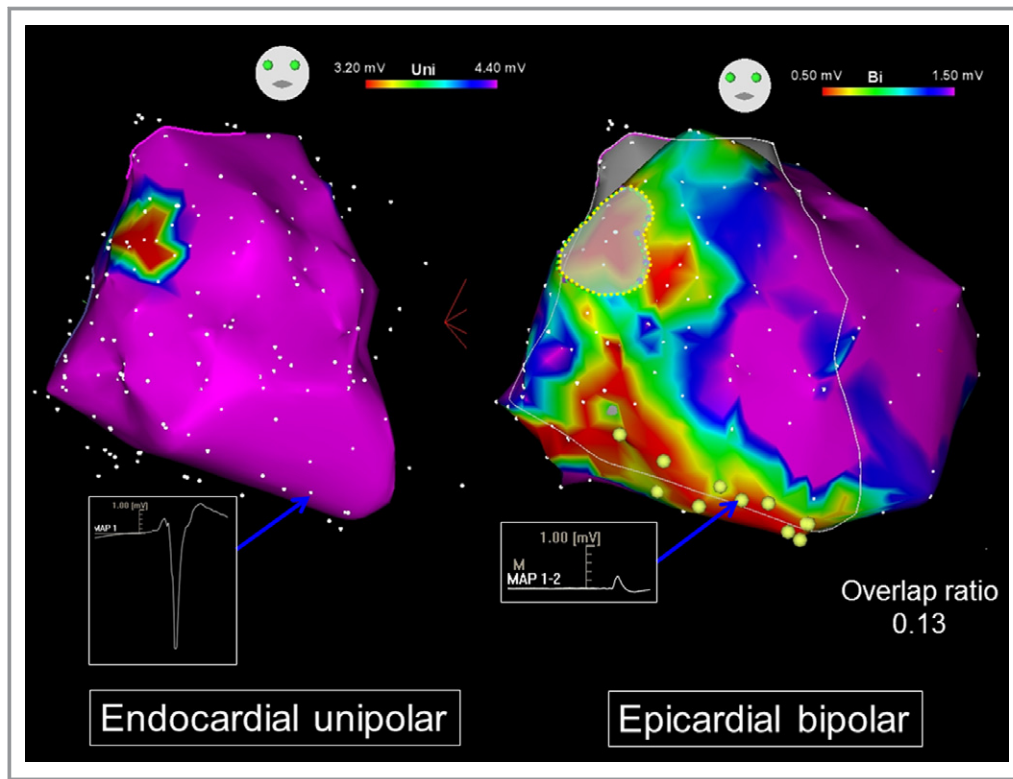
### Causes of Mismatch

Epicardial fat can lead overestimation of epicardial scar. A previous study suggested an epicardial bipolar voltage  $\geq 1.5$  mV as the best correlated with the absence of epicardial fat in patients without cardiomyopathy.<sup>15</sup> Tung et al<sup>9</sup> compared the electrogram characteristics of epicardial fat and scar in a porcine infarct model. An electrogram duration  $>80$  ms, deflections  $>8$ , and late potentials was 99%, 92%, and 99% specific for scar, respectively. In the present study, we used criteria to attempt to reject sites with overlying fat. These

excluded points did have greater endocardial unipolar amplitude, and their inclusion reduced the correlation of endocardial unipolar with epicardial bipolar amplitude. Unfortunately, we do not have computed tomography (CT) or magnetic resonance (MR) imaging to identify fat for comparison to further clarify this issue.

Intramural scar may be a cause of a larger endocardial low-voltage region compared to the epicardial region. Detection of these intramural scars is of interest, as they can also be the substrate for VT. Further study of this issue is warranted. We also, however, observed cases of clear epicardial scar containing the VT substrate that was not detected from analysis of the endocardial electrograms. Whether this reflects a thin epicardial rim of abnormal myocardium, or other characteristics of scars in some patients is not known. It was more commonly observed in nonischemic cardiomyopathy than in ischemic heart disease patients. This limitation of endocardial unipolar mapping is important to recognize.

The reason that the correlation of endocardial with epicardial electrogram amplitude was somewhat better for ICM than for NICM is not clear, but could relate to differences



**Figure 7.** RV endocardial unipolar voltage map indicates small scar in anterior tricuspid annulus (left panel). However, the epicardial bipolar map shows a substantially larger low-voltage area over the RV free wall. Overlapped area is framed by yellow dotted line. The overlap ratio is 0.13. The yellow tags on epicardial surface indicate the point met the criteria adjacent to epicardial fat. RV indicates right ventricle.

in scar distribution and anatomy. Whereas scar tissue in ICM patients is commonly located in the subendocardium and infarct scars are often thinner regions of the ventricle, scar in NICM is more variable in location, often found in the midmyocardium or the epicardium.<sup>1,2,16</sup> Although the epicardial and endocardial points were in close proximity, the variations in distance imposed by differences in LV wall thickness could still influence unipolar electrogram amplitude, and our results. The distance likely influences the degree to which signal depolarization of the epicardium contributes to the endocardial signal, and vice versa. It is possible that ventricular wall thickness over areas of scar is more variable, and thicker in NICM than ICM, contributing to the poorer correlation in NICM.

### Study Limitations

Since we do not have cardiac MRI in most patients who had undergone ICD implantation, the potential effect of intramural scar cannot be determined. Therefore, selection bias could occur. The low-amplitude bipolar electrogram criteria have, however, been validated as a conservative indication of scar in MR studies and animal models. These studies suggest that electrogram criteria can underestimate scar areas, as may occur when scar is intramural.<sup>12,14</sup> The pairs of points were

selected according to location and sampling tended to focus on abnormal areas, such that it was unlikely to be uniform. As there were fewer epicardial points than endocardial points, we only recorded the data of the nearest endocardial point. It is possible that inclusion of additional surrounding points would affect the results. We also excluded epicardial points for which low voltage might have been due to fat, based on absence of other indications that the tissue was abnormal. It is likely that some points with low voltage not due to fat were excluded. We now state this in the limitations section. Electrogram amplitude can vary with electrode contact to the tissue; further study using contact sensing catheter would be of interest in studying this concern. Our criteria for avoiding fat should have excluded some potential points with poor contact. The correlation can be weaker along the scar border where varied amplitudes may be more mixed. Filter settings affect electrogram characteristics. Our bipolar electrograms recorded in the mapping system were band pass filtered from 16 to 500 Hz.

### Conclusions

The broader field of view of unipolar electrograms has been shown to be capable of indicating the presence of overlying epicardial scar during endocardial mapping. This study defines a lower amplitude threshold for detecting scar than has



previously been reported. Significant limitations are still present, however, such that epicardial substrate for VT cannot be excluded based on a normal-appearing unipolar endocardial map, particularly in nonischemic heart disease. Further studies correlating unipolar and bipolar electrograms with anatomy may help further define scar-related arrhythmia substrates to guide catheter ablation and mapping and improve ability to distinguish epicardial fat from low-voltage scar.

## Acknowledgments

We wish to thank Daishi Hirano, MD, MPH (the Jikei University School of Medicine, Tokyo, Japan) for his guidance in statistical analysis.

## Disclosures

Dr Stevenson is co-holder of a patent for needle ablation that has been consigned to Brigham and Women's Hospital. Dr Tedrow has received consulting moneys from St Jude Medical and Boston Scientific as well as nonsalary research dollars from Biosense Webster and St Jude Medical.

## References

1. Roberts WC, Siegel RJ, McManus BM. Idiopathic dilated cardiomyopathy: analysis of 152 necropsy patients. *Am J Cardiol.* 1987;60:1340–1355.
2. McCrohon JA, Moon JC, Prasad SK, McKenna WJ, Lorenz CH, Coats AJ, Pennell DJ. Differentiation of heart failure related to dilated cardiomyopathy and coronary artery disease using gadolinium-enhanced cardiovascular magnetic resonance. *Circulation.* 2003;108:54–59.
3. Polin GM, Haqqani H, Tzou W, Hutchinson MD, Garcia FC, Callans DJ, Zado ES, Marchlinski FE. Endocardial unipolar voltage mapping to identify epicardial substrate in arrhythmogenic right ventricular dysplasia/cardiomyopathy. *Heart Rhythm.* 2011;8:76–83.
4. Hutchinson MD, Gerstenfeld EP, Desjardins B, Bala R, Riley MP, Garcia FC, Dixit S, Lin D, Tzou WS, Cooper JM, Verdino RJ, Callans DJ, Marchlinski FE. Endocardial unipolar voltage mapping to detect epicardial VT substrate in patients with nonischemic left ventricular cardiomyopathy. *Circ Arrhythm Electrophysiol.* 2011;4:49–55.
5. Tokuda M, Tedrow UB, Kojodjojo P, Inada K, Koplan BA, Michaud GF, John RM, Epstein LM, Stevenson WG. Catheter ablation of ventricular tachycardia in non-ischemic heart disease. *Circ Arrhythm Electrophysiol.* 2012;5:992–1000.
6. Smeets JL, Ben-Haim SA, Rodriguez LM, Timmermans C, Wellens HJ. New method for nonfluoroscopic endocardial mapping in humans: accuracy assessment and first clinical results. *Circulation.* 1998;97:2426–2432.
7. Marchlinski FE, Callans DJ, Gottlieb CD, Zado E. Linear ablation lesions for control of unmappable ventricular tachycardia in patients with ischemic and non-ischemic cardiomyopathy. *Circulation.* 2000;101:1288–1296.
8. Sosa E, Scanavacca M, d'Avilla A, Pillegi F. A new technique to perform epicardial mapping in the electrophysiology laboratory. *J Cardiovasc Electrophysiol.* 1996;7:531–536.
9. Tung R, Nakahara S, Ramirez R, Lai C, Fishbein MC, Shivkumar K. Distinguishing epicardial fat from scar: analysis of electrograms using high-density electroanatomic mapping in a novel porcine infarct model. *Heart Rhythm.* 2010;7:389–395.
10. Stevenson WG, Soejima K. Recording techniques for clinical electrophysiology. *J Cardiovasc Electrophysiol.* 2005;16:1017–1022.
11. Perin EC, Silva GV, Sarmento-Leite R, Sousa AL, Howell M, Muthupillai R, Lambert B, Vaughn WK, Flamm SD. Assessing myocardial viability and infarct transmural depth with left ventricular electromechanical mapping in patients with stable coronary artery disease: validation by delayed-enhancement magnetic resonance imaging. *Circulation.* 2002;106:957–961.
12. Codreanu A, Odille F, Aliot E, Marie PY, Magnin-Poull I, Andronache M, Mandry D, Djaballah W, Régent D, Felblinger J, de Chillou C. Electroanatomic characterization of post-infarct scars comparison with 3-dimensional myocardial scar reconstruction based on magnetic resonance imaging. *J Am Coll Cardiol.* 2008;52:839–842.
13. Desjardins B, Crawford T, Good E, Oral H, Chugh A, Pelosi F, Morady F, Bogun F. Infarct architecture and characteristics on delayed enhanced magnetic resonance imaging and electroanatomic mapping in patients with postinfarction ventricular arrhythmia. *Heart Rhythm.* 2009;6:644–651.
14. Wijnmaalen AP, van der Geest RJ, van Huls van Taxis CF, Siebelink HM, Kroft LJ, Bax JJ, Reiber JH, Schalij MJ, Zeppenfeld K. Head-to-head comparison of contrast-enhanced magnetic resonance imaging and electroanatomical voltage mapping to assess post-infarct scar characteristics in patients with ventricular tachycardias: real-time image integration and reversed registration. *Eur Heart J.* 2011;32:104–114.
15. Desjardins B, Morady F, Bogun F. Effect of epicardial fat on electroanatomical mapping and epicardial catheter ablation. *J Am Coll Cardiol.* 2010;56:1320–1327.
16. De Cobelli F, Pieroni M, Esposito A, Chimenti C, Belloni E, Mellone R, Canu T, Perseghin G, Gaudio C, Maseri A, Frustaci A, Del Maschio A. Delayed gadolinium-enhanced cardiac magnetic resonance in patients with chronic myocarditis presenting with heart failure or recurrent arrhythmias. *J Am Coll Cardiol.* 2006;47:1649–1654.