



OPEN ACCESS

Clinical management of immune-related adverse events following immunotherapy treatment in patients with non-small cell lung cancer

Hannah Elizabeth Green ,¹ Jorge Nieva²¹University of Dallas, Irving, Texas, USA²Department of Internal Medicine, Division of Medical Oncology, University of Southern California - Norris Comprehensive Cancer Center and Hospital, Los Angeles, California, USA**Correspondence to**

Dr Jorge Nieva, University of Southern California - Norris Comprehensive Cancer Center and Hospital, Los Angeles, CA 90033, USA; Jorge.Nieva@med.usc.edu

Accepted 27 April 2021

Published Online First

14 June 2021

ABSTRACT

The advent of checkpoint blockade-based immunotherapy is rapidly changing the management of lung cancer. Whereas past anticancer drugs' primary toxicity was hematologic, the newer agents have primarily autoimmune toxicity. Thus, it is no longer enough for oncology practitioners to be skilled only in hematology. They must also understand management of autoimmune conditions, leveraging the skills of the rheumatologist, endocrinologist and gastroenterologist in the process. Herein we describe the mechanism of action and toxicities associated with immune checkpoint blockade in patients with lung cancer and provide a framework for management of adverse events.

INTRODUCTION

Immunotherapy for lung cancer is the new standard of care for the majority of patients. Since 2018, there have been six immune checkpoint inhibitors (ICIs) approved by the Food and Drug Administration to treat lung cancer. Nivolumab (Bristol Myers Squibb), pembrolizumab (Merck), atezolizumab (Roche), durvalumab (AstraZeneca) and cemiplimab (EMD Serono) all work by interfering with the interaction between the programmed death-1 protein on T cells (PD-1) and its ligand on target cells (PD-L1). This makes tumor cells more susceptible to immune attack by T cells. Ipilimumab (Bristol Myers Squibb) is a different type of checkpoint inhibitor, approved in combination with nivolumab, and works by a different mechanism: blocking the interaction between cytotoxic T lymphocyte-associated protein 4 (CTLA-4) and its ligand, thereby promoting greater immune response against tumor cells.

These novel drugs come with novel toxicity. As the drugs unmask cancer cells to immune surveillance mechanisms, they generally lower the threshold for immune attack and can result in autoimmune syndromes in a subset of patients. While often the immune adverse events are not life-threatening, they are common. In a series of studies reporting adverse events comprising 1472 patients, the rate of immune-related adverse events (irAEs) was 64.7% for any-grade irAE, with 17.1% of patients experiencing grade 3–5 events.^{1–3} By comparison, in the

chemotherapy arms of these trials comprising 1074 patients, 87.4% of patients treated with chemotherapy experienced any-grade adverse event and 41.1% experienced grade 3 and 4 adverse events.^{1–3}

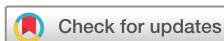As an alternative to cytotoxic chemotherapy or radiation treatment, this new avenue of anti-neoplastic therapy has proven to be tremendously successful across many cancer types, with dozens of new indications in the past 5 years for these agents. For treatment of lung cancer in particular, immunotherapy has provided something that was not previously seen: sustained remissions in metastatic patients. For some patients, the long remissions suggest the possibility that the treatments represent a cure. It is therefore imperative, given the extraordinary clinical benefits, that immune toxicity be properly managed. Since any organ system can be affected, all medical specialties will have a role to play.

ORGAN TARGETS OF IRAES

Immune adverse events can occur in most any organ system of the body (figure 1). For patients with lung cancer in particular, an understanding of pneumonitis is essential because lung inflammation can also occur from radiation changes, lymphangitic tumor infiltration, postobstructive pneumonia and from other drugs such as osimertinib and pemetrexed. Other important sites of irAE include the gastrointestinal tract, endocrine glands, liver and skin. Each of these is reviewed in the following sections.

Pneumonitis

Pneumonitis associated with checkpoint inhibitors is characterized most frequently by dyspnea and/or cough with fever, with chest pain being less common.⁴ Findings on lung radiographs include both interstitial and alveolar infiltrates along with fibrosis (figure 2). Pneumonitis is an irAE that is particularly relevant for patients with non-small cell lung cancer,⁵ especially for those who have received prior radiotherapy. Nearly half of radiation-exposed patients with lung cancer will experience some degree of radiation lung injury.⁶ A secondary analysis of the Keynote-001 trial, the first large open-label study of pembrolizumab in lung cancer, found



© American Federation for Medical Research 2021.

Re-use permitted under CC BY-NC. No commercial re-use. Published by BMJ.

To cite: Green HE, Nieva J. *J Investig Med* 2021;**69**:1281–1286.

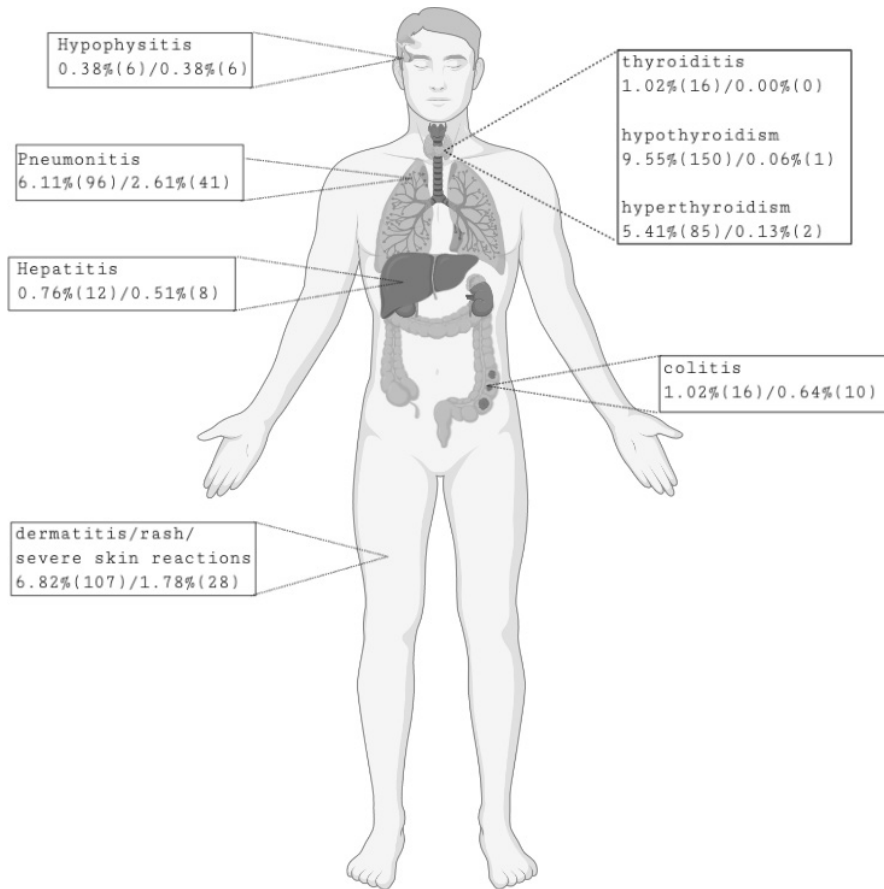


Figure 1 Total incidence of any-grade/grade 3–5 PD-1/PD-L1 immune-related adverse events in the entire patient population. We have amalgamated four randomized lung cancer trials selected because each reported data for non-small cell lung cancer adverse events that included reports of occurrence in 1% of patients or less,^{1–3,26} with 1570 patients. Shown are the number of patients and percentage who had toxicity at the site following PD-1/PD-L1 treatment: percentage of all grades (number of affected all-grade patients)/percentage of grades 3–5 (number of affected patients of grades 3–5). PD-1, programmed death-1 protein; PD-L1, PD-1 ligand.

higher rates of pulmonary toxicity in patients who had prior thoracic radiotherapy.⁷ ICI-related pneumonitis presents as bilateral ground-glass opacities or nodules, and usually manifests as organizing pneumonia histopathologically, often with vague non-necrotizing airspace granulomas.

Foamy macrophages and pneumocyte vacuolization are characteristic and rare eosinophils are often seen.⁸ The rate of all-grade and high-grade pneumonitis from PD-1/PD-L1 inhibitors was 15.2% in one series.⁹ In a meta-analysis of 23 randomized clinical trials across all tumor types,

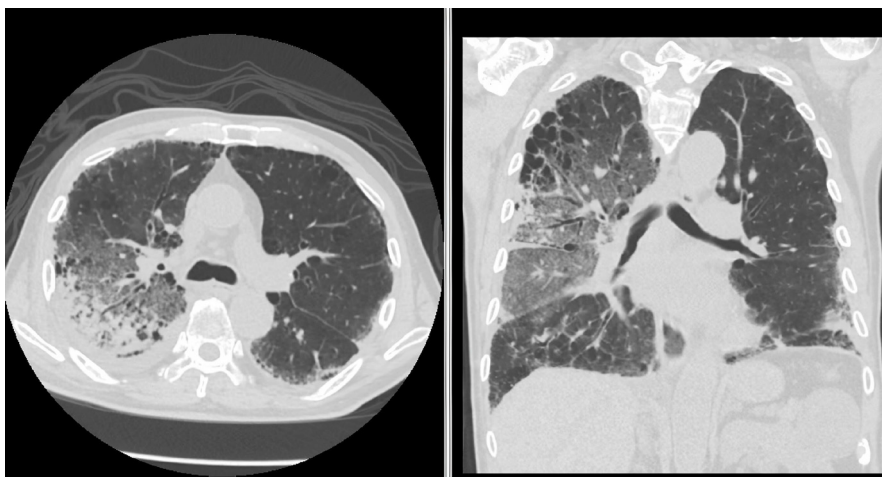


Figure 2 Example of checkpoint-related pneumonitis.

Table 1 Percentage of patients who get any grade of pneumonitis

Treatment	Pneumonitis incidence (%)	Median duration of response (months)	References
Atezolizumab 1200 mg every 3 weeks	1.6	16.3	Rittmeyer <i>et al</i> ³⁸
Docetaxel 75 mg/m ² every 3 weeks	0.3	6.2	
Atezolizumab 1200 mg every 3 weeks	3.5	14.3	Fehrenbacher <i>et al</i> ³⁹
Docetaxel 75 mg/m ² every 3 weeks	0.0	7.2	
Durvalumab 10 mg/kg every 2 weeks	11.2	NR	Antonia <i>et al</i> ⁴⁰
Placebo	5.1	13.8	
Nivolumab 3 mg/kg every 2 weeks	2.3	NR	Brahmer <i>et al</i> ¹³
Docetaxel 75 mg/m ² every 3 weeks	0.0	8.4	
Nivolumab 3 mg/kg every 2 weeks	3.8	17.2	Borghaei <i>et al</i> ⁴¹
Docetaxel 75 mg/m ² every 3 weeks	0.7	5.6	
Pembrolizumab 200 mg every 3 weeks	8.4	NR	Reck <i>et al</i> ¹
Chemotherapy	1.3	6.3	
Pembrolizumab 2 mg/kg every 3 weeks	6.2	NR	Herbst <i>et al</i> ²
Pembrolizumab 10 mg/kg every 3 weeks	5.5	NR	
Ipilimumab + chemotherapy	0.5	5.7	Govindan <i>et al</i> ⁴²
Chemotherapy + placebo	1.1	4.7	
Pembrolizumab + chemotherapy	6.8	NR	Langer <i>et al</i> ⁴³
Chemotherapy	0.0	NR	
Nivolumab 1 + ipilimumab 3	4.9	7.7	Antonia <i>et al</i> ²⁶
Nivolumab 3 + ipilimumab 1	9.2	4.4	
Nivolumab	4.1	NR	

NR, not reached.

multivariate analysis found that the addition of a CTLA-4 inhibitor to a PD-1/PD-L1 blocking drug increased the risk of pneumonitis by a factor of 3.27.¹⁰ Pneumonitis is the most common cause of anti-PD-(L)1-associated fatality, encompassing 35% of fatalities associated with checkpoint inhibition.^{4 11} For patients treated with ICI therapy, the diagnostic CT scan of pneumonitis displays a spectrum of findings typically observed in interstitial pneumonias.¹² For grade 1 pneumonitis, no intervention is usually required. For grade 2 events and higher, the ICI is held, and corticosteroids 1 mg/kg are initially administered until severity improves to grade 1 and then the steroids can be tapered. For patients who relapse and cannot successfully come off steroids, or who are steroid-refractory, additional interventions are applied in series, including tumor necrosis factor (TNF) blockade, mycophenolate or tocilizumab. Fortunately, most cases can be managed with drug withdrawal and corticosteroids alone. In one clinical trial evaluating the efficacy and safety of nivolumab, 272 patients were randomly assigned nivolumab or docetaxel; all but one of the patients with treatment-related pulmonary adverse events were treated with glucocorticoid and all the cases were resolved.¹³ One patient had a recurrence of pneumonitis which was able to be managed with another round of glucocorticoid treatment. In this same trial, pneumonitis in the nivolumab group was the most common treatment-related adverse event that led to discontinuation of treatment in 2% of patients.¹³ A summary of incidence rates of pneumonitis from checkpoint blockade can be found in [table 1](#).

Colitis

Patients experiencing immune-related colitis will complain of diarrhea in 91% of cases, abdominal pain in 53% and/or similarly nausea/vomiting in 53%. The most common

finding on laboratory analysis is leukocytosis, which affects 20% of patients, with a median white cell count of $15.3 \times 10^9/L$. Bowel wall thickening is an almost universal finding, seen in 97% of cases, with a fluid-filled colon observed in 82%.¹⁴ Along with abdominal pain and diarrhea, colitis may present with rectal bleeding and/or mucus in the patient's stool.¹⁵ Colitis and diarrhea are among the most common side effects of ipilimumab therapy.¹⁶ Colitis is the cause of 70% of anti-CTLA-4 fatalities and 37% of combination PD-1/CTLA-4 therapy fatalities across all tumor types.^{4 11} It is seen less commonly in single-agent PD-1/PD-L1 blockade. Both steroid and antibiotic therapies have been used by some to treat colitis associated with checkpoint inhibitors. The use of antibiotics to treat inhibitor-mediated colitis has been proven to be associated with an increased risk of severe ICI-mediated diarrhea and/or colitis.¹⁷ Caution is urged when considering antibiotic administration in the setting of immune-related colitis. Symptomatic treatment with antimotility agents is safe for non-severe colitis and diarrhea.¹⁸ Checkpoint inhibitor treatment discontinuation is recommended in the case of grade II or persistent grade I diarrhea.¹⁵ Corticosteroids are the typical management route for immune-related colitis. In the case of corticosteroid failure, the patient can be administered infliximab or other¹⁵ TNF inhibitors.⁴

Endocrine abnormalities

Thyroiditis should be given particular attention for routine laboratory monitoring because it is the most common irAE and initially clinically presents with a painless asymptomatic phase.^{19 20} The chances of contracting ICI-associated thyroiditis are increased if the patient has thyroid autoantibodies before treatment.⁴ Thyroid dysfunction in regard to ICIs begins with lymphocytes infiltrating the thyroid. This resembles Hashimoto thyroiditis.²¹ In ICI-mediated

thyroiditis, hyperthyroidism, hypothyroidism and thyroiditis are part of the same disease process.¹⁹ It begins as an early onset of thyroid hormone excess that is mostly asymptomatic; although it rarely progresses to thyrotoxicosis, it rapidly becomes hypothyroidism.¹⁹ Hypothyroidism is the most common manifestation of thyroiditis, as it is present in 3%–6% of patients following immunotherapy. Although because it is relatively easy to manage, it does not usually lead to discontinuation of therapy. Thyroidal irAEs typically develop within 6–12 weeks following immunotherapy but may develop quicker with the combination of anti-CTLA-4 and anti-PD-1 therapies.²⁰ If ICI-associated thyroiditis occurs, there is little risk to continuation of ICI therapy and the patient should simply undergo thyroid replacement treatment.⁴

Less common than thyroiditis but more concerning is pituitary hypophysitis. Common symptoms of hypophysitis include fatigue, headache and weakness, along with other non-specific symptoms. It may not be detected radiographically as the brain MRI may appear normal in some cases.²² A typical presentation on imaging however is that of pituitary stalk enlargement and pituitary enlargement.²³ Hypophysitis is an irAE that occurs much more commonly in CTLA-4-treated patients than in PD-L1 blockade. In 1698 treated patients across all tumor types, the number of patients who developed hypophysitis in response to PD-1/PD-L1 blockade was 11, for a total incidence of 0.65%. By contrast, in 920 CTLA-4-treated patients, we found that 28 had hypophysitis, for a total incidence rate of 3%. Hypophysitis is a rare complication in anti-PD-L(1)-treated individuals, and more likely in the case of anti-CTLA-4 treatment.⁴ Treatment plans should include hormone supplementation and initial high-dose corticosteroids.²⁴

Adrenal insufficiency is a very uncommonly reported immune-related endocrine side effect (<1% of cases).²⁵ In two randomized clinical trials authored by Herbst *et al*² and Antonia *et al*,²⁶ a total patient population of 780 patients were treated, while only 5 patients (0.64%) were reported to have adrenal insufficiency. Like most other endocrine insufficiency syndromes, treatment is largely centered around replacement of hormone deficiencies, typically with hydrocortisone in this case.

Hepatitis

Hepatitis associated with checkpoint inhibitors can be asymptomatic or can be manifested by fatigue, fever, jaundice and nausea.⁴ If ICI-related hepatitis is suspected, it is important to rule out other causes of liver injury, as abnormal liver function tests can be seen with progressive hepatic metastasis. Laboratory evaluation should include albumin and coagulation studies for assessment of synthetic function. For patients who are symptomatic and awaiting results of hepatic viral serologic testing, beginning steroid treatment while waiting for results is appropriate if the patient is compromised or if there is no other apparent cause of the ICI-related hepatitis symptoms.²⁷ Hepatitis encompasses 22% of anti-PD-1-related fatalities¹¹ and should be routinely monitored with each drug administration. Distinct histologic patterns have been noticed with anti-CTLA-4-associated hepatitis versus anti-PD-1/PD-L1-associated hepatitis. Anti-CTLA-4-associated hepatitis is

characterized by granulomatous hepatitis with fibrin ring granulomas and central vein endotheliitis, while anti-PD-1/PD-L1 hepatitis is characterized by lobular hepatitis.²⁸ On recognition of aspartate transaminase (AST) or alanine transaminase (ALT) greater than 3× the upper limit of normal, ICI therapy should be held and steroid therapy should be instituted, tapering when AST and ALT are improved. If there is recurrence after discontinuation of steroids or lack of response, the optimal second-line therapy is mycophenolate or azathioprine rather than TNF blockade owing to the increased risk of hepatic injury from TNF-based agents.²⁹

Dermatitis

While not usually severe, the dry skin, itching and flaking resulting from ICIs are among the most common complaints from treated patients. While multiple types of dermatitis can present following inhibitor treatment, the most commonly encountered histopathologic type of irAE biopsied by dermatologists is ICI-related lichenoid dermatitis,³⁰ detected in 50% of biopsy specimens from this population. Histologically it appears as band-like lymphocytic infiltrate in the papillary dermis with epidermal necrosis, and spongiotic dermatitis (40%) characterized by epidermal spongiosis with lymphocytic infiltrate surrounding the vessels of the superficial plexus with the presence of eosinophils.³¹ More severe is bullous skin disease, which is fortunately much less common but usually results in a need to permanently discontinue the ICI.

THERAPEUTIC APPROACHES TO IRAES

It is essential to recognize that ICI therapy for patients with lung cancer represents the only home for long-term remission for many of them. Thus, the diagnosis of an irAE should not be made in a cavalier fashion. Clinicians should have a low threshold for pathologic confirmation of irAE-associated changes in the liver, colon or lung before considering permanent discontinuation of ICI therapy.

Corticosteroids are first line for all the severe toxicities not amenable to topical therapy or simple hormone replacement. Starting doses are usually 1 mg/kg and therapy is continued until toxicity returns to grade 1. Drug tapering should be slow, over a 4-week period. In refractory cases, either when steroids are ineffective or cannot be tapered, substitutes for corticosteroids should be used, with TNF blockade being the most common second-line therapy, followed by purine synthesis inhibitors such as mycophenolate mofetil and azathioprine. Interleukin 6 (IL-6) blockade is usually reserved as a last resort for refractory cases. For the majority of patients, corticosteroids are sufficient management.^{13 32–35}

For patients who fail corticosteroid treatment, it is generally recommended that they undergo treatment with a TNF blockade such as infliximab. The exception to this is in the case of autoimmune hepatitis, in which it is not recommended due to risk of hepatic injury from this class of agents. In patients with liver toxicity, mycophenolate should be pursued. The use of infliximab can be seen in Shoushtari *et al*'s³⁶ melanoma trial, where 14 patients (22%) required infliximab for steroid-refractory diarrhea.

Purine synthesis inhibitors can be used as the next line of treatment. Data on the use of mycophenolate are also very

limited. Like infliximab, its use can be seen in Shoushtari *et al.*'s³⁶ melanoma trial, in which two patients (3%) required mycophenolate for steroid-refractory transaminitis. Severe hepatitis has been treated with mycophenolate in the case that it is persistent despite corticosteroid therapy, as TNF blockade is not permitted.

Early experience from small series demonstrates activity for IL-6 blockade. The use of tocilizumab can be seen in an article authored by Stroud *et al.*³⁷ In this paper, 87 patients were treated with nivolumab and 37 patients (39.1%) required the use of tocilizumab, with most of these patients being patients with lung cancer (88.2%). It is noted that all patients were on corticosteroids. Of the patients 52.9% required one dose of tocilizumab, but up to four doses were given when required. There was noted clinical improvement in 27 of 34 patients (79%). This article also recognizes the need for randomized trials for better understanding of the safety and efficacy of tocilizumab.³⁷

CONCLUSION

The use of ICIs as an alternative or addition to chemotherapy has revolutionized lung cancer treatment. It has provided an avenue for the immune system to perform its own attack on cancerous cells. With this ability to attack cancer cells comes the ability to attack one's own cells, requiring treating physicians to develop a new set of skills with regard to toxicity management. Fortunately, most oncologists are well versed in the use of steroids, which is all that most patients will ever need. It will be increasingly necessary for physicians who use ICI therapy to become routinely practiced with the use of TNF blockade agents, IL-6 and purine synthesis inhibitors, which until recently were not regularly used oncology drugs.

Unlike chemotherapy toxicity, with its predictable timing and focus on infectious risks, ICI-based toxicities are unpredictable in their timing. Hematology training, once an essential knowledge base for management of cancer drug toxicity, is gradually being supplanted by the need for rheumatology training. Medical oncology training programs should begin to increasingly leverage rheumatology faculty for education of their trainees. Attention to the impact of toxicity on cancer survivorship is something that should be encouraged by research funding agencies if we are to achieve the best outcomes for the increasing number of survivors generated by this exciting new class of drugs.

Acknowledgements Figure images were produced with the assistance of Biorender.com software.

Contributors Concept design, writing and editing were done by HEG and JN.

Funding This work was supported in part by the National Cancer Institute's USC/Norris Cancer Center Support Grant (P30 CA014089).

Competing interests HEG received personal fees AstraZeneca and Fujirebio and has equity interests in Cansera and Epic Sciences.

Patient consent for publication Not required.

Provenance and peer review Not commissioned; externally peer reviewed.

Open access This is an open access article distributed in accordance with the Creative Commons Attribution Non Commercial (CC BY-NC 4.0) license, which permits others to distribute, remix, adapt, build upon this work non-commercially, and license their derivative works on different terms, provided the original work is properly cited, an indication of whether changes were

made, and the use is non-commercial. See: <http://creativecommons.org/licenses/by-nc/4.0/>.

ORCID iD

Hannah Elizabeth Green <http://orcid.org/0000-0001-5066-4540>

REFERENCES

- 1 Reck M, Rodríguez-Abreu D, Robinson AG, *et al.* Pembrolizumab versus chemotherapy for PD-L1-positive non-small-cell lung cancer. *N Engl J Med* 2016;375:1823–33.
- 2 Herbst RS, Baas P, Kim D-W, *et al.* Pembrolizumab versus docetaxel for previously treated, PD-L1-positive, advanced non-small-cell lung cancer (KEYNOTE-010): a randomised controlled trial. *Lancet* 2016;387:1540–50.
- 3 Mok TSK, Wu Y-L, Kudaba I, *et al.* Pembrolizumab versus chemotherapy for previously untreated, PD-L1-expressing, locally advanced or metastatic non-small-cell lung cancer (KEYNOTE-042): a randomised, open-label, controlled, phase 3 trial. *Lancet* 2019;393:1819–30.
- 4 Chan KK, Bass AR. Autoimmune complications of immunotherapy: pathophysiology and management. *BMJ* 2020;369:m736.
- 5 Garon EB, Rizvi NA, Hui R, *et al.* Pembrolizumab for the treatment of non-small-cell lung cancer. *N Engl J Med* 2015;372:2018–28.
- 6 Inoue A, Kunitoh H, Sekine I, *et al.* Radiation pneumonitis in lung cancer patients: a retrospective study of risk factors and the long-term prognosis. *Int J Radiat Oncol Biol Phys* 2001;49:649–55.
- 7 Shaverdian N, Lisberg AE, Bornazyan K, *et al.* Previous radiotherapy and the clinical activity and toxicity of pembrolizumab in the treatment of non-small-cell lung cancer: a secondary analysis of the KEYNOTE-001 phase 1 trial. *Lancet Oncol* 2017;18:895–903.
- 8 Larsen BT, Chae JM, Dixit AS, *et al.* Clinical and histopathologic features of immune checkpoint inhibitor-related pneumonitis. *Am J Surg Pathol* 2019;43:1331–40.
- 9 Cui P, Huang D, Wu Z, *et al.* Association of immune-related pneumonitis with the efficacy of PD-1/PD-L1 inhibitors in non-small cell lung cancer. *Ther Adv Med Oncol* 2020;12:1758835920922033.
- 10 Su Q, Zhu EC, Wu J-B, *et al.* Risk of pneumonitis and pneumonia associated with immune checkpoint inhibitors for solid tumors: a systematic review and meta-analysis. *Front Immunol* 2019;10:108.
- 11 Wang DY, Salem J-E, Cohen JV, *et al.* Fatal toxic effects associated with immune checkpoint inhibitors: a systematic review and meta-analysis. *JAMA Oncol* 2018;4:1721–8.
- 12 Nishino M, Sholl LM, Hodi FS, *et al.* Anti-PD-1-related pneumonitis during cancer immunotherapy. *N Engl J Med* 2015;373:288–90.
- 13 Brahmer J, Reckamp KL, Baas P, *et al.* Nivolumab versus docetaxel in advanced squamous-cell non-small-cell lung cancer. *N Engl J Med* 2015;373:123–35.
- 14 Shieh AC, Guler E, Pfau D, *et al.* Imaging and clinical manifestations of immune checkpoint inhibitor-related colitis in cancer patients treated with monotherapy or combination therapy. *Abdom Radiol* 2020;45:3028–35.
- 15 Prieux-Klotz C, Dior M, Damotte D, *et al.* Immune checkpoint inhibitor-induced colitis: diagnosis and management. *Target Oncol* 2017;12:301–8.
- 16 Mitchell KA, Kluger H, Sznol M, *et al.* Ipilimumab-induced perforating colitis. *J Clin Gastroenterol* 2013;47:781–5.
- 17 Abu-Sbeih H, Herrera LN, Tang T, *et al.* Impact of antibiotic therapy on the development and response to treatment of immune checkpoint inhibitor-mediated diarrhea and colitis. *J Immunother Cancer* 2019;7:242.
- 18 Hryniewicki AT, Wang C, Shatsky RA, *et al.* Management of immune checkpoint inhibitor toxicities: a review and clinical guideline for emergency physicians. *J Emerg Med* 2018;55:489–502.
- 19 Iyer PC, Cabanillas ME, Waguespack SG, *et al.* Immune-related thyroiditis with immune checkpoint inhibitors. *Thyroid* 2018;28:1243–51.
- 20 Garon-Czmil J, Petitpain N, Rouby F, *et al.* Thyroiditis and immune checkpoint inhibitors: the post-marketing experience using the French national pharmacovigilance database. *Fundam Clin Pharmacol* 2019;33:241–9.
- 21 Caturegli P, De Remigis A, Rose NR. Hashimoto thyroiditis: clinical and diagnostic criteria. *Autoimmun Rev* 2014;13:391–7.
- 22 Chang L-S, Yialamas MA. Checkpoint inhibitor-associated hypophysitis. *J Gen Intern Med* 2018;33:125–7.
- 23 Valecha G, Pant M, Ibrahim U, *et al.* Immunotherapy-induced autoimmune hypophysitis. *J Oncol Pharm Pract* 2019;25:217–20.
- 24 Ileana-Dumbrava E, Subbiah V. Autoimmune hypophysitis. *Lancet Oncol* 2018;19:e123.
- 25 Hescot S, Haissaguerre M, Pautier P, *et al.* Immunotherapy-induced Addison's disease: a rare, persistent and potentially lethal side-effect. *Eur J Cancer* 2018;97:57–8.

- 26 Antonia SJ, López-Martin JA, Bendell J, *et al.* Nivolumab alone and nivolumab plus ipilimumab in recurrent small-cell lung cancer (CheckMate 032): a multicentre, open-label, phase 1/2 trial. *Lancet Oncol* 2016;17:883–95.
- 27 Spain L, Diem S, Larkin J. Management of toxicities of immune checkpoint inhibitors. *Cancer Treat Rev* 2016;44:51–60.
- 28 De Martin E, Michot J-M, Papouin B, *et al.* Characterization of liver injury induced by cancer immunotherapy using immune checkpoint inhibitors. *J Hepatol* 2018;68:1181–90.
- 29 Zhang HC, Luo W, Wang Y. Acute liver injury in the context of immune checkpoint inhibitor-related colitis treated with infliximab. *J Immunother Cancer* 2019;7:47.
- 30 Tetzlaff MT, Tang S, Duke T, *et al.* Lichenoid dermatitis from immune checkpoint inhibitor therapy: an immune-related adverse event with mycosis-fungoides-like morphologic and molecular features. *J Cutan Pathol* 2019;46:872–7.
- 31 Min Lee CK, Li S, Tran DC, *et al.* Characterization of dermatitis after PD-1/PD-L1 inhibitor therapy and association with multiple oncologic outcomes: a retrospective case-control study. *J Am Acad Dermatol* 2018;79:1047–52.
- 32 Rizvi NA, Mazières J, Planchard D, *et al.* Activity and safety of nivolumab, an anti-PD-1 immune checkpoint inhibitor, for patients with advanced, refractory squamous non-small-cell lung cancer (CheckMate 063): a phase 2, single-arm trial. *Lancet Oncol* 2015;16:257–65.
- 33 Gettinger S, Rizvi NA, Chow LQ, *et al.* Nivolumab monotherapy for first-line treatment of advanced non-small-cell lung cancer. *J Clin Oncol* 2016;34:2980–7.
- 34 Gettinger SN, Horn L, Gandhi L, *et al.* Overall survival and long-term safety of nivolumab (Anti-Programmed death 1 antibody, BMS-936558, ONO-4538) in patients with previously treated advanced non-small-cell lung cancer. *J Clin Oncol* 2015;33:2004–12.
- 35 Ott PA, Elez E, Hirt S, *et al.* Pembrolizumab in patients with extensive-stage small-cell lung cancer: results from the phase Ib KEYNOTE-028 study. *J Clin Oncol* 2017;35:3823–9.
- 36 Shoushtari AN, Friedman CF, Navid-Azarbaijani P, *et al.* Measuring toxic effects and time to treatment failure for nivolumab plus ipilimumab in melanoma. *JAMA Oncol* 2018;4:98–101.
- 37 Stroud CR, Hegde A, Cherry C, *et al.* Tocilizumab for the management of immune mediated adverse events secondary to PD-1 blockade. *J Oncol Pharm Pract* 2019;25:551–7.
- 38 Rittmeyer A, Barlesi F, Waterkamp D, *et al.* Atezolizumab versus docetaxel in patients with previously treated non-small-cell lung cancer (OAK): a phase 3, open-label, multicentre randomised controlled trial. *Lancet* 2017;389:255–65.
- 39 Fehrenbacher L, Spira A, Ballinger M, *et al.* Atezolizumab versus docetaxel for patients with previously treated non-small-cell lung cancer (poplar): a multicentre, open-label, phase 2 randomised controlled trial. *Lancet* 2016;387:1837–46.
- 40 Antonia SJ, Villegas A, Daniel D, *et al.* Durvalumab after chemoradiotherapy in stage III non-small-cell lung cancer. *N Engl J Med* 2017;377:1919–29.
- 41 Borghaei H, Paz-Ares L, Horn L, *et al.* Nivolumab versus docetaxel in advanced Nonsquamous non-small-cell lung cancer. *N Engl J Med* 2015;373:1627–39.
- 42 Govindan R, Szczesna A, Ahn M-J, *et al.* Phase III trial of ipilimumab combined with paclitaxel and carboplatin in advanced squamous non-small-cell lung cancer. *J Clin Oncol* 2017;35:3449–57.
- 43 Langer CJ, Gadgeel SM, Borghaei H, *et al.* Carboplatin and pemetrexed with or without pembrolizumab for advanced, non-squamous non-small-cell lung cancer: a randomised, phase 2 cohort of the open-label KEYNOTE-021 study. *Lancet Oncol* 2016;17:1497–508.