



Since January 2020 Elsevier has created a COVID-19 resource centre with free information in English and Mandarin on the novel coronavirus COVID-19. The COVID-19 resource centre is hosted on Elsevier Connect, the company's public news and information website.

Elsevier hereby grants permission to make all its COVID-19-related research that is available on the COVID-19 resource centre - including this research content - immediately available in PubMed Central and other publicly funded repositories, such as the WHO COVID database with rights for unrestricted research re-use and analyses in any form or by any means with acknowledgement of the original source. These permissions are granted for free by Elsevier for as long as the COVID-19 resource centre remains active.

# FELINE INFECTIOUS PERITONITIS

## ABCD guidelines on prevention and management



**Diane Addie, Sándor Belák, Corine Boucraut-Baralon, Herman Egberink, Tadeusz Frymus, Tim Gruffydd-Jones, Katrin Hartmann, Margaret J Hosie, Albert Lloret, Hans Lutz, Fulvio Marsilio, Maria Grazia Pennisi, Alan D Radford, Etienne Thiry, Uwe Truyen and Marian C Horzinek**

**Overview** Feline coronavirus infection is ubiquitous in domestic cats, and is particularly common where conditions are crowded. While most FCoV-infected cats are healthy or display only a mild enteritis, some go on to develop feline infectious peritonitis, a disease that is especially common in young cats and multi-cat environments. Up to 12% of FCoV-infected cats may succumb to FIP, with stress predisposing to the development of disease.

**Disease signs** The 'wet' or effusive form, characterised by polyserositis (abdominal and/or thoracic effusion) and vasculitis, and the 'dry' or non-effusive form (pyogranulomatous lesions in organs) reflect clinical extremes of a continuum. The clinical picture of FIP is highly variable, depending on the distribution of the vasculitis and pyogranulomatous lesions. Fever refractory to antibiotics, lethargy, anorexia and weight loss are common non-specific signs. Ascites is the most obvious manifestation of the effusive form.

**Diagnosis** The aetiological diagnosis of FIP ante-mortem may be difficult, if not impossible. The background of the cat, its history, the clinical signs, laboratory changes, antibody titres and effusion analysis should all be used to help in decision-making about further diagnostic procedures.

At the time of writing, there is no non-invasive confirmatory test available for cats without effusion.

**Disease management** In most cases FIP is fatal.

Supportive treatment is aimed at suppressing the inflammatory and detrimental immune response. However, there are no controlled studies to prove any beneficial effect of corticosteroids.

### Vaccination recommendations

At present, only one (intranasal) FIP vaccine is available, which is considered as being non-core. Kittens may profit from vaccination when they have not been exposed to FCoV (eg, in an early-weaning programme), particularly if they enter a FCoV-endemic environment.



### Virus properties

Feline coronavirus (FCoV) belongs to the family *Coronaviridae* of the order *Nidovirales*. These viruses are large, spherical, enveloped, positive-sense single-stranded RNA viruses. With a genome of 27–32 kb, encoding a replicase polyprotein, four structural proteins (spike [S], matrix [M], nucleocapsid [N] and envelope [E]) and several non-essential, non-structural proteins, coronaviruses possess the largest RNA genome known to date.<sup>1</sup>

Together with the enteric canine coronavirus and porcine transmissible gastroenteritis virus, FCoV belongs to the group I coronaviruses, as defined by their antigenic and genomic properties.

Serological and genomic properties have allowed FCoV to be assigned to two types, of which type I is most prevalent worldwide.<sup>2</sup> Type II virus results from recombination between type I FCoV and canine coronavirus.<sup>3</sup> Most research has focused on type II since it can be readily propagated *in vitro*.<sup>4</sup> Previously, FCoV strains have also been assigned to the 'biotypes' feline enteric coronavirus and feline infectious peritonitis virus,<sup>5</sup> but since all FCOVs may induce systemic infections, these terms should be avoided.

Feline coronavirus can survive for 7 weeks in a dry environment,<sup>6</sup> and may be transmitted indirectly (eg, via litter trays, shoes, hands and clothes), including at cat shows. However, FCoV is readily inactivated by most household detergents and disinfectants.

### Epidemiology

Feline coronavirus infection is ubiquitous in domestic cats, and wild felids may also be seropositive. Infection is particularly common where conditions are crowded (all cats may test seropositive), while the prevalence is lower in single pets.<sup>7–10</sup> About one in nine (12%) FCoV-infected cats go on to develop FIP, a

#### European Advisory Board on Cat Diseases

The European Advisory Board on Cat Diseases (ABCD) is a body of experts in immunology, vaccinology and clinical feline medicine that issues guidelines on prevention and management of feline infectious diseases in Europe, for the benefit of the health and welfare of cats. The guidelines are based on current scientific knowledge of the diseases and available vaccines concerned.

An extended version of the feline infectious peritonitis guidelines presented in this article is available at [www.abcd-vets.org](http://www.abcd-vets.org)



European Advisory Board on Cat Diseases  
[www.abcd-vets.org](http://www.abcd-vets.org)

Corresponding author: Dianne Addie  
Email: [draddie@btinternet.com](mailto:draddie@btinternet.com)





## Faeces are the main source of FCoV, with litter boxes representing the principal source of oral infection in groups of cats.

fatal disease that is most common in multi-cat environments [EBM grade III].<sup>8,11</sup>

Some breeds (eg, Bengals) and individual lines within breeds are more likely to succumb to FIP.<sup>12</sup> Age is an important risk factor, and 70% of cases are less than 1 year old.<sup>13,14</sup> However, the disease has been observed in cats 17 years of age; it may also be more likely in entire cats compared with neutered ones.<sup>12</sup>

Stress experienced by persistently FCoV-infected cats (eg, surgery, visit to a cattery, moving, co-infection with feline leukaemia virus), predisposes them to develop FIP.<sup>13</sup> Stress management is therefore an important part of control.

In breeding catteries, kittens usually become infected at a young age, mostly at 5–6 weeks, when maternally derived antibodies (MDA) have waned; however, infection at 2 weeks of age has also been detected.<sup>15</sup>

Faeces are the main source of FCoV, with litter boxes representing the principal source of oral infection in groups of cats. Since virus is rarely found in the saliva of healthy cats, it plays a minor role in groups with close contact or when sharing feeding bowls.<sup>16</sup> Transplacental transmission has been described from a queen that developed the disease during pregnancy,<sup>17</sup> but is very rare.<sup>18</sup>

Susceptible cats are most likely to be infected following contact with FCoV in faeces from asymptomatic cats. Although transmission from FIP cases may occur, this usually does not lead to disease under natural conditions; however it has been demonstrated experimentally.

After natural infection, cats begin to shed virus in the faeces within 1 week and continue to shed for weeks, months, and a few even for life (also called carriers).<sup>2,16,19</sup> Faecal excretion may reach high levels and appears to be continuous.<sup>2,16,19</sup>

### Pathogenesis

Most FCoV-infected cats either stay healthy or show only a mild enteritis. Only a proportion of FCoV-infected cats will develop FIP, a pyogranulomatous vasculitis.<sup>5,28</sup>

The pathogenesis of FIP may be explained by an increased number of mutants, stochastically arising during bursts of replication (eg, under immune suppression), some of them growing to high concentrations in monocytes and macrophages.<sup>21–23</sup> Mutations have been

identified in non-structural genes, and more may remain to be identified. These highly virulent FCoV mutants have consistently induced FIP under experimental conditions, but their virulence has not been traced to a molecular source.<sup>24,25</sup> The viral load and the cat's immune response determine whether FIP will develop. Both viral genetics and host immunity are likely to play a role in the development of FIP.<sup>23,26,27</sup>

The pathology of FIP has been classified into two forms: an effusive (wet) FIP characterised by polyserositis (eg, thoracic and abdominal effusion) (Fig 1) and vasculitis, and a non-effusive (dry) FIP characterised by granulomatous lesions in organs (Fig 2).<sup>28</sup> These two forms reflect clinical extremes of a continuum. An uncommon enteric form described in young cats with diarrhoea and vomiting was associated with nodular intestinal pyogranulomatous lesions.<sup>29</sup>



## Susceptible cats are most likely to be infected following contact with FCoV in faeces from asymptomatic cats.

### EBM ranking used in this article

Evidence-based medicine (EBM) is a process of clinical decision-making that allows clinicians to find, appraise and integrate the current best evidence with individual clinical expertise, client wishes and patient needs (see Editorial on page 529 of this special issue, doi:10.1016/j.jfms.2009.05.001).

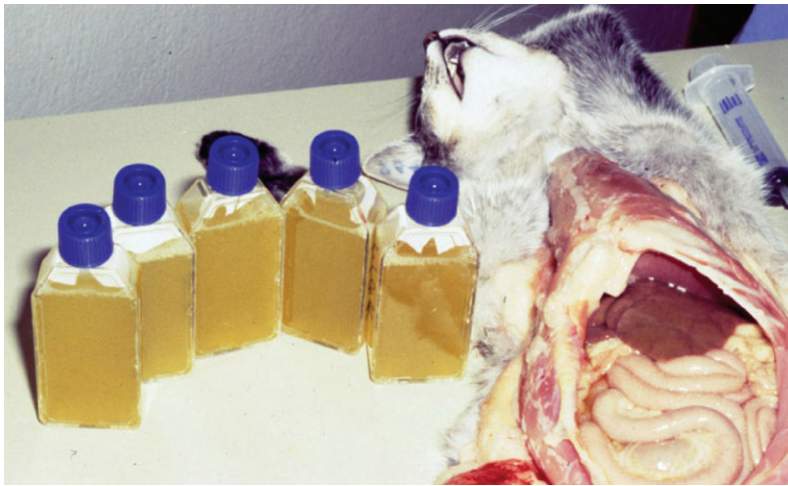This article uses EBM ranking to grade the level of evidence of statements in relevant sections on epidemiology, diagnosis, disease management and control, as well as vaccination. Statements are graded on a scale of I to IV as follows:

- ✦ **EBM grade I** This is the best evidence, comprising data obtained from properly designed, randomised controlled clinical trials in the target species (in this context cats);
- ✦ **EBM grade II** Data obtained from properly designed, randomised controlled studies in the target species with spontaneous disease in an experimental setting;
- ✦ **EBM grade III** Data based on non-randomised clinical trials, multiple case series, other experimental studies, and dramatic results from uncontrolled studies;
- ✦ **EBM grade IV** Expert opinion, case reports, studies in other species, pathophysiological justification. **If no grade is specified, the EBM level is grade IV.**

#### Further reading

Roudebush P, Allen TA, Dodd CE, Novotny BJ. Application of evidence-based medicine to veterinary clinical nutrition. *J Am Vet Med Assoc* 2004; **224**: 1765–71.



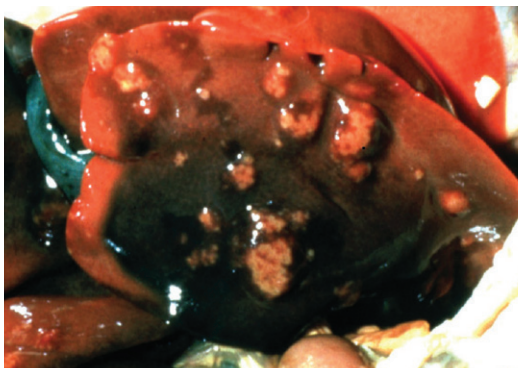


**FIG 1** Effusive form of feline infectious peritonitis showing the huge amount of effusion present in some cases. Courtesy of Merial

The form that a cat develops is thought to depend on the strength of the T cell-mediated response, which is probably the only efficient immune response against disease progression.<sup>5,21</sup> Progression of the infection to FIP may be the consequence of severe immunodepression by T cell depletion.<sup>30</sup> The wet forms are presumed to arise as a consequence of weak cell-mediated immune responses.<sup>5</sup>

Attempts to identify a tissue distribution of FCoV that is diagnostic for FIP have been fruitless. In cats with FIP, virus replicates to high titres in monocytes and can be found in many organs.<sup>28,32</sup> In asymptomatic cats, FCoV is mainly confined to the intestine. However, a low level monocyte-associated viraemia can sometimes also be detected in healthy animals by reverse-transcriptase PCR (RT-PCR).<sup>31,75</sup> A significant difference in viral replication in haemolymphatic tissues has been demonstrated between cats that died from FIP and healthy long-term carriers.<sup>32</sup>

Monocytes and macrophages remain infected in the presence of high antibody levels. The mechanism of this immune evasion could be an escape from antibody-dependent lysis due to the absence of viral antigens on the surface of infected cells.<sup>22,33</sup> The direct consequence may be a quiescent infection state and long incubation period. When monocytes and



**FIG 2** Dry form of feline infectious peritonitis showing granulomatous lesions on the liver. Courtesy of Merial

perivascular macrophages are activated, the typical widespread pyogranulomatous and vasculitis/perivasculitis lesions may develop in the kidneys, mesenteric lymph nodes, lungs, liver, spleen, omentum and brain of cats with FIP.<sup>28</sup>

## Immunity

It has been suggested that cats mounting a strong cell-mediated immune response do not develop FIP, whereas cats showing a predominantly humoral response progress to disease.<sup>5</sup> Hypergammaglobulinaemia is common in cats with FIP.<sup>34,51,54</sup> Also, a drastic depletion of T cells from blood and lymphoid tissues has been described.<sup>30,35</sup>

### Passive immunity

Maternally derived antibodies usually provide protection until about 5–6 weeks of age.<sup>8</sup> Levels decline and become undetectable by 6–8 weeks of age.

### Active immune response

❖ **Cell-mediated immunity** Cats that stayed healthy after experimental FCoV infection have been shown to display a better cell-mediated immune response than those that progressed to FIP.<sup>30</sup>

❖ **Humoral immunity** The role of humoral immunity in protecting against FIP is ambiguous. Clearance of natural infections has been associated with antibodies directed against the FCoV S protein.<sup>36</sup> Conversely, antibodies directed against the S protein can be detrimental. In cats with pre-existing antibodies, ‘antibody-dependent enhancement’ has been observed experimentally, resulting in a shortened disease course and earlier death. This enhancement was observed irrespective of whether cats had acquired antibodies through passive or active immunisation.<sup>37–39</sup> However, pre-existing antibody is not a precondition; in field studies cats developed FIP on first exposure to FCoV.<sup>2,40</sup>

## Clinical signs

The clinical picture of FIP is highly variable, reflecting the variability in the distribution of the vasculitis and pyogranulomatous lesions.

The distinction between effusive and non-effusive (wet and dry) forms of FIP is of some value in recognising the clinical presentations; however, although it may contribute to diagnosis, there is considerable overlap between the two forms.

Fever that is refractory to antibiotics, lethargy, anorexia and weight loss are common

non-specific signs but occasional cases remain bright and retain body condition; lesions compatible with FIP pathology have also been found incidentally in healthy cats undergoing abdominal surgery.

Ascites is the most obvious manifestation of the effusive form (Figs 3 and 4).<sup>41</sup> Thoracic and pericardial effusion may occur. In some cats, effusion is restricted to the thorax and these cases usually present with dyspnoea. Serositis can involve the tunica vaginalis of the testes, leading to scrotal enlargement. Non-effusive FIP is often more difficult to diagnose. Fever, anorexia and lethargy may be the only signs, particularly in the early stages of disease.

More specific signs will depend on the organs affected by the vasculitis and pyogranulomatous lesions, commonly the abdominal organs. Renal involvement (Fig 5) may lead to renomegaly, which is detectable on palpation. Mural lesions in the colon or ileocaecocolic junction occasionally occur and may be associated with chronic diarrhoea and vomiting. There may also be palpable enlargement of the mesenteric lymph nodes, which potentially may be misinterpreted as neoplasia.<sup>42</sup> A diffuse pyogranulomatous pneumonia is seen in some cases, leading to severe dyspnoea.<sup>43</sup>

Ocular involvement with uveitis is common (Fig 6), leading to changes in iris colour, dyscoria or anisocoria secondary to iritis,<sup>44</sup> sudden loss of vision and hyphaema (Fig 7). Keratic precipitates may appear as 'mutton fat' deposits on the ventral corneal endothelium (Fig 8). The iris may show swelling and a nodular surface, and aqueous flare may be detected. On ophthalmoscopic examination,

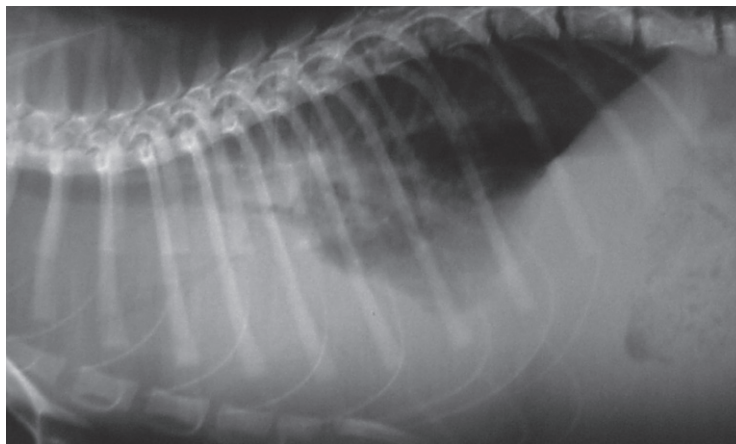


FIG 3 Radiograph of a cat with effusive feline infectious peritonitis showing thoracic and abdominal effusion. Courtesy of Albert Lloret



FIG 4 Cat with feline infectious peritonitis showing a distended abdomen due to fluid accumulation. Purebred cats (like this Sphinx) seem to be affected more commonly by the disease. Courtesy of Hannah Dewerchin, Ghent University

chorioretinitis, fluffy perivascular cuffing (representing retinal vasculitis), dull perivascular puffy areas (pyogranulomatous chorioretinitis), linear retinal detachment and fluid blistering under the retina may be seen (Fig 9).

Neurological signs are reported in at least 10% of cats with FIP.<sup>13,45</sup> They reflect focal, multifocal or diffuse involvement of the brain, spinal cord and meninges.<sup>46</sup> The most commonly reported signs are ataxia, hyperaesthesia, nystagmus, seizures, behavioural changes and cranial nerve deficits.<sup>45,47</sup>

Cutaneous signs – multiple nodular lesions caused by pyogranulomatous-necrotising dermal phlebitis and skin fragility – have recently been reported.<sup>48,49</sup>

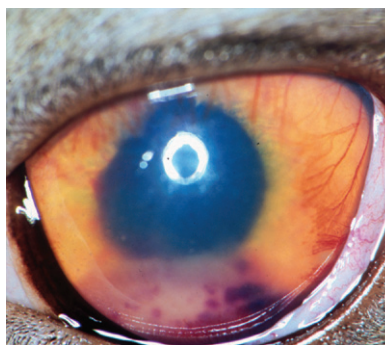


FIG 6 Uveitis in a cat with the dry form of feline infectious peritonitis. Courtesy of Eric Déan

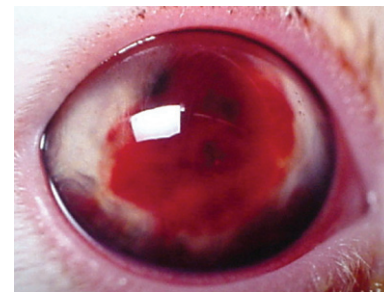


FIG 7 Hyphaema in a cat developing feline infectious peritonitis. Courtesy of Albert Lloret

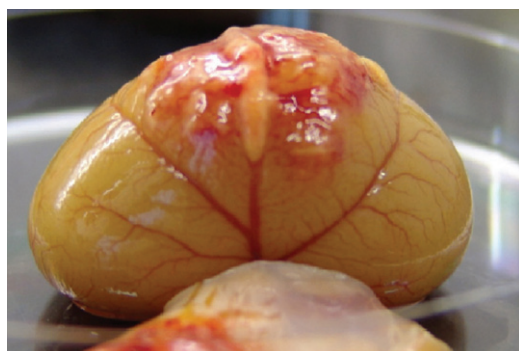

FIG 5 Vasculitis and granulomatous lesions on the kidneys of a cat with feline infectious peritonitis. Courtesy of Hannah Dewerchin, Ghent University

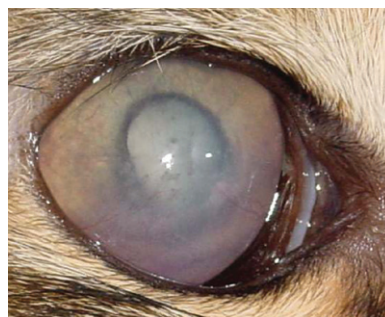

FIG 8 Ocular lesions and keratic precipitates in a Maine Coon with feline infectious peritonitis. Courtesy of Andy Sparkes

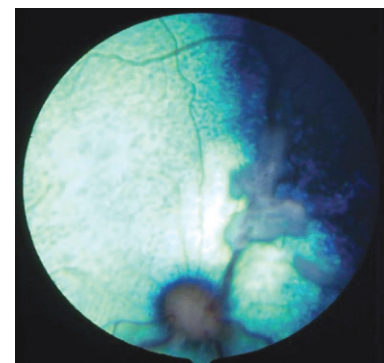


FIG 9 Marked perivascular retinal exudate in a 2-year-old Birman with feline infectious peritonitis. Courtesy of Andy Sparkes and Sheila Crispin



## Diagnosis

Aetiological diagnosis of FIP ante-mortem may be difficult, if not impossible, because of the invasiveness of taking biopsies from a sick cat. Currently, there is no non-invasive confirmatory test available for cats without effusion. Effusions should first be looked for, because their analysis is very useful and they can be obtained relatively non-invasively. The background of the cat, its history, the clinical signs, laboratory changes and antibody titres should all be used to help in decision-making about further diagnostic procedures.<sup>13</sup>

### Haematology

Haematology profiles are often altered in cats with FIP. White blood cell counts can be either decreased or increased. Lymphopenia is common; but lymphopenia in combination with neutrophilia, known as a 'stress leukogram', can occur in many other diseases. However, a normal lymphocyte count makes FIP unlikely. A mild to moderate non-regenerative anaemia is also a common finding, but may occur in almost any chronic disease of the cat.

A common laboratory finding is an increase in total serum protein concentration caused mainly by a rise in gamma globulins.<sup>50</sup> Hyperglobulinaemia was found in around 50% of cats with effusion and about 70% of cats without effusion.<sup>51</sup> After experimental infection, an early increase in alpha-2 globulins was seen, while gamma globulins and antibody titres increased just before the onset of clinical signs.<sup>52,53</sup> Serum total protein levels can reach concentrations of  $\geq 120$  g/l (12 g/dl).

The albumin/globulin ratio has a higher diagnostic value than either total serum protein or gamma globulin concentrations, because if the liver is affected, both albumin and globulin will decrease.<sup>13,54</sup> Although viral antigen has not been found in the glomeruli of cats with FIP,<sup>55</sup> it is hypothesised that low albumin is usually associated with protein loss caused by glomerulopathy secondary to immune complex deposition, or by extravasation of protein-rich fluid during vasculitis. An optimum cut-off value of 0.8 has been determined for the albumin/globulin ratio, above which FIP is extremely unlikely [EBM grade I].<sup>54,56</sup> Serum protein electrophoresis may reveal both polyclonal and monoclonal hypergammaglobulinaemia as well as an increase in acute phase proteins.

Liver enzymes, urea and creatinine can all be elevated, depending on the degree and site of organ damage, but are generally not useful in establishing a diagnosis. Hyperbilirubinaemia and icterus are frequent and often reflect hepatic necrosis.<sup>54</sup> High bilirubin levels in the absence of haemolysis and elevation of

liver enzyme activity should raise the suspicion of FIP. High serum alpha-1 acid glycoprotein (AGP) levels ( $>1500$   $\mu\text{g/ml}$ ) may support the diagnosis,<sup>57</sup> but levels are also high in other inflammatory conditions. Additionally, AGP levels may be high in healthy cats infected with FCoV, especially in households where the infection is endemic.<sup>58</sup>

### Tests on effusion fluid

If there is effusion, a sample must be obtained, because tests on effusions have a higher diagnostic value than blood tests. However, only about half of cats with effusion suffer from FIP.<sup>59</sup> Although effusions of clear yellow colour and sticky consistency are often called 'typical', their presence alone in body cavities is not diagnostic. Sometimes the fluid has a different appearance and cases with pure chylous effusion have been reported.<sup>60</sup> Usually, the protein content is very high ( $>35$  g/l), consistent with that of an exudate, whereas the cellular content is low ( $<5000$  nucleated cells/ml) and approaches that of a modified or pure transudate. Cytology of the effusion in cats with FIP is variable but usually consists predominantly of macrophages and neutrophils. Electrophoresis is a diagnostic tool with a high positive predictive value if the albumin/globulin ratio is  $<0.4$ , and a high negative predictive value if the ratio is  $>0.8$ .<sup>56</sup> Major differential diagnoses include inflammatory liver disease, lymphoma, heart failure and bacterial peritonitis or pleuritis.

'Rivalta's test' is a simple, inexpensive method that can be performed in clinical practice to distinguish transudates from exudates.

### Rivalta's test

Rivalta's test is useful for differentiating between FIP effusions and effusions caused by other diseases [EBM grade I].<sup>54</sup> Not only the high protein content, but also high concentrations of fibrinogen and inflammatory mediators, lead to a positive reaction.

The test has a positive predictive value of 86%, and a high negative predictive value of 96% for FIP, as determined by a study of cats that presented with effusion (prevalence of FIP, 51%).<sup>54</sup>

Positive Rivalta's test results may also be obtained in cats with bacterial peritonitis or lymphoma. However, it is usually easy to differentiate these effusions by macroscopic examination, cytology and/or bacterial culture.

To perform the test, a transparent reagent tube (volume 10 ml) is filled with 7–8 ml distilled water, and one drop of acetic acid (98%) is added and mixed thoroughly. One drop of the effusion fluid is carefully layered onto the surface of this solution. If the drop disappears and the solution remains clear, the Rivalta's test is defined as negative. If the drop retains its shape, stays attached to the surface or slowly floats down to the bottom of the tube (drop- or jellyfish-like), the test is defined as positive.



## A high percentage of healthy cats are FCoV antibody-positive and most of them will never develop FIP. Thus, the presence of antibodies does not indicate FIP and their absence does not exclude FIP.

### Cerebrospinal fluid analysis

Analysis of cerebrospinal fluid (CSF) from cats with neurological signs due to FIP lesions may reveal elevated protein (50–350 mg/dl; normal value <25 mg/dl) and pleocytosis (100–10,000 nucleated cells/ml) with mainly neutrophils, lymphocytes and macrophages. However, this is not diagnostic.<sup>46</sup> In many cats with FIP that have neurological signs, the CSF is normal.

### Antibody detection

Serum antibody titres may contribute diagnostic information, if interpreted with care. A high percentage of healthy cats are FCoV antibody-positive and most of them will never develop FIP. Thus, the presence of antibodies does not indicate FIP and their absence does not exclude FIP. It has been contended that more cats have been killed as a result of false interpretation of FCoV antibody test results than by the disease itself. There is no 'FIP antibody test' – all that can be measured is antibody against FCoV.

Methodology (and titres) may vary considerably between laboratories. Low titres do not rule out FIP, and a significant proportion of cats manifesting FIP are seronegative. In cats with fulminant FIP, titres may decrease terminally because the high virus loads in the cat's body bind antibody, forming immune complexes. Very high titres can be of (limited) diagnostic value since they indicate an increased likelihood of FIP.<sup>52,54</sup>

### FCoV reverse-transcriptase PCR

The RT-PCR to detect FCoV in blood is sometimes used diagnostically. However, the assay cannot diagnose FIP: positive FCoV RT-PCR results have also been obtained in healthy carriers that did not develop FIP for a period of some 70 months [EBM grade I].<sup>31,61</sup> In addition, negative FCoV RT-PCR results are not uncommon in cats with FIP.<sup>54</sup>

### Immunostaining of FCoV antigen in macrophages

Methods of virus detection include the demonstration of FCoV antigen in macrophages in effusions by immunofluorescence,<sup>54,62</sup> or in tissue samples by immunohistochemistry. While FCoV may be present systemically in healthy cats, only in FIP cases will there be sufficient viral antigen in macrophages to result in positive staining. Positive staining of intra-

**Diagnostic strategies**  
In essence there are two strategies to obtain a laboratory diagnosis of FIP. If there is effusion, positive immunofluorescence staining of macrophages present is conclusive. If there is no effusion, tissue samples of affected organs have to be obtained and processed for immunohistochemical staining. A diagnostic algorithm is shown on page 600.



cellular FCoV antigen in macrophages in effusions can be 100% predictive of FIP, versus a negative predictive value of 57%; this discrepancy is explained by low numbers of macrophages in effusion smears.<sup>54</sup>

Immunohistochemistry has been used to detect FCoV antigen, and it was also 100% predictive of FIP when positive.<sup>63</sup> However, invasive methods (eg, laparotomy or laparoscopy) are usually necessary to obtain the tissue samples.

### Disease management

Any cat in a hospital is a potential source of FCoV infection, and routine hygiene measures must be taken. Any FIP case will shed FCoV and precautions to avoid infection of other cats are particularly important. However, in a multi-cat household, the other cats will probably already have been exposed to the FCoV from the patient, so there is no benefit in isolating the patient.

In households where a single FIP patient has been euthanased, it is recommended to wait for 2 months before obtaining a new cat, to allow environmental FCoV to die off. If there are other cats in that household, they are likely to carry FCoV. Before introducing a new cat into that environment, the FCoV infection status of both existing and new cats should be established,<sup>26,73</sup> and the number of cats per floor space, their age, social compatibility and other factors likely to influence their behavioural interactions must be considered.

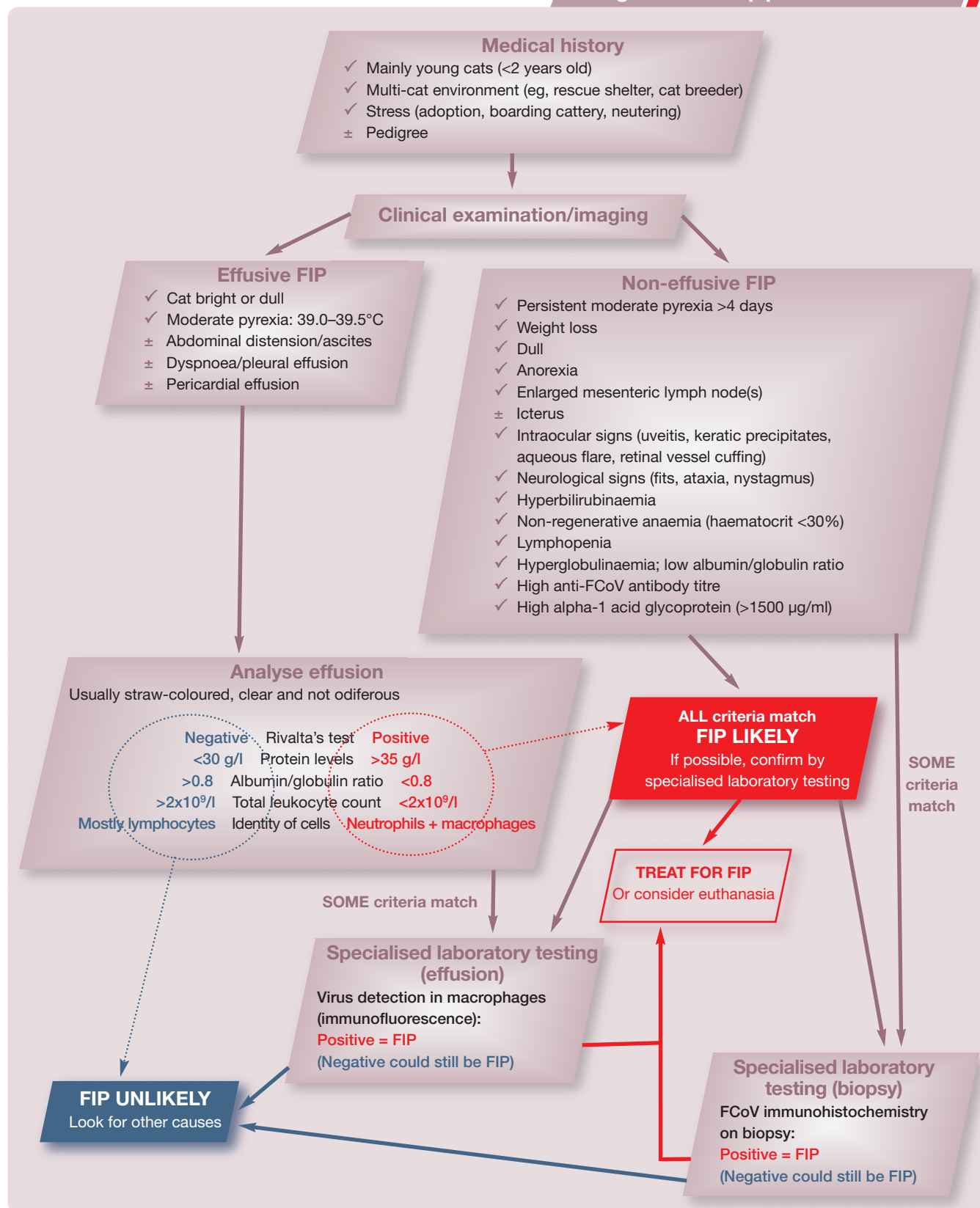
### Treatment

Treatment (or euthanasia) should only be considered after every effort has been made to obtain a definitive diagnosis. Feline infectious peritonitis is fatal in most cases. There have been occasional reports of cats surviving for several months after diagnosis.<sup>64</sup> However, few controlled field studies have been published. In one placebo-controlled study of treatment with feline interferon-omega, no benefit was observed [EBM grade I].<sup>65</sup> Other drugs

**Prognosis**  
The prognosis for cats with FIP is poor: the median survival after diagnosis is around 9 days.<sup>65</sup> Factors that indicate a short survival time are low lymphocyte counts, high bilirubin values, and large volumes of effusion. Cats that do not improve within 3 days are unlikely to show any benefit from treatment and euthanasia should be considered.



Diagnostic approach to FIP



have been tried (Table 1), but these studies were not properly controlled.

Supportive treatment is aimed at suppressing the inflammatory and detrimental immune

response, usually with corticosteroids. However, there are no controlled studies to prove any beneficial effect of corticosteroids, only anecdotal reports [EBM grade III].



**TABLE 1** Drugs that have been suggested for use in FIP cases

Drug	Comments	ABCD recommendation [EBM grade*]
<b>ANTIVIRALS</b>		
Ribavirin	Works in vitro but toxic in cats	Not recommended [II]
Vidarabine	Works in vitro but toxic in cats	Likely ineffective [IV]
Human interferon-alpha – SC high dose	Although human interferon-alpha has in vitro effects on FCoV, SC treatment did not work in an experimental trial	Ineffective [I]
Human interferon-alpha – PO low dose	No trials Only acts as immune stimulant if given orally Immune stimulation should be avoided in cats with FIP	Contraindicated [IV]
Feline interferon-omega	One placebo-controlled study of naturally occurring cases and one uncontrolled study	No benefit was observed [grade I study]; may require further studies in view of anecdotal clinical evidence [IV]
<b>IMMUNOSUPPRESSANTS</b>		
Prednisolone/dexamethasone – immunosuppressive doses	No controlled studies. Some cats have improved during treatment and survived for several months, but does not cure FIP	Currently supportive treatment of choice [III] If effusion is present, dexamethasone IT or IP may help
Pentoxifylline	Aimed at treating the vasculitis Some veterinarians in practice have tried this treatment, but there are no published studies or case reports	Requires studies [IV]
Ozagrel hydrochloride	Thromboxane synthesis inhibitor aimed at treating the inflammatory response. Only used in two cases with beneficial effect	Controlled studies needed [III]
Ciclosporin A	Aimed to immunosuppress (lower the corticosteroid dose). No published studies	Not recommended because directed more at cellular immunity than humoral (lack of data) [IV]
Cyclophosphamide	Aimed to immunosuppress (lower the corticosteroid dose). No published studies	Might be considered in combination with glucocorticoids [IV]
Chlorambucil	Aimed to immunosuppress (lower the corticosteroid dose). No published studies	Might be considered in combination with glucocorticoids [IV]
Azathioprine	Toxic in cats (!) Aimed to immunosuppress (lower the corticosteroid dose). No published studies	Not recommended [IV]
Salicylic acid (aspirin) – platelet inhibitory dosage	Aimed at treating the inflammatory response as well as the vasculitis. No published studies	May have some beneficial effect, but side effects possible if used in combination with high steroid doses
*For explanation of EBM grades, see box on page 595. SC = subcutaneous, PO = oral, IP = intraperitoneal, IT = intrathoracic		

## Vaccination

At present there is only one FIP vaccine available, which the ABCD considers as being non-core (see box on page 602).

## Disease control in specific situations

Feline infectious peritonitis is a problem in cats kept in groups, particularly in breeding catteries and rescue situations. Since the virus is transmitted predominantly via the faecal–oral route, hygiene is most important. Feline coronavirus infection is maintained in a household or cattery by continual cycles of infection and re-infection, the source of infection being the litter tray.<sup>2,46</sup> Rarely is FIP a problem among cats leading an indoor–outdoor lifestyle. Reduction of FCoV

contamination and risk of transmission can be achieved by avoiding large numbers of cats in individual households, keeping groups of  $\leq 3$  (well-adapted) cats per room, observing strict hygiene, and providing outdoor access to allow the cats to bury their faeces. Otherwise, sufficient litter trays should be provided, cleaned frequently, and kept in different rooms from the food bowls.

### Breeding catteries

Breeding catteries are high-risk environments for FIP. In most European countries there are few catteries where FCoV is not endemic. In some, attempts have been made to control viral spread by segregation. A policy of separating high FCoV shedders from low shedders and negative cats has been suggested for reducing transmission rates,<sup>26,73</sup> but the value

of this approach is controversial. Shedders can be detected using real-time quantitative RT-PCR screening of faeces, but multiple sampling is necessary. Virus shedding occurs over several months and is sometimes lifelong, especially in multi-cat households.<sup>2,16,19</sup>

Kittens typically develop FIP in the post-weaning period.<sup>74</sup> Breeders are often unaware of an endemic FCoV infection, because FIP deaths usually occur when the kittens have left the cattery and are in a new household. Most kittens are protected from FCoV infection by MDA until they are 5–6 weeks of age. Feline coronavirus transmission has been prevented by isolating pregnant queens 2 weeks before birth, moving their kittens to a clean environment when they are 5–6 weeks old, and maintaining them there until they go to a new home.<sup>8,26</sup> For this method to succeed, the breeder is required to follow strict quarantine hygiene methods, which require special knowledge and facilities. The efficacy of this method has been questioned.<sup>15</sup>

### Rescue and boarding catteries

Strict hygiene precautions must be enforced at all times to minimise viral spread and virus contamination. Ideally, cats should be kept separately. New catteries should be designed with infectious disease control and stress reduction as priorities. Vaccination may be considered for cats that are unlikely to have experienced FCoV infection before entering a boarding or rescue cattery.

### Acknowledgements

The European Advisory Board on Cat Diseases (ABCD) is indebted to Dr Karin de Lange for her judicious assistance in organising this special issue, her efforts at coordination, and her friendly deadline-keeping. The tireless editorial assistance of Christina Espert-Sanchez is gratefully acknowledged. The groundwork for this series of guidelines would not have been possible without financial support from Merial. The ABCD particularly appreciates the support of Dr Jean-Christophe Thibault, who respected the team's insistence on scientific independence.

### References

- de Vries AAF, Horzinek MC, Rottier PJM, de Groot RJ. The genome organization of the nidovirales: similarities and differences between arteri-, toro-, and coronaviruses. *Semin Virol* 1997; **8**: 33–47.
- Addie DD, Schaap IA, Nicolson L, Jarrett O. Persistence and transmission of natural type I feline coronavirus infection. *J Gen Virol* 2003; **84**: 2735–44.
- Herrewegh AA, Smeenk I, Horzinek MC, Rottier PJ, de Groot RJ. Feline coronavirus type II strains 79-1683 and 79-1146 originate from a double recombination between feline coronavirus type I and canine coronavirus. *J Virol* 1998; **72**: 4508–14.
- Pedersen NC, Evermann JF, McKeirnan AJ, Ott RL. Pathogenicity studies of feline coronavirus isolates 79-1146 and 79-1683. *Am J Vet Res* 1984; **45**: 2580–85.
- Pedersen NC. Virologic and immunologic aspects of feline infectious peritonitis virus infection. *Adv Exp Med Biol* 1987; **218**: 529–50.
- Scott FW. Update on FIP. Proceedings of the 12th Kal Kan Symposium, 1988: 43–7.
- Horzinek MC, Osterhaus AD. Feline infectious peritonitis: a world-wide serosurvey. *Am J Vet Res* 1979; **40**: 1487–92.
- Addie DD, Jarrett O. A study of naturally occurring feline coronavirus infection in kittens. *Vet Rec* 1992; **130**: 133–37.
- Addie DD. Clustering of feline coronaviruses in multicat households. *Vet J* 2000; **159**: 8–9.
- Herrewegh AA, de Groot RJ, Cepica A, Egberink HF, Horzinek MC, Rottier PJ. Detection of feline coronavirus RNA in feces, tissues, and body fluids of naturally infected cats by reverse transcriptase PCR. *J Clin Microbiol* 1995; **33**: 684–89.
- Addie DD, Toth S, Murray GD, Jarrett O. The risk of feline infectious peritonitis in cats naturally infected with feline coronavirus. *Am J Vet Res* 1995; **56**: 429–34.
- Pesteanu-Somogyi LD, Radzai C, Pressler BM. Prevalence of feline infectious peritonitis in specific cat breeds. *J Feline Med Surg* 2006; **8**: 1–5.

## Vaccination

### General considerations

Many attempts have been made to develop an FIP vaccine, most of which failed, with antibody-dependent enhancement of infection observed experimentally and resulting in more vaccinated than control cats developing FIP. At present there is only one vaccine, available in the USA and in some European countries. It is administered intranasally and contains a temperature-sensitive mutant of the type II FCoV strain DF2; type I coronaviruses are, however, more prevalent in the field.<sup>2,16</sup>

Results from experimental studies have been inconsistent, with preventable fractions between 0 and 75%.<sup>66–69</sup> The results of field studies have been equally contradictory.<sup>70–72</sup> The not unexpected conclusion is that this vaccine might not be effective in seropositive cats that have already been exposed to FCoV. The antibody-dependent enhancement of infection that was a feature of some experimental vaccine trials has not been observed in field studies, suggesting that the vaccine can be considered safe.<sup>70–72</sup>

### Primary course

The ABCD considers the FIP vaccine to be non-core. Kittens may profit from vaccination if they have not been exposed to FCoV (eg, in an early-weaning programme), particularly if they enter an FCoV-endemic environment.

If immunisation is considered, a primary vaccination course consisting of two doses 3 weeks apart from the age of 16 weeks onwards should be followed. Vaccination before 16 weeks has been shown not to protect against infection.<sup>15</sup> In breeding catteries, most kittens are already seropositive by the time of vaccination, FCoV infections occurring much earlier than at 16 weeks of age.<sup>8,15,19</sup>

### Booster vaccinations

Where a cat's lifestyle has justified primary vaccination, annual boosters may be considered. Although studies on the duration of immunity are lacking, it is thought to be short-lived.

#### Non-core vaccine

The ABCD considers the FIP vaccine as being non-core.



**KEY POINTS**

- ❖ Feline infectious peritonitis (FIP) is caused by feline coronavirus (FCoV), which is ubiquitous in domestic cats.
- ❖ Only a proportion of infected cats develops FIP.
- ❖ Stress (adoption, neutering, boarding) predisposes cats to FIP.
- ❖ FIP is especially common in young cats and in multi-cat environments.
- ❖ Faeces are the main source of infection.
- ❖ After infection, cats start shedding the virus within 1 week and continue to shed for weeks or months, sometimes even for life.
- ❖ Two forms of FIP are described:
  - an effusive (wet) form, characterised by polyserositis (ascites, thoracic and/or pericardial effusion) and vasculitis;
  - a non-effusive (dry) form, characterised by granulomatous lesions in various organs (renomegaly, chronic diarrhoea, lymph node enlargement).
 The two forms represent the clinical extremes of a continuum.
- ❖ Ocular signs include uveitis, keratic precipitates, chorioretinitis, retinal perivascular cuffing and pyogranulomatous chorioretinitis.
- ❖ Neurological signs (seen in at least 10% of cats with FIP) include ataxia, hyperaesthesia, nystagmus, seizures, behavioural changes and cranial nerve deficits.
- ❖ Haematology suggestive of FIP shows lymphopenia, non-regenerative anaemia, increased total serum protein, hyperglobulinaemia, a low albumin/globulin ratio, high alpha-1 acid glycoprotein levels and high FCoV antibody titres.
- ❖ Effusion suggestive of FIP reacts positively to Rivalta's test, has high protein levels and a low albumin/globulin ratio, and contains neutrophils and macrophages.
- ❖ The prognosis for cats with FIP is poor. The median survival time after diagnosis is around 9 days.
- ❖ Euthanasia should only be considered after every effort has been made to obtain a definitive diagnosis.
- ❖ FIP is a problem in group-housed cats (breeding and rescue catteries), and is rarely encountered in cats leading an indoor-outdoor lifestyle.
- ❖ At present, there is only one (intranasal) vaccine, available in the USA and in some European countries.



- 13 Rohrer C, Suter PF, Lutz H. The diagnosis of feline infectious peritonitis (FIP): a retrospective and prospective study. *Kleintierprax* 1993; **38**: 379.
- 14 Hartmann K. Feline infectious peritonitis. *Vet Clin North Am Small Anim Pract* 2005; **35**: 39–79.
- 15 Lutz H, Gut M, Leutenegger CM, et al. Kinetics of FCoV infection in kittens born in catteries of high risk for FIP under different rearing conditions. Proceedings of the Second International Feline Coronavirus/Feline Infectious Peritonitis Symposium, Glasgow, Scotland, 2002.
- 16 Addie DD, Jarrett O. Use of a reverse-transcriptase polymerase chain reaction for monitoring feline coronavirus shedding by healthy cats. *Vet Rec* 2001; **148**: 649–53.
- 17 Pastoret PP, Henroteaux M. Epigenetic transmission of feline infectious peritonitis. *Comp Immunol Microbiol Infect Dis* 1987; **1**: 67–70.
- 18 Addie DD, Jarrett O. Control of feline coronavirus infection in kittens. *Vet Rec* 1990; **126**: 164.
- 19 Pedersen NC, Allen CE, Lyons LA. Pathogenesis of feline enteric coronavirus infection. *J Feline Med Surg* 2008; **10**: 529–41.
- 20 Horzinek MC, Lutz H. An update on feline infectious peritonitis. *Vet Sci Tomorrow* 2001; **1**: 1–8. [www.vetscite.org/issue1/reviews/txt\\_index\\_0800.htm](http://www.vetscite.org/issue1/reviews/txt_index_0800.htm)
- 21 Vennema H, Poland A, Foley J, Pedersen NC. Feline infectious peritonitis viruses arise by mutation from endemic feline enteric coronaviruses. *Virology* 1998; **243**: 150–57.
- 22 Cornelissen E, Dewerchin HL, Van Hamme E, Nauwynck HJ. Absence of surface expression of feline infectious peritonitis virus (FIPV) antigens on infected cells isolated from cats with FIP. *Vet Microbiol* 2007; **121**: 131–37.
- 23 Rottier PJ, Nakamura K, Schellen P, Volders H, Haijema BJ. Acquisition of macrophage tropism during the pathogenesis of feline infectious peritonitis is determined by mutations in the feline coronavirus spike protein. *J Virol* 2005; **79**: 14122–30.
- 24 Poland AM, Vennema H, Foley JE, Pedersen NC. Two related strains of feline infectious peritonitis virus isolated from immunocompromised cats infected with a feline enteric coronavirus. *J Clin Microbiol* 1996; **34**: 3180–84.
- 25 Dye C, Siddell SG. Genomic RNA sequence of feline coronavirus strain FCoV F1Je. *J Feline Med Surg* 2007; **9**: 202–13.
- 26 Addie DD, Jarrett O. Control of feline coronavirus infections in breeding catteries by serotesting, isolation and early weaning. *Feline Pract* 1995; **23**: 92–5.
- 27 Dewerchin HL, Cornelissen E, Nauwynck HJ. Replication of feline coronaviruses in peripheral blood monocytes. *Arch Virol* 2005; **150**: 2483–500.
- 28 Kipar A, May H, Menger S, Weber M, Leukert W, Reinacher M. Morphologic features and development of granulomatous vasculitis in feline infectious peritonitis. *Vet Pathol* 2005; **42**: 321–30.
- 29 Harvey CJ, Lopez JW, Hendrick MJ. An uncommon intestinal manifestation of feline infectious peritonitis: 26 cases (1986–1993). *J Am Vet Med Assoc* 1996; **209**: 1117–20.
- 30 de Groot-Mijnes JD, van Dun JM, van der Most RG, de Groot RJ. Natural history of a recurrent feline coronavirus infection and the role of cellular immunity in survival and disease. *J Virol* 2005; **79**: 1036–44.
- 31 Gunn-Moore DA, Gruffydd-Jones TJ, Harbour DA. Detection of feline coronaviruses by culture and reverse transcriptase-polymerase chain reaction of blood samples from healthy cats and cats with clinical feline infectious peritonitis. *Vet Microbiol* 1998; **62**: 193.
- 32 Kipar A, Baptiste K, Barth A, Reinacher M. Natural FCoV infection: cats with FIP exhibit significantly higher viral loads than healthy infected cats. *J Feline Med Surg* 2006; **8**: 69–72.
- 33 Dewerchin HL, Cornelissen E, Nauwynck HJ. Feline infectious peritonitis virus-infected monocytes internalize viral membrane-bound proteins upon antibody addition. *J Gen Virol* 2006; **87**: 1685–90.
- 34 Paltrinieri S, Cammarata MP, Cammarata G, Comazzi S. Some aspects



- of humoral and cellular immunity in naturally occurring feline infectious peritonitis. *Vet Immunol Immunopathol* 1998; **65**: 205–20.
- 35 Haagmans BL, Egberink HF, Horzinek MC. Apoptosis and T-cell depletion during feline infectious peritonitis. *J Virol* 1996; **70**: 8977–83.
- 36 Gonon V, Duquesne V, Klonjowski B, Monteil M, Aubert A, Eloit M. Clearance of infection in cats naturally infected with feline coronaviruses is associated with an anti-S glycoprotein antibody response. *J Gen Virol* 1999; **80**: 2315–17.
- 37 Weiss RC, Scott FW. Pathogenesis of feline infectious peritonitis: pathologic changes and immunofluorescence. *Am J Vet Res* 1981; **42**: 2036–48.
- 38 Vennema H, de Groot RJ, Harbour DA, et al. Early death after feline infectious peritonitis virus challenge due to recombinant vaccinia virus immunization. *J Virol* 1990; **64**: 1407–9.
- 39 de Groot RJ, Horzinek MC. Feline infectious peritonitis. In: Siddell SG, ed. *The coronaviridae*. New York: Plenum Press, 1995: 293–309.
- 40 Addie DD, Toth S, Murray GD, Jarrett O. The risk of typical and antibody enhanced feline infectious peritonitis among cats from feline coronavirus endemic households. *Feline Pract* 1995; **23**: 24–6.
- 41 Wolfe LG, Griesemer RA. Feline infectious peritonitis. *Pathol Vet* 1966; **3**: 255–70.
- 42 Kipar A, Koehler K, Bellmann S, Reinacher M. Feline infectious peritonitis presenting as a tumour in the abdominal cavity. *Vet Rec* 1999; **144**: 118–22.
- 43 Trulove SG, McCahon HA, Nichols R, Fooshee SK. Pyogranulomatous pneumonia associated with generalized non-effusive feline infectious peritonitis. *Feline Pract* 1992; **20**: 25–9.
- 44 Norris JM, Bosward KL, White JD, Baral RM, Catt MJ, Malik R. Clinicopathological findings associated with feline infectious peritonitis in Sydney, Australia: 42 cases (1990–2002). *Aust Vet J* 2005; **83**: 666–73.
- 45 Kline KL, Joseph RJ, Averill DR. Feline infectious peritonitis with neurologic involvement: clinical and pathological findings in 24 cats. *J Am Anim Hosp Assoc* 1994; **30**: 111–18.
- 46 Foley JE, Rand C, Leutenegger C. Inflammation and changes in cytokine levels in neurological feline infectious peritonitis. *J Feline Med Surg* 2003; **5**: 313–22.
- 47 Timmann D, Cizinauskas S, Tomek A, Doherr M, Vandeveld M, Jaggy A. Retrospective analysis of seizures associated with feline infectious peritonitis in cats. *J Feline Med Surg* 2008; **10**: 9–15.
- 48 Cannon MJ, Silkstone MA, Kipar AM. Cutaneous lesions associated with coronavirus-induced vasculitis in a cat with feline infectious peritonitis and concurrent feline immunodeficiency virus infection. *J Feline Med Surg* 2005; **7**: 233–36.
- 49 Trotman TK, Mauldin E, Hoffmann V, Del Piero F, Hess RS. Skin fragility syndrome in a cat with feline infectious peritonitis and hepatic lipidosis. *Vet Dermatol* 2007; **18**: 365–69.
- 50 Paltrinieri S, Comazzi S, Spagnolo V, Giordano A. Laboratory changes consistent with feline infectious peritonitis in cats from multicat environments. *J Vet Med A Physiol Pathol Clin Med* 2002; **49**: 503–10.
- 51 Sparkes AH, Gruffydd-Jones TJ, Harbour DA. An appraisal of the value of laboratory tests in the diagnosis of feline infectious peritonitis. *J Am Anim Hosp Assoc* 1994; **30**: 345.
- 52 Pedersen NC. The history and interpretation of feline coronavirus serology. *Feline Pract* 1995; **23**: 46.
- 53 Gunn-Moore DA, Caney SM, Gruffydd-Jones TJ, Helps CR, Harbour DA. Antibody and cytokine responses in kittens during the development of feline infectious peritonitis (FIP). *Vet Immunol Immunopathol* 1998; **65**: 221–42.
- 54 Hartmann K, Binder C, Hirschberger J, et al. Comparison of different tests to diagnose feline infectious peritonitis. *J Vet Intern Med* 2003; **17**: 781–90.
- 55 Hayashi T, Ishida T, Fujiwara K. Glomerulonephritis associated with feline infectious peritonitis. *Nippon Juigaku Zasshi* 1982; **44**: 909–16.
- 56 Shelly SM, Scarlett-Kranz J, Blue JT. Protein electrophoresis on effusions from cats as a diagnostic test for feline infectious peritonitis. *J Am Anim Hosp Assoc* 1988; **24**: 495–500.
- 57 Duthie S, Eckersall PD, Addie DD, Lawrence CE, Jarrett O. Value of alpha 1-acid glycoprotein in the diagnosis of feline infectious peritonitis. *Vet Rec* 1997; **141**: 299–303.
- 58 Paltrinieri S, Giordano A, Tranquillo V, Guazetti S. Critical assessment of the diagnostic value of feline alpha 1-acid glycoprotein for feline infectious peritonitis using the likelihood ratios approach. *J Vet Diagn Invest* 2007; **19**: 266–72.
- 59 Hirschberger J, Hartmann K, Wilhelm N, Frost J, Lutz H, Kraft W. Clinical symptoms and diagnosis of feline infectious peritonitis. *Tierarztl Prax* 1995; **23**: 92–9.
- 60 Savary KC, Sellon RK, Law JM. Chylous abdominal effusion in a cat with feline infectious peritonitis. *J Am Anim Hosp Assoc* 2001; **37**: 35–40.
- 61 Herrewegh AA, Mähler M, Hedrich HJ, et al. Persistence and evolution of feline coronavirus in a closed cat-breeding colony. *Virology* 1997; **234**: 349–63.
- 62 Cammarata Parodi M, Cammarata G, Paltrinieri S, Ape F. Using direct immunofluorescence to detect coronaviruses in peritoneal and pleural effusions. *J Small Anim Pract* 1993; **34**: 609–13.
- 63 Tammer R, Evensen O, Lutz H, Reinacher M. Immunohistological demonstration of feline infectious peritonitis virus antigen in paraffin-embedded tissues using feline ascites or murine monoclonal antibodies. *Vet Immunol Immunopathol* 1995; **49**: 177–82.
- 64 Ishida T, Shibana A, Tanaka S, Uchida K, Mochizuki M. Use of recombinant feline interferon and glucocorticoid in the treatment of feline infectious peritonitis. *J Feline Med Surg* 2004; **6**: 107–9.
- 65 Ritz S, Egberink H, Hartmann K. Effect of feline interferon-omega on the survival time and quality of life of cats with feline infectious peritonitis. *J Vet Intern Med* 2007; **21**: 1193–97.
- 66 Hoskins JD, Henk WG, Storz J, Kearney MT. The potential use of a modified live FIPV vaccine to prevent experimental FECV infection. *Feline Pract* 1995; **23**: 89–90.
- 67 McArdle F, Tennant B, Bennett M, Kelly DF, Gaskell RM. Independent evaluation of a modified live FIPV vaccine under experimental conditions (University of Liverpool experience). *Feline Pract* 1995; **23**: 67–71.
- 68 Scott FW, Olsen CW, Corapi WV. Independent evaluation of a modified live FIPV vaccine under experimental conditions (Cornell experience). *Feline Pract* 1995; **23**: 74–6.
- 69 Gerber JD, Ingersoll JD, Gast AM, et al. Protection against feline infectious peritonitis by intranasal inoculation of a temperature-sensitive FIPV vaccine. *Vaccine* 1990; **8**: 536–42.
- 70 Postorino Reeves N. Vaccination against naturally occurring FIP in a single large cat shelter. *Feline Pract* 1995; **23**: 81–2.
- 71 Fehr D, Holznagel E, Bolla S, et al. Evaluation of the safety and efficacy of a modified live FIPV vaccine under field conditions. *Feline Pract* 1995; **23**: 83–8.
- 72 Fehr D, Holznagel E, Bolla S, et al. Placebo-controlled evaluation of a modified live virus vaccine against feline infectious peritonitis: safety and efficacy under field conditions. *Vaccine* 1997; **15**: 1101–9.
- 73 Kass PH, Dent TH. The epidemiology of feline infectious peritonitis. *Feline Pract* 1995; **23**: 27–32.
- 74 Cave TA, Thompson H, Reid SWJ, Hodgson DR, Addie DD. Kitten mortality in the United Kingdom: a retrospective analysis of 274 histopathological examinations (1986–2000). *Vet Rec* 2002; **151**: 497–501.
- 75 Simons FA, Vennema H, Rofina JE, et al. A mRNA PCR for the diagnosis of feline infectious peritonitis. *J Virol Methods* 2005; **124**: 111–16.