

## Case Report

# Ectopic pineal chordoma

Eberval G. Figueiredo, Wagner M. Tavares, Leonardo Welling, Sergio Rosemberg<sup>1</sup>, Manoel Jacobsen Teixeira

Division of Neurological Surgery, <sup>1</sup>Department of Pathology, University of Sao Paulo, School of Medicine, Sao Paulo, Brazil

E-mail: \*Eberval G. Figueiredo - [ebgadelha@yahoo.com](mailto:ebgadelha@yahoo.com); Wagner M. Tavares - [wagnermt@hotmail.com](mailto:wagnermt@hotmail.com); Leonardo Welling - [leonardowelling@yahoo.com.br](mailto:leonardowelling@yahoo.com.br); Sergio Rosemberg - [ebgadelha@yahoo.com](mailto:ebgadelha@yahoo.com); Manoel Jacobsen Teixeira - [manoeljacobson@gmail.com](mailto:manoeljacobson@gmail.com)

\*Corresponding author

Received: 26 August 11

Accepted: 7 September 11

Published: 12 October 11

### This article may be cited as:

Figueiredo EG, Tavares WM, Welling L, Rosemberg S, Teixeira MJ. Ectopic pineal chordoma. *Surg Neurol Int* 2011;2:145.

Available FREE in open access from: <http://www.surgicalneurologyint.com/text.asp?2011/2/1/145/85986>

Copyright: © 2011 Figueiredo EG. This is an open-access article distributed under the terms of the Creative Commons Attribution License, which permits unrestricted use, distribution, and reproduction in any medium, provided the original author and source are credited.

## Abstract

**Background:** Chordomas are rare tumors that arise from the remnants of embryonic notochord anywhere along the neuroaxis. Even though they may occur in an extraosseous intradural location, the most common sites include the sacrococcygeal and clivus regions. The authors report a unique presentation encompassing the pineal region with metastasis to the peritoneum after a ventriculoperitoneal (VP) shunt procedure and review the current knowledge about their pathophysiology and management. The presentation and clinical history endorse the idea that intradural extraosseous chordomas may be distinct from echordosis physaliphora and probably do not derive from it.

**Case Description:** An 18-year-old male with previous history of VP shunt presented to the emergency room with pain and abdominal distension. Computed tomography (CT) scans revealed a mass in the pineal region and in the abdominal cavity. Histopathologic exams showed chordoma in both abdominal and cranial samples. The patient died due to systemic complications.

**Conclusion:** The authors hypothesized that notochord remnants may subsist within the brain and occasionally may generate a neoplastic lesion.

**Key Words:** Chordoma, metastasis, notochord, pineal region, ventriculoperitoneal shunt

### Access this article online

#### Website:

[www.surgicalneurologyint.com](http://www.surgicalneurologyint.com)

#### DOI:

10.4103/2152-7806.85986

#### Quick Response Code:



## INTRODUCTION

Chordomas are rare aggressive tumors originating from the notochord. Primary sites include the clivus, vertebrae and sacrococcygeal region.<sup>[3,9]</sup> Their growing behavior is variable; however, they are locally destructive and slow growing with a propensity for recurrence. They may also occur in an extraosseous intradural location and some controversy exists about their origin in such instances.<sup>[7]</sup> The current knowledge is that probably such intradural chordomas arise from benign hamartomatous

“echordosis physaliphora;” however, there is no consensus in this regard.<sup>[7]</sup> Chordomas arising within the brain are extremely rare, and thus far only one occurrence has been reported.<sup>[7]</sup> We report a case of a pineal region chordoma with metastasis through a ventriculoperitoneal (VP) shunt and hypothesize on the origin of these intraparenchymal chordomas.

## CASE REPORT

An 18-year-old man presented with abdominal

pain, distension and constipation. His past medical history included VP shunt and a craniotomy with a supracerebellar infratentorial access to a pineal mass that had a histological diagnosis of germinoma in April 1994. Postoperatively, he was submitted to radiotherapy (5400 rads).

Physical examination revealed stable vital signs. Heart and lung auscultation revealed no abnormalities. Abdominal exam showed a large, solid mesogastric mass associated with pain and distension. On neurological exam, the patient was alert, oriented, with Parinaud syndrome and left oculomotor nerve paresis. Abdominal ultrasonography revealed a large solid and cystic abdominal mass around the VP catheter. The tumor produced pyelocalyceal ectasia and bowel distention and was accompanied by moderate ascites. During the admission, peritoneocentesis was performed. Aspiration cytology revealed no abnormalities. Magnetic resonance imaging (MRI) showed a pineal irregular mass occupying the superior cerebellar and quadrigeminal cisterns with hyposignal on T1, medium signal on T2 and heterogeneous enhancement after gadolinium injection [Figure 1]. Based on the size and diffuse abdominal infiltration of the tumor, surgery was not carried out. A specimen was taken for histology by abdominal computed tomography (CT)-guided puncture.

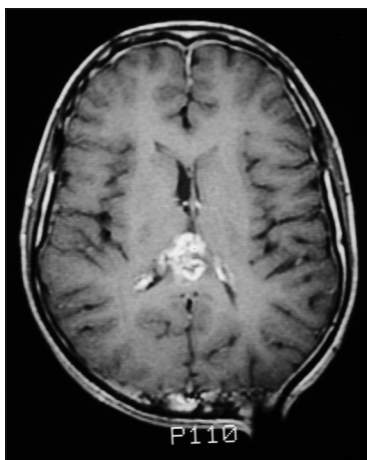
The histopathologic analysis revealed cells of various shapes, from polyhedral to prismatic, arranged in a lobular manner. Thin-walled blood vessels surrounded by a fibrous trabeculae framework with variable thickness were noticed. They were arranged in cords and sheets and exhibited an eosinophilic cytoplasm with intervening epithelial and intracellular mucin containing cells [Figure 2]. Immunohistochemical staining using immunoperoxidase technique was characteristic of

chordoma with positive results for AE3 and vimentin and negative results for AE1, EMA, S100, HNF35, enolase, placental alkaline phosphatase. Based on these findings, the previous histopathologic diagnosis was revised and established as chordoma. However, during the admission, the patient presented with systemic clinical complications and he died. The primary pineal origin of the chordoma was confirmed by autopsy.

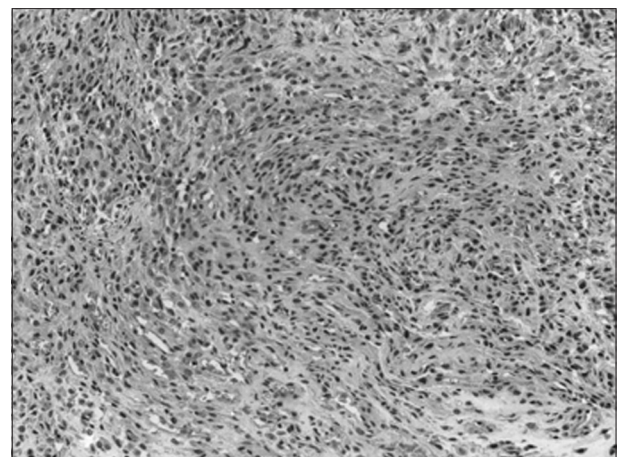
## DISCUSSION

Chordomas are very rare tumors that arise from notochord embryonic remnants. They may be found anywhere along the axial skeleton between the skull base and coccyx, where the notochord vestiges may be encountered.<sup>[1]</sup> The sacrococcygeal and clivus regions are the sites of origin in 53% and 35% of the cases, respectively.<sup>[12]</sup> Despite their benign histology, the biological behavior is malignant with local invasiveness and bone destruction.<sup>[6]</sup> Metastasis occurs in 5–20% of cases<sup>[10]</sup> and usually presents within the first 3 years. The most common metastatic primary site is the sacrococcygeal region (73% of the cases) and typically involves lymph nodes, lung, liver and bones.<sup>[7]</sup> Rare cases of completely extraosseous, intradural chordomas have been reported in the prepontine, suprasellar, and foramen magnum regions.<sup>[7]</sup>

The origin of intradural extraosseous chordoma is still debated and it is speculated that it may arise from an ecchordosis physaliphora.<sup>[2]</sup> Ecchordosis physaliphora is a small, well-circumscribed intradural lesion usually found on the ventral surface of the brainstem, attached to the dorsum sellae and mostly discovered incidentally at autopsy.<sup>[7]</sup> Ecchordosis is thought to originate from migration of hamartomatous notochordal remnants to the intradural space via a small opening in the dura.<sup>[7]</sup>



**Figure 1:** Axial MRI view. A heterogeneously enhanced lesion may be appreciated in the pineal region. An artifact generated by a ventriculoperitoneal shunt catheter is noticed. No leptomeningeal enhancement is observed



**Figure 2:** Histopathologic view. Cells of several shapes may be seen arranged in a lobular manner. They exhibit an eosinophilic cytoplasm with intervening epithelial and intracellular mucin containing cells. Thin-walled vessels surrounded by a fibrous framework may be appreciated

Despite the fact that it presents the same histological characteristics of chordoma, it is not a neoplasm<sup>[2]</sup> and its clinical behavior differs substantially from that of typical chordomas,<sup>[7]</sup> even though the possibility that intradural extraosseous chordomas may simply be giant ecchordosis physaliphora has also been pointed out.<sup>[2]</sup>

The notochord appears at nearly 3 weeks of fetal development.<sup>[7,11]</sup> At 5 weeks, it constitutes part of the odontoid process and the spheno-occipital plate, extending to the pituitary fossa and the submucosal tissue of the developing nasopharynx, the regions of the paranasal sinuses and lateral peripharyngeal spaces.<sup>[6,7]</sup> It commences to disintegrate by the 8<sup>th</sup> week, leaving remnants trapped among the descending myotomes and sclerotomes of the head and neck.<sup>[7]</sup>

This is the second case of chordoma arising within the brain. Commins *et al.* reported an exceptional occurrence of a hypothalamic chordoma.<sup>[2]</sup> They speculated that the tumor may have arisen from an usual ecchordosis physaliphora located in an extraordinary site.<sup>[7]</sup> Nevertheless, an alternative hypothesis is that it may have arisen directly from the notochord rests lying within or nearby the pituitary fossa. In our case, however, origin from an ecchordosis physaliphora or other usually topic notochord vestiges is not plausible. The pineal location is unique and distant from the axial skeleton, the usual site of notochord remnants. Also, the aggressive metastatic behavior of the tumor argues against the hypothesis that intradural chordomas may represent giant ecchordosis physaliphora. Interestingly, like in the other intraparenchymal case,<sup>[2]</sup> the tumor was located in the midline. It is possible that notochord remnants may subsist also within the brain tissue and occasionally underwent further biological transformation.

Notwithstanding the low incidence of chordomas' metastasis, the tumor presents a high rate of recurrence (85%) and recent publications have demonstrated a high frequency of tumor implants on the tumor surgical field.<sup>[5,8]</sup> Possible mechanisms include direct tumor seeding during the operation or hematogenous spread produced by an increase of regional blood flow and chemotaxic factors.<sup>[8]</sup> Chordomas may metastasize non-selectively to any tissue including bone, mucus membranes, tentorium, abdominal subcutaneous fat and neck muscles. In this report, it is likely that the spread had occurred by CSF that might be seeded during the cranial operation or after that by direct tumor seeding. The neoplastic cells were free to grow in the abdominal cavity that was not submitted to radiotherapy and

remained undetected until the late symptoms developed.

The current treatment for chordomas is surgical removal followed by radiotherapy (4500–5500 rads) on the tumor bed.<sup>[11]</sup> The prognosis for patients with metastatic chordomas is generally poor with a life expectancy of less than 5% in 5 years.<sup>[4]</sup> Nevertheless, intracranial lesions situated in non-critical sites may be completely removed, improving long-term prognosis.

## CONCLUSION

The authors present their experience with an unusual occurrence of an intracerebral chordoma with a rare metastatic mechanism. The presentation and clinical history endorse the idea that intradural extraosseous chordomas are distinct from usual ecchordosis physaliphora and probably do not derive from it. We hypothesized that notochord remnants may subsist within the brain parenchyma and may occasionally undergo further transformation. Additionally, special attention should be given for the use of VP shunts in chordomas since the possibility of abdominal metastasis exists and treatment might be delayed as metastases may develop without early symptoms.

## REFERENCES

1. Arnautovic KI, Al-Mefty O. Surgical seeding of chordomas. *J Neurosurg* 2001;95:798-803.
2. Commins D, Baran GA, Molleston M, Vollmer D. Hypothalamic chordoma. *J Neurosurg* 1994;81:130-2.
3. Dahlin DC, MacCarty CA. Chordoma: A study of fifty-nine cases. *Cancer* 1952;5:1170-8.
4. Fagundes MA, Hug EB, Liebsch NJ, Daly W, Efrid J, Munzenrider JE. Radiation therapy for chordomas of the base of skull and cervical spine: Patterns of failure and outcome after relapse. *Int J Radiat Oncol Biol Phys* 1995;33:579-84.
5. Fischbein NJ, Kaplan MJ, Holliday RA, Dillon WP. Recurrence of clival chordoma along the surgical pathway. *Am J Neuroradiol* 2000;21:578-83.
6. Graham DI, Lantos PL. *Greenfield's Neuropathology*. 7<sup>th</sup> ed. London: Arnold; 2002.
7. Gormley WB, Beckman ME, Ho KL, Boyd SB, Rock JP. Primary craniofacial chordoma: Case report. *Neurosurgery* 1995;36:1196-9.
8. Greene D, Deschler D, Kaplan MJ. Dermal metastases of pectoralis major flap donor site from a laryngeal squamous cell carcinoma. *Ear Nose Throat J* 1998;77:102-4.
9. Heffelfinger JM, Dahlin DC, MacCarty CS, Beabout JW. Chordomas and cartilaginous tumors at the skull base. *Cancer* 1973;32:410-20.
10. Hug EB, Loredano LN, Slater JD, DeVries A, Grove RI, Schaefer RA, *et al.* Proton radiation therapy for chordomas and chondrosarcomas of the skull base. *J Neurosurg* 1999;91:432-9.
11. Klekamp J, Samii M. Spinal chordomas – results of treatment over a 17-year period. *Acta Neurochir (Wien)* 1996;138:514-9.
12. O'Neill P, Bell BA, Miller JD, Jacobson I, Guthrie W. Fifty years of experience with chordomas in southeast Scotland. *Neurosurgery* 1985;16:166-70.