



Original Research

Routine Pathologic Examination of the Femoral Head in Total Hip Arthroplasty: A Survey Study of the American Association of Hip and Knee Surgeons

Sumon Nandi, MD, MBA ^{a, *}, Javad Parvizi, MD, FRCS ^b, AAHKS Research Committee

^a University of Maryland School of Medicine, Baltimore, MD, USA

^b Rothman Institute, Thomas Jefferson University; Philadelphia, PA, USA

ARTICLE INFO

Article history:

Received 27 June 2022

Received in revised form

24 November 2022

Accepted 4 December 2022

Available online xxx

Keywords:

Femoral head

Hip

Arthroplasty

Pathology

Routine

Cost

ABSTRACT

Background: Current literature does not provide conclusive evidence on whether routine pathologic examination of femoral heads from total hip arthroplasty is indicated or cost-effective. As a result, there is substantial variation in opinion among surgeons related to this issue. Our study aim was to determine factors that impact surgeon propensity to order pathologic examination of femoral heads.

Methods: A 12-question survey was created to evaluate surgeon practices, indications, and patient care implications surrounding routine pathologic examination of femoral heads. The email survey was distributed to all members of the American Association of Hip and Knee Surgeons (n = 2598).

Results: There were 572 survey respondents. Out of all respondents, 28.4% always send femoral heads to pathology, and 27.6% reported an institutional requirement to do so. Of the 572 surgeons, 73.6% report femoral head pathology has never resulted in a change in patient disease course. Factors that increase the likelihood of surgeons ordering femoral head pathologic examination include institutional requirements, medicolegal concern, and prior experience with femoral head pathologic examination changing patients' disease course ($P < .001$). Cost concern decreases the likelihood of surgeons ordering femoral head pathologic examination ($P = .0012$).

Conclusions: A minority of surgeons routinely send femoral heads from total hip arthroplasty for pathologic examination, mostly because of institutional requirement. The majority of surgeons feel that femoral head pathologic examination never changes patient management, although others have infrequently detected malignancy and infection. Institutional policy, concern for litigation, and prior experience with discordant pathologic diagnoses increase femoral head pathologic examinations, while cost concern decreases them.

Published by Elsevier Inc. on behalf of The American Association of Hip and Knee Surgeons. This is an open access article under the CC BY-NC-ND license (<http://creativecommons.org/licenses/by-nc-nd/4.0/>).

Introduction

According to the United States Agency for Healthcare Research and Quality, 599,500 inpatient total hip arthroplasties (THAs) were performed in 2018 with exponential growth expected over subsequent years [1,2]. As a result, THA care delivery processes have significant implications on quality and cost for the health-care system. There is current evidence demonstrating a standardized process improves both quality and cost of total joint arthroplasty (TJA) [3,4].

There is substantial variation among surgeons in the routine utilization of femoral head pathologic examination in THA. Several studies have reported routine pathologic examination of femoral head specimens may result in discordant diagnoses, those that differ from preoperative clinical diagnoses and change patient management [5–9]. Equally numerous groups argue against this practice and have found routine femoral head pathologic examination does not yield discordant diagnoses [10–16].

Routine pathologic examination of femoral head specimens obtained during THA is estimated to cost up to \$63 million per year [17]. Metrics of cost-effectiveness are based on an intervention's impact on patients' longevity and quality of life. As the value of routine femoral head pathology is disputed in the literature, assessments of its cost-effectiveness are also expected to differ accordingly [6,8,10–14,16].

* Corresponding author. University of Maryland School of Medicine, 110 S. Poca St., Suite 300, Baltimore, MD 21201, USA. Tel.: +1 410-683-2130.

E-mail address: sumon.nandi@gmail.com

Widely disparate conclusions of the existing literature contribute little to the effort to establish a standard process governing pathologic examination of femoral head specimens in THA. It is thus essential to identify the reasons why surgeons performing THA request femoral head pathologic examination.

Our study aim was to determine the factors that impact surgeons' propensity to order pathologic examination of femoral heads obtained during THA.

Material and methods

Study design

A 12-question survey was created to evaluate surgeon and institutional practices, indications, and patient care implications surrounding routine pathologic examination of femoral head specimens obtained during THA. The survey (Fig. 1) was distributed by email to all American Association of Hip and Knee Surgeons (AAHKS) members ($n = 2598$) and administered using a Web-based survey platform, SurveyMonkey (San Mateo, CA). Respondents completed the survey between January 21, 2021, and April 18, 2021. This study was reviewed, approved, and deemed exempt by our institutional review board.

Statistical analysis

Frequencies and percentages were calculated for all categorical question responses. Ordinal responses were transformed into numeric scores, and Pearson product-moment correlation was utilized to identify associations between question pairs. Stepwise multivariate logistic regressions were performed to identify significant predictors of the main outcome, probability of sending femoral heads for pathologic examination, as well as a secondary outcome, probability of discussing the need for routine femoral head examination with the pathology department. Ordinal logistic

1. What is your practice setting?
 - a. Private practice
 - b. Academic
 - c. Private practice with academic affiliation
 - d. Military
 - e. Hospital employed
2. What is your total joint replacement reimbursement model? Select all that apply.
 - a. Bundled payment
 - b. Capitated payment
 - c. Fee for service
3. How many years have you been in practice?
 - a. 0-5
 - b. 6-10
 - c. 11-20
 - d. 21-30
 - e. More than 30
4. How many hip arthroplasties do you perform per year?
 - a. Less than 100
 - b. Between 100 and 200
 - c. Between 201 and 300
 - d. Between 301 and 500
 - e. More than 500
5. Do you send femoral head specimens for pathologic examination during routine total hip arthroplasty?
 - a. Always
 - b. Sometimes
 - c. Never
6. Is submission of femoral head specimens for routine pathologic examination a hospital/institutional requirement?
 - a. Yes
 - b. No

Figure 1. Routine femoral head pathologic examination survey.

7. Please select the most important factors in your decision to send or not send femoral head specimens for pathologic examination. Select all that apply.
 - a. Hospital/institutional policy
 - b. Cost
 - c. Training
 - d. Advice of peers
 - e. Patient medical history/diagnosis
 - f. Medicolegal concern
8. If patient medical history or diagnosis impacts your decision to send femoral head specimens for pathologic examination, for which conditions do you send the femoral head? Select all that apply.
 - a. Fracture
 - b. Infection
 - c. Malignancy
 - d. Crystalline arthropathy
 - e. Avascular necrosis
 - f. Rheumatoid arthritis or other autoimmune disorder
 - g. Paget's Disease
9. Has femoral head pathologic examination in your patients ever yielded a diagnosis different than the preoperative diagnosis? Select all that apply.
 - a. Yes, infection
 - b. Yes, malignancy
 - c. Yes, crystalline arthropathy (e.g., gout, pseudogout)
 - d. Yes, avascular necrosis
 - e. Yes, rheumatoid arthritis or other autoimmune disorder
 - f. Yes, Paget's Disease
 - g. No, never
10. Has femoral head pathologic examination in your patients ever resulted in a change in management?
 - a. Yes, an intervention that changed disease course
 - b. Yes, increased surveillance only
 - c. No, never
11. How often has femoral head pathologic examination resulted in an intervention that changed disease course in your patients?
 - a. Never
 - b. Once
 - c. More than once
12. Have you ever discussed the need for routine femoral head examination with your pathology department?
 - a. Yes
 - b. No

Figure 1. (continued).

regressions were used to determine if a reimbursement model or years in practice were predictors of the main outcome or another secondary outcome, observation of a femoral head pathologic diagnosis different than the preoperative diagnosis. P values $< .05$ were considered significant. All analyses were performed in SAS 9.4 (Cary, NC).

Results

Response distributions

There were 572 respondents to our survey, making the response rate 22% (572/2598) and margin of error 3.62% at a 95% confidence level. The frequency of each survey question answer is given in Figure 2.

Most surveyed surgeons are in private practice (49.0%), followed by those in academics (23.2%), or hospital employed (17.5%). Nearly half of the surgeons (43.5%) perform 100 to 200 hip arthroplasties per year. The most common reimbursement model is fee for service (82.3%) although 42.9% of all surgeons also perform cases in a bundled payment model.

Of all the respondents, 36.6% never send femoral head specimens for pathologic examination during a routine THA; 28.4% of surgeons always send these specimens for pathologic examination, with 27.6% of surgeons reporting an institutional requirement to do so.

AAHKS members reported the most important factor in deciding to send femoral heads for pathologic examination is patients' medical history (65.9%), followed by cost (32.7%), and institutional

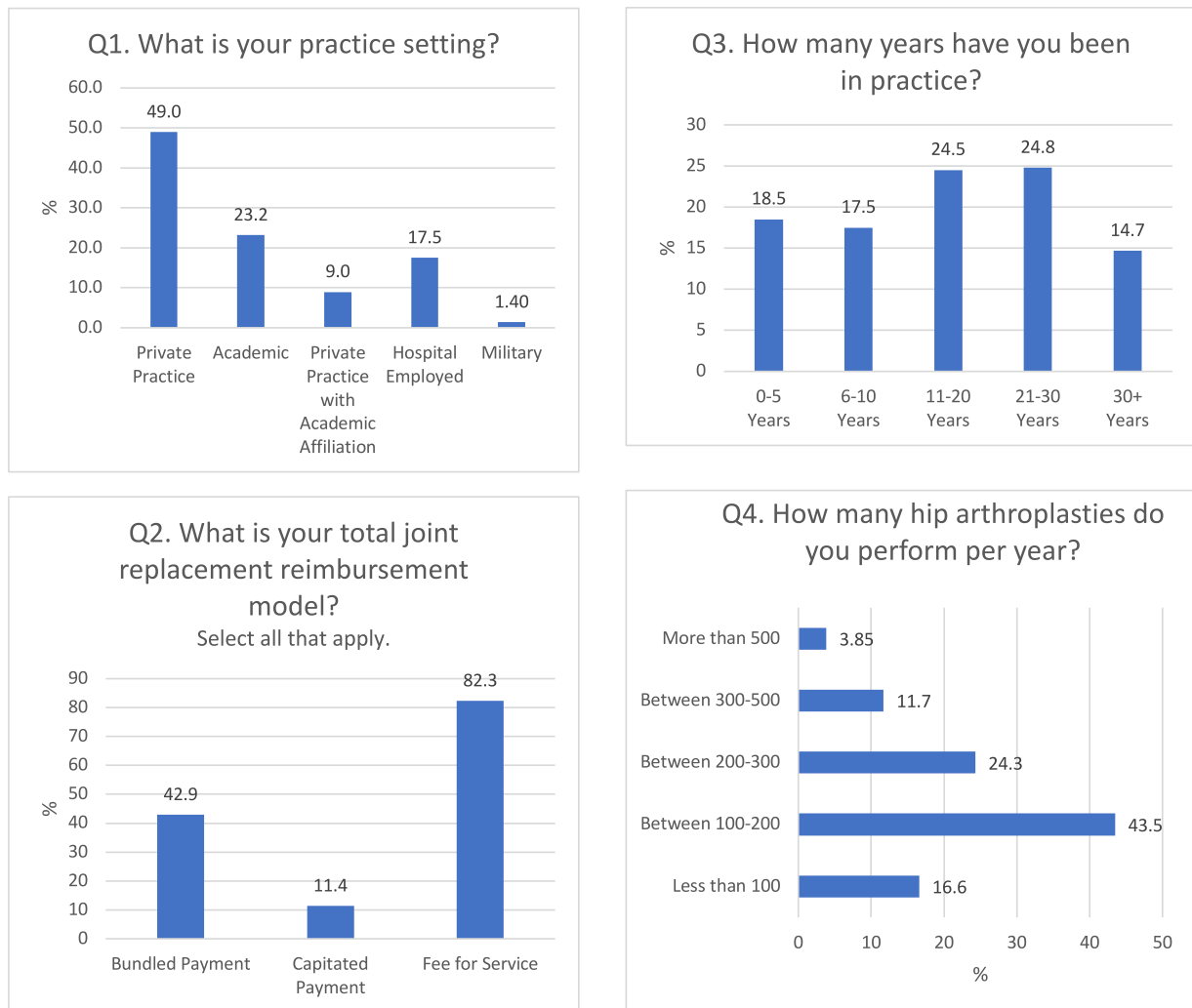


Figure 2. Distribution of responses to routine femoral head pathologic examination survey.

policy (32.2%). When patients' medical history impacts a surgeon's decision to send femoral head specimens for pathologic examination, concern for malignancy (96.5%) or infection (50.7%) is the most common reason for doing so.

For most surgeons (65.7%) surveyed, femoral head pathologic examination has never yielded a diagnosis different from the preoperative diagnosis. However, for some surgeons, femoral head pathology has resulted in a new diagnosis of malignancy (24.2% of all respondents) or infection (5.43% of all respondents). Of all surgeons who responded, 73.6% report femoral head pathologic examination has never resulted in an intervention that changed a patient's disease course.

Response correlations

With a hospital or institutional requirement to send femoral heads to pathology, surgeons are 1203 times more likely to always do so (odds ratio [OR] 1203; 95% confidence interval [CI] 96.8-14,960; $P < .0001$) and 2.35 times more likely to discuss the need for routine femoral head examination with the pathology department (OR 2.35; 95% CI 1.58-3.50; $P < .0001$).

Surgeons for whom medicolegal concern is the most important factor in the decision to send femoral head specimens for pathologic examination are 232 times more likely to always send femoral

heads to pathology than other surgeons (OR 232; 95% CI 14.5-3703; $P = .0001$).

When cost is the most important factor in a surgeon's decision to send femoral heads to pathology, those surgeons are 4/10,000 as likely as others to always do so (OR 0.000395; 95% CI 0.00-0.0460; $P = .0012$). Accordingly, those practicing in a bundled payment reimbursement model are less likely to always send femoral heads for pathologic examination (OR 0.69; 95% CI 0.49-0.98; $P = .036$).

Surgeons are 479 times more likely to always send femoral heads to pathology when patients have a history of rheumatoid arthritis or other autoimmune disorder (OR 479; 95% CI 25.2-9089; $P < .0001$).

Only after more than 30 years in practice are surgeons more likely to report finding a femoral head pathologic diagnosis that differs from the preoperative clinical diagnosis (OR 3.60; 95% CI 1.90-6.82; $P < .0001$).

When femoral head pathologic examination resulted in an intervention that changed the disease course of a patient, his or her surgeon is subsequently 248 times more likely to always send femoral heads for pathologic examination (OR 248; 95% CI 11.7-5239; $P = .0004$). When surgeons reported that femoral head pathologic examination resulted in an intervention that changed the disease course, the most common associated pathologic diagnoses were infection (OR 84.8; 95% CI 7.24-994; $P = .0004$),

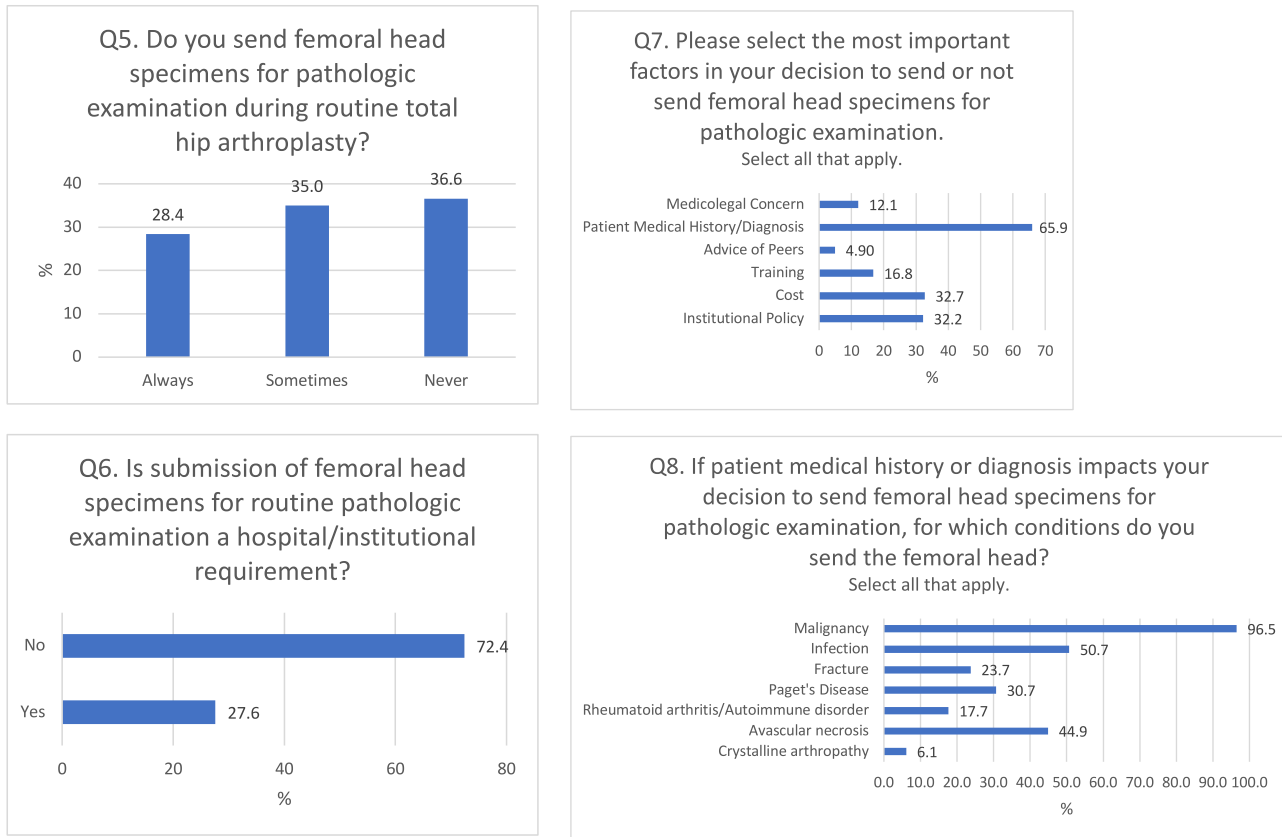


Figure 2. (continued).

malignancy (OR 68.0; 95% CI 7.92–584; $P = .0001$), or autoimmune disorder (OR 16.2; 95% CI 1.64–160; $P = .0172$).

Discussion

Standardized care pathways in TJA have been shown to optimize quality and cost [3,4]. However, there is surgeon variation in the use of routine pathologic examination of femoral head specimens obtained during THA. The current literature does not provide conclusive evidence on whether a routine femoral head pathologic examination is indicated or cost-effective [5–16]. Our aim was to determine if those factors are impactful in THA surgeons' decision to routinely order femoral head pathologic examination or not. We found that institutional policy, cost, medicolegal concern, and prior experience with the utility of pathologic examination most strongly influence surgeon behavior surrounding orders for femoral head pathologic examination.

A minority of surgeons (28.4%) always send femoral head specimens from THA for pathologic examination, which corresponds to the proportion of surgeons with an institutional requirement to do so. We found that hospital or institutional policy to be one of the most impactful drivers of surgeon behavior, increasing the likelihood of routine femoral head pathologic examination by over 1200-fold. The Joint Commission on Accreditation of Healthcare Organizations does allow exceptions to institutional requirements for femoral head pathologic examination if this decision is made collaboratively between surgeons and pathologists [18]. It follows that AAHKS members are more than twice as likely to discuss the need for femoral head examination with their pathology colleagues when there is an institutional mandate for specimen submission to pathology.

Of the surgeons who responded, 36.6% never send THA femoral head specimens for pathologic examination. Almost as many (35%) surgeons make the decision to send femoral heads for pathologic examination on a case-by-case basis. In addition to the institutional policy, we identified numerous determinants of surgeons' propensity to order femoral head pathologic examination.

Nearly one-third (32.7%) of surgeons surveyed reported cost as the most important factor in deciding whether to utilize routine femoral head pathologic examination. These surgeons are far less likely, in fact 4/10,000 as likely, to send femoral heads for pathologic examination. Greater cost transparency surrounding femoral head pathologic examination, which ranges from \$60 to \$283 per specimen, may inform surgeons' decisions to routinely order pathology [8,10–14,16]. This is particularly relevant for surgeons performing cases in a bundled payment model, who comprised 42.9% of AAHKS respondents.

Of the surgeons who responded, 12.1% cited medicolegal concern as the most important factor in their decision to order pathologic examination of femoral heads. The risk of litigation makes these surgeons 232 times more likely to send femoral heads for pathologic examination. Of note, based on a legal research database query of TJA malpractice cases from 2008 to 2018, "unnecessary surgery, failure to refer or consult, and failure to treat" were each an allegation in less than 8% of cases [19]. This is reassuring, suggesting that routine femoral head pathologic examination may not be essential to legal defense, particularly given all THA patients have preoperative radiographs documenting appearance of the femoral head and indication for a surgery.

A small fraction of surgeons, 10.5%, found femoral head pathologic examination resulted in a change in patient disease course

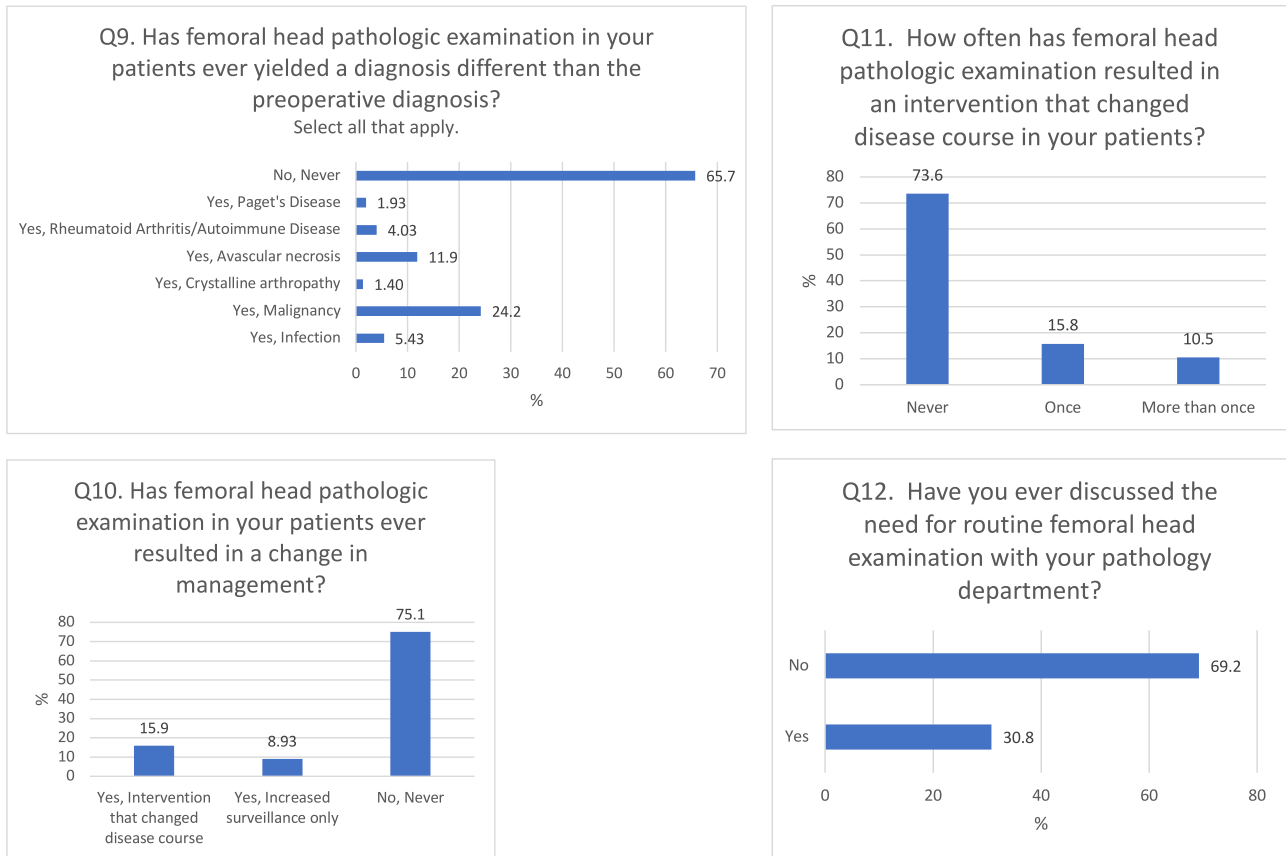


Figure 2. (continued).

more than once in their careers. Of the surgeons who responded, 15.8% noted that femoral head pathologic examination yielded a change in disease course for just 1 patient in their practice. While AAHKS surgeons have reported discordant diagnoses on femoral head pathology (24.2% of respondents found malignancy, 5.43% found infection), to further clarify, most performed more than 100 THAs per year and have made only 1 such observation in their entire career. These events, while rare, make surgeons more than 200 times more likely to subsequently order femoral head pathologic examination on all patients. It has been previously reported that personal experience with a treatment algorithm outcome is impactful in TJA surgeons' decision-making [20].

Only after 30 years in practice are surgeons more likely to observe a femoral head pathologic diagnosis that differs from the preoperative clinical diagnosis. Consistent with the proportion of surgeons for whom femoral head pathologic examination has led to a change in patients' disease course, approximately 15% of AAHKS surgeons surveyed have been in practice for more than 30 years. This may have also resulted in an inflated representation of discordant diagnoses in survey responses compared to the true incidence.

Our findings may guide formulation of standard protocols for pathologic examination of THA femoral head specimens, but we understand our work has limitations. First, we surveyed only AAHKS members, not all surgeons performing THA. As a result, our work may suffer from sample bias as AAHKS members may have attitudes and practices not generalizable to all THA surgeons. Second, although our response rate of 22% is higher than that previously reported for surgeon surveys, response rates lower than 70% may result in a nonrepresentative sample [21]. Third, surgeon

responses may not reflect their actual practice patterns. This may occur, in part, if survey answer choices were not exhaustive of all potential responses. Surgeon responses based on an anecdote rather than a quantitative retrospective analysis are also potentially contributory.

Conclusions

Existing evidence is largely retrospective and not conclusive for or against routine pathologic examination of femoral head specimens obtained during THA. As a result, there is significant surgeon and institutional variation in the utilization of femoral head pathology. Our survey study demonstrates only 28.4% of surgeons always send femoral head specimens for pathologic examination, which corresponds to the proportion of surgeons with an institutional requirement to do so. Of the surgeons who responded, 73.6% report femoral head pathologic examination has never resulted in a change in patients' disease course. Others, largely those in practice for more than 30 years, have infrequently detected malignancy and infection upon pathologic examination of THA femoral head specimens.

An institutional policy requiring femoral head pathologic examination, concern for litigation, and prior observation of a discordant femoral head pathologic diagnosis increase the likelihood that femoral head pathologic examination is ordered. Conversely, the concern for cost decreases the likelihood that a surgeon will order pathologic examination of the femoral head. These factors must be addressed in any effort to establish a standardized process for ordering femoral head pathologic examination. Potential measures include greater cost transparency

surrounding pathology services and surgeon medicolegal education. Further prospective studies are needed to accurately establish the rates of discordant femoral head pathologic diagnoses that change patients' disease course, which may serve as a foundation for institutional or organizational policy.

Conflicts of interest

Dr. S. Nandi receives financial or material support from Springer Publishing, is in the editorial or governing board of JOA, and is a board member in AAOS and AAHKS. Dr. J. Parvizi receives royalties from Corentec; is a paid consultant for Zimmer Biomet, Corentec, Ethicon, Tenor, KCI/3M (Acelity), Heraeus, MicroGenDx, Jointstem, Peptilogics, and Fidia Phram; has stock or stock options in Parvizi Surgical Innovations and subsidiaries, Hip Innovation Technologies, Corentec, Alphaeon/Strathsby Crown, Joint Purification Systems, Ceribell, Acumed, PRN-Veterinary, MD-valuate, Intellijoint, MicroGenDx, Nanoxygenic, Sonata, and Molecular Surface Technologies; receives financial or material support from Data Trace, Elsevier, Jaypee Publishers, SLACK Incorporated, Wolters Kluwer, and Becton Dickenson. The AAHKS Research Committee declares no potential conflicts of interest.

For full disclosure statements refer to <https://doi.org/10.1016/j.artd.2022.101079>.

References

- [1] Singh JA, Yu S, Chen L, Cleveland JD. Rates of total joint replacement in the United States: future projections to 2020-2040 using the National inpatient sample. *J Rheumatol* 2019;46:1134–40.
- [2] Sloan M, Premkumar A, Sheth NP. Projected volume of primary total joint arthroplasty in the U.S., 2014 to 2030. *J Bone Joint Surg Am* 2018;100:1455–60.
- [3] Loftus T, Agee C, Jaffe R, Tao J, Jacofsky DJ. A simplified pathway for total knee arthroplasty improves outcomes. *J Knee Surg* 2014;27:221–8.
- [4] Schubert A, Patterson M, Sumrall WD, Broussard D, Dias D, Aboalfaraj A, et al. Perioperative population management for primary hip arthroplasty reduces hospital and postacute care utilization while maintaining or improving care quality. *J Clin Anesth* 2021;68:110072.
- [5] Dermawan JK, Goldblum A, Reith JD, Kilpatrick SE. Accurate and reliable diagnosis of avascular necrosis of the femoral head from total hip arthroplasty specimens requires pathologic examination. *Am J Clin Pathol* 2021;155:565–74.
- [6] DiCarlo EF, Klein MJ. Comparison of clinical and histologic diagnoses in 16,587 total joint arthroplasties: implications for orthopedic and pathologic practices. *Am J Clin Pathol* 2014;141:111–8.
- [7] Layfield LJ, Crim JR, Oserowsky A, Schmidt RL. Pathology assessment of femoral head resection specimens: an important quality assurance procedure. *Arch Pathol Lab Med* 2020;144:580–5.
- [8] Liow MHL, Agrawal K, Anderson DW, Freiberg AA, Rubash HE, Kwon YM. Unsuspected malignancies in routine femoral head histopathologic examination during primary total hip arthroplasty: cost-effectiveness analysis. *J Arthroplasty* 2017;32:735–42.
- [9] Zwisser EW, de Gast A, Basie MJ, van Kemenade FJ, van Royen BJ. B-cell lymphoma in retrieved femoral heads: a long term follow up. *BMC Musculoskelet Disord* 2009;10:53.
- [10] Campbell ML, Gregory AM, Mauerhan DR. Collection of surgical specimens in total joint arthroplasty. Is routine pathology cost effective? *J Arthroplasty* 1997;12:60–3.
- [11] Kocher MS, Erens G, Thornhill TS, Ready JE. Cost and effectiveness of routine pathological examination of operative specimens obtained during primary total hip and knee replacement in patients with osteoarthritis. *J Bone Joint Surg Am* 2000;82:1531–5.
- [12] Lawrence T, Moskal JT, Diduch DR. Analysis of routine histological evaluation of tissues removed during primary hip and knee arthroplasty. *J Bone Joint Surg Am* 1999;81:926–31.
- [13] Lin MM, Goldsmith JD, Resch SC, DeAngelis JP, Ramappa AJ. Histologic examinations of arthroplasty specimens are not cost-effective: a retrospective cohort study. *Clin Orthop Relat Res* 2012;470:1452–60.
- [14] Meding JB, Ritter MA, Jones NL, Keating EM, Faris PM. Determining the necessity for routine pathologic examinations in uncomplicated total hip and total knee arthroplasties. *J Arthroplasty* 2000;15:69–71.
- [15] Niggemeyer O, Steinhagen J, Zustin J, R  ther W. The value of routine histopathology during hip arthroplasty in patients with degenerative and inflammatory arthritis. *Hip Int* 2011;21:98–106.
- [16] Raab SS, Slagel DD, Robinson RA. The utility of histological examination of tissue removed during elective joint replacement. A preliminary assessment. *J Bone Joint Surg Am* 1998;80:331–5.
- [17] Nandi S, Schwarzkopf R, Chen A, Seyler T, Wheeler L, Parvizi J. Routine pathologic examination of femoral head specimens from total hip arthroplasty may not be indicated or cost-effective: a systematic review. *Arthroplast Today* 2022;15:182–187.e3.
- [18] Clark CR, Bauer T. Routine pathological examination of operative specimens from primary total hip and total knee replacement: another look. *J Bone Joint Surg Am* 2000;82:1529–30.
- [19] Samuel LT, Sultan AA, Rabin JM, Surace PA, Yao B, Moskal JT, et al. Medical malpractice litigation following primary total joint arthroplasty: a comprehensive, nationwide analysis of the past decade. *J Arthroplasty* 2019;34:S102–7.
- [20] Moore AJ, Blom AW, Whitehouse MR, Gooberman-Hill R. Managing uncertainty - a qualitative study of surgeons' decision-making for one-stage and two-stage revision surgery for prosthetic hip joint infection. *BMC Musculoskelet Disord* 2017;18:154.
- [21] Sprague S, Quigley L, Bhandari M. Survey design in orthopaedic surgery: getting surgeons to respond. *J Bone Joint Surg Am* 2009;91 Suppl 3:27–34.