

# Incidental Paranasal Sinus Findings on Computed Tomography Images of Pediatric Patients: A Cross-sectional Prevalence Study

Priyanka Talwade<sup>1</sup>, Prasannasrinivas S Deshpande<sup>2</sup>, Shailesh Pene<sup>3</sup>, Shruti Kumar<sup>4</sup>, Vishal Kudagi<sup>5</sup>, Mrinal Limaye<sup>6</sup>

## ABSTRACT

**Objectives:** The study was conducted to assess the prevalence of incidental paranasal sinus pathologies in children on computed tomography (CT) scans.

**Materials and methods:** A nonrandomized retrospective study was done on CT scans of 232 pediatric patients taken in the past 6 months duration. These scans were evaluated in different age groups from 0–13 years who had visited or were admitted to the hospital for various other head and neck-related problems. Each scan was examined for incidental pathologic findings in all the paranasal sinuses. The data were analyzed using descriptive statistics and Fisher's exact test to determine non-random associations between variables.

**Results:** A total of 232 subjects were examined, amongst which 72 (31.03%) had incidental sinus pathologies. Multiple sinus pathologies were found in 36 subjects, 28 had single sinus involvement, and four showed no development of frontal sinus at the age of 11 years. Four subjects had pathology in multiple sinuses as well as no development of frontal sinus at the age of 6–7 years age range.

**Conclusion:** Sinus pathologies are not unusual in the asymptomatic children population, and the incidence is almost equivalent to that of the adult population. Early identification can aid in diagnosing orofacial pain of unknown origin and also if children are susceptible to upper respiratory tract infections and their secondary effects like sleep apnea, mouth breathers, etc.

**Keywords:** Computed tomography, Incidental finding, Maxillary sinus, Paranasal sinus, Sinus pathology.

*International Journal of Clinical Pediatric Dentistry* (2023): 10.5005/jp-journals-10005-2528

## INTRODUCTION

The role of sinuses and their pathologies can always be of prime importance for dentists, especially in case of unknown orofacial pain and/or referred pain in healthy maxillary teeth giving a confounding clinical scenario. But these pathologies have always been overlooked by dentists.

Conventional imaging modalities have a limited role in identifying these pathologies due to inherent shortcomings like soft tissue resolution, overlapping of adjacent bony structures, etc.

In the recent past, the revolutionization in diagnostic imaging using three-dimensional imaging like CT, magnetic resonance imaging (MRI), and cone beam CT (CBCT) has made the complex craniofacial structures more accessible for examination and early and accurate diagnosis of deep-seated pathologies. A review found that the frequency of incidental findings was 23.6%, and this frequency of incidental findings was higher in studies involving CT.<sup>1</sup> However the prevalence of sinus pathologies on MRI was found to vary from 20 to 62% according to Lim et al.<sup>2</sup> On CBCT images study by Raghav et al. revealed 59.7% incidental maxillary sinus pathologies in Indian dental patients.<sup>3</sup>

However, the literature available on incidental sinus findings in children on three-dimensional modalities is limited. This study was designed to assess the prevalence of such in children.

## MATERIALS AND METHODS

The procedure protocol was reviewed and approved by the Institutional Research Ethics Committee. The present study was a

<sup>1,4,5</sup>Department of Pediatric and Preventive Dentistry, JSS Dental College & Hospital, JSS Academy of Higher Education and Research, Mysuru, Karnataka, India

<sup>2</sup>Department of Oral Medicine and Radiology, JSS Dental College and Hospital, JSS Academy of Higher Education and Research, Mysuru, Karnataka, India

<sup>3</sup>Department of Interventional Radiology, Narayana Multispecialty Hospital, Mysuru, Karnataka, India

<sup>6</sup>Department of Periodontology and Implantology, KVG Dental College and Hospital, Sullia, Karnataka, India

**Corresponding Author:** Prasannasrinivas S Deshpande, Department of Oral Medicine and Radiology, JSS Dental College and Hospital, JSS Academy of Higher Education and Research, Mysuru, Karnataka, India, Phone: +91 9886473872, e-mail: drprasanna\_deshpande@yahoo.com

**How to cite this article:** Talwade P, Deshpande PS, Pene S, et al. Incidental Paranasal Sinus Findings on Computed Tomography Images of Pediatric Patients: A Cross-sectional Prevalence Study. *Int J Clin Pediatr Dent* 2023;16(2):292–294.

**Source of support:** Nil

**Conflict of interest:** None

retrospective type and was conducted utilizing existing CT image records from the Radiology department of medical hospitals.

A retrospective study was designed using a total of 232 head and neck CT scan images of pediatric patients of age groups from 0–13 years of age who had visited the Outpatient Department or were admitted to the hospital for various other head and neck-related problems in the past one-year duration.

These 232 subjects were further divided into different age groups, as shown in Table 1, to help the radiologists differentiate between developmental and pathological aspects. Among the 232 total children, 148 (63.8%) were male, and 84 (36.3%) were female. All 232 scans were evaluated by two experienced radiologists using Accuim age Software (Merge e-film, Merge Healthcare, Illinois, United States of America) for incidental pathologic findings.

**RESULTS**

Out of 232 subjects, incidental sinus pathologies were noted in 72 (31.03%). And among those 72 subjects with positive radiographic findings, 36 had pathologies involving multiple sinuses, 28 had single sinus involvement, and four showed no development of frontal sinus at the age of 11 years. Four subjects of 6 years of age had pathology in multiple sinuses along with the failure of frontal sinus development.

Maxillary sinus mucosal thickening (MT) was noted in 48 subjects. Out of which, 28 had bilateral MT, eight subjects had right maxillary MT, and left maxillary MT was seen in 12 subjects (Table 2).

Ethmoid sinus MT was noted in 52 subjects. Bilateral thickening was seen in 32, 12 showed on the right side, and the left was seen in eight subjects. Sphenoid sinus MT was noted in 16 subjects. Frontal sinus MT was noted in eight subjects, while in eight subjects, the sinus was absent (Tables 3 to 5 and Fig. 1).

**DISCUSSION**

The development of the sinuses begins in the 3rd–4th-month intrauterine period; however, at birth, not all the sinuses are well observed on the radiographic images. The majority of pneumatization in the skeleton is observed postnatally.<sup>4</sup>

In the present study, incidental sinus pathologies were noted in 31.03%, which is in accordance with the past studies done by Diamant et al.<sup>5</sup> and Havas et al.,<sup>6</sup> which was around 30%. However, CBCT studies have shown a higher incidence of 24–56%.<sup>7–10</sup> This could be attributed to two facts, firstly, the studies for incidental findings

on CT are few, and secondly that CBCT studies are primarily done on maxillary sinuses while the CT studies include all paranasal sinuses. A study on incidental findings of sinus comparing CT and MRI showed that MRI had a higher prediction rate of 87%. In the same study, the incidence in the younger population (<19 years) and adult population (>19 years) showed no significant variation and was 33–37% which was again similar to the values in the present study.<sup>11</sup>

Asymptomatic patients were evaluated in a few studies involving three-dimensional imaging of sinuses, and pathologies were noted in 8.2–57.1%.

In the present study, MT was the most commonly observed pathology in 68 (29%) scans, followed by underdevelopment/failure to develop in eight cases. Similar MT was observed by Pazera et al.<sup>9</sup> The incidence of MT in maxillary sinus has been observed between 40 and 60% or sometimes higher in studies involving the general population and implant patients.<sup>12</sup> Bilateral MT in maxillary and ethmoid sinus was higher than unilateral involvement.

Frontal sinus was not appreciated in eight subjects from 6 to 11 years. However, the development of the frontal sinus is seen between 1 and 3 years but is appreciated on radiographs only after 4 years. Thereafter it grows in various phases and ceases at maturity. It is absent at birth.<sup>13,14</sup>

**Table 3:** Distribution of pathologies in ethmoid sinus

Age	Ethmoid sinus				
	No finding	MT			Total
		Bilateral	Right	Left	
1–3 years	68	12	0	0	80
4–6 years	28	12	0	0	40
7–9 years	32	4	8	4	48
10–12 years	52	4	4	4	64
Total	180	32	12	8	232

Fisher's exact test  $p = 0.316$

**Table 4:** Distribution of pathologies in sphenoid sinus

Age	Sphenoid sinus			Total
	No finding	MT		
1–3 years	76	4		80
4–6 years	32	8		40
7–9 years	48	0		48
10–12 years	60	4		64
Total	216	16		232

Fisher's exact test  $p = 0.427$

**Table 5:** Distribution of pathologies in frontal sinus

Age	Frontal sinus				
	No finding	MT			Total
		Bilateral	Right	Undeveloped	
1–3 years	80	0	0	0	80
4–6 years	36	0	0	4	40
7–9 years	44	4	0	0	48
10–12 years	56	0	4	4	64
Total	216	4	4	8	232

Fisher's exact test  $p = 0.308$

**Table 1:** Age distribution of subjects

Age	No. of subjects	Percentage
1–3 years	80	34.5
4–6 years	40	17.2
7–9 years	48	20.7
10–12 years	64	27.6
Total	232	100.0

**Table 2:** Distribution of pathologies in maxillary sinus

Age	Maxillary sinus				
	No finding	MT			Total
		Bilateral	Right	Left	
1–3 years	68	8	0	4	80
4–6 years	28	12	0	0	40
7–9 years	32	4	8	4	48
10–12 years	56	4	0	4	64
Total	184	28	8	12	232

Fisher's exact test  $p = 0.319$

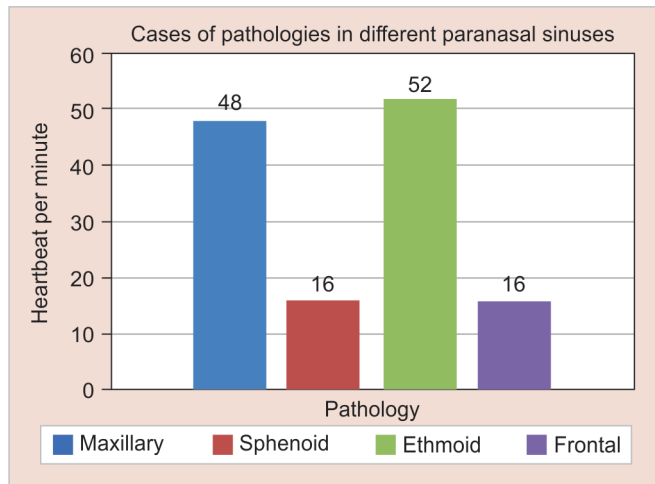


Fig. 1: Number of cases of pathologies in different paranasal sinuses

The maxillary sinus is the first sinus to develop from the mesoderm of the first brachial arch.<sup>4</sup> Development begins at 3 weeks of gestation, and at birth, the size is approximately 7–8 × 4–6 × 3–4 mm. The growth of it is faster in the initial 6 months, remains slow, and studies until the age of 8 years; after that, it becomes much slower and grows up to the age of 15–18 years.<sup>2,4</sup> Agenesis of the maxillary sinus is extremely rare.

Maxillary sinus and maxillary premolar, and first molar root apices have close approximation and are known to have a high rate of pathology transmission. Apical periodontitis and periodontal disease are among the major causes of odontogenic sinus disorders.<sup>15</sup> In the contradictory scenario, patients may suffer from referred pain in these teeth by maxillary sinusitis, making them seek dentist consultation.

A few drawbacks of the present study were—no detailed clinical history except for exclusion criteria were considered and the lack of a sample group with symptomatic patients of upper respiratory infection for comparative analysis. Sinus inflammation may often be found in children as upper respiratory tract infection; however, studies have also shown that these findings are not rare in the asymptomatic common population.<sup>16</sup> Our study was in accordance with them as 30% of the children who were subjected to CT for reasons other than upper respiratory infections and sinusitis had shown pathological changes. Literature has shown that maxillary sinus development affects not only the maxilla but also the growth and symmetry of the lower jaw.<sup>17</sup> Incidental sinus inflammatory diseases and their secondary dental effects may be an impending area of further research.

## CONCLUSION

Sinus pathologies are not unusual in the asymptomatic children population, and the incidence is almost equivalent to that of the adult population. The maxillary sinus is the most involved among all the paranasal sinuses, which have a vital role. Most of these maxillary sinus pathologies were noted in the 7–9 years age group, which marks the beginning of mixed dentition.

## Clinical Significance

Early identification can aid in diagnosing orofacial pain of unknown origin and early identification of children susceptible to upper respiratory tract infections and their secondary effects like sleep apnea, mouth breathers, etc.

## ORCID

Priyanka Talwade <https://orcid.org/0000-0001-6451-2804>

Prasannasrinivas S Deshpande <https://orcid.org/0000-0002-3347-8241>

## REFERENCES

- Lumbreras B, Donat L, Hernández-Aguado I. Incidental findings in imaging diagnostic tests: a systematic review. *Br J Radiol* 2010;83(988):276–289. DOI: 10.1259/bjr/98067945
- Lim WK, Ram B, Fasulakis S, et al. Incidental magnetic resonance image sinus abnormalities in asymptomatic Australian children. *J Laryngol Otol* 2003;117(12):969–972. DOI: 10.1258/002221503322683858
- Raghav M, Karjodkar FR, Sontakke S, et al. Prevalence of incidental maxillary sinus pathologies in dental patients on cone-beam computed tomographic images. *Contemp Clin Dent* 2014;5(3):361–365. DOI: 10.4103/0976-237X.137949
- Değermenci M, Ertekin T, Ülger H, et al. The age-related development of maxillary sinus in children. *J Craniofac Surg* 2016;27(1):e38–e44. DOI: 10.1097/SCS.0000000000002304
- Diament MJ, Senac MO Jr, Gilsanz V, et al. Prevalence of incidental paranasal sinuses opacification in pediatric patients: a CT study. *J Comput Assist Tomogr* 1987;11(3):426–431. DOI: 10.1097/00004728-198705000-00011
- Havas TE, Motbey JA, Gullane PJ. Prevalence of incidental abnormalities on computed tomographic scans of the paranasal sinuses. *Arch Otolaryngol Head Neck Surg* 1988;114(8):856–859. DOI: 10.1001/archotol.1988.01860200040012
- Rege IC, Sousa TO, Leles CR, et al. Occurrence of maxillary sinus abnormalities detected by cone beam CT in asymptomatic patients. *BMC Oral Health* 2012;12:30. DOI: 10.1186/1472-6831-12-30
- Cha JY, Mah J, Sinclair P. Incidental findings in the maxillofacial area with 3-dimensional cone-beam imaging. *Am J Orthod Dentofacial Orthop* 2007;132(1):7–14. DOI: 10.1016/j.ajodo.2005.08.041
- Pazera P, Bornstein MM, Pazera A, et al. Incidental maxillary sinus findings in orthodontic patients: a radiographic analysis using cone-beam computed tomography (CBCT). *Orthod Craniofac Res* 2011;14(1):17–24. DOI: 10.1111/j.1601-6343.2010.01502.x
- Ritter L, Lutz J, Neugebauer J, et al. Prevalence of pathologic findings in the maxillary sinus in cone-beam computerized tomography. *Oral Surg Oral Med Oral Pathol Oral Radiol Endod* 2011;111(5):634–340. DOI: 10.1016/j.tripleo.2010.12.007
- Nazri M, Bux SI, Tengku-Kamalden TF, et al. Incidental detection of sinus mucosal abnormalities on CT and MRI imaging of the head. *Quant Imaging Med Surg* 2013;3(2):82–88. DOI: 10.3978/j.issn.2223-4292.2013.03.06
- Vogiatzi T, Kloukos D, Scarfe WC, et al. Incidence of anatomical variations and disease of the maxillary sinuses as identified by cone beam computed tomography: a systematic review. *Int J Oral Maxillofac Implants* 2014;29(6):1301–1304. DOI: 10.11607/jomi.3644
- Kim HJ, Park ED, Choi PY, et al. Normal development of the paranasal sinuses in children: a CT study. *J Korean Radiol Soc* 1993;29(6):1313–1319.
- Kaitlin Moore, Ann Ross. Frontal sinus development and juvenile age estimation. *Anat Rec (Hoboken)* 2017;300(9):1609–1617. DOI: 10.1002/ar.23614
- Roque-Torres GD, Ramirez-Sotelo LR, Vaz SL, et al. Association between maxillary sinus pathologies and healthy teeth. *Braz J Otorhinolaryngol* 2016;82(1):33–38. DOI: 10.1016/j.bjorl.2015.11.004
- Kristo A, Alho OP, Luotonen J, et al. Cross-sectional survey of paranasal sinus magnetic resonance imaging findings in schoolchildren. *Acta Paediatr* 2003;92(1):34–36. DOI: 10.1111/j.1651-2227.2003.tb00465.x
- Basdra EK, Stellzig A, Komposch G. The importance of the maxillary sinuses in facial development: a case report. *Eur J Orthod* 1998;20(1):1–4. DOI: 10.1093/ejo/20.1.1