



Contents lists available at ScienceDirect

# Asia-Pacific Journal of Sports Medicine, Arthroscopy, Rehabilitation and Technology

journal homepage: [www.ap-smart.com](http://www.ap-smart.com)

## Original Article

## Middle-to long-term outcome after medial patellofemoral ligament reconstruction with Insall's proximal realignment for patellar instability

Ryo Shimizu <sup>a,\*</sup>, Yoshio Sumen <sup>a</sup>, Kazuki Sakaridani <sup>a</sup>, Masaki Matsuura <sup>a</sup>, Nobuo Adachi <sup>b</sup><sup>a</sup> Department of Orthopaedic Surgery, JA Onomichi General Hospital, 1-10-23, Hirahara, Onomichi, Hiroshima, 722-8508, Japan<sup>b</sup> Department of Orthopaedic Surgery, Graduate School of Biomedical and Health Sciences, Hiroshima University, 1-2-3 Kasumi, Minami-ku, Hiroshima, 734-8551, Japan

## ARTICLE INFO

## Article history:

Received 8 November 2018

Received in revised form

28 January 2019

Accepted 18 February 2019

Available online 1 April 2019

## ABSTRACT

**Background:** Recently, medial patellofemoral ligament (MPFL) reconstruction has become a common, widely used procedure to treat patellar instability. However, few reports exist on the long-term outcome after MPFL reconstruction. We elucidated the middle- to long-term outcome after MPFL reconstruction with Insall's proximal realignment. **Methods:** From 1999 to 2012, 42 knees of 32 patients who underwent MPFL reconstruction with Insall's proximal realignment were reviewed with a minimum follow-up of five years. Patients who could visit our office and receive some designated examinations were included in this study. The re-dislocation rate and patellar apprehension sign postoperatively were evaluated. The Kujala score and Knee Injury and Osteoarthritis Outcome Score (KOOS) were calculated. We assessed the images using plane x-ray and magnetic resonance imaging (MRI). The tilting angle (TA), congruence angle (CA), and lateral shift ratio (LSR) on the plane x-ray were measured pre- and postoperatively and at final follow-up. Using MRI, osteochondral lesions at the patellofemoral joint were evaluated.

**Results:** A total of 20 knees of 15 patients (two male, 13 female) who could visit our office were studied. The follow-up rate was 47.6%. The mean age at operation was 19.9 (11–41) years and mean follow-up was 123 (60–215) months. One knee (5.5%) had a history of postoperative subluxation, and five (25%) had a positive apprehension sign. The mean Kujala score significantly improved from 65.5 to 86.1 points ( $P < 0.05$ ). The mean KOOS (symptom, pain, activities of daily living [ADL], sports, quality of life [QOL]) was 74.4, 92.4, 97.3, 84.1, and 73.2 points, respectively, at final follow-up. On the plane x-ray, patellofemoral alignment was improved postoperatively, and this improvement was maintained at final follow-up. On MRI, in five of 20 cases, the patellofemoral osteoarthritic change was observed at final follow-up. However, in four of these five knees with severe osteochondral lesions, osteochondral fixation or transplantation surgery had been performed. Only one of the remaining 15 knees had a patellofemoral osteoarthritic change observed at final follow-up.

**Conclusion:** Middle- to long-term outcome after MPFL reconstruction with Insall's proximal realignment at our institution was evaluated, and good clinical results were observed. Most patients who did not have a severe cartilage lesion preoperatively did not develop osteoarthritic change.

© 2019 Asia Pacific Knee, Arthroscopy and Sports Medicine Society. Published by Elsevier (Singapore) Pte Ltd. This is an open access article under the CC BY-NC-ND license (<http://creativecommons.org/licenses/by-nc-nd/4.0/>).

## Introduction

After the medial patellofemoral ligament (MPFL) was reported to be the primary stabilizer against lateral patellar instability,<sup>1–3</sup>

MPFL reconstruction became a common and widely used procedure to treat patellar instability, including recurrent lateral dislocation of the patella. Many different surgical techniques have been reported for MPFL reconstruction, but graft choice, type of fixation, graft positioning, and correct tension remain controversial. MPFL reconstruction has been implemented on a large scale, alone and combined with other procedures, to correct soft tissue imbalance or bony malalignment. Many surgical procedures have been

\* Corresponding author.

E-mail address: [shimiro22@hotmail.com](mailto:shimiro22@hotmail.com) (R. Shimizu).

performed, and good or excellent clinical outcomes have been reported.<sup>4–6</sup> However, few reports exist on the long-term outcome after MPFL reconstruction. At our institution, MPFL reconstruction with Insall's proximal realignment<sup>7</sup> has been performed in patients who complained of patellar instability since 1999. Previous studies showed that the MPFL contribution to resisting lateral patellar dislocation is greatest during the first 30° of knee flexion.<sup>8,9</sup> With >30° of knee flexion, MPFL tension gradually decreased. Thus, in our surgical procedure, advancement of the vastus medialis oblique was performed in all cases because it stabilizes the lateral patella shift at over 30° flexion angle.

Because relatively young patients experience recurrent patellar instability after lateral patellar dislocation, the long-term clinical outcome is important. When a long time passes, the recurrence rate of patellar dislocation or the patellofemoral joint disorder may increase. The purpose of this study is to elucidate the middle-to long-term outcome after MPFL reconstruction with Insall's proximal realignment at our institution for patients with patellar instability.

## Materials and methods

This retrospective case series was approved by the institutional review board of our hospital (Approval No: OJH-201847).

### Subjects

From 1999 to 2012, 42 knees of 32 patients who underwent MPFL reconstruction with Insall's proximal realignment to treat patellar instability at our institution were reviewed with a minimum follow-up of five years. The patients' clinical records were collected. After telephone contact, patients who could visit our office and receive some designated examinations were included in this study. Patients who could not be contacted or refused to visit our office were excluded. Written informed consent was obtained from all study patients.

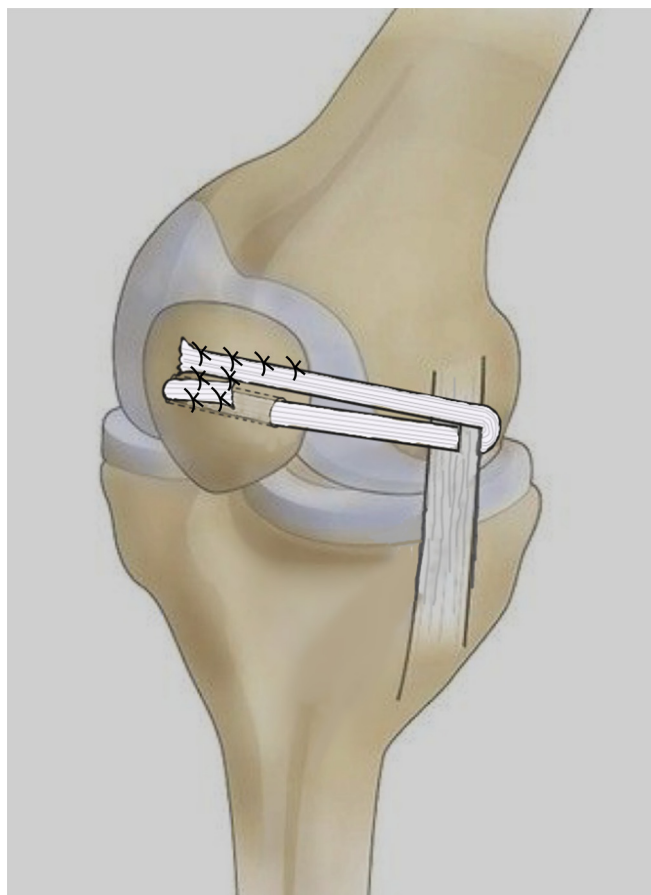
### Surgical procedure

All procedures were performed by one experienced senior author (SY). Our surgical procedure was based on the method developed by Ochi.<sup>10,11</sup> First, we harvested the semitendinosus tendon, as an MPFL graft, using an open tendon stripper. The muscle tissue was removed from the harvested tendon. Then, we performed arthroscopy to evaluate the cartilage lesions. For graft fixation of the femoral side, a 2 cm incision was made over the femoral attachment of the medial collateral ligament (MCL) to expose its femoral attachment. A 1 cm slit was made in the posterior one-third of the proximal MCL, and the harvested graft was passed through it. A gently curved incision was made over the patella from the proximal to distal poles. It was possible to expose the lateral and medial sides of the patella with this incision. If the patient had lateral retinacular tightness, we performed a lateral retinacular release. However, if the patient had medial instability, which was checked by the surgeon manually, we did not perform lateral retinacular release because it might increase medial instability of the patella postoperatively. Additionally, in cases with a massive osteochondral lesion, we fixated the osteochondral fragment using bioabsorbable pins or osteochondral transplantation. For graft fixation of the patella side, a bone tunnel was made using a 4.5 mm cannulated drill after a 2.0 mm guidewire was passed from the medial to the lateral aspects. One side of the graft was passed through a bone tunnel, and the other side was not passed on the patella (Fig. 1). The transferred tendon was then sutured onto the patella surface with the knee flexed at 30°. When the graft was sutured, an assistant kept the patellar position manually as the

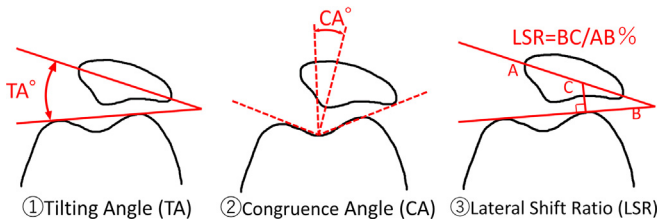
lateral edge of the patella and the lateral articular margin of the femoral trochlea were congruent to avoid medial excessive tension. In six patients who underwent osteochondral surgery because of a massive osteochondral patellar lesion, it was difficult to make a bone tunnel in the patella. In those cases, both sides of the graft tendon were sutured on the patellar surface. Finally, we performed vastus medialis advancement with the knee flexed at 40°. For postoperative rehabilitation, the patients' knees were immobilized for 10 days with a soft knee brace. Ten days postoperatively, the patients were allowed to start range of motion. Three weeks postoperatively, they began partial weightbearing. After approximately six weeks, the patients could walk without crutches.

### Assessment

The primary outcome was re-dislocation of the patella. The secondary outcome included the patellar apprehension sign, Kujala score,<sup>12</sup> and the Knee Injury and Osteoarthritis Outcome Score (KOOS)<sup>13</sup> at final follow-up. Patellofemoral joint alignment was evaluated using the skyline view of a plain x-ray at 30° and 60° of flexion. The tilting angle (TA), congruence angle (CA), and lateral shift ratio (LSR) were measured preoperatively, at three months postoperatively, and at final follow-up (Fig. 2). The patellofemoral joint cartilage was evaluated using magnetic resonance imaging (MRI) at final follow-up. Proton density-weighted axial images were evaluated by the first author. The integrity of the cartilage and osteochondral lesion were evaluated.



**Fig. 1.** A free semitendinosus tendon was transferred through the pulley of the posterior one-third of the proximal medial collateral ligament. One side of the graft was transferred through a 4.5 mm diameter patellar bone tunnel. Both sides of the graft were sutured with periosteum onto the patella.



**Fig. 2.** These parameters are measured on an x-ray skyline view, at 30° and 60° knee flexion, pre- and postoperatively and at final follow-up. (1) TA is formed between the patellar transverse axis line and the line tangent to the anterior part of the medial and lateral femoral condyle. (2) CA is measured by bisecting the sulcus angle to construct a reference line and then projecting a second line from the apex of the sulcus angle to the central ridge of the patella. (3) LSR is obtained by drawing three lines: 1) the patellar transverse axis, 2) tangent to the anterior medial and lateral femoral condyle, and 3) vertical to the first line from the anterior part of the lateral femoral condyle. The LSR is calculated from the distance of BC divided by the distance of AB.

**Statistical analysis**

Categorical variables are presented as frequencies and percentages. Continuous variables are presented as mean values and standard deviation or range. A paired *t*-test was used to compare the Kujala score preoperatively and at final follow-up. Repeated analysis of variance was used for time series comparison of TA, CA, and LSR measured from x-ray skyline views pre- and postoperatively, and at final follow-up. All calculations and statistical analyses were performed using SPSS 11.0 (SPSS, Inc., Chicago, IL, USA). Statistical significance level was set at *P* < 0.05.

**Results**

Twenty knees of 15 patients (2 males, 13 females) who could visit our office were evaluated as a final follow-up and included in this study. Eight patients replied that they could not visit us because they already had moved far from our hospital. We could not contact the remaining nine patients. The follow-up rate was 47.6%, mean follow-up was 123 (60–215) months, and mean age at operation was 19.9 (11–41) years. Six knees (30%) with severe osteochondral patellar lesions were treated with osteochondral fixation (three knees) and osteochondral transplantation (three knees). The preoperative mean Kujala score was 65.5 ± 17.0 points. The demographic data are shown in Table 1.

**Clinical outcome**

Re-dislocation was not observed in this series, but one patient had a history of subluxation postoperatively, and five knees (25%) had a positive apprehensive sign. Regarding the patient-reported outcome at final follow-up, mean the Kujala score was 86.7 ± 14.9 points, which was significantly improved compared to the score preoperatively (*P* < 0.05). The subscales of mean KOOS at final follow-up were as follows: Symptom (75.5 ± 17.1), pain

**Table 1**  
Demographic data.

Subjects	20 knees (15 patients)	
Gender	male 2	female 13
Rt Lt	Rt 11	Lt 9
Mean age at operation (years)	19.9 (11–41)	
Mean follow up (months)	123 (60–215)	
Patella alta (Insall-salvati index>1.2)	7 (35%)	
Sulcus angle	149.7 ± 11.2	
Osteochondral lesion before surgery	6 (30%)	
Preoperative Mean Kujala's Score	65.5 ± 17.0	

**Table 2**  
Clinical Outcome at final follow up.

Re-dislocation	none (1 subluxation)
Apprehension sign	5 (25%)
Mean Kujala Score	86.7 ± 14.9
Mean KOOS	
Symptom	75.5 ± 17.1
Pain	92.1 ± 12.1
ADL	97.3 ± 5.85
Sports	83.3 ± 17.9
QOL	73.5 ± 24.3

KOOS ( The Knee Injury and Osteoarthritis Outcome Score ).

(92.1 ± 12.1), activities of daily living (ADL; 97.6 ± 5.85), sports (73.5 ± 24.3), and quality of life (QOL, 73.5 ± 24.3). Regarding postoperative complications, one knee had temporary joint stiffness at two months postoperatively, but improved to full range of motion after manipulation under anesthesia. Limited range of motion was not observed in all knees at final follow-up. The clinical outcome is shown at Table 2.

**Radiographic outcome of patellofemoral alignment**

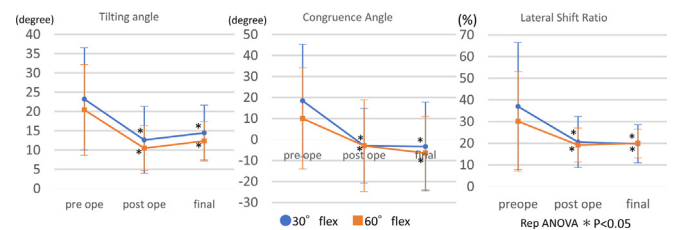
The graphic charts in Fig. 3 show the mean values of TA, CA, and LSR on x-ray as time passes. Each value, at 30° and 60° of flexion, significantly improved postoperatively, and these improvements were maintained at final follow-up (*P* < 0.05).

**Cartilage evaluation on MRI**

In our case series, 15 knees had no evidence of cartilage and subchondral lesion at the patellofemoral joint on MRI at final follow-up. Of the remaining five knees, three had cartilage irregularity, and all had subchondral bone changes that included high intensity or a subchondral cyst. These five knees had been considered cases of patellofemoral joint osteoarthritic change postoperatively. Four of these five knees had a severe osteochondral lesion preoperatively, and osteochondral fixation or osteochondral transplantation surgery had been performed simultaneously. Only one of 15 knees without a severe osteochondral lesion preoperatively had osteoarthritic change at final follow-up.

**Discussion**

The middle-to long-term clinical outcome of MPFL reconstruction with Insall's proximal realignment was considered almost acceptable. There was no incidence of re-dislocation and no major complications with maintaining axial patellofemoral alignment corrected by surgery. Patient-reported outcomes, including the Kujala score and KOOS, were almost comparable to other



**Fig. 3.** This graphic chart shows the time course of each parameter measured from the x-ray skyline view. The circle dot represents the parameters of the 30° knee flexion. The square dot represents the parameters 60° of knee flexion. Repeated ANOVA was performed, and significant difference was *P* < 0.05.

previously reported outcomes. In a recent systematic review of clinical outcomes after MPFL reconstruction, Daniel et al.<sup>14</sup> reported a mean postoperative Kujala score of 85.8 (95% confidence interval [CI], 81.6–90.0) from 14 articles. Long-term follow-up studies have been reported. Nomura et al.<sup>15</sup> reported that 22 patients who underwent MPFL reconstruction were reviewed at a mean follow-up of 11.9 years, and the postoperative Kujala score was 94.2 points. Deie et al.<sup>10</sup> also reported the clinical outcome of 33 at a mean of 120 months follow-up after MPFL reconstruction. The Kujala score and x-ray alignment were significantly improved postoperatively, and those good results were maintained until final follow-up.

In our study, radiologic alignment using the skyline view was improved postoperatively and maintained long-term postoperatively at 30° and 60° of flexion. Five cases (25%) had positive apprehension signs at final follow-up. The previously reported rate of positive apprehension sign ranged from 0% to 20.8%.<sup>10,15–18</sup> Kita et al.<sup>18</sup> reported the positive apprehension sign after MPFL reconstruction was evident in eight of 44 knees (18.2%). They concluded that the risk factor associated with patellar instability was severe trochlea dysplasia concomitant with an increased tibial tuberosity-trochlear groove (TT-TG) distance. Although we did not evaluate those bony risk factors of patellar instability, three of the five with a positive apprehension sign had severe osteochondral lesions preoperatively. These osteochondral lesions might affect the appearance of a positive apprehension sign. During lateral stress to the patellofemoral joint, an osteochondral lesion might cause discomfort.

The important issue of this long-term follow-up was influence on the patellofemoral cartilage after changing the patellofemoral alignment with surgical treatment. Before MPFL reconstruction has been performed widely, other kinds of realignment surgeries or trochleoplasty were performed. Although good short-term clinical results were reported after these surgeries, patellofemoral osteoarthritic change was commonly observed in the long-term. Nakagawa et al.<sup>19</sup> reported that definite osteoarthritic changes were detected on radiographs in 13 of 31 knees (42%) after the Elmslie-Trillat procedure with a mean follow-up of 161 months. Knoch et al.<sup>20</sup> reported that degenerative changes of the patellofemoral joint developed in 30% of the knees after trochleoplasty for recurrent patellar dislocation with a mean follow-up of 8.3 years. Shllanpää et al.<sup>21</sup> reported that patellofemoral full-thickness cartilage lesions were observed on MRI images in 78% of patients after traditional nonanatomic patellofemoral stabilizing surgery with a minimum follow-up of 10 years. On the other hand, Nomura et al.<sup>13</sup> reported that only two of 24 knees (8.3%) had a definite osteoarthritic change on radiographs after MPFL reconstruction with a mean follow-up of 11.9 years. In our study, on plane x-ray evaluation, three of 20 knees (15%) had an osteoarthritic change postoperatively. This is one of the few studies evaluating osteochondral change using MRI, and cartilage irregularity or an osteochondral lesion was observed in five of 20 knees (25%). However, four of these five knees had a severe osteochondral lesion preoperatively and underwent osteochondral surgery simultaneously. Except for these cases, cartilage deterioration was observed in only one of 15 knees (6.7%) on MRI. Thus, our MPFL reconstruction procedure had less influence on the patellofemoral joint long-term postoperatively than traditional methods. However, the cases with a severe osteochondral lesion preoperatively have a risk of cartilage degeneration long-term postoperatively.

The advantage of our surgical procedure was that the bone tunnel and metal implant for femoral fixation were not used. Therefore, our procedure could be performed for skeletally immature patients with no risk of damaging the femoral physal plate.

Our study has several limitations. The follow-up rate was very low because, after a long-term postoperatively, it was difficult to

contact the patients because they were relatively young students at surgery and had already moved for employment or entrance into a higher-grade school. The surgical procedure was not the same in all knees because the lateral retinacular release was performed only in case the surgeon manually checked for medial stability during surgery. However, MPFL reconstruction and Insall's vastus medialis oblique advancement were performed in all cases, and the clinical and radiographical results were satisfactory. The patellofemoral cartilage was not deteriorated long-term postoperatively in cases where there was no preoperative evidence of severe osteochondral lesions.

MPFL reconstruction, including our surgical procedure, is recommended as a strategy for treating recurrent lateral patellar dislocation, because the clinical outcomes were good and the radiologic alignment improved for a long-term postoperatively. However, if a severe osteochondral lesion is coexisted, cartilage deterioration of patellofemoral joint was observed long-term after MPFL reconstruction even with osteochondral repair surgery. To avoid the degenerative change of patellofemoral joint, the better osteochondral repair procedures including regenerative medicine should be considered.

## Conclusion

Middle-to long-term outcomes after MPFL reconstruction with Insall's proximal realignment at our institution were evaluated, and good clinical results were observed. Degenerative change at the patellofemoral joint did not occur in most patients without a severe cartilage lesion preoperatively.

## Conflict of interest

None of the authors have relevant conflicts of interest to declare.

## References

- Desio SM, Burks RT, Bachus KN. Soft tissue restraints to lateral patellar translation in the human knee. *Am J Sports Med.* 1998;26(1):59–65.
- Conlan T, Garth WP, Lemons JE. Evaluation of the medial soft-tissue restraints of the extensor mechanism of the knee. *J Bone Jt Surg Ser A.* 1993;75(5):682–693.
- Hautamaa PV, Fithian DC, Kaufman KR, Daniel DM, Pohlmeier AM. Medial soft tissue restraints in lateral patellar instability and repair. *Clin Orthop Relat Res.* 1998;349:174–182.
- Mackay ND, Smith NA, Parsons N, Spalding T, Thompson P, Sprowson AP. Medial patellofemoral ligament reconstruction for patellar dislocation: a systematic review. *Orthop J Sport Med.* 2014;2(8):1–7.
- Fisher B, Nyland J, Brand E, Curtin B. Medial patellofemoral ligament reconstruction for recurrent patellar dislocation: a systematic review including rehabilitation and return-to-sports efficacy. *Arthroscopy.* 2010;26(10):1384–1394.
- Burnham JM, Howard JS, Hayes CB, Lattermann C. Medial patellofemoral ligament reconstruction with concomitant tibial tubercle transfer: a systematic review of outcomes and complications. *Arthroscopy.* 2016;32(6):1185–1195.
- Insall J, Falvo KA, Wise DW. Chondromalacia patellae. a prospective study. *J Bone Joint Surg Am.* 1976;58(1):1–8.
- Amis AA, Firer P, Mountney J, Senavongse W, Thomas NP. Anatomy and biomechanics of the medial patellofemoral ligament. *Knee.* 2003;10(3):215–220.
- Sanchis-Alfonso V, Ramirez-Fuentes C, Montesinos-Berry E, Domenech J, Martí-Bonmati L. Femoral insertion site of the graft used to replace the medial patellofemoral ligament influences the ligament dynamic changes during knee flexion and the clinical outcome. *Knee Surg Sports Traumatol Arthrosc.* 2017;25(8):2433–2441.
- Deie M, Ochi M, Sumen Y, Adachi N, Kobayashi K, Yasumoto M. A long-term follow-up study after medial patellofemoral ligament reconstruction using the transferred semitendinosus tendon for patellar dislocation. *Knee Surg Sports Traumatol Arthrosc.* 2005;13(7):522–528.
- Ochi M, Deie M, Ikuta Y. A new surgical procedure for recurrent patellar dislocation and subluxation. In: *2nd AOSSM/JOSSM Trans-Pacific Meeting* 38. 1993.
- Kujala UM, Jaakkola LH, Koskinen SK, Taimela S, Hurme M, Nelimarkka O. Scoring of patellofemoral disorders. *Arthroscopy.* 1993;9(2):159–163.
- Roos EM, Roos HP, Lohmander LS, Ekdahl C, Beynon BD. Knee Injury and



- osteoarthritis outcome score (KOOS)—development of a self-administered outcome measure. *J Orthop Sports Phys Ther.* 1998;28(2):88–96.
14. Schneider DK, Grawe B, Magnussen RA, et al. Outcomes after isolated medial patellofemoral ligament reconstruction for the treatment of recurrent lateral patellar dislocations. *Am J Sports Med.* 2016;44(11):2993–3005.
  15. Nomura E, Inoue M, Kobayashi S. Long-term follow-up and knee osteoarthritis change after medial patellofemoral ligament reconstruction for recurrent patellar dislocation. *Am J Sports Med.* 2007;35(11):1851–1858.
  16. Han H, Xia Y, Yun X, Wu M. Anatomical transverse patella double tunnel reconstruction of medial patellofemoral ligament with a hamstring tendon autograft for recurrent patellar dislocation. *Arch Orthop Trauma Surg.* 2011;131(3):343–351.
  17. Astur DC, Gouveia GB, de Souza Borges JH, et al. Medial patellofemoral ligament reconstruction: a longitudinal study comparison of 2 techniques with 2 and 5-years follow-up. *Open Orthop J.* 2015;9(2):198–203.
  18. Kita K, Tanaka Y, Toritsuka Y, et al. Factors affecting the outcomes of double-bundle medial patellofemoral ligament reconstruction for recurrent patellar dislocations evaluated by multivariate analysis. *Am J Sports Med.* 2015;43(12):2988–2996.
  19. Nakagawa K, Wada Y, Minamide M, Tsuchiya A, Moriya H. Deterioration of long-term clinical results after the Elmslie-Trillat procedure for dislocation of the patella. *J Bone Joint Surg Br.* 2002;84(6):861–864.
  20. von Knoch F. Trochleaplasty for recurrent patellar dislocation in association with trochlear dysplasia: a 4- to 14-year follow-up study. *J Bone Jt Surg Br.* 2006;88(10):1331–1335.
  21. Sillanpää PJ, Mattila VM, Visuri T, Mäenpää H, Pihlajamäki H. Patellofemoral osteoarthritis in patients with operative treatment for patellar dislocation: a magnetic resonance-based analysis. *Knee Surg Sports Traumatol Arthrosc.* 2011;19(2):230–235.