

Contents lists available at [ScienceDirect](http://www.sciencedirect.com)

## International Journal of Surgery Case Reports

journal homepage: [www.casereports.com](http://www.casereports.com)

## A rare case of a intracardiac lipoma

Sarabjeet Singh<sup>a,\*</sup>, Mukesh Singh<sup>b</sup>, Daniela Kovacs<sup>b</sup>, Daniel Benatar<sup>b</sup>, Sandeep Khosla<sup>b</sup>, Harpreet Singh<sup>c</sup><sup>a</sup> Department of Medicine at Mount Sinai Hospital, 1500 S California, Dept of medicine 9th floor, Chicago, IL 60608, USA<sup>b</sup> Department of Cardiology at Mount Sinai Hospital, USA<sup>c</sup> Windsor University School of Medicine, USA

## ARTICLE INFO

## Article history:

Received 11 December 2014

Received in revised form 14 February 2015

Accepted 15 February 2015

Available online 20 February 2015

## ABSTRACT

**INTRODUCTION:** Primary tumors of the heart are exceedingly rare, accounting for less than 5% of all cardiac tumors; the remaining 95% of tumors are metastatic tumors to the heart. The most common primary cardiac tumors in adults are myxomas (usually occurring in the left atrium) followed by papillary fibroelastomas and lipomas with rhabdomyoma the most common in children.

**PRESENTATION OF CASE:** We are presenting a case of a 74-years-old female who initially presents with dizziness. No other associated symptoms reported and initial labs were in normal range. Echocardiogram was done as part of the dizziness/syncope work up which demonstrated a large right atrial mass. Due to the size of the mass and patient being symptomatic the mass was surgically resected with complete resolution of her symptoms and pathology consistent with a lipoma.

**DISCUSSION:** Cardiac lipomas are benign and may be associated with a spectrum of symptoms which depends upon the size and location of the lipoma; although most cardiac lipomas are found incidentally and are asymptomatic. The best radiologic study to identify and help differentiate cardiac lipoma is echocardiogram. Cardiac computerized tomography (CCT) and cardiac magnetic resonance imaging (CMR) also place a role in differentiating cardiac lipomas from other cardiac tumors/lesions.

**CONCLUSION:** Cardiac lipomas are benign primary tumors which have no defined age or sex distribution and present with a wide range of symptoms. Echocardiography is first line diagnosis method with CCT/CMR for better imaging before surgical intervention. Surgical resection of the symptomatic cardiac lipomas remains the mainstream treatment.

Published by Elsevier Ltd. on behalf of Surgical Associates Ltd. This is an open access article under the CC BY-NC-ND license (<http://creativecommons.org/licenses/by-nc-nd/4.0/>).

## 1. Introduction

Primary tumors of the heart are exceedingly rare, accounting for less than 5% of all cardiac tumors; the remaining 95% of tumors are metastatic tumors to the heart. The most common primary cardiac tumors in adults are myxomas (usually occurring in the left atrium), followed by papillary fibroelastomas and lipomas. In children the most common cardiac tumor is rhabdomyoma. We are presenting a rare case of a large right atrial lipoma where the patient presented with dizziness and symptom resolution status post surgical resection.

## 2. Case

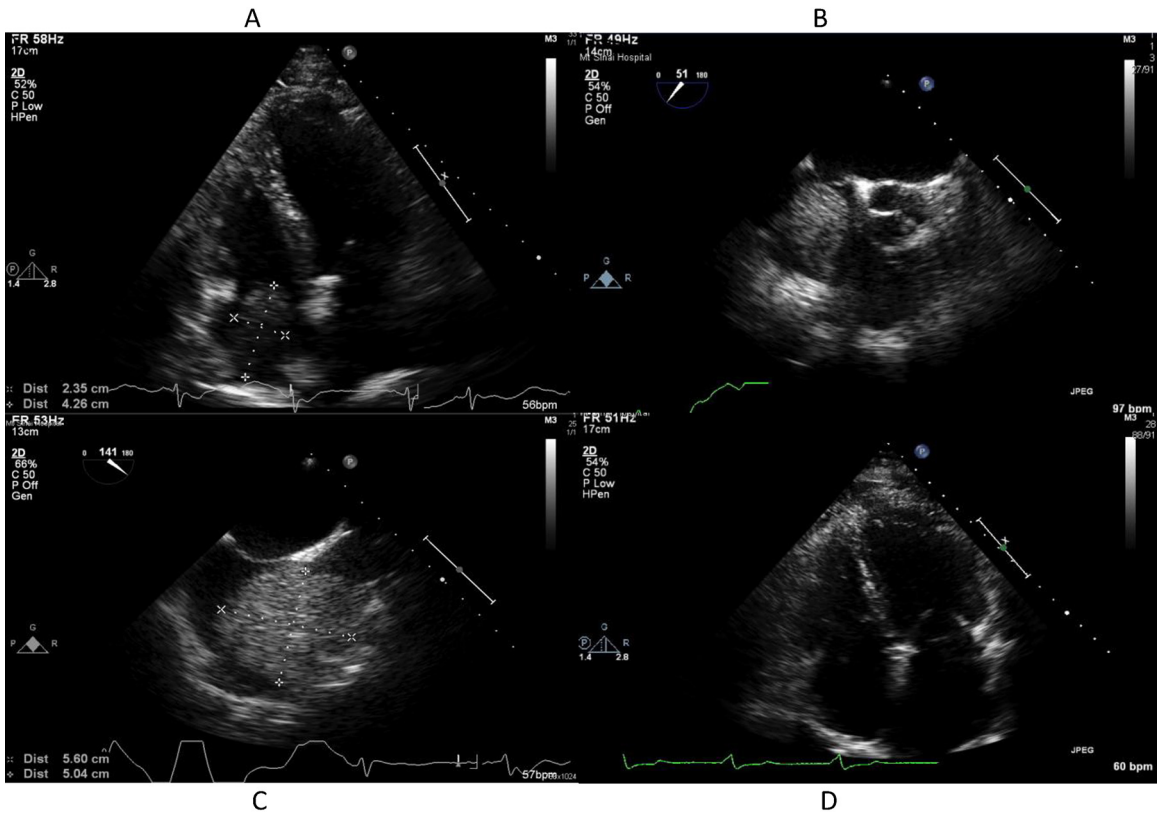
A 74-years-old female presented with history of recurrent episodes of intermittent dizziness for several months and pre-syncope episode. The dizziness was non-exertional and not related

to postural changes or meals; in particular there was no relation to head or neck movement. There was no associated chest pain, dyspnea, orthopnea, paroxysmal nocturnal dyspnea, leg swelling, palpitations, nausea, vomiting, or hearing loss. Her past medical history and family history were unremarkable. She denied smoking, alcohol or illicit drug use. Vital signs on presentation were: heart rate: 48 beats/min, regular rhythm, blood pressure: 145/62 mm Hg, respiratory rate: 16/min, SpO<sub>2</sub>: 99% on room air. There were no orthostatic changes in her blood pressure and heart rates measured in lying and standing position. Physical examination revealed normal cardiovascular, respiratory and nervous system findings. Laboratory tests demonstrated a normal complete blood count, renal function, electrolytes and liver function tests.

Computed tomography (CT) of brain showed no acute pathology. Standard 12 lead electrocardiogram (ECG) showed normal sinus rhythm, normal P waves and QRS complex with flattened T waves in inferior leads. She was admitted to the telemetry unit and was noted to have sinus bradycardia and no other significant arrhythmias on the monitor. Transthoracic echocardiogram showed normal left ventricular systolic function with a large mass in the right atrium. (Fig. 1A) Following this finding a

\* Corresponding author. Tel.: +1 5168088587.

E-mail address: [Serge.singh@yahoo.com](mailto:Serge.singh@yahoo.com) (S. Singh).

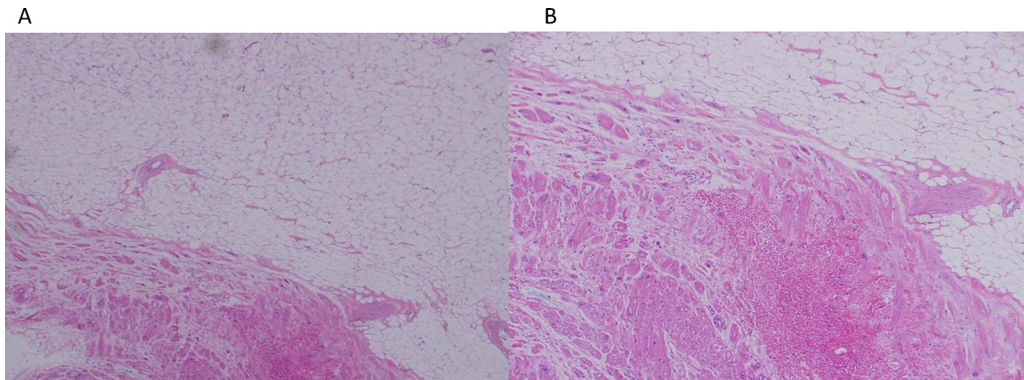


**Fig. 1.** A: transthoracic echocardiogram (TTE): showing a mobile mass in right atria. B: transesophageal echocardiogram (TEE) shows mass in right atria. C: transesophageal echocardiogram (TEE) image of the R atrial mass and with approximate size. D: transthoracic echocardiogram (TTE) 1 year post surgery.

trans-esophageal echocardiogram was performed which showed 5.6 cm × 5 cm large mass attached to free wall of the right atrium close to the superior vena cava (Fig. 1B and C). The TEE demonstrated an ejection fraction of greater than 65%, no abnormalities of the aortic or mitral valve with mild physiologic tricuspid regurgitation. Following this cardiothoracic surgery was consulted for lipomectomy and it was decided that no further imaging such as cardiac computerized tomography (CCT) or cardiac magnetic resonance images (CMR) were needed. During the open heart surgery it was noted that the mass was 6 cm × 6 cm which was intimately attached to the right side of the atrial septum and the right atrial free wall. Histological examination of the surgical specimen was consistent with a lipoma (Fig. 2). Post-surgery, she recovered well with complete resolution of her symptoms (Fig. 1D).

**3. Discussion**

Cardiac lipomas are benign tumors which are asymptomatic and are typically found incidentally on echocardiography, CCT or CMR. Cardiac lipomas are well encapsulated tumors composed of mature fat cells and are much less common than lipomatous hypertrophy. Cardiac lipoma can be associated with a spectrum of symptoms that depend upon the size and location of the lipoma. The indication for surgical resection is the presence of symptoms which includes heart failure and obstructive symptoms due to blockage of the intra-cardiac circulation by hindering the opening and closing of valves. They can also cause atrial or ventricular arrhythmias including heart block by invading the cardiac conduction system. There have also been reports of thromboembolisms to



**Fig. 2.** A: pathology slide showing normal cardiac tissue on left lower side and lipoma on right upper stained with hematoxylin and eosin (H and E) at 100 magnification. B: high-1000 magnification of boundary of normal cardiac and lipoma tissue.

**Table 1**  
Literature review of right atrial cardiac lipoma case reports.

Case reports	Age	Presenting symptom	Size of lipoma	Diagnosis method	Management
Mullen et al. (1995) [2]	17 Female	Dyspnea and decrease exercises tolerance	25 cm × 15 cm	ECHO/CMR	Surgical resection
Sankar et al. (1998) [3]	38 Male	Palpitation	5 cm × 4 cm	ECHO	Surgical resection
Mauera et al. (2001) [4]	54 Female	Palpitation	7 cm × 3 cm	ECHO/CCT	Surgical resection
Silveira et al. (2001) [5]	54 Male	Fever of unknown origin	6 cm × 5 cm	ECHO/CCT	Surgical resection
Pego-Fernandes et al. (2003) [6]	48 Male	HTN and epistaxis	4.6 cm × 3.5 cm	ECHO/PET	Surgical resection
Tempin et al. (2006) [7]	51 Male	Dyspnea	7.3 cm × 4.2 cm	ECHO/CMR	Surgical resection
Smith (2006) [8]	53 Female	Fatigue and dyspnea	3 separate lipoma	ECHO	Surgical resection
			7 cm × 4 cm		
			6 cm × 3 cm		
			4 cm × 2.5 cm		
Gulmez et al. (2008) [9]	68 Female	No symptoms – incidental finding on ECHO	5.8 cm × 2.5 cm	ECHO	Close monitoring
Kitzing (2008) [10]	63 Male	No symptoms – history of malignant melanoma	2.8 cm × 2 cm	CCT/CMR ECHO	Close monitoring
Joaquim et al.(2009) [11]	27 Male	Fatigue and intermittent tachycardia	5.5 cm × 5.3 cm	ECHO	Surgical resection
Ceresa et al. (2010) [12]	62 Male	New onset A flutter	–	CMR	Surgical resection
Alameddine et al. (2011) [13]	21 Transgender male	Dyspnea	15 cm × 13 cm	CCT/CMR	Surgical resection
Kusmierczyk et al. (2012) [14]	59 Female	New onset A. fib and lower extremity edema	4.4 cm × 6.3 cm	ECHO/CCT	Surgical resection
Khalilii et al. (2013) [15]	56 Male	Dyspnea and cardiac tamponade like symptoms	11 cm × 7.5 cm	ECHO/CCT	Surgical resection
Current case (2014)	74 Female	Dizziness	6 cm × 6 cm	ECHO	Surgical resection

systemic/pulmonary circulations and pericardial effusion with or without cardiac tamponade.

Cardiac lipomas account for 8.4% of benign primary cardiac tumors with a broad range of appearance and sizes. They are most common in the body of the right atrium and left ventricle as sessile masses but occasionally may be present as pedunculated masses [1]. Lipomas do not have a defined age distribution but are generally found in older patients and equal frequency in both sexes. They can have their origins from all 3 layers of cardiac tissue, sub-endocardium (50%), sub-pericardium (25%) and myocardium (25%). Data search for cardiac lipoma was done and 14 articles were selected for review, which ranged from 1995 to 2013 in the english language describing right atrial lipomas. Below is the summary of the literature (Table 1, [2–15]). Our patient's lipoma on surgery was 6 cm × 6 cm which was intimately attached to the right side of the atrial septum and the right atrial free wall. The largest lipoma reported to date to the best of our knowledge was in 1995 at 25 cm × 15 cm in the right atria in a 17-years-old female who presented with dyspnea. The second largest was in 2011 reported at 15 cm × 13 cm in a 21-year-old transgender male who presented with dyspnea. One unique case which was reported found three separate lipomas in a 53-years-old female on the free wall of the right atria, where the patient presented with dyspnea.

Imaging studies are helpful in the diagnosis and differentiation of cardiac tumors from other structures and lesions such as thrombus and anatomical variants. Echocardiography (transthoracic and trans-esophageal) is the primary screening tool for patients with known or suspected intra-cardiac tumors with 90% sensitivity and 95% specificity [16,17]. Echocardiography allows dynamic evaluation of intra-cardiac masses with the advantage, compared to other imaging techniques, that both the anatomic extent and the physiologic consequences of the mass can be evaluated. In addition, associated abnormalities such as valvular pathology and conditions that predispose to the development of a mass including apical aneurysm leading to left ventricular thrombus or rheumatic mitral stenosis resulting in left atrial thrombus can be assessed. On echocardiography lipomas typically appears as well demarcated homogenous and hypo-echogenic masses.

CCT allows for high resolution images of cardiac tumor in which the morphology of the tumor may be identified. CCT can also detect small tumors which may have been overlooked on echocardiography. Disadvantages of CCT include exposure to radiation and nephrotoxic contrast. Cardiac magnetic resonance (CMR) is similar CCT but is more accurate due to higher resolution with T1 and T2 imaging. CMR imaging demonstrates the composition of

the tumor which can help differentiate between the various types of tumors/lesions. The disadvantages of CMR are the cost and the patient may not be a suitable candidate due to metallic foreign bodies/devices. On both CCT and CMR, lipomas have low density from –80 to –110 HU [18].

It is important to distinguish cardiac lipomas from lipomatous hypertrophy of the inter-atrial septum (LHIS). LHIS as the name implies is fat cell deposition in the inter-atrial septum which is typically asymptomatic and found incidentally on cardiac imaging. LHIS is more common than cardiac lipoma but generally seen in older obese patients with higher incidences in females. Symptoms of LHIS are similar to cardiac lipomas and on ECHO appear as thickening of atrial septum. CCT shows a fat containing lesion in the atrial septum which does not enhance and CMR shows homogeneous atrial septal thickening with high signal in T1 imaging [19].

Management of cardiac tumors depends on the type of tumor and whether patients are symptomatic. For benign symptomatic tumors the treatment is surgical resection with 95% curative rate with overall good prognosis. Malignant primary and metastatic tumors may require surgical resection due to there size but will need adjunct chemo/radiotherapy. Malignant tumors have very poor prognosis with survival rate of less than one year from diagnosis. Our patient had surgical resection with good result (resolution of dizziness) and remains asymptomatic 3 years after her surgery.

#### 4. Conclusion

Cardiac lipomas are the third most common type of primary cardiac tumor which in of as itself is very rare. There is no defined age or sex distribution and can present with a wide range of symptoms. Echocardiography remains the initial diagnostic tool for cardiac lipoma. However, CCT/CMR provides a better image resolution and details prior to surgical resection. Surgical resection remains the main stay of treatment of symptomatic cardiac lipomas.

#### Conflict of interest

All of the authors do not have financial or personal relationships to disclose.

#### Funding

The authors do not have sources of funding to report.

**Ethical approval**

N/A – this is case report.

**Author contribution**

Sarabjeet Singh – data collection, interpretation and writing paper.

Mukesh Singh MD – date interpretation and writing paper, concept.

Daniela Kovacs MD – data analysis.

Daniel Benatar MD – date analysis.

Sandeep Khosla – date analysis.

**Consent**

We have obtained written consent from patient and can provide a copy if needed.

**Guarantor**

Sarabjeet Singh MD.

**Acknowledgement**

The authors have no acknowledgements or disclosures.

**References**

- [1] A.M. Grande, G. Minzioni, C. Pederzoli, Cardiac lipomas: descriptions of 3 cases, *J. Cardiovasc. Surg.* 39 (1998) 813–815.
- [2] J.C. Mullen, S.A. Schipper, S.S. Sett, G.A. Trusler, Right atrial lipoma, *Ann. Thorac. Surg.* 59 (1995) 1239–1241, PubMed PMID: 7733737.
- [3] N.M. Sankar, T. Thiruchelvam, K. Thirunavukkarasu, K. Pang, W.M. Hanna, Symptomatic lipoma in the right atrial free wall. a case report, *Tex. Heart Inst. J.* 25 (1998) 152–154, PubMed PMID: 9654663.
- [4] N. Maurea, A. Molla, M. Boccalatte, S. Esposito, L. Agozzino, R. Belliti, Lipoma of the heart, *Ital. Heart J.* 2 (2001) 621–623, PubMed PMID: 11577837.
- [5] W.L. Da Silveira, M.W. Nery, E.C. Soares, A.F. Leite, H. Nazzetta, M.A. Batista, et al., Lipoma of the right atrium, *Arq. Bras. De Cardiol.* 77 (2001) 361–368, English, Portuguese. PubMed PMID: 11733805.
- [6] P. Pego-Fernandes, P. Costa, F. Fernandes, L. Bevenuti, S. Oliveria, Right atrial lipoma, *Arq. Bras. De Cardiol.* 80 (2003) 97–99, PubMed PMID: 12612728.
- [7] C. Templin, J. Ghadri, L. Wilkins, M. Niehaus, Difficult differential diagnosis of a right atrial intracardiac mass, *Int. J. Cardiol.* 125 (2006) 19–20, PubMed PMID: 17395313.
- [8] M.A. Smith, Multiple synchronous atrial lipomas, *Cardiovasc. Pathol.* 16 (2007) 187–188, PubMed PMID: 17502250.
- [9] O. Gulmez, S. Pehlivanoglu, R. Turkoz, E. Demiralay, B. Gumus, Lipoma of the right atrium, *J. Clin. Ultrasound* 37 (2009) 185–188, PubMed PMID: 18506745.
- [10] B. Kitzing, Cardiac lipoma in a patient with a history of malignant tumours: a case report, *Cases J.* 1 (2008) 41, PubMed PMID: 2483951.
- [11] M.R. Joaquim, D.M. Braille, M.V. Arruda, M.J. Soares, Right atrial lipoma resection and partial reconstruction using bovine pericardium, *Rev. Bras. De Cirurgia Cardiovasc.* 24 (2009) 239–241, PubMed PMID: 19768305.
- [12] F. Ceresa, G. Calarco, E. Franzì, F. Patanè, Right atrial lipoma in patient with Cowden syndrome, *Interact. Cardiovasc. Thorac. Surg.* 11 (2010) 803–804, PubMed PMID: 20852328.
- [13] A.K. Alameddine, V.K. Alimov, G.S. Turner Jr, D.W. Deaton, Surgical pitfalls of excising an intramyocardial lipoma, *J. Thorac. Cardiovasc. Surg.* 141 (2011) 592–594, PubMed PMID: 20674939.
- [14] M. Kuśmierczyk, A. Drohomirecka, P. Stachurski, I. Michałowska, J. Różański, Giant pericardial lipoma compressing the right atrium, *J. Cardiac Surg.* 27 (2012) 722–723, PubMed PMID: 23173859.
- [15] A. Khalili, S. Ghaffari, A. Jodati, B. Shokoohi, L. Pourafkari, Giant right atrial lipoma mimicking tamponade, *Asian Cardiovasc. Thorac. Ann.* 23 (2013) 317–319, PubMed PMID: 24887890.
- [16] K.G. Shyu, J.J. Chen, J.J. Cheng, Comparison of transthoracic and transesophageal echocardiography in the diagnosis of intracardiac tumors in adults, *J. Clin. Ultrasound* 22 (1994) 381–389, PubMed PMID: 8071456.
- [17] R. Engberding, W.G. Daniel, R.L. Erbel, Diagnosis of heart tumors by transesophageal echocardiography: a multicentre study in 154 patients, *Eur. Heart J.* 14 (1993) 1223–1228.
- [18] Braunwald, E., Zipes, D.P., Libby, P., Bonow, R.O., Primary Tumors of the Heart. In *Heart disease: A textbook of cardiovascular medicine*, 8th ed., Saunders, pp. 1819–1820.
- [19] M.C. Bois, J.P. Bois, N.S. Anavekar, A.M. Oliveira, J.J. Maleszewski, Benign lipomatous masses of the heart: a comprehensive series of 47 cases with cytogenetic evaluation, *Hum. Pathol.* 45 (2014) 1859–1865, PubMed PMID: 24996689.

**Open Access**

This article is published Open Access at [sciedirect.com](http://sciedirect.com). It is distributed under the [IJSCR Supplemental terms and conditions](#), which permits unrestricted non commercial use, distribution, and reproduction in any medium, provided the original authors and source are credited.