

# Endoscopic treatment of intussusception due to small intestine polyps in patients with Peutz-Jeghers Syndrome

OPEN  
ACCESS



## Authors

Kunihiko Oguro<sup>1</sup>, Hirotosugu Sakamoto<sup>1</sup>, Tomonori Yano<sup>1</sup>, Yohei Funayama<sup>1</sup>, Masafumi Kitamura<sup>1</sup>, Manabu Nagayama<sup>1</sup>, Keihiro Sunada<sup>1</sup>, Alan Kawarai Lefor<sup>2</sup>, Hironori Yamamoto<sup>1</sup>

## Institutions

- 1 Department of Medicine, Division of Gastroenterology, Jichi Medical University, Tochigi, Japan
- 2 Department of Surgery, Jichi Medical University, Tochigi, Japan

submitted 16.5.2022

accepted after revision 30.9.2022

published online 30.9.2022

## Bibliography

Endosc Int Open 2022; 10: E1583–E1588

DOI 10.1055/a-1954-0110

ISSN 2364-3722

© 2022. The Author(s).

This is an open access article published by Thieme under the terms of the Creative Commons Attribution-NonDerivative-NonCommercial License, permitting copying and reproduction so long as the original work is given appropriate credit. Contents may not be used for commercial purposes, or adapted, remixed, transformed or built upon. (<https://creativecommons.org/licenses/by-nc-nd/4.0/>)

Georg Thieme Verlag KG, Rüdigerstraße 14,  
70469 Stuttgart, Germany

## Corresponding author

Tomonori Yano, MD, PhD, Department of Medicine, Division of Gastroenterology, Jichi Medical University, 3311-1 Yakushiji, Shimotsuke, Tochigi, 329-0498, Japan  
Fax: +81-285-44-8297  
tomonori@jichi.ac.jp

## ABSTRACT

**Background and study aims** Intussusception caused by intestinal polyps in patients with Peutz-Jeghers syndrome usually requires laparotomy. Patients following successful endoscopic reduction using double-balloon endoscopy (DBE) have been reported. The aim of this study was to evaluate the feasibility of endoscopic treatment of intussusception.

**Patients and methods** We retrospectively reviewed patients who underwent DBE for intussusception due to small intestine polyps in patients with Peutz-Jeghers syndrome from January 2004 to June 2020.

**Results** Twenty-seven (antegrade 22, retrograde 5) DBEs were performed in 19 patients with 25 sites of intussusception identified during the study period. If the intussusception remained once the endoscope reached the site, endoscopic reduction of the intussusception was performed as needed (15 sites). Ultimately, endoscopic resections (8 sites) or ischemic polypectomies (16 sites) of the polyp causing the intussusception were completed at 24 sites. Only one site could not be treated endoscopically and was treated surgically. The final per-site and per-patient success rates of endoscopic treatment were 96% (24/25) and 95% (18/19) respectively. Two patients developed mild acute pancreatitis and one patient developed intussusception after the procedures, both of which were treated non-operatively.

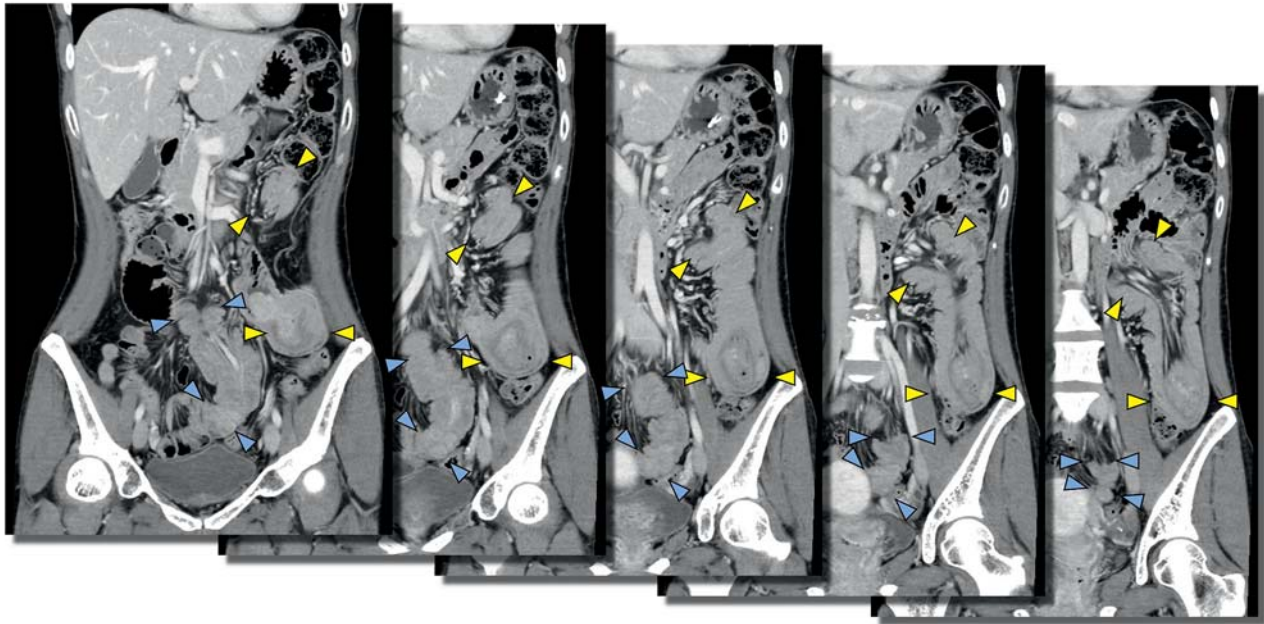
**Conclusions** Endoscopic treatment of intussusception is feasible to avoid laparotomy in patients with Peutz-Jeghers syndrome.

## Introduction

Peutz-Jeghers syndrome (PJS) is an autosomal-dominant inherited syndrome caused by a pathogenic variant in the germline of the *STK11* gene, resulting in hamartomatous polyposis in all parts of the gastrointestinal tract except the esophagus [1]. Polyps larger than 15 mm in diameter have the potential to cause intussusception, and it has been reported that about 70% of patients who develop intussusception require laparotomy by age 18 [2]. Polypectomy of small intestine polyps in pa-

tients with PJS under balloon-assisted endoscopy may have reduced the risk of subsequent intussusception [3], and endoscopic resection of small intestine polyps larger than 15 mm is recommended in European and Japanese guidelines [4, 5].

However, for patients with PJS who develop intussusception due to polyps, operative intervention including laparoscopic surgery and intraoperative endoscopy are often performed. Several patients who underwent successful endoscopic reduction of intussusception due to small bowel polyps using double-balloon endoscopy (DBE) have been reported [6, 7]. The



► **Fig. 1** CT scans of a double intussusception of the jejunum. There are intussusceptions in the proximal jejunum (yellow arrows) and in the distal jejunum (blue arrowheads).

aim of this study is to evaluate whether endoscopic treatment of intussusception due to intestinal polyps in patients with PJS was feasible and safe.

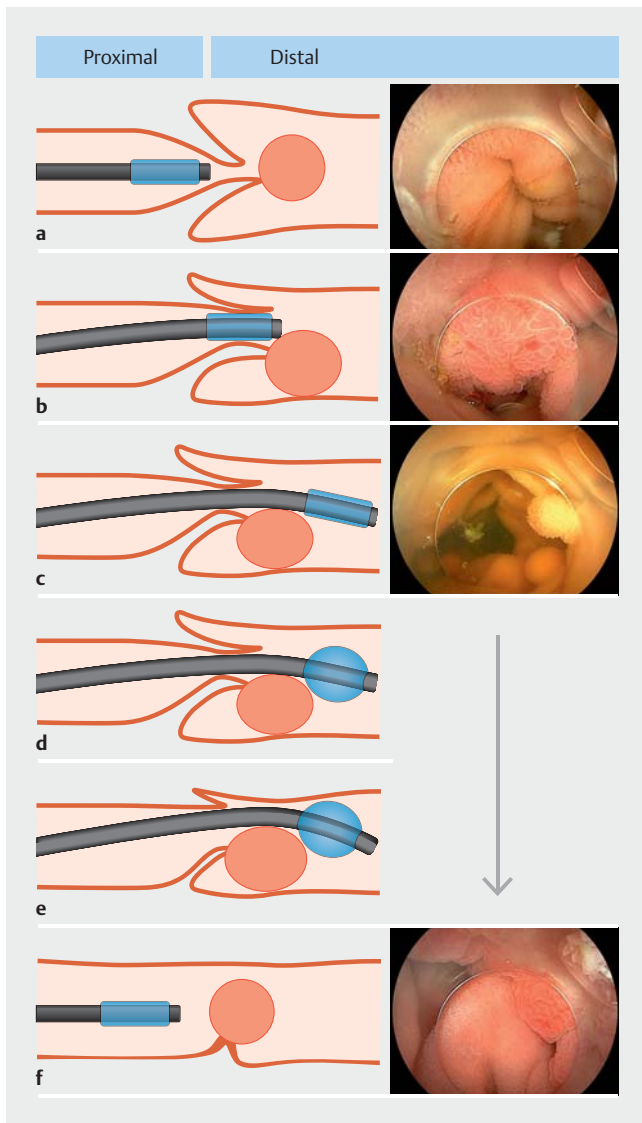
## Patients and methods

This was a retrospective, open-label, single-center case series. The records of 67 consecutive patients with PJS who underwent DBE at Jichi Medical University Hospital from January 2004 to June 2020 were retrospectively reviewed. Among these patients, 19 patients with intussusception (28%, 19/67) due to small intestine polyps were included in this series. Written informed consent was obtained from all patients before the procedure. This study was approved by the Institutional Review Board.

No patient treated during the study period required urgent surgery due to intussusception with necrosis or perforation. Patients with persistent severe abdominal pain or bloating at the time of diagnosis of intussusception had undergone urgent DBE, and other patients had undergone DBE on a standby basis, which was defined as when the patient had no or mild symptoms such as abdominal discomfort and the attending physician decided that urgent DBE was not necessary. All patients were admitted before DBE. For patients diagnosed using imaging findings, we chose an antegrade DBE if the site of intussusception was from the duodenum to the jejunum (► **Fig. 1**), or a retrograde DBE if it was in the ileum. Unless the patient had emergent symptoms suspected to be due to intestinal obstruction, such as abdominal pain or vomiting, bowel preparation by taking 2 L of polyethylene glycol electrolyte solution was performed with the split-dose method on the day before and the

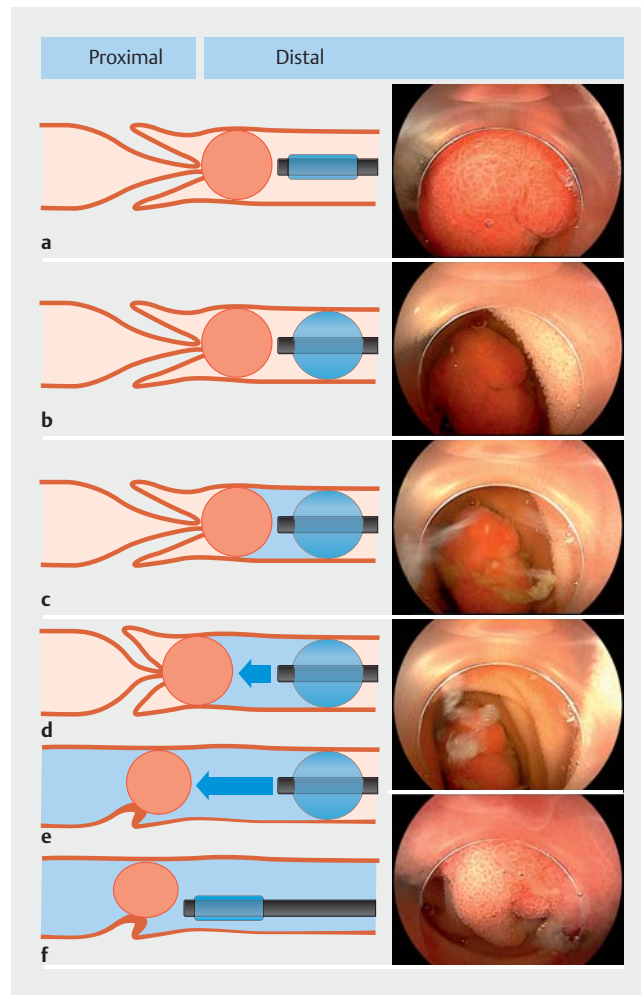
day of the retrograde DBE. Conscious sedation with a combination of intravenous pethidine and midazolam was used for 23 DBEs/16 patients. General anesthesia was selected for some pediatric patients and emergency procedures in some patients (4 DBEs/4 patients).

A therapeutic-type (EN-580T or EN-450T5/W with TS-13140; Fujifilm, Tokyo, Japan) or a short-type (EI-580BT, EI-530B or EC-450BI5 with TS-13101; Fujifilm) double-balloon endoscope, and a 4-mm transparent cap (D-201-10704; Olympus, Tokyo, Japan) fitted to the tip of the endoscope were routinely used. If the location of the intussusception was known from imaging findings, we selected a short endoscope when the intussusception was up to the proximal jejunum or deeper than the distal ileum. In antegrade DBE, after insertion distal to the intussusceptum, the endoscope tip balloon was partially expanded and pulled back to reduce the intussusception (► **Fig. 2**). In retrograde DBE, the endoscope tip balloon was dilated on the distal side of the intussusceptum, and 50 to 150 mL of water or contrast medium was manually injected with a syringe to reduce the intussusception (► **Fig. 3**) [8]. Since the balloon controller automatically maintains the pressure of the endoscope tip balloon at 45 mmHg (6 kPa), it is expected that excess water spills over when the intraluminal pressure reaches 45 mm Hg (6 kPa) during the procedure. The procedures are shown in ► **Video 1**. We also attempted endoscopic removal of the polyp that caused the intussusception (which served as the intussusceptum) with or without endoscopic reduction of the intussusception. All polyps after 2012 have been treated with the ischemic polypectomy method that we reported [9]. We defined successful endoscopic treatment when the responsible polyps were removed endoscopically after successful endo-



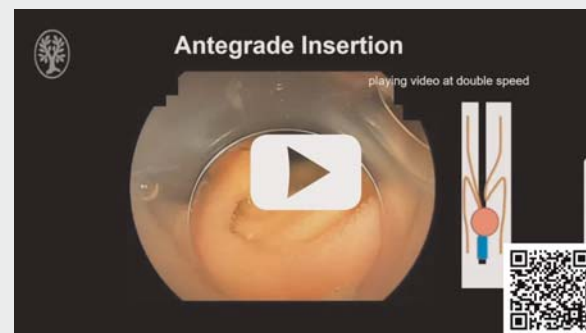► **Fig. 2** The method for endoscopic reduction in antegrade double-balloon endoscopy. **a,b,c** After insertion distal to the intussusception, **d** the endoscope tip balloon is partially expanded and **d,e** pulled back to reduce the intussusception. **f** After achieving endoscopic reduction, the polyp can be treated endoscopically. The endoscopic images show the intussusception in the proximal jejunum from the patient in ► **Fig. 1**.

scopic reduction or when the intussusception was reduced after removing the polyps. The following backgrounds and outcomes were recorded: (1) patient characteristics (age, gender, history of abdominal surgery, symptoms, diagnostic trigger); (2) results (size of the polyps that caused intussusception, methods of endoscopic resection of the polyps, success rates of endoscopic treatment for each site and per patient); (3) adverse events.



► **Fig. 3** The method for endoscopic reduction in retrograde double-balloon endoscopy. **a,b** The endoscope tip balloon is dilated distal to the intussusception, **c** water or contrast medium is injected, **d,e** and the intussusception is pushed back proximally to reduce the intussusception. **f** After achieving endoscopic reduction, the polyp can be treated endoscopically.

► **VIDEO**



► **Video 1** Endoscopic reduction of intussusception

► **Table 1** Patient characteristics.

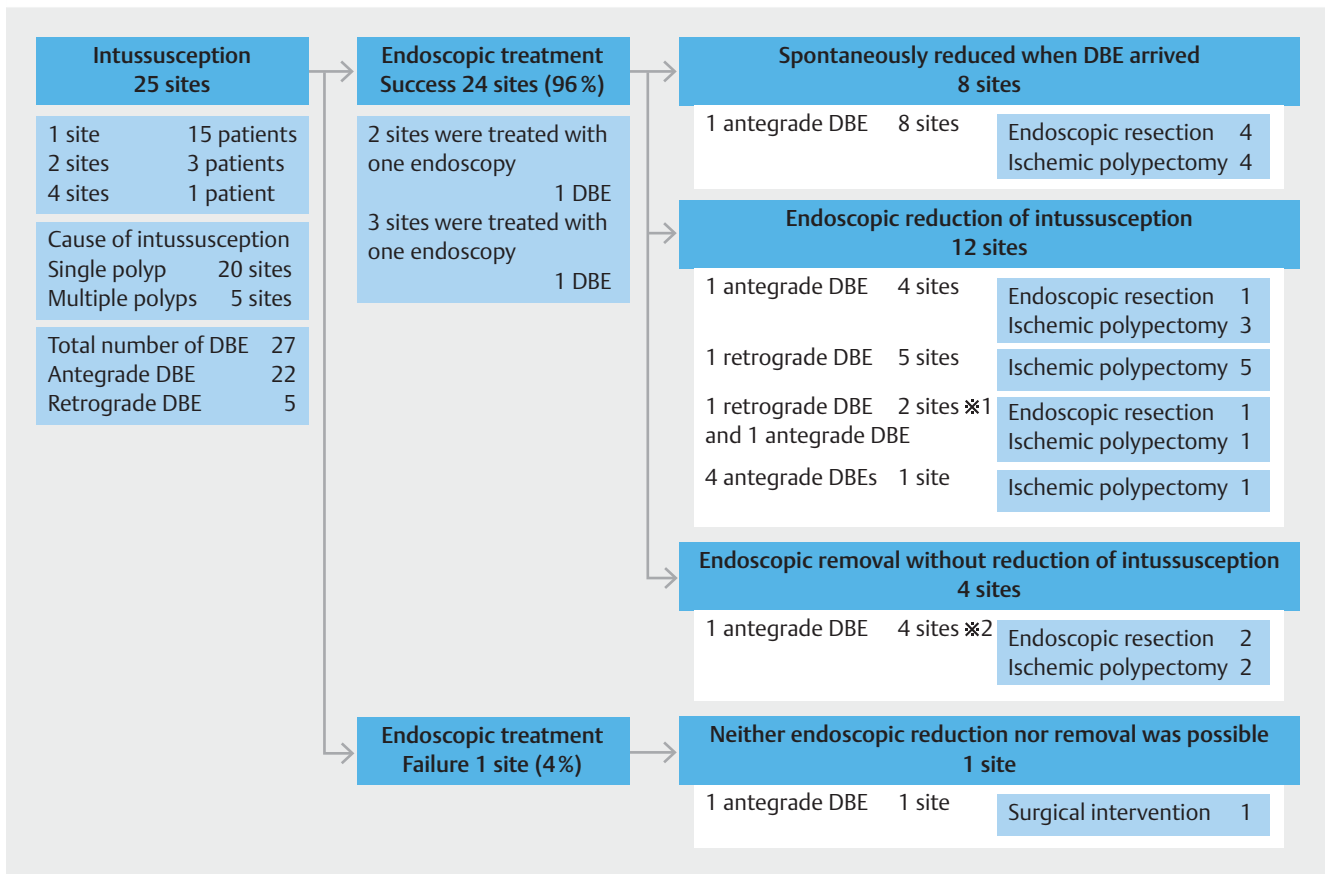
Total number of patients	19
Gender, N (%)	
▪ Male	11 (58%)
▪ Female	8 (42%)
Median age, years (range)	30 (10–63)
History of laparotomy, N (%)	15 (79%)
Symptoms of intussusception, N (%)	10 (53%)
▪ Abdominal pain	7
▪ Abdominal discomfort	3
Patients who had more than two intussusceptions, N (%)	4 (21%)
Diagnostic trigger	
▪ Computed tomography scan	17
▪ Endoscopy	2

## Results

Nineteen patients (11 male, 8 female) were included in this study. Patient characteristics are summarized in ► **Table 1**. The median age of the patients was 30 years (range: 10–63). Fifteen patients (79%) had a history of previous laparotomy, and most of the abdominal operations were performed for intussusception. Ten patients (53%) had symptoms (abdominal pain 7, abdominal discomfort 3) associated with intussusception. Intussusceptions were detected by contrast-enhanced CT scan before DBE in 17 patients and confirmed for the first-time during DBE in two patients.

In 19 patients, 25 sites (1 site: 15 patients, 2 sites: 3 patients, 4 sites: 1 patient) of intussusception were identified and 27 DBEs (22 antegrade, 5 retrograde) were performed (► **Fig. 4**). The median maximum diameter of the polyp responsible for intussusception (the intussusceptum) was 33 mm (10–100), and multiple adjacent polyps were considered responsible for intussusception at five sites (5/25, 20%).

At eight sites (8/25, 32%) treated with antegrade DBEs, the intussusception had reduced by the time the endoscope reached the site. The responsible polyps were removed by



► **Fig. 4** Outcomes of intussusception. Details of the clinical outcomes at 25 intussusception sites. At two sites where insertion was changed to antegrade from retrograde, both sites were reduced endoscopically using the retrograde insertion. After that, at both sites, the intussusceptions were detected again. Of these, one was reduced endoscopically and the other had spontaneously reduced when DBE arrived in antegrade DBEs. Reduction of the intussusception was attempted at two of four sites but could not be achieved. They were treated completely after removing the responsible polyps.

endoscopic resection at four sites and by ischemic polypectomy at 4 sites. At twelve sites (12/25, 48%), the intussusceptions were successfully treated with endoscopic removal of the responsible polyps after endoscopic reduction of the intussusception. Of these, the responsible polyps were endoscopically removed after endoscopic reduction with a single antegrade DBE at four sites (endoscopic resection 1, ischemic polypectomy 3) and a single retrograde DBE at five sites (ischemic polypectomy 5). Also, in two sites in two patients, the initial retrograde DBE allowed reduction of the intussusception, however, complete endoscopic removal of the responsible polyp could not be performed. Therefore, antegrade DBE was performed later. After the intussusceptions were reduced again, the polyp at one site was endoscopically resected, and at the other site was removed by ischemic polypectomy. At one site, regressing the responsible polyp, which was 100 mm in diameter and polynodular, required four antegrade DBE procedures with piecemeal ischemic polypectomy.

At four sites (4/25, 16%), the responsible polyps were removed endoscopically (endoscopic resection 2, ischemic polypectomy 2) without reduction of the intussusception. At two of these sites, although endoscopic reduction of the intussusception was attempted, it was not successful, and subsequent removal of the responsible polyp resolved the intussusception.

Ultimately, only one intussusception was treated surgically due to difficulties during both endoscopic reduction of the intussusception and endoscopic removal of the responsible polyp. The final success rates of endoscopic treatment per site and patient were 96% (24/25) and 95% (18/19), respectively.

Two patients developed mild pancreatitis (2/27 DBEs, 7%) as endoscopy-related adverse events, and both were treated conservatively. In another patient, an endoscopically resected polyp became stuck in a distal polyp, resulting in another intussusception (1/27 DBE, 4%), and was treated endoscopically.

## Discussion

This case series demonstrates the usefulness of endoscopic treatment for intussusception due to small bowel polyps in patients with PJS. Endoscopic treatment was completed in 95% of patients (18/19) with intussusception attempted endoscopically. This suggests that endoscopic treatment of intussusception can be accomplished safely even in the presence of symptoms such as abdominal pain.

When DBE reached the site of intussusception, all (7/7) intussusceptions were confirmed during retrograde insertion, whereas in 45% (9/20) of sites with antegrade insertion, the intussusception had reduced when the DBE reached the sites of intussusception. In these cases, the intussusception seemed to gradually reduce before the DBE reached the responsible polyp (the intussusceptum) because both the small bowel and intussuscepted polyps were pulled proximally during the shortening maneuver in antegrade DBE. In terms of the endoscopic reduction procedure of the intussusception, all intussusceptions (7/7) were reduced by injecting fluid distally during retrograde insertion, whereas 67% of those (6/9) were successfully reduced by pulling back with the endoscope tip balloon during ante-

grade insertion. Obviously, the reduction of intussusception is only temporary and will soon recur if the responsible polyps were not removed. In the cases of antegrade insertion, even if it was difficult to reduce the intussusception, in most of them it was possible to identify the stalk of the polyp and complete the endoscopic treatment. In the cases of retrograde insertion, it was observed in 14% (1/7) of lesions that the polyp moved proximally after the intussusception reduced, making it difficult to approach the polyp. Although we generally recommend treating the responsible polyps after reducing the intussusception to identify the stalk correctly, it may be necessary to consider treating the polyp before reducing the intussusception during retrograde DBE with poor maneuverability.

In terms of endoscopic removal of the intussusceptum, ischemic polypectomy was chosen in 64% (16/25) of lesions and endoscopic resection in 32% (8/25). As we previously reported, ischemic polypectomy can be performed if the polyp stalk can be identified [9], suggesting that it may be useful in the endoscopic treatment of large polyps resulting in intussusception, especially in the distal small intestine, where maneuverability is often poor. However, when endoscopic treatment is performed without reducing the intussusception, it may be safer to place clips as close to the polyp as possible to strangulate it because of the risk of perforation by snaring the intussuscepted intestine. Furthermore, if polyps are not retrieved after resection, there is a risk that they may become stuck in distal polyps and cause further episodes of intussusception, whereas ischemic polypectomy may be safer because the strangulated polyps will gradually regress. The disadvantages of ischemic polypectomy are the inability to recover the tissue for pathologic evaluation and the inability to confirm complete removal of polyps. However, PJS polyps are typically benign hamartomatous polyps and their malignant potential is quite low. It is estimated that 80% to 90% of treated polyps become necrotic, and it has been shown that both the number of polyps (>15 mm) and their maximum diameter tended to decrease over repeated sessions of ischemic polypectomy [9]. Therefore, we believe the polyps which cause intussusception can be adequately treated with ischemic polypectomy. The procedure-related complication rate was 11%, which is similar to the 8% rate observed with therapeutic DBE in a review [10]. The procedure may be acceptable as a treatment to remove polyps after reducing the intussusception.

Although there have been reports on the usefulness of endoscopic treatment of small intestine polyps for PJS, and guidelines recommend endoscopic treatment, surgical treatment is currently recommended in patients with intussusception [5]. However, even once the polyp causing the intussusception has been removed, new polyps may develop one after another in some patients. It is also a concern that repeated laparotomy will not only make it difficult to insert the DBE distally due to adhesions, but also make the surgery itself difficult. Endoscopic treatment does not cause adhesions and can be performed repeatedly, and considering the characteristics of PJS, we believe that it is an ideal therapeutic approach rather than surgical treatment. The results of the present study show that careful endoscopic reduction and removal of the responsi-

ble polyp can be safely performed even in the presence of symptoms due to intussusception.

This study has acknowledged limitations. It is a single-center retrospective study, with a small number of patients. Although it would be desirable to compare the long-term course of patients with PJS with that of patients in whom surgery was performed for intestinal overload, it is difficult to conduct such a prospective comparative study because PJS is a rare disease.

## Conclusions

In conclusion, the endoscopic treatment of intussusception is feasible to avoid laparotomy in patients with PJS. The results of this study need to be validated by future multicenter studies.

## Competing interests

Dr. Yamamoto is a consultant for Fujifilm Corp. and has received honoraria, grants, and royalties from the company. Drs. Sakamoto, Yano, and Sunada have received honoraria from Fujifilm Corp. Dr. Sakamoto has also received a grant from Fujifilm Medical Corporation. Other authors declare no conflicts of interest regarding this study.

## References

- [1] Beggs AD, Latchford AR, Vasen HF et al. Peutz-Jeghers syndrome: a systematic review and recommendations for management. *Gut* 2010; 59: 975–986
- [2] Hinds R, Philp C, Hyer W et al. Complications of childhood Peutz-Jeghers syndrome: implications for pediatric screening. *J Pediatr Gastroenterol Nutr* 2004; 39: 219–220
- [3] Sakamoto H, Yamamoto H, Hayashi Y et al. Nonsurgical management of small-bowel polyps in Peutz-Jeghers syndrome with extensive polypectomy by using double-balloon endoscopy. *Gastrointest Endosc* 2011; 74: 328–333
- [4] Yamamoto H, Ogata H, Matsumoto T et al. Clinical practice guideline for enteroscopy. *Digest Endosc* 2017; 29: 519–546
- [5] Wagner A, Aretz S, Auranen A et al. The management of Peutz-Jeghers syndrome: European Hereditary Tumour Group (EHTG) Guideline. *J Clin Med* 2021; 10: 473
- [6] Miura Y, Yamamoto H, Sunada K et al. Reduction of ileoileal intussusception by using double-balloon endoscopy in Peutz-Jeghers syndrome (with video). *Gastrointest Endosc* 2010; 72: 658–659
- [7] AlSamman MA, Ferreira JD, Moustafa A et al. Successful endoscopic reduction of an ileocolonic intussusception in an adult with Peutz-Jeghers syndrome. *Gastroenterology Res* 2019; 12: 40–42
- [8] Okada M, Sakamoto H, Hayashi Y et al. Curative endoscopic treatment of intussusception due to a giant colonic lipoma using a wedged balloon and ligation with detachable snares. *Clin J Gastroenterol* 2019; 12: 320–324
- [9] Khurelbaatar T, Sakamoto H, Yano T et al. Endoscopic ischemic polypectomy for small-bowel polyps in patients with Peutz-Jeghers syndrome. *Endoscopy* 2021; 53: 744–748
- [10] Rondonotti E, Spada C, Adler S et al. Small-bowel capsule endoscopy and device-assisted enteroscopy for diagnosis and treatment of small-bowel disorders: European Society of Gastrointestinal Endoscopy (ESGE) Technical Review. *Endoscopy* 2018; 50: 423–446