

## CASE REPORT

# Salvage of an osteocutaneous thermonecrosis secondary to tibial reaming by the induced membrane procedure

Adeline Cambon-Binder<sup>1</sup>, Marc Revol<sup>2</sup> & Didier Hannouche<sup>3</sup> 

<sup>1</sup>Department of Orthopaedic and Hand Surgery, AP-HP, Hôpital Saint Antoine, Université Paris 6 Pierre et Marie Curie, Paris, France

<sup>2</sup>Department of Plastic and Reconstructive Surgery, AP-HP, Hôpital Saint Louis, Université Paris 7 Denis Diderot, Paris, France

<sup>3</sup>Department of Orthopaedic Surgery, Hôpitaux Universitaires de Genève, Université de Genève, Geneva, Switzerland

### Correspondence

Didier Hannouche, Department of Orthopaedic Surgery, HUG, Avenue Gabrielle Perret Gentil 4, Geneva 1206, Switzerland.  
Tel: +41 22 372 78 02;  
Fax: +41 22 372 78 45;  
E-mail: didier.hannouche@aphp.fr

### Funding Information

No sources of funding were declared for this study

Received: 25 March 2017; Revised: 11 June 2017; Accepted: 17 June 2017

*Clinical Case Reports* 2017; 5(9): 1471–1476

doi: 10.1002/ccr3.1093

## Introduction

Osteocutaneous thermonecrosis is a rare and severe complication of intramedullary reaming leading to combined bone and soft tissue loss, and for which treatment is not standardized [1–4]. It occurs after forced reaming of small tibial medullary canals, which generates a rise in temperature in the bone cortex and the surrounding tissues up to 175–225°C after 2 min of reaming [5]. The physiopathology of this disease can be compared to osteoradionecrosis with structural and functional changes of the bone tissue, including inhibition of bone morphogenetic proteins (BMPs) expression, inhibition of collagen formation, and cell ischemia induced by devascularisation [6].

Treatment of osteocutaneous thermonecrosis is multidisciplinary and often very challenging, as it has to address segmental bone loss and necrosis, soft tissue necrosis and deep infection. Recently, Masquelet et al. [7] described a two-step surgical procedure aiming at repairing large and infected diaphyseal bone defects by providing a favorable environment that facilitates bone engraftment. In the first step, a polymethylmethacrylate

### Key Clinical Message

Osteocutaneous thermonecrosis is a rare but devastating complication of tibial reaming, which can cause large and infected bone and cutaneous defects. The case presented here illustrates that the induced membrane technique described by Masquelet is a valuable option in treating this complication.

### Keywords

Bone infection, induced membrane technique, Masquelet technique, nail, non-union, reaming.

(PMMA) cement spacer is inserted into the defect inducing formation of an encapsulation membrane. The so-called induced membrane has a rich capillary network and contains high concentrations of growth (Vascular Endothelial Growth factor, VEGF, and Transforming Growth factor, TGF-beta 1) and osteoinductive factors (BMP-2) [8]. After 6–8 weeks, the spacer is removed and the cavity is filled with autologous cancellous bone grafts harvested from the iliac crest [9–13].

We present a patient, who had osteothermonecrosis after the reaming of an aseptic tibial nonunion with an obstructed medullary canal. The 8-cm bone defect was successfully treated with the induced membrane technique. To our knowledge, this procedure has never been evaluated in such a condition. The case report is followed by a review of the literature concerning risk factors and therapeutic options.

## Case Report

A 27-year-old patient had a previous medical history of a Gustilo-Anderson type 1 open fracture of the midshaft of

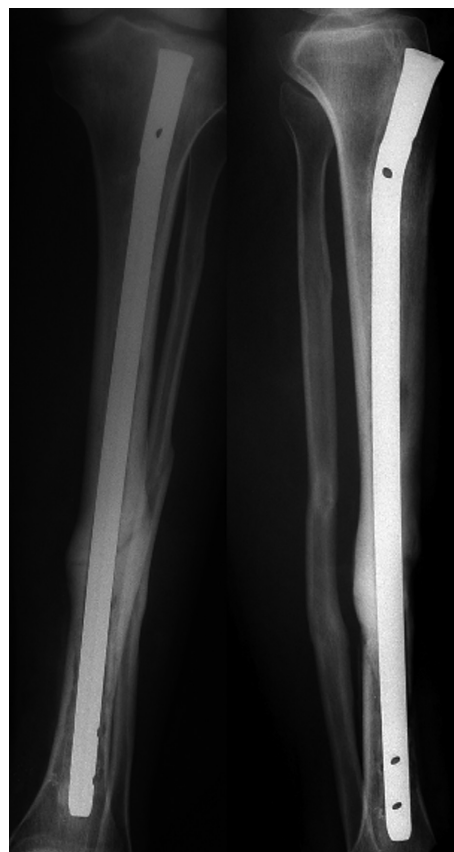the left tibia that had been treated by tibial reaming and interlocking nailing. The patient recovered completely, returned to full-time work, and the nail was removed 2 years later. Four years after the initial operation, the patient sustained a fatigue fracture of the left tibia after a 4-h walk. A splint was applied to the leg for 5 months, with 50% weight bearing allowed with two crutches. In the presence of ongoing pain at the fracture site and radiologic signs of delayed healing, the patient was taken to the operating room for tibial nailing. Surgery was performed under general anesthesia using a transpatellar approach, and with the use of a tourniquet. The introduction of a reaming guide wire was very difficult to achieve because the medullary canal was obstructed. Reaming was performed by solid reamers (Synthes Inc., Zuchwil, Switzerland) up to 12 mm, and an 11-mm unlocked tibial nail (Stryker Inc., Kalamazoo, MI) was inserted. The patient received one shot of Cefazolin (1 g) 30 min prior to surgery.

Over the week after surgery, a blister measuring  $8 \times 5$  cm developed on the anteromedial aspect of the leg at the level of the fracture, leading within few days to an extensive exposure of the tibia. It was possible to see the nail through the tibial cortex, as it had become transparent. The underlying bone was devitalized, and a radiograph showed an important thinning of the anteromedial tibial cortex (Fig. 1). The patient was referred to our department for further debridement and treatment. Considering the presence of a large bone defect, the high risk of infection, and the poor quality of the surrounding soft tissues (Fig. 2A), we decided to perform a staged reconstruction procedure, according to the induced membrane method described by Masquelet [7]. First, the tibial nail was removed, and a large debridement of the devitalized and necrotic cutaneous and osseous tissue was performed (Fig. 2B). The tibial shaft was reamed with solid reamers up to 13 mm in order to reopen and clean the medullary canal. A single-plane external fixator (Orthofix Inc., Lewisville, TX) was applied to stabilize the tibia using hydroxyapatite-coated pins. Bone and soft tissue cultures revealed the presence of a polymicrobial (*Streptococcus sanguis*, *Enterococcus faecalis*, and *Neisseria subflavia*) and fungal infection (*Candida albicans*). A 4-month antibiotic course was administered, using trimethoprim associated with rifampicin. The fungal infection was treated with fluconazole. One week later, the patient was taken to the operating room for iterative debridement and curettage of persistent devascularized bone. A polymethylmethacrylate cement spacer impregnated with gentamycin (Palacos<sup>®</sup>, Heraeus Inc., Hanau, Germany) was placed in the bone defect. The extent of bone resection was determined on the basis of the presence of viable bleeding bone on the resected surfaces. A myocutaneous latissimus dorsi free flap with an anastomosis on the anterior tibial artery was

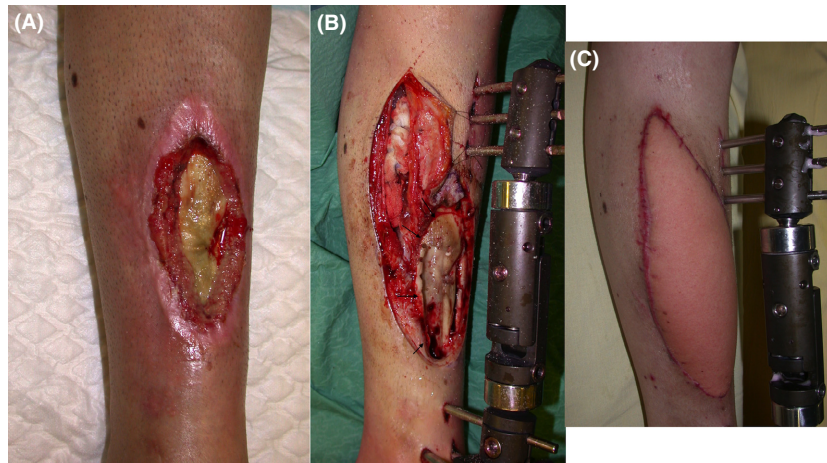
performed to achieve soft tissue reconstruction (Fig. 2C). The cutaneous paddle of the flap measured  $10 \times 6$  cm. Four months later, the spacer was removed while preserving the induced membrane, which was filled with morcellized corticocancellous bone taken from the contralateral posterior iliac crest. The bone defect measured  $8 \times 3$  cm. The membrane was closed with a continuous resorbable suture. Fifty percent weight bearing was allowed for the first 6 months. Follow-up examinations were carried out at two-week intervals initially. We did not observe any complication, such as pin track infection or recurrence of infection at the fracture site. After 7 months, an autologous iliac intertibiofibular graft was performed using a posterolateral approach to reinforce the fracture site. Bone healing was achieved at 12 months (Fig. 3), and the external fixator was removed 6 months later allowing the patient to fully bear the weight without any pain. The patient was lastly evaluated 5 years since surgery (Fig. 4).

## Discussion

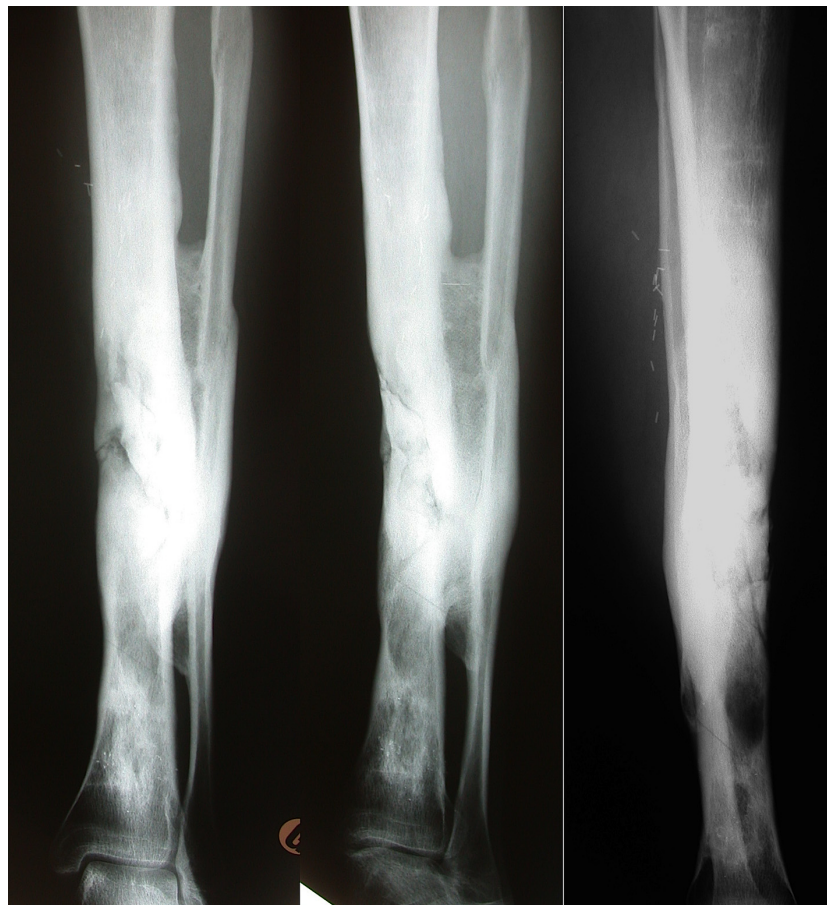The aim of tibial reaming was to sufficiently enlarge the canal to allow the insertion of a larger and stronger nail



**Figure 1.** Initial AP and lateral X-Rays showing an important thinning of the anteromedial cortex of the left tibia.



**Figure 2.** (A) Initial aspect showing an extensive cutaneous necrosis with a translucent anteromedial tibial cortex. (B) The nail was removed and debridement of the necrotic tissues was performed; the fracture was stabilized using an external fixator. The bone defect after debridement measured  $8 \times 3$  cm (black arrows). (C) Soft tissue coverage was achieved using a free myocutaneous latissimus dorsi flap.

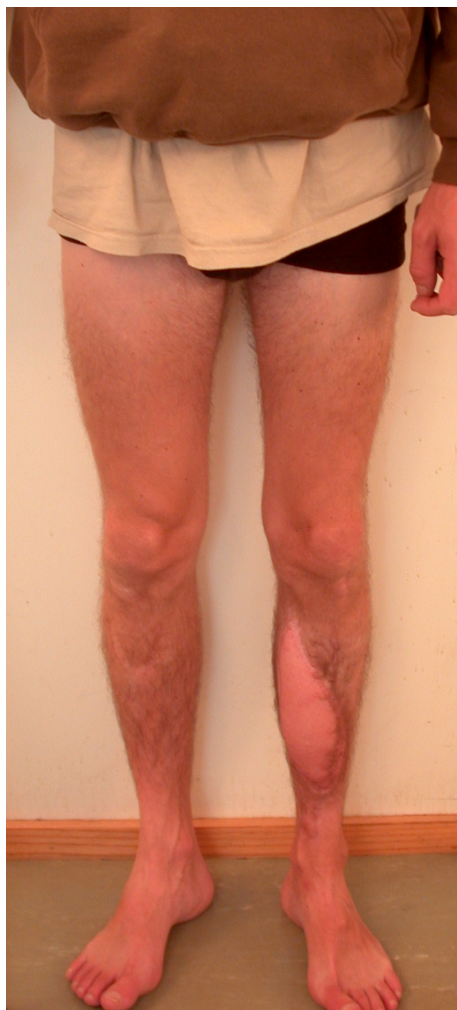

**Figure 3.** AP and Lateral X-Rays at 1 year postsurgery showing bone healing of the left tibia and successful engraftment of a tibiofibular graft.

that provides a more stable fixation in both the frontal and the sagittal planes. With the use of larger nails, the risk of fatigue failure of the implant and particularly of

the locking screws is significantly reduced [14]. In open tibial shaft fractures, reaming reduces the risk of reoperation for delayed union [15], and, in aseptic tibial





**Figure 4.** At 5 years follow-up, the patient was able to fully bear the weight without any pain.

nonunions, reaming followed by intramedullary nailing stimulates fracture healing and minimizes the need for bone grafting [16]. However, reaming of small medullary canals may result in increased temperatures in the core of the tibial shaft, which may have dramatic consequences, such as in our patient. We acknowledge that we did not monitor tibial shaft temperature during the procedure in our case. But, the reported excessive force that was needed to access and ream the medullary canal, as well as the immediate postoperative course made the diagnosis of osteocutaneous thermonecrosis. Also, we did not perform histological analysis on bone and soft tissue biopsies, as it often reveals nonspecific signs such as disappeared osteocytes and inflammatory cells invasion.

Osteothermonecrosis was mainly reported in the lower leg, where the trefoil shape of the tibia and the thin soft tissue envelope may be important risk factors [17]. Other

reported factors include a pre-existing fracture or deformity, an abnormal small diameter of the medullary canal [1–3], the duration of the reaming, and a short time between two reamer passages, which all increase the temperature locally [18]. Temperature increase during reaming is correlated with reamer size, especially when reamer diameter is greater than that of the intramedullary canal [19–21]. Denaturation of Alkaline Phosphatase occurs above 56°C, which appears to be the critical temperature required to induce osteothermonecrosis [22]. Baumgart *et al.* [5] showed that, while a 50°C temperature may be observed after 30 sec of reaming in safe conditions (high rotational speed, high force, high friction coefficient), temperature may rise up to 175°C in narrow canals with subsequent irreversible thermal damage. A 70°C temperature leads to immediate cell necrosis [23], and delayed cell death occurs when a temperature of 47°C is applied for 1 min [24–26]. Histological analysis performed 3 weeks after the reaming of a miniature pig's cortical bone showed areas of bone resorption with piecemeal necrosis, scar tissue, and the absence of osteocytes in the bone lacunae close to the medullary canal [18]. Ochsner *et al.* [2] developed a classification of heat-induced damage based on histological and clinical findings. In the most severe grade, the entire cross section of the bone including the periosteum is devitalized at the level of its narrowest diameter consecutive to the devascularization. These lesions lead to a delayed union and septic complications. Additional damages of soft tissues are possible, from the depth to the surface, including muscle, nerve, and skin lesions. The use of a tourniquet might also increase heat production locally, as it eliminates convective heat transfer due to blood flow interruption [1]. In a prospective randomized study of 34 patients that were treated with reamed intramedullary nailing, Giannoudis *et al.* [20] studied the effect of the use of a tourniquet on the temperature measured at the tibial cortex. The temperature rose from 36.3°C to 51.6°C for 20 sec during reaming, but the authors did not observe any statistical difference in between the two groups. In an experimental study performed in dogs, similar temperatures were also measured at the diaphyseal cortex with and without the tourniquet. High peak temperatures were generated in small-diameter medullary canals, suggesting that thermal necrosis was more related to reaming conditions than to tourniquet inflation [27]. Recently, in order to reduce the incidence of thermal necrosis and fat embolism, a new reaming system has been developed, the Reaming Irrigator Aspirator (RIA; Synthes Inc., Zuchwill, Switzerland). By allowing continuous suction and irrigation during the procedure, this system is supposed to cool the local temperature below the threshold of thermal damage to the bone [28]. Higgins *et al.* [29] performed a cadaveric

experiment on eight pairs of tibia specimens comparing the RIA to a standard stepwise reaming. In the RIA group, the temperature was significantly lower, with a mean 28% decrease in the temperatures recorded ( $42.0 \pm 9.1^\circ\text{C}$  vs.  $58.7 \pm 15.9^\circ\text{C}$ ). However, there is still a lack of clinical evidence about the RIA to support its widespread use [30].

The treatment of osteocutaneous thermonecrosis is very challenging, as it has to address the problem of soft tissue coverage, polymicrobial infection, and large bone defect reconstruction. Among the previously reported cases of bone thermonecrosis, Ilizarov's bone transport treatment was performed in nine cases [27, 31, 32], autologous cancellous or corticocancellous bone grafts associated with hemisoleus muscle flaps in three cases [1, 2], and osteoseptocutaneous fibular flap grafts in two cases [1]. Lovisetti *et al.* [32] reported a series of seven patients treated at four different centres by internal bone transport using a circular external fixator. The amount of necrotic bone removed averaged 8 cm. Fracture healing occurred in all patients at an average of 11.5 months. High-risk patients could not be screened, although most of the patients were diabetic with a poor vascular supply in this series. Recently, the induced membrane technique developed by Masquelet has gained recognition in treating infected large bone defects [7]. It is a relatively simple technique, which avoids the use of a vascularized fibular graft. In this procedure, cancellous bone grafts harvested from the iliac crest are implanted in the membrane induced by a PMMA cement spacer placed in the void. In our case, soft tissue reconstruction and bone coverage were achieved by a myocutaneous latissimus dorsi free flap, which provided a well-vascularized environment that enhanced antibiotics diffusion and promoted bone healing. During the time necessary to treat bone infection, the cement spacer has a mechanical role in preventing scar tissue formation in the recipient site. It also induces the formation of a pseudosynovial membrane, which contains important growth factors that protect bone graft from resorption and stimulate bone vascularization and healing, especially when bone defects exceed 4–5 cm [8, 33]. Using this method, bone defects up to 25 cm were successfully treated, although several surgeries including an intertibiofibular graft could have been necessary to achieve definite bone healing [11, 34, 35].

## Conclusion

Surgeons should be aware of the potential factors that may contribute to osteocutaneous thermonecrosis, including narrow medullary canals and improper reaming. This case illustrates that the induced membrane technique described by Masquelet is a valuable option in treating

this devastating complication, which can cause large and infected bone and cutaneous defects.

## Conflict of Interest

All authors certify that they have NOT received any payments or benefits, during the study period.

## Ethical Review Committee Statement

The patient was informed that data from the case would be submitted for publication and gave his consent. Each author certifies that his institution approved the human protocol for this investigation that all investigations were conducted in conformity with ethical principles of research.

## Authorship

DH: was in charge of the patient. He conceived and designed the study, interpreted the results, and wrote the manuscript. MR: was in charge of the patient; he designed the study and made corrections to the manuscript. AC-B: interpreted the data and wrote the manuscript.

## References

1. Leunig, M., and R. Hertel. 1996. Thermal necrosis after tibial reaming for intramedullary nail fixation. A report of three cases. *J. Bone Joint Surg. Br.* 78:584–587.
2. Ochsner, P. E., F. Baumgart, and G. Kohler. 1998. Heat-induced segmental necrosis after reaming of one humeral and two tibial fractures with a narrow medullary canal. *Injury* 29(Suppl. 2):B1–B10.
3. Ruedi, T. 2004. An unusual case of an extensive heat necrosis. *Ther. Umsch.* 61:721–724.
4. Saldua, N. S., K. M. Kuhn, and M. T. Mazurek. 2008. Thermal necrosis complicating reamed intramedullary nailing of a closed tibial diaphysis fracture: a case report. *J. Orthop. Trauma* 22:737–741.
5. Baumgart, F., G. Kohler, and P. E. Ochsner. 1998. The physics of heat generation during reaming of the medullary cavity. *Injury* 29(Suppl. 2):B11–B25.
6. Cannon, C. P., P. P. Lin, V. O. Lewis, and A. W. Yasko. 2008. Management of radiation-associated fractures. *J. Am. Acad. Orthop. Surg.* 16:541–549.
7. Masquelet, A. C., F. Fitoussi, T. Begue, and G. P. Muller. 2000. Reconstruction of the long bones by the induced membrane and spongy autograft. *Ann. Chir. Plast. Esthet.* 45:346–353.
8. Pelissier, P., A. C. Masquelet, R. Bareille, S. M. Pelissier, and J. Amedee. 2004. Induced membranes secrete growth factors including vascular and osteoinductive factors and could stimulate bone regeneration. *J. Orthop. Res.* 22:73–79.

9. Blair, C., A. T. Simela, and B. J. Cross. 2015. A challenging case of limb salvage requiring a combination of composite fixation and masquelet technique to address significant segmental bone loss. *Case Rep. Orthop.* 2015:369469.
10. Luo, T. D., F. A. Jr Nunez, A. A. Lomer, and F. A. Sr Nunez. 2017. Management of recalcitrant osteomyelitis and segmental bone loss of the forearm with the Masquelet technique. *J. Hand Surg. Eur.* 42: 640–642.
11. Masquelet, A. C. 2003. Muscle reconstruction in reconstructive surgery: soft tissue repair and long bone reconstruction. *Langenbecks Arch. Surg.* 388:344–346.
12. Morelli, I., L. Drago, D. A. George, E. Gallazzi, S. Scarponi, and C. L. Romano. 2016. Masquelet technique: myth or reality? A systematic review and meta-analysis *Injury* 47(Suppl. 6):S68–S76.
13. Olesen, U. K., H. Eckardt, P. Bosemark, A. W. Paulsen, B. Dahl, and A. Hede. 2015. The Masquelet technique of induced membrane for healing of bone defects. A review of 8 cases. *Injury* 46(Suppl. 8):S44–S47.
14. Blachut, P. A., P. J. O'Brien, R. N. Meek, and H. M. Broekhuysse. 1997. Interlocking intramedullary nailing with and without reaming for the treatment of closed fractures of the tibial shaft. A prospective, randomized study. *J. Bone Joint Surg. Am.* 79:640–646.
15. Hupel, T. M., J. A. Weinberg, S. A. Aksenov, and E. H. Schemitsch. 2001. Effect of unreamed, limited reamed, and standard reamed intramedullary nailing on cortical bone porosity and new bone formation. *J. Orthop. Trauma* 15:18–27.
16. Collins, D. N., C. E. Pearce, and M. P. McAndrew. 1990. Successful use of reaming and intramedullary nailing of the tibia. *J. Orthop. Trauma* 4:315–322.
17. Dodenhoff, R. M. 1997. Thermal necrosis after tibial reaming. *J. Bone Joint Surg. Br.* 79:341.
18. Garcia, O. G., F. L. Mombiela, C. J. De La Fuente, M. G. Aranguez, D. V. Escribano, and J. V. Martin. 2004. The influence of the size and condition of the reamers on bone temperature during intramedullary reaming. *J. Bone Joint Surg. Am.* 86-A:994–999.
19. Giannoudis, P. V., S. Snowden, S. J. Matthews, S. W. Smye, and R. M. Smith. 2002. Friction burns within the tibia during reaming. Are they affected by the use of a tourniquet? *J. Bone Joint Surg. Br.* 84:492–496.
20. Giannoudis, P. V., S. Snowden, S. J. Matthews, S. W. Smye, and R. M. Smith. 2002. Temperature rise during reamed tibial nailing. *Clin. Orthop. Relat. Res.* 395:255–261.
21. Henry, S. L., R. A. Adcock, J. A. Von Fraunhofer, and D. Seligson. 1987. Heat of intramedullary reaming. *South. Med. J.* 80:173–176.
22. Pape, H. C., and P. Giannoudis. 2007. The biological and physiological effects of intramedullary reaming. *J. Bone Joint Surg. Br.* 89:1421–1426.
23. Berman, A. T., J. S. Reid, D. R. Jr Yanicko, G. C. Sih, and M. R. Zimmerman. 1984. Thermally induced bone necrosis in rabbits. Relation to implant failure in humans. *Clin. Orthop. Relat. Res.* 186:284–292.
24. Eriksson, A., T. Albrektsson, B. Grane, and D. McQueen. 1982. Thermal injury to bone. A vital-microscopic description of heat effects. *Int. J. Oral. Surg.* 11:115–121.
25. Eriksson, R. A., and T. Albrektsson. 1984. The effect of heat on bone regeneration: an experimental study in the rabbit using the bone growth chamber. *J. Oral Maxillofac. Surg.* 42:705–711.
26. Eriksson, R. A., T. Albrektsson, and B. Magnusson. 1984. Assessment of bone viability after heat trauma. A histological, histochemical and vital microscopic study in the rabbit. *Scand J. Plast. Reconstr. Surg.* 18:261–268.
27. Karunakar, M. A., E. P. Frankenburg, T. T. Le, and J. Hall. 2004. The thermal effects of intramedullary reaming. *J. Orthop. Trauma* 18:674–679.
28. Cox, G., E. Jones, D. McGonagle, and P. V. Giannoudis. 2011. Reamer-irrigator-aspirator indications and clinical results: a systematic review. *Int. Orthop.* 35:951–956.
29. Higgins, T. F., V. Casey, and K. Bachus. 2007. Cortical heat generation using an irrigating/aspirating single-pass reaming vs conventional stepwise reaming. *J. Orthop. Trauma* 21:192–197.
30. Billow, D., A. Khlopa, M. Chughtai, A. Saleh, M. B. Siqueira, P. Marinello, et al. 2016. The reamer-irrigator-aspirator system: a review. *Surg. Technol. Int.* XXIX:287–294.
31. Cattaneo, R., M. Catagni, and E. E. Johnson. 1992. The treatment of infected nonunions and segmental defects of the tibia by the methods of Ilizarov. *Clin. Orthop. Relat. Res.* 280:143–152.
32. Lovisetti, G., F. Sala, A. M. Thabet, M. A. Catagni, and S. Singh. 2011. Osteocutaneous thermal necrosis of the leg salvaged by TSF/Ilizarov reconstruction. Report of 7 patients. *Int. Orthop.* 35:121–126.
33. Viateau, V., M. Bensidhoum, G. Guillemin, H. Petite, D. Hannouche, F. Anagnostou, et al. 2010. Use of the induced membrane technique for bone tissue engineering purposes: animal studies. *Orthop. Clin. North Am.* 41:49–56.
34. Pelissier, P., D. Martin, J. Baudet, S. Lepreux, and A. C. Masquelet. 2002. Behaviour of cancellous bone graft placed in induced membranes. *Br. J. Plast. Surg.* 55:596–598.
35. Tarchala, M., E. J. Harvey, and J. Barralet. 2016. Biomaterial-stabilized soft tissue healing for healing of critical-sized bone defects: the Masquelet technique. *Adv. Healthc. Mater.* 5:630–640.