



Since January 2020 Elsevier has created a COVID-19 resource centre with free information in English and Mandarin on the novel coronavirus COVID-19. The COVID-19 resource centre is hosted on Elsevier Connect, the company's public news and information website.

Elsevier hereby grants permission to make all its COVID-19-related research that is available on the COVID-19 resource centre - including this research content - immediately available in PubMed Central and other publicly funded repositories, such as the WHO COVID database with rights for unrestricted research re-use and analyses in any form or by any means with acknowledgement of the original source. These permissions are granted for free by Elsevier for as long as the COVID-19 resource centre remains active.



SARS-CoV-2 infection associated with hepatitis in an infant with X-linked severe combined immunodeficiency

Nicolai S.C. van Oers^{a,b,c}, Natasha W. Hanners^b, Paul K. Sue^d, Victor Aquino^d, Quan-Zhen Li^a, John W. Schoggins^c, Christian A. Wysocki^{b,d,e,*}

^a Department of Immunology, The University of Texas Southwestern Medical Center, 6000 Harry Hines Boulevard, Dallas, TX 75390-9093, United States of America

^b Department of Pediatrics, The University of Texas Southwestern Medical Center, 6000 Harry Hines Boulevard, Dallas, TX 75390-9093, United States of America

^c Department of Microbiology, The University of Texas Southwestern Medical Center, 6000 Harry Hines Boulevard, Dallas, TX 75390-9093, United States of America

^d Children's Health, 1935 Medical District Drive, Dallas, TX 75235, United States of America

^e Department of Internal Medicine, The University of Texas Southwestern Medical Center, 6000 Harry Hines Boulevard, Dallas, TX 75390-9093, United States of America

ARTICLE INFO

Keywords:

SARS-CoV-2

COVID-19

Severe combined immunodeficiency

Inborn errors of immunity

Adaptive immunity

ABSTRACT

X-linked severe combined immunodeficiency (X-SCID) is a disorder of adaptive immunity caused by mutations in the IL-2 receptor common gamma chain gene resulting in deficiencies of T and natural killer cells, coupled with severe dysfunction in B cells. X-SCID is lethal without allogeneic stem cell transplant or gene therapy due to opportunistic infections. An infant with X-SCID became infected with SARS-CoV-2 while awaiting transplant. The patient developed severe hepatitis without the respiratory symptoms typical of COVID-19. He was treated with convalescent plasma, and thereafter was confirmed to have SARS-CoV-2 specific antibodies, as detected with a microfluidic antigen array. After resolution of the hepatitis, he received a haploidentical CD34 selected stem cell transplant, without conditioning, from his father who had recovered from COVID-19. SARS CoV-2 was detected via RT-PCR on nasopharyngeal swabs until 61 days post transplantation. He successfully engrafted donor T and NK cells, and continues to do well clinically.

1. Introduction

The threat to human health imposed by COVID-19 is enormous, with ongoing studies attempting to ascertain the pathogenic mechanisms of SARS-CoV-2. The roles of innate and adaptive immunity remain ill-defined. The high infectivity and rapid community spread are posited to reflect lack of existing immunity in the general population. Lymphopenia and markers of T-cell exhaustion correlate with severe disease and poor outcome [1,2]. Passive immunization with convalescent plasma may help reduce disease severity [3,4]. T-cells specific to viral peptides, as well as neutralizing antibodies, were shown to be present in patients surviving SARS and MERS [5,6], supporting the hypothesis that the adaptive response to novel coronaviruses is crucial for viral clearance and patient survival.

Information on SARS-CoV-2 infection in patients with defined inborn errors of immunity (IEI) has been limited [7–10]. One IEI is X-linked SCID, a severe disorder of adaptive immunity caused by mutations in the IL2RG gene, which encodes the IL-2 receptor common gamma chain.

Many cytokines signal through this receptor subunit, including IL-2, IL-4, IL-7, IL-9, IL-15 and IL-21 [11]. Deleterious mutations in IL2RG cause severe deficiencies in T cell and NK cell development (due to ineffective signaling in response to IL-7 and IL-15, respectively). Furthermore, while mature B cells develop in these patients, they are unable to mount nascent antibody responses owing to a lack of T cell help coupled with defective signaling through IL-4 and IL-21 receptors. This disease is lethal due to opportunistic infections unless an allogeneic hematopoietic stem cell transplantation or gene correction with lentiviral vector-based gene therapy is undertaken [12].

We report for the first time an infant with uncorrected X-linked SCID who became infected with SARS-CoV-2 while awaiting stem cell transplantation. The atypical course of COVID-19 disease in this infant is discussed, including his associated hepatitis, and the transfusion of convalescent plasma found to have IgG binding activity to diverse SARS-CoV-2 antigens. The patient was ultimately able to tolerate allogeneic stem cell transplantation. He had prolonged viral shedding, clearing after engraftment of donor T and NK cells.

* Corresponding author at: 5323 Harry Hines Boulevard, F4.100B, Dallas, TX 75390-8859, United States of America.

E-mail address: Christian.Wysocki@UTSouthwestern.edu (C.A. Wysocki).

<https://doi.org/10.1016/j.clim.2020.108662>

Received 29 October 2020; Received in revised form 29 December 2020; Accepted 30 December 2020

Available online 4 January 2021

1521-6616/© 2020 Elsevier Inc. All rights reserved.

2. Methods

2.1. Study approval

The Institutional Review Board at UT Southwestern Medical Center approved this study (IRB# 072010-009 and IRB# 112010-013). Parental consent was obtained from the father of the child. Serum samples were also obtained from 1-year toddlers who presented for standard of care Wellness visits prior to the emergence of COVID-19. Serum samples from COVID-19 patients were used as positive controls. This component of the study was conducted by Dr. Nicolai S.C. van Oers and Christian A. Wysocki utilizing samples and data supplied by the UT Southwestern SARS-CoV-2 Biorepository (<https://www.utsouthwestern.edu/covid-19/researchers/projects.html>). This manuscript was prepared by the authors of the study and does not necessarily reflect the opinions or views of the UT Southwestern SARS-CoV-2 Biorepository leadership or staff.

2.2. Antigen array analysis

Serum IgG antibody reactivities against SARS-Cov-2 antigens was assessed with a microfluidic antigen array comprising antigens from diverse Coronaviruses, including those from SARS-CoV-2. This customized antigen panel is available from the Genomics & Microarray Core Facility at The University of Texas Southwestern Medical Center. The various antigens are printed in quadruplet on a nitrocellulose membrane-coated slide with 16 identical sub-arrays, allowing comparisons of 15 different serum samples along with a PBS control [13,14]. The antigen arrays were performed as previously described [14]. In brief, serum samples were first heat-inactivated (56 °C 30 min) and 1 µl of serum from each sample was diluted 1:50 in PBS containing 0.01% Tween 20 (1/100). This was applied to the slide array with microfluidics, and IgG antibodies binding with antigens on the array was detected with Cy-3 conjugated anti-human IgG (1:1000) secondary antibody (Jackson ImmunoResearch Laboratory). The slides were scanned with a GenePix 4400A scanner (Molecular Device). Images in the array were converted to Genepix Report file (GPR) with Genepix Pro7.0 software (Molecular Device). The averaged fluorescent signal intensity of each antigen was subtracted by local background, the PBS control signal and normalized to internal controls to obtain the normalized signal intensity value (NSI).

2.3. RNA isolation from blood

RNA was isolated from the patient's whole blood and a negative control sample (derived from an unrelated patient prior to the SARS-CoV-2 epidemic) using trizol reagent and Direct-zol™ RNA Miniprep kit (Zymo Research).

2.4. Quantitative reverse transcription PCR (qRT-PCR), blood

A 20 µL reaction contained 5 µL RNA, 5ul TaqMan Fast Virus 1-step Master mix, 1.8 µL SARS-CoV-2 Primer/Probe mix, 1.8 µL GAPDH Primer/Probe mix, 6.4 µL Hyclone Cell Culture Grade dH2O. SARS-CoV-2 primers and probe were designed as recommended by the Center for Disease Control (<https://www.cdc.gov/coronavirus/2019-ncov/lab/rt-pcrpanel-primer-probes.html>). GAPDH primers and probe were designed as published [15]. (Table S2). All oligonucleotides were synthesized by LGC Biosearch Technologies. RT was performed at 50 °C for 5 min, followed by inactivation at 95 °C for 2 min, and 40 cycles of PCR (95 °C for 3 s, 60 °C for 30 s) on an ABI 7500 Fast thermocycler (Applied Biosystems).

2.5. SARS-CoV-2 positive control for qRT-PCR, blood

SARS-Cov-2 nucleocapsid (N) gene was amplified from a synthesized

N gene fragment (IDT) with primers that introduced a T7 promoter sequence on the 3' end (IDT) (Table S1). PCR product was purified using Qiagen PCR Purification Kit (Qiagen). *In vitro* transcription was performed using T7 RiboMAX Express Large Scale RNA Production System following manufacturers protocol (Promega). RNA was quantitated by nanodrop on DS11 FX. *In vitro* transcribed RNA was used to generate a standard curve for qPCR from a 10-fold dilution series starting at 5e10 copies of RNA.

3. Case description

3.1. Severe combined immunodeficiency diagnosis and initial management

A male infant was born full-term to nonconsanguineous parents. He is their only child. Newborn screens revealed the absence of T-cell receptor excision circles (TRECs). Flow cytometry demonstrated a pattern of T⁻ B⁺ NK⁻ SCID (Table 1). Maternal engraftment studies were negative. Proliferation to the T-cell mitogen phytohemagglutinin was also absent. Genetic analysis revealed a likely pathogenic splice site mutation in the IL2RG gene (c.758-2A > G) (Fig. 1A). Based on the above data, he met the diagnostic criteria for SCID [16].

The child was started on Bactrim and acyclovir prophylaxis along with monthly intravenous immunoglobulin (IVIG). Baseline IgG level prior to start of IVIG was 597 mg/dL. Regular laboratory monitoring demonstrated normal complete blood counts (with the exception of lymphopenia related to his X-SCID), normal hepatic and renal function, and negative PCR surveillance for cytomegalovirus, Epstein Barr virus, adenovirus and human herpesvirus 6. Initial PCR for HIV, herpes simplex, varicella zoster, hepatitis B and C viruses was negative. Given the X-linked SCID genotype, the patient was referred for allogeneic stem cell transplant. His father was matched at 6 out of 10 HLA markers and was selected as the donor.

Table 1

Lymphocyte enumeration in blood by flow cytometry (Day of life (DOL), hospital day (HD) and post-transplant day (T)) (note: absolute lymphocyte counts for flow cytometry were calculated on separate samples than CBC with differential from same day, thus slight differences exist between data in this table and supplemental Table 1).

	DOL 28	DOL 53	DOL 83 (HD#4)	DOL 104 (HD#25)	DOL 154 (T + 47)	Reference range
Absolute lymphocyte count (/ul)	977	1271	1510	2512	3920	
CD3+ %	11.7	1.3	2.7	0.7	31.3	51–77%
CD3+ abs (/ul)	114	16	39	18	1300	2500–5800/ul
CD3 + 4+ %	1.2	0.4	1.1	0.4	27	35–58%
CD3 + 4+ abs (/ul)	12	5	15	9	1120	1800–4000/ul
CD3 + 8+ %	9.7	0.9	2.4	0.6	5.1	12–23%
CD3 + 8+ abs (/ul)	95	12	34	16	213	590–1600/ul
CD16/56+ %	5.5	2.3	0.3	0.5	12	3–14%
CD16/56+ abs (/ul)	54	29	4	13	497	170–830/ul
CD19+ %	78.8	95.1	94.6	95	51.3	11–41%
CD19+ abs (/ul)	770	1208	1340	2386	2133	430–3000/ul
CD3 + 4 + RA + 62 L+ % of tot CD4	<0.1	33.3		<0.1		64–92%
CD3 + 8 + RA + 62 L+ % of tot CD8	8.3	15		<0.1		53–88%

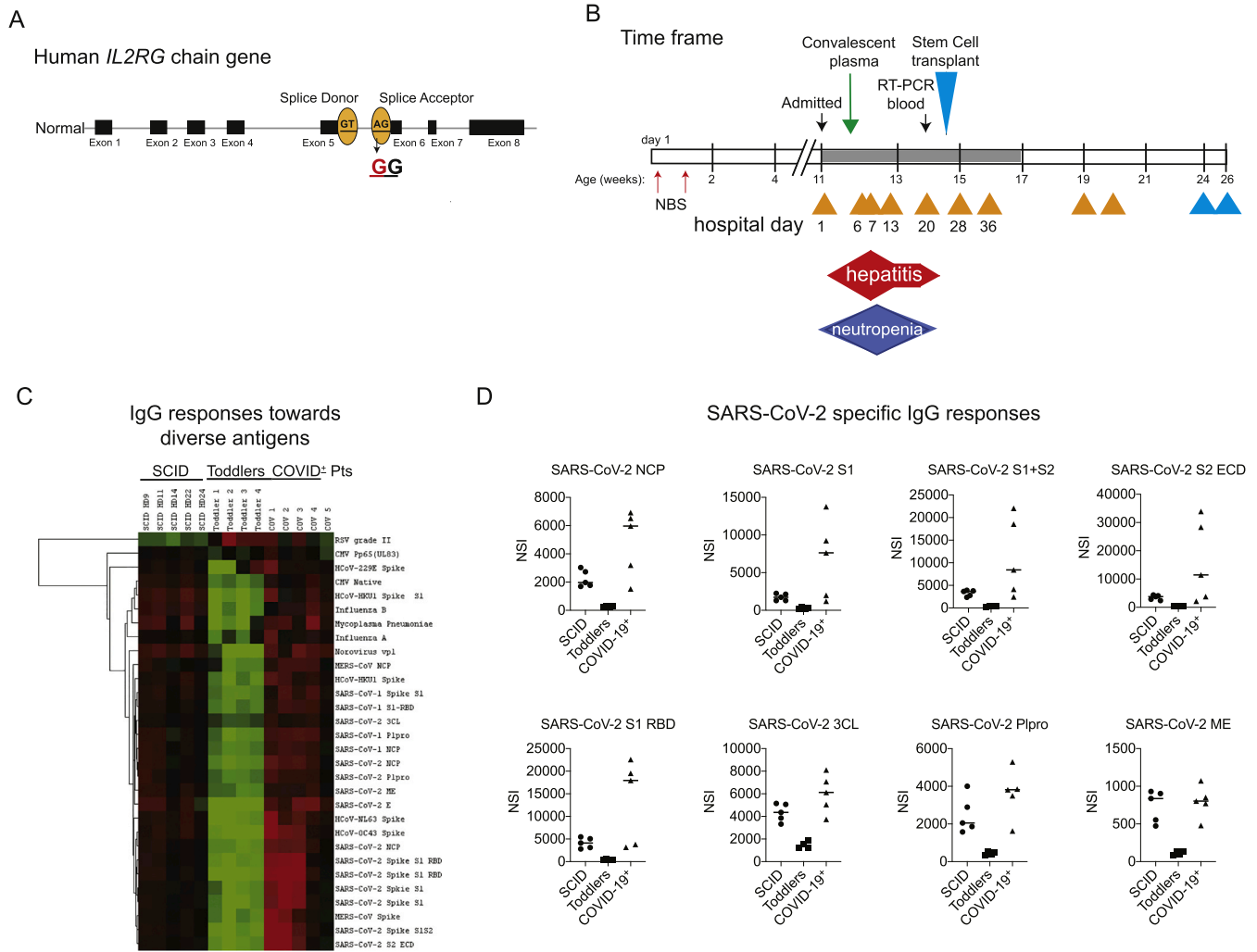


Fig. 1. A. IL2RG gene map with patient’s mutation at the intron 5 splice acceptor. B. Time course of events throughout the patient’s life. Grey filled horizontal bar represents the hospitalization. Small yellow triangles represent positive RT-PCR tests for SARS-CoV-2. Small blue triangles indicate negative tests. C. Heatmap of IgG binding activity in patient serum at various timepoints after convalescent plasma, in samples from non-SARS-CoV-2 infected infants, and COVID-19 patients from a patient registry. D. Relative IgG binding activity for SARS-CoV-2 spike proteins S1 and S2, RBD, NCP as well as S2 extracellular domain (ECD), 3CL and Papain-like proteases (Plpro), and M and Envelope proteins. Y axes represent net signal intensity (NSI) in which background staining is subtracted from each sample. (For interpretation of the references to colour in this figure legend, the reader is referred to the web version of this article.)

3.2. SARS-CoV-2 infection and disease course

As the infant was awaiting transplant, his father developed fever, pharyngitis, and cough, and tested positive for SARS-CoV-2 infection. The 11-week old infant was also was determined to be SARS-CoV-2 positive by RT-PCR on a nasopharyngeal (NP) swab and was admitted for an assessment. He was afebrile, hemodynamically stable, respiratory rate was normal and oxygen saturation 99% on room air. His physical exam was normal. A chest radiograph showed mild bronchial wall thickening without focal opacity. Lab evaluations showed a significant and worsening hepatitis during the first several days of the hospitalization. Transaminases peaked on hospital day (HD) 6 with aspartate aminotransferase (AST) 1412 U/L and alanine aminotransferase (ALT) 623 U/L. An extensive evaluation for other infections was performed including PCR tests for adenovirus, CMV, EBV, HSV, VZV, HHV-6, hepatitis A, hepatitis B, hepatitis C, hepatitis E, enterovirus, parvovirus, and an extensive panel of respiratory viruses, all of which were negative. He had a positive d-dimer. His activated partial thromboplastin time was slightly elevated while other coagulation tests were normal. He was not given anticoagulation. Ferritin and procalcitonin were elevated on admission. Sedimentation rate, C-reactive protein and

fibrinogen were normal. IL-10 was modestly elevated, while pro-inflammatory cytokines such as IL-6, IL-1 beta, TNF-alpha, IL-12 and interferon-gamma were within normal reference ranges. He was neutropenic for the first 11 days of the hospitalization with nadir at day 7. Lymphocyte counts remained low (in keeping with his SCID), but not below his pre-hospitalization baseline. A detailed view of lab data during the hospitalization is in Supplementary Table 1.

SARS-CoV-2 specific RT PCR was performed using NP swabs and was positive on HD6, HD7, HD13, HD20 and HD28 (Cepheid XPERT^R Express SARS-CoV-2 assay, Sunnyvale, California, U.S.A.) (Table 2). The limit of detection with this assay is 0.0050 PFU/ml for the nucleocapsid gene (N2 region) (mean cycle threshold (Ct) 40.5), and 0.0200 PFU/ml for the envelope (E) gene (mean Ct 36.4). Available Ct values for patient samples are detailed in supplemental Table 1. Although initially near the limit of detection, later samples were clearly not in equivocal ranges.

His worsening hepatitis precluded treatment with remdesivir. Given his immunodeficiency, he was treated with COVID-19 convalescent plasma at a dose of 20 mL/kg on HD6 and was continued on IVIG every 2 weeks. IgG specific for SARS-CoV-2 was assessed thereafter and was positive in serum on HD8 using a qualitative test (Abbott, Abbot Park, Illinois, U.S.A.). Seropositivity was still evident at HD11 and 19,

eventually becoming negative on HD25 (supplemental Table 1). RT-PCR on blood collected on HD19 was negative for SARS-CoV-2, indicating a lack of systemic viremia at that timepoint (supplemental Table 1).

To get a better perspective on the nature of the seropositivity to SARS-CoV-2 after plasma treatment, a microfluidic antigen array containing diverse coronaviruses, SARS-CoV-2 specific antigens and other infectious agents was used to screen the IgG binding reactivities. Serum samples from HD9, 11, 14, 22 and 24 were tested with these arrays (Fig. 1C and D). The serum from each time point had IgG binding activity to the SARS-CoV-2 S1 and S2 spike proteins, the receptor binding domain (RBD) of spike protein, the nucleocapsid protein (NCP) and the envelope protein. For comparison and to establish baseline levels of IgG reactivity, samples from a cohort of normal 1-year old toddlers was also tested. None of these samples demonstrated SARS-CoV-2 specific IgG responses. Unfortunately, no pre-treatment serum sample was available from our patient. As positive controls, the serum from 5 children (age range 5–12 years) with COVID-19 were also tested. While these samples showed positive reactivity towards diverse SARS-CoV-2 antigens, there were some individual variations regarding the proteins being recognized.

For the SARS-CoV-2-infected infant, the transaminitis began improving after the convalescent plasma infusion, normalizing by HD27. Neutropenia (presumed to be due to viral suppression) normalized on HD14. The patient did not develop cough or respiratory compromise at any point. During the patient's hospitalization, his father became asymptomatic, and was able to donate hematopoietic stem cells after G-CSF mobilization. These were CD34 selected and administered to the patient without conditioning, on HD27. Post-transplant course was complicated only by mild skin GVHD, resolving with a 3-day course of oral steroid. Chimerism testing at day +33 post-transplantation showed 100% donor in CD3⁺ T cells, 99% in CD56⁺ NK cells, with 0% in CD19⁺ B cells and CD33⁺ cells, as expected. Day +47 post-transplant, flow cytometry showed evidence of T and NK cell recovery (Table 1). The patient remained positive for SARS-CoV-2 by RT-PCR on NP swabs on days +2, 9 and 33 post-transplant, yet remained asymptomatic with normal liver function tests. RT-PCR on NP swabs became negative on transplant day +61 and remained negative on day +75 (Fig. 1B). Therefore, the total time of RT-PCR positivity in nasal swabs was at least 59 days (from the first hospital day, through the last negative test on day +33 after transplant), and the total time to negative PCR testing was 87 days (from the first hospital day until post-transplant day +61).

4. Discussion

The X-linked SCID patient described in the current study had an atypical course with SARS-CoV-2 infection, with hepatitis, minimal respiratory involvement and prolonged viral shedding, raises intriguing questions as to the role which adaptive immunity and NK cells play in disease severity and viral clearance. The notion that adaptive immune dysfunction may not portend severe COVID-19 disease is supported by findings in HIV patients [17], patients with congenital agammaglobulinemia [7], patients immunocompromised due to malignancy or transplant [18], and in a recent retrospective analysis of 94 mainly adult patients with diverse inborn errors of immunity [9]. Furthermore, a detailed comparison of immune responses in patients with COVID-19 demonstrated that an early and sustained elevation in type 1, 2 and 3 cytokines correlated with severe disease [19], suggesting that the strength and persistence of the adaptive and cellular immune response to SARS-CoV-2 infection may determine the severity of the clinical manifestations. The relative role of the innate type I interferon response in determining disease severity has been suggested by the enrichment in deleterious variants in genes involved in type I interferon signaling, and high frequency of autoantibodies against interferon-omega or interferon-alpha in patients with life-threatening COVID-19 disease [10,20]. This in turn suggests that the lack of T and NK cells in our patient may have mitigated immune and inflammatory damage in

typical sites such as lung, while the innate type I interferon response remained intact to provide containment of infection.

The duration of SARS-CoV-2 viral shedding in pediatric patients with COVID-19 has been examined in detail. A recent systematic review compiled data on 69 children from 17 published studies, and found that positivity by RT-PCR on NP swabs ranged 0–24 days, with the mean duration of viral shedding in symptomatic patients 11.1 days after symptom onset, and mean total viral shedding in asymptomatic patients 9.4 days [21]. A report on 110 children from Wuhan, China showed a range of 5–37 days (median 15 days), with symptomatic infection, fever, pneumonia and lymphopenia associated with longer durations of viral shedding [22]. While data on the duration of viral shedding in patients with IEI are lacking, data in transplant patients on cellular immunosuppressants indicate prolonged periods of viral shedding. In one study in adult renal transplant patients, only 8 of 40 study patients cleared the virus by RT-PCR within the 53 day follow up period [23]. Our patient had a very protracted period of viral shedding in comparison to immunocompetent children, with clearance by RT-PCR on NP swabs correlating with engraftment of donor T and NK cells. This suggests that while adaptive and cellular immunity may contribute to the deleterious effects of SARS-CoV-2 infection, they may ultimately be necessary for viral clearance.

Although this patient did not have respiratory compromise, his severe hepatitis suggests viral cytopathology in the liver. The SARS-CoV-2 receptor, angiotensin converting enzyme 2 (ACE2) is expressed on cholangiocytes and to a lesser degree on hepatocytes [24]. In fact, hepatitis is seen in 14–53% of COVID-19 cases, caused by direct viral cytopathic effect, immune and inflammatory damage, sepsis, thrombotic disease and/or drug induced injury [25]. In our patient's case the isolated hepatitis was perplexing with no evidence of sepsis, and no disseminated intravascular coagulation. He did not meet the case definition criteria for multisystem inflammatory disease in children (MIS-C) [26,27]. The infant tolerated all prophylactic medications according to pre-hospitalization labs with no evidence of drug induced injury.

Although not directly tested, the patient's ability to mount a nascent IgG antibody response to SARS-CoV-2 infection was likely severely compromised by both his age and IL-2 common gamma chain deficiency. We therefore attempted to provide passive IgG immunity through transfusion of COVID-19 convalescent plasma. A recent Cochrane systematic review indicated uncertainty as to whether convalescent plasma reduces COVID-19 disease mortality, although noted that it may increase improvement in symptoms at 15–30 days post-infusion [28]. In our patient's case we may have provided additional passive neutralizing anti-SARS-CoV-2 IgG through his IVIG infusions [29]. We were able to confirm the presence in the patient's circulation of broad IgG binding activity against SARS-CoV-2 viral proteins at several timepoints after plasma transfusion. The improvement in the patient's hepatitis which was observed after administration of convalescent plasma was intriguing although only correlative.

In summary, the lack of T cells, NK cells, and functional B cells in our patient did not lead to fulminant or severe respiratory compromise typical of COVID-19 disease, but instead was associated with an atypical course which included hepatitis of presumed viral etiology and prolonged viral shedding in nasal samples. Clinical improvement correlated with delivery of convalescent plasma with broad binding activity against SARS-CoV-2 antigens. Viral clearance correlated with engraftment of donor T and NK cells after allogeneic stem cell transplant. The findings in this unique patient should inform future studies on the role of adaptive immunity and NK cells in determining the severity and clinical manifestations of COVID-19 and viral clearance.

Declaration of Competing Interest

None.

Acknowledgements

We appreciate the immense help from Drs. D Greenberg, B. Greenberg, N. Monson, and M. Gill in procuring COVID-19 positive serum samples from the UT Southwestern Medical Center Biorepository. Thank you to Jennifer Eitson for technical advice and supplies for qRT-PCR. Thank you to Claudia Rivera for assistance with IRB documentation and consent procedures, and to Nic Duly and Laura Filkins for assistance with lab sample and data procurement. Our work was supported in part by grants from the National Institutes of Health RO1 (RO1 AI114523 N. S.C. v.O.), NIH grant K08 AI132751-01A1 (N.W.H.), Beecherl funds from the Department of Immunology at UT Southwestern Medical Center (N.S.C.v.O.) and funds from the Jeffrey Modell Foundation (C.A. W.).

Appendix A. Supplementary data

Supplementary data to this article can be found online at <https://doi.org/10.1016/j.clim.2020.108662>.

References

- [1] C. Huang, Y. Wang, X. Li, L. Ren, J. Zhao, Y. Hu, L. Zhang, G. Fan, J. Xu, X. Gu, Z. Cheng, T. Yu, J. Xia, Y. Wei, W. Wu, X. Xie, W. Yin, H. Li, M. Liu, Y. Xiao, H. Gao, L. Guo, J. Xie, G. Wang, R. Jiang, Z. Gao, Q. Jin, J. Wang, B. Cao, Clinical features of patients infected with 2019 novel coronavirus in Wuhan, China, *Lancet*. 395 (2020) 497–506, [https://doi.org/10.1016/S0140-6736\(20\)30183-5](https://doi.org/10.1016/S0140-6736(20)30183-5).
- [2] B. Diao, C. Wang, Y. Tan, X. Chen, Y. Liu, L. Ning, L. Chen, M. Li, Y. Liu, G. Wang, Z. Yuan, Z. Feng, Y. Zhang, Y. Wu, Y. Chen, Reduction and functional exhaustion of T cells in patients with coronavirus disease 2019 (COVID-19), *Front. Immunol.* 11 (2020) 1–7, <https://doi.org/10.3389/fimmu.2020.00827>.
- [3] E. Salazar, K.K. Perez, M. Ashraf, J. Chen, B. Castillo, P.A. Christensen, T. Eubank, D.W. Bernard, T.N. Eagar, S.W. Long, S. Subedi, R.J. Olsen, C. Leveque, M. R. Schwartz, M. Dey, C. Chavez-East, J. Rogers, A. Shehabeldin, D. Joseph, G. Williams, K. Thomas, F. Masud, C. Talley, K.G. Dlouhy, B.V. Lopez, C. Hampton, J. Lavinder, J.D. Gollihar, A.C. Maranhao, G.C. Ippolito, M.O. Saavedra, C. C. Cantu, P. Yerramilli, L. Pruiett, J.M. Musser, Treatment of coronavirus disease 2019 (COVID-19) patients with convalescent plasma, *Am. J. Pathol.* 190 (2020) 1680–1690, <https://doi.org/10.1016/j.ajpath.2020.05.014>.
- [4] C. Shen, Z. Wang, F. Zhao, Y. Yang, J. Li, J. Yuan, F. Wang, D. Li, M. Yang, L. Xing, J. Wei, H. Xiao, Y. Yang, J. Qu, L. Qing, L. Chen, Z. Xu, P. Peng, Y. Li, H. Zheng, F. Chen, K. Huang, Y. Jiang, D. Liu, Z. Zhang, Y. Liu, L. Liu, Treatment of 5 critically ill patients with COVID-19 with convalescent plasma, *JAMA - J. Am. Med. Assoc.* 323 (2020) 1582–1589, <https://doi.org/10.1001/jama.2020.4783>.
- [5] H. Peng, L. Tao Yang, J. Li, Z. Qiang Lu, L. Yun Wang, R.A. Koup, R.T. Bailer, C. You Wu, Human memory T cell responses to SARS-CoV E protein, *Microbes Infect.* 8 (2006) 2424–2431, <https://doi.org/10.1016/j.micinf.2006.05.008>.
- [6] J. Zhao, A.N. Alshukairi, S.A. Baharoon, W.A. Ahmed, A.A. Bokhari, A.M. Nehdi, L. A. Layqah, M.G. Alghamdi, M.M. Al Gethamy, A.M. Dada, I. Khalid, M. Boujelal, S. M. Al Johani, L. Vogel, K. Subbarao, A. Mangalam, C. Wu, P. Ten Eyck, S. Perlman, J. Zhao, Recovery from the Middle East respiratory syndrome is associated with antibody and T cell responses, *Sci. Immunol.* 2 (2017) 1–11, <https://doi.org/10.1126/sciimmunol.aan5393>.
- [7] I. Quinti, V. Lougaris, C. Milito, F. Cinetto, A. Pecoraro, I. Mezzaroma, C. M. Mastroianni, O. Turriziani, M.P. Bondioni, M. Filippini, A. Soresina, G. Spadaro, C. Agostini, R. Carsetti, A. Plebani, A possible role for B cells in COVID-19? Lesson from patients with agammaglobulinemia, *J. Allergy Clin. Immunol.* 146 (2020), <https://doi.org/10.1016/j.jaci.2020.04.013>.
- [8] L.M. Castano-Jaramillo, M.A. Yamazaki-Nakashimada, S.C. Scheffler Mendoza, J. C. Bustamante-Ogando, S.E. Espinosa-Padilla, S.O. Lugo Reyes, A male infant with COVID-19 in the context of ARPC1B deficiency, *Pediatr. Allergy Immunol.* (2020), <https://doi.org/10.1111/pai.13322>.
- [9] I. Meyts, G. Buccioli, I. Quinti, B. Neven, A. Fischer, E. Seoane, E. Lopez-Granados, C. Gianelli, A. Robles-Marhuenda, P.-Y. Jeandel, C. Paillard, V.G. Sankaran, Y. C. Demirdag, V. Lougaris, A. Aiuti, A. Plebani, C. Milito, V.A. Dalm, K. Guevara-Hoyer, S. Sánchez-Ramón, L. Bezrodnik, F. Barzaghi, L.L. Gonzalez-Granado, G. R. Hayman, G. Uzel, L.O. Mendonça, C. Agostini, G. Spadaro, R. Badolato, A. Soresina, F. Vermuelen, C. Bosteels, B.N. Lambrecht, M. Keller, P.J. Mustillo, R. S. Abraham, S. Gupta, A. Ozen, E. Karakoc-Aydiner, S. Baris, A. Freeman, M. Yamazaki-Nakashimada, S. Scheffler-Mendoza, S. Espinosa-Padilla, A. R. Gennery, S. Jolles, Y. Espinoza, M.C. Poli, C. Fieschi, F. Hauck, C. Cunningham-Rundles, N. Mahlaoui, K. Warnatz, K.E. Sullivan, S.G. Tangye, Coronavirus disease 2019 in patients with inborn errors of immunity: an international study, *J. Allergy Clin. Immunol.* (2020) 1–12, <https://doi.org/10.1016/j.jaci.2020.09.010>.
- [10] Q. Zhang, P. Bastard, Z. Liu, J. Le Pen, M. Moncada-Velez, J. Chen, M. Ogishi, I.K. D. Sabli, S. Hodeib, C. Korol, J. Rossan, K. Bilguvar, J. Ye, A. Bolze, B. Bigio, R. Yang, A.A. Arias, Q. Zhou, Y. Zhang, F. Onodi, S. Korniotis, L. Karpf, Q. Philippot, M. Chbihi, L. Bonnet-Madin, K. Dorgham, N. Smith, W.M. Schneider, B.S. Razoooky, H.-H. Hoffmann, E. Michailidis, L. Moens, J.E. Han, L. Lorenzo,
- L. Bizien, P. Meade, A.-L. Neehus, A.C. Ugurbil, A. Corneau, G. Kerner, P. Zhang, F. Rapaport, Y. Seeleuthner, J. Manry, C. Masson, Y. Schmitt, A. Schlüter, T. Le Voyer, T. Khan, J. Li, J. Fellay, L. Roussel, M. Shahrooei, M.F. Alosaimi, D. Mansouri, H. Al-Saud, F. Al-Mulla, F. Almoufry, S.Z. Al-Muhsen, F. Alosaime, S. Al Turki, R. Hasanato, D. van de Beek, A. Biondi, L.R. Bettini, M. D'Angio, P. Bonfanti, L. Imberti, A. Sottini, S. Paghera, E. Quirós-Roldan, C. Rossi, A.J. Oler, M.F. Tompkins, C. Alba, I. Vandernoot, J.-C. Goffard, G. Smits, I. Migeotte, F. Haerynck, P. Soler-Palacin, A. Martin-Nalda, R. Colobran, P.-E. Morange, S. Keles, F. Çölkesen, T. Özcelik, K.K. Yasar, S. Senoglu, Ş.N. Karabela, C. R. Gallego, G. Novelli, S. Hraiech, Y. Tandjaoui-Lambiotte, X. Duval, C. Laouénan, A.L. Snow, C.L. Dalgard, J. Milner, D.C. Vinh, T.H. Mogensen, N. Marr, A.N. Spaan, B. Boisson, S. Boisson-Dupuis, J. Bustamante, A. Puel, M. Ciancanelli, I. Meyts, T. Maniatis, V. Soumelis, A. Amara, M. Nussenzweig, A. García-Sastre, F. Kramer, A. Pujol, D. Duffy, R. Lifton, S.-Y. Zhang, G. Gorochov, V. Béziat, E. Jouanguy, V. Sancho-Shimizu, C.M. Rice, L. Abel, L.D. Notarangelo, A. Cobat, H.C. Su, J.-L. Casanova, Inborn errors of type I IFN immunity in patients with life-threatening COVID-19, *Science* 4570 (2020) eabd4570, <https://doi.org/10.1126/science.abd4570>.
- [11] W.J. Leonard, J.X. Lin, J.J. O'Shea, The γ c family of cytokines: basic biology to therapeutic ramifications, *Immunity*. 50 (2019) 832–850, <https://doi.org/10.1016/j.immuni.2019.03.028>.
- [12] E. Mamcarz, S. Zhou, T. Lockey, H. Abdelsamed, S.J. Cross, G. Kang, Z. Ma, J. Condori, J. Dowdy, B. Triplett, C. Li, G. Maron, J.C. Aldave Becerra, J.A. Church, E. Dokmeci, J.T. Love, A.C. Da Matta Ain, H. Van Der Watt, X. Tang, W. Janssen, B. Y. Ryu, S.S. De Ravin, M.J. Weiss, B. Youngblood, J.R. Long-Boyle, S. Gottschalk, M.M. Meagher, H.L. Malech, J.M. Puck, M.J. Cowan, B.P. Sorrentino, Lentiviral gene therapy combined with low-dose busulfan in infants with SCID-X1, *N. Engl. J. Med.* 380 (2019) 1525–1534, <https://doi.org/10.1056/NEJMoa1815408>.
- [13] L.Z. Quan, C. Xie, T. Wu, M. Mackay, C. Aranow, C. Putterman, C. Mohan, Identification of autoantibody clusters that best predict lupus disease activity using glomerular proteome arrays, *J. Clin. Invest.* 115 (2005) 3428–3439, <https://doi.org/10.1172/JCI23587>.
- [14] Q.Z. Li, J. Zhou, A.E. Wandstrat, F. Carr-Johnson, V. Branch, D.R. Karp, C. Mohan, E.K. Wakeland, N.J. Olsen, Protein array autoantibody profiles for insights into systemic lupus erythematosus and incomplete lupus syndromes, *Clin. Exp. Immunol.* 147 (2007) 60–70, <https://doi.org/10.1111/j.1365-2249.2006.03251.x>.
- [15] K. Shirato, M. Kawase, S. Matsuyama, Middle East respiratory syndrome coronavirus infection mediated by the transmembrane serine protease TMPRSS2, *J. Virol.* 87 (2013) 12552–12561, <https://doi.org/10.1128/jvi.01890-13>.
- [16] W.T. Shearer, E. Dunn, L.D. Notarangelo, C.C. Dvorak, J.M. Puck, B.R. Logan, L. M. Griffith, D.B. Kohn, R.J. O'Reilly, T.A. Fleisher, S.Y. Pai, C.A. Martinez, R. H. Buckley, M.J. Cowan, Establishing diagnostic criteria for severe combined immunodeficiency disease (SCID), leaky SCID, and Omenn syndrome: the primary immune deficiency treatment consortium experience, *J. Allergy Clin. Immunol.* 133 (2014) 1092–1098, <https://doi.org/10.1016/j.jaci.2013.09.044>.
- [17] P. Vizcarra, M.J. Pérez-Eliás, C. Quereda, A. Moreno, M.J. Vivanco, F. Dronza, J. L. Casado, S. Moreno, M.J. Pérez-Eliás, J. Fortín, E. Navas, S. Del Campo, R. López-Vélez, J. Cobo Reinoso, J.L. Casado, F. Norman, P. Martín-Dávila, J.M. Hermida, J. A. Pérez Molina, B. Monge, V. Pintado, S. Serrano-Villar, M. Sánchez-Conde, S. Chamorro, R. Escudero, F. Gioia, B. Comeche, C. Crespillo, S. Herrera, R. Ron, J. Martínez-Sanz, M. Pons-Guillén, M.J. Vivanco, Description of COVID-19 in HIV-infected individuals: a single-centre, prospective cohort, *Lancet HIV* 7 (2020) e554–e564, [https://doi.org/10.1016/S2352-3018\(20\)30164-8](https://doi.org/10.1016/S2352-3018(20)30164-8).
- [18] C. Minotti, F. Tirelli, E. Barbieri, C. Giaquinto, D. Donà, How is immunosuppressive status affecting children and adults in SARS-CoV-2 infection? A systematic review, *J. Inf. Secur.* 81 (2020) e61–e66, <https://doi.org/10.1016/j.jinf.2020.04.026>.
- [19] C. Lucas, P. Wong, J. Klein, T.B.R. Castro, J. Silva, M. Sundaram, M.K. Ellingson, T. Mao, J.E. Oh, B. Israelow, T. Takahashi, M. Tokuyama, P. Lu, A. Venkataraman, A. Park, S. Mohanty, H. Wang, A.L. Wylie, C.B.F. Vogels, R. Earnest, S. Lapidus, I. M. Ott, A.J. Moore, M.C. Muenker, J.B. Fournier, M. Campbell, C.D. Odio, A. Casanovas-Massana, A. Obaid, A. Lu-Culligan, A. Nelson, A. Brito, A. Nunez, A. Martin, A. Watkins, B. Geng, C. Kalinich, C. Harden, C. Todeasa, C. Jensen, D. Kim, D. McDonald, D. Shepard, E. Courchaine, E.B. White, E. Song, E. Silva, E. Kudo, G. Defulius, H. Rahming, H.J. Park, I. Matos, J. Nouws, J. Valdez, J. Fauver, J. Lim, K.A. Rose, K. Anastasio, K. Brower, L. Glick, L. Sharma, L. Sevanan, L. Knaggs, M. Minasyan, M. Batsu, M. Petrone, M. Kuang, M. Nakahata, M. Campbell, M. Linehan, M.H. Askenase, M. Simonov, M. Smolgovsky, N. Sonnert, N. Naushad, P. Vijayakumar, R. Martinello, R. Datta, R. Handoko, S. Bermejo, S. Prophet, S. Bickerton, S. Velazquez, T. Alpert, T. Rice, W. Khoury-Hanold, X. Peng, Y. Yang, Y. Cao, Y. Strong, R. Herbst, A.C. Shaw, R. Medzhitov, W.L. Schulz, N.D. Grubaugh, C. Dela Cruz, S. Farhadian, A.I. Ko, S. B. Omer, A. Iwasaki, Longitudinal analyses reveal immunological misfiring in severe COVID-19, *Nature* 584 (2020), <https://doi.org/10.1038/s41586-020-2588-y>.
- [20] P. Bastard, L.B. Rosen, Q. Zhang, E. Michailidis, H.-H. Hoffmann, Y. Zhang, K. Dorgham, Q. Philippot, J. Rosain, V. Béziat, J. Manry, E. Shaw, L. Haljasmägi, P. Peterson, L. Lorenzo, L. Bizien, S. Trouillet-Assant, K. Dobbs, A. De Jesus, A. Belot, A. Kallaste, E. Catherinot, Y. Tandjaoui-Lambiotte, J. Le Pen, G. Kerner, B. Bigio, Y. Seeleuthner, R. Yang, A. Bolze, A.N. Spaan, O.M. Delmonte, M.S. Abers, A. Aiuti, G. Casari, V. Lampasona, L. Piemonti, F. Ciceri, K. Bilguvar, R.P. Lifton, M. Vasse, D.M. Smadja, M. Migaud, J. Hadjadj, B. Terrier, D. Duffy, L. Quintana-Murci, D. van de Beek, L. Roussel, D.C. Vinh, S.G. Tangye, F. Haerynck, D. Dalmau, J. Martinez-Picado, P. Brodin, M.C. Nussenzweig, S. Boisson-Dupuis, C. Rodríguez-Gallego, G. Vogt, T.H. Mogensen, A.J. Oler, J. Gu, P.D. Burbelo, J. Cohen, A. Biondi, L.R. Bettini, M. D'Angio, P. Bonfanti, P. Rossignol, J. Mayaux, F. Rieux-Laucat, E.S. Husebye, F. Fusco, M.V. Ursini, L. Imberti, A. Sottini, S. Paghera,

- E. Quiros-Roldan, C. Rossi, R. Castagnoli, D. Montagna, A. Licari, G.L. Marseglia, X. Duval, J. Ghosn, J.S. Tsang, R. Goldbach-Mansky, K. Kisand, M.S. Lionakis, A. Puel, S.-Y. Zhang, S.M. Holland, G. Gorochov, E. Jouanguy, C.M. Rice, A. Cobat, L.D. Notarangelo, L. Abel, H.C. Su, J.-L. Casanova, Auto-antibodies against type I IFNs in patients with life-threatening COVID-19, *Science* 4585 (2020) eabd4585, <https://doi.org/10.1126/science.abd4585>.
- [21] C.L.H. Xu, M. Raval, J.A. Schnall, J.C. Kwong, N.E. Holmes, Duration of respiratory and gastrointestinal viral shedding in children with SARS-CoV-2: a systematic review and synthesis of data, *Pediatr. Infect. Dis. J.* 39 (2020) E249–E256, <https://doi.org/10.1097/INF.0000000000002814>.
- [22] Y. Lu, Y. Li, W. Deng, M. Liu, Y. He, L. Huang, M. Lv, J. Li, H. Du, Symptomatic infection is associated with prolonged duration of viral shedding in mild coronavirus disease 2019: a retrospective study of 110 children in Wuhan, *Pediatr. Infect. Dis. J.* 39 (2020) E95–E99, <https://doi.org/10.1097/INF.0000000000002729>.
- [23] I. Benotmane, G. Gautier-Vargas, M.J. Wendling, P. Perrin, A. Velay, X. Bassand, D. Bedo, C. Baldacini, M. Sagnard, D.F. Bozman, M. Della-Chiesa, M. Solis, F. Gallais, N. Cognard, J. Olagne, H. Delagrèverie, L. Gontard, B. Panaget, D. Marx, F. Heibel, L. Braun-Parvez, B. Moulin, S. Caillard, S. Fafi-Kremer, In-depth virological assessment of kidney transplant recipients with COVID-19, *Am. J. Transplant.* (2020) 1–11, <https://doi.org/10.1111/ajt.16251>.
- [24] X. Chai, L. Hu, Y. Zhang, W. Han, Z. Lu, A. Ke, J. Zhou, G. Shi, N. Fang, J. Fan, J. Cai, J. Fan, F. Lan, Specific ACE2 expression in cholangiocytes may cause liver damage after 2019-nCoV infection, *bioRxiv* (2020), <https://doi.org/10.1101/2020.02.03.931766>.
- [25] D. Jothimani, R. Venugopal, M.F. Abedin, I. Kaliamoorthy, M. Rela, COVID-19 and liver, *J. Hepatol.* (2020), <https://doi.org/10.1016/j.jhep.2020.06.006>.
- [26] Health Alert Network (HAN): Multisystem Inflammatory Syndrome in Children (MIS-C) Associated with Coronavirus Disease 2019 (COVID-19). <https://emergency-cdc.gov.foyer.swmed.edu/han/2020/han00432.asp>, 2020 (Accessed on May 15, 2020).
- [27] L. Jiang, K. Tang, M. Levin, O. Irfan, S.K. Morris, K. Wilson, J.D. Klein, Z.A. Bhutta, COVID-19 and multisystem inflammatory syndrome in children and adolescents, *Lancet Infect. Dis.* (2020) 1–3, [https://doi.org/10.1016/s1473-3099\(20\)30651-4](https://doi.org/10.1016/s1473-3099(20)30651-4).
- [28] V. Piechotta, C. Kl, V. Sj, C. Doree, I. Monsef, W. Em, A. Lamikanra, C. Kimber, Z. Mcquilten, E. Lj, N. Skoetz, V. Piechotta, C. Kl, V. Sj, C. Doree, I. Monsef, W. Em, A. Lamikanra, C. Kimber, Z. Mcquilten, E. Lj, N. Skoetz, With COVID-19: A Living Systematic Review (Review), 2020, <https://doi.org/10.1002/14651858.CD013600.pub3.Copyright>.
- [29] J.M. Díez, C. Romero, J. Vergara-Alert, M. Belló-Perez, J. Rodon, J.M. Honrubia, J. Segalés, I. Sola, L. Enjuanes, R. Gajardo, Cross-neutralization activity against SARS-CoV-2 is present in currently available intravenous immunoglobulins, *Immunotherapy* (2020), <https://doi.org/10.2217/imt-2020-0220>.