

# Unusual co-occurrence of cold agglutinin disease in a bladder transitional cell carcinoma patient with unexplained anemia and cold-related symptoms

Shuo Li<sup>1</sup>, Lu Zhang<sup>2</sup>, Wei Wang<sup>2</sup>

<sup>1</sup>Department of Plastic Surgery, Peking Union Medical College Hospital, Chinese Academy of Medical Sciences and Peking Union Medical College, Beijing 100730, China;

<sup>2</sup>Department of Hematology, Peking Union Medical College Hospital, Chinese Academy of Medical Sciences and Peking Union Medical College, Beijing 100730, China.

*To the Editor:* Anemia is a very common clinical scenario, which could be caused by various kinds of diseases. Though common, sometimes it could be exceedingly difficult to find out the underlying causes of anemia, especially for complicated cases. Herein, we reported a case of an old patient with a seemingly evident cause of anemia (hematuria), who was afterward diagnosed with a rare disease of cold agglutinin (CA) disease (CAD), which was confirmed to be the main etiology of his severe anemia.

In 2017, an 86-year-old man was referred to our hospital due to acrocyanosis, triggered by slight cold exposure, weakness, fatigue, and slight dyspnea for the past 5 years. He had a 15-year history of bladder carcinoma and had undergone local resection of the bladder tumor for three times, respectively in 2002, 2010, and 2012, due to the recurrence of the tumor. Transitional cell carcinoma of bladder was confirmed by the post-operative pathology. The patient manifested with hematuria recently. The cystoscope and ultrasonic examination of urogenital system showed a 2.4 cm × 2.5 cm × 3.1 cm lesion in the bladder, which highly suggested the recurrence of the tumor. Physical examination revealed anemic appearance and an operational scar at the lower abdomen. Yellowish skin or eyes, enlarged lymph nodes, hepatomegaly, and splenomegaly were not observed.

A blood routine test showed severe anemia with a hemoglobin (HGB) level of 58 g/L (normal reference range, 120–160 g/L), which not only raised safety concern for further surgery targeting the bladder tumor but could also not be explained by the extent of his hematuria. Inspired by the phenomenon that his symptoms exacerbated after cold exposure as well as the agglutination of his blood after the blood draw, further tests aiming to investigate the underlying reason of his anemia were

carried out. Further laboratory investigations indicated the following: elevated reticulocytes (RET%), 3.2% (normal reference range, 0.8%–2% of red blood cells [RBCs]); lactic dehydrogenase (LDH), 291 U/L (normal reference range, 135.0–215.0 U/L); free hemoglobin (FHb), 10.4 mg/dL (normal reference range, 0–5 mg/dL);  $\beta$ 2-microglobulin, 5 mg/L (normal reference range, 0.7–1.8 mg/L); complement C3, 0.511 g/L (normal reference range, 0.73–1.46 g/L); complement C4, 0.048 g/L (normal reference range, 0.1–0.4 g/L); direct Coombs test (+) for anti-C3 (+++); indirect antiglobulin Coombs test (–); CA tests (+): 4°C 1: 512, 25°C 1: 8, 37°C no agglutinin; autologous erythrocyte agglutination assay (–); elution test (–); urine protein (+); urine occult blood (+); blood film examination [Figure 1] showed strong agglutination of RBCs; bone marrow aspiration indicated erythroid hyperplasia and inverted ratio of granulocytes to erythrocytes: 0.85:1 (normal reference range, 1–5.2:1); bone marrow biopsy revealed some bone marrow and bone tissue of iliac bone, increased amount of hematopoietic tissue in bone marrow and decreased ratio of granulocytes to erythrocytes in hematopoietic tissue; immunoglobulin G (IgG) 13.08 g/L, IgA 2.15 g/L, and IgM 1.39 g/L were within normal reference range; antinuclear antibodies and antineutrophil cytoplasmic antibody (–); no obvious abnormal detections in serum protein electrophoresis and serum immunofixation electrophoresis. The patient did not undergo flow cytometry immunophenotypic analysis. Polymerase chain reaction (PCR) methods for clonal IgH rearrangement detects can be used to determine B-cell clonality, even when there is no obvious evidence of lymphoma invasion in early bone marrow and peripheral blood cells. The PCR detection of *IgH* gene rearrangement in the present case was negative, indicating that there was no sufficient evidence of B-cell malignancies. Autologous erythrocyte agglutination assay (–) excluded the possibili-

Access this article online

Quick Response Code:



Website:

www.cmj.org

DOI:

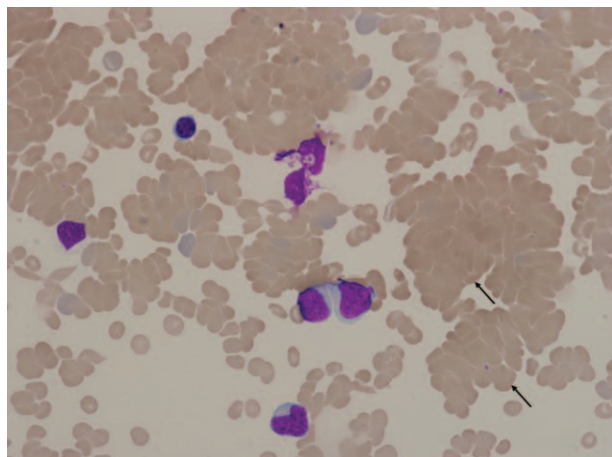
10.1097/CM9.0000000000001277

**Correspondence to:** Dr. Lu Zhang, Department of Hematology, Peking Union Medical College Hospital, Chinese Academy of Medical Sciences and Peking Union Medical College, Beijing 100730, China  
E-Mail: pumczhanglu@126.com

Copyright © 2021 The Chinese Medical Association, produced by Wolters Kluwer, Inc. under the CC-BY-NC-ND license. This is an open access article distributed under the terms of the Creative Commons Attribution-Non Commercial-No Derivatives License 4.0 (CCBY-NC-ND), where it is permissible to download and share the work provided it is properly cited. The work cannot be changed in any way or used commercially without permission from the journal.

Chinese Medical Journal 2021;134(5)

Received: 06-10-2020 Edited by: Qiang Shi and Peng Lyu



**Figure 1:** Blood film examination showed strong agglutination of red blood cells (hematoxylin-eosin staining, original magnification  $\times 200$ ).

ty of autoagglutination. Direct Coombs test (+) for anti-C3 (+++) and indirect antiglobulin Coombs test (–) indicated that the patient had autoimmune hemolytic anemia (AIHA). A diagnosis of CAD was made. In order to improve his HGB level, which could help the patient better tolerate further surgery, rituximab  $375 \text{ mg/m}^2$  weekly was administered for 4 weeks along with precautions for cold exposure. The patient's anemia and cold-induced circulatory symptoms have apparently alleviated, with laboratory values HGB  $92 \text{ g/L}$ , RET%  $2.89\%$ , and FHb  $4 \text{ mg/dL}$ , and no obvious erythroid hyperplasia shown in the bone marrow smear. Afterward, the patient underwent transurethral resection of bladder tumor successfully, and the pathology confirmed the recurrence of his bladder carcinoma. Post-operative outcome was uneventful. The patient was discharged after surgery and experiences no tumor recurrence or metastasis after a 3-year follow-up period.

CAD is a rare AIHA caused by antibodies (CA) that are of the IgM kappa immunoglobulin class in most cases and will agglutinate erythrocytes and lead to hemolysis through complement activation and fixation at  $0$  to  $4^\circ\text{C}$ . CAD is firmly diagnosed by chronic hemolysis (anemia, elevated RET%, LDH and bilirubin, abnormal RBC agglutination in the blood film examination, and erythroid hyperplasia shown by bone marrow aspiration), CA titer  $\geq 1:64$  at  $4^\circ\text{C}$ , and positive direct Coombs test (positive for complement protein C3d).<sup>[1]</sup> According to the earlier diagnosis criteria of CAD, the patient can be firmly diagnosed as bladder carcinoma and concomitant CAD.

CAD is a rare form of AIHA with a reported incidence rate of about  $1/1,000,000$  per year.<sup>[2]</sup> The occurrence of CAD can be divided as “primary” when the pathogenesis is unknown or as “secondary” to clonal B-cell lymphoproliferative bone marrow disorders, autoimmune, infectious diseases, or non-hematologic malignancies. However, it is exceedingly rare for CAD to occur with non-hematologic malignancies concomitantly. Until now, there are very few reports on the co-occurrence of CAD with solid tumors.<sup>[3]</sup> This is the first case with CAD possibly secondary to transitional cell carcinoma of bladder.

Although the occurrence of CAD secondary to non-hematologic malignancies is very rare, the association between them in the present case does not appear to be fortuitous. In the present case, the clinical onset of the tumor was before the presence of CA. Based on this fact, although the cold-agglutinin syndrome in the present case might be of the primary type, this patient was more likely to be cold-agglutinin syndrome secondary to bladder carcinoma.

The association between bladder carcinoma and CAD has been rarely explored and elaborated. It might be related with several mechanisms.<sup>[4]</sup> (1) Generally, the monoclonal antibody is produced by the tumor in cases of CAD in patients with lymphoma. The possibility still exists that the solid tumors including bladder carcinoma could be adequately dedifferentiated to produce enough antibodies. (2) The CAD secondary to non-hematologic malignancies might be caused by a generalized immunodeficiency state, including failure to control immunologic recognition and neoplastic growth. In conclusion, in patients with CAD, an occult non-hematologic malignancy should be considered.

Treatments for CAD include avoidance of cold exposure and rituximab<sup>[5]</sup>; splenectomy and corticosteroids are generally considered to be not effective. In the present case, the patient achieved a partial response after rituximab treatment and won an opportunity of surgical resection of his tumor. In conclusion, clinicians should be aware of the unusual co-occurrence of CAD in cancer patients with unexplained anemia and cold-related symptoms.

#### Declaration of patient consent

The authors certify that they have obtained the appropriate patient consent forms. In the form, the patient has given his consent for his images and other clinical information to be reported in the journal. The patient understand that his name and initials will not be published and due efforts will be made to conceal his identity.

#### Funding

This work was supported by the the National Natural Science Foundation of China (No.81900202) and Fundamental Research Funds for the Central Universities (No. 3332018036).

#### Conflicts of interest

None.

#### References

- Berentsen S, Beiske K, Tjønnfjord GE. Primary chronic cold agglutinin disease: an update on pathogenesis, clinical features and therapy. *Hematology* 2007;12:361–370. doi: 10.1080/10245330701445392.
- Janvier D, Lam Y, Galicier L, Bierling P. A new cold autoagglutinin specificity: the third external loop of band 3. *Transfusion* 2010;50:47–52. doi: 10.1111/j.1537-2995.2009.02383.x.
- Al-Matham K, Alabed I, Zaidi SZ, Qushmaq KA. Cold agglutinin disease in fibrolamellar hepatocellular carcinoma: a rare association with a rare cancer variant. *Ann Saudi Med* 2011;31:197–200. doi: 10.4103/0256-4947.76409.

4. Wortman J, Rosse W, Logue G. Cold agglutinin autoimmune hemolytic anemia in nonhematologic malignancies. *Am J Hematol* 1979;6:275–283. doi: 10.1002/ajh.2830060312.
5. Swiecicki PL, Hegerova LT, Gertz MA. Cold agglutinin disease. *Blood* 2013;122:1114–1121. doi: 10.1182/blood-2013-02-474437.

---

**How to cite this article:** Li S, Zhang L, Wang W. Unusual co-occurrence of cold agglutinin disease in a bladder transitional cell carcinoma patient with unexplained anemia and cold-related symptoms. *Chin Med J* 2021;134:608–610. doi: 10.1097/CM9.0000000000001277