

Sclerotic Bone Disease in a Male---A Harbinger of an Unsuspecting Malignancy?

Sir,

We describe a 40-year-old male, a driver by occupation who presented to the orthopedic department with mechanical back pain of 4 months duration with no prior trauma. He also reported unintentional and significant weight loss of about 10 kg in the last 6 months. Clinical examination was unremarkable. An X-ray of the spine was done, on which the vertebrae appeared to be sclerotic, and this was subsequently confirmed on a dual energy X-ray Absorptiometry Scan (Z score of 6.8 at lumbar spine) [Figure 1a and b]. In the presence of severe sclerotic bone disease of recent onset in an adult male, the possibilities of renal osteodystrophy, renal tubular acidosis, Paget's disease of bone and sclerotic metastasis due to an underlying malignancy were considered.

His biochemical evaluation showed a haemoglobin of 8.9 (N: 13–16 g/dL), albumin corrected calcium of 8.8 (N: 8.3–10.4 mg/dL), phosphate of 3.1 (N: 2.5–4.5 mg/dL), total alkaline phosphatase of 1576 (N: 40–125 U/L), 25 hydroxy vitamin D of 70.7 (N: 30–70 ng/mL), and PTH of 78 (N: 18.4 to 80.1 pg/mL). His electrolytes and renal function tests were normal, thereby ruling out the possibility of renal osteodystrophy. Liver function tests were also within normal limits. Further, his bone resorption marker C-terminal telopeptide of type 1 collagen was 6,000 (N: 142–584 pg/mL), and bone formation marker, pro-collagen Type-1 N-terminal

propeptide was 1,200 (N: 15–63 ng/ml) which was suggestive of a high bone turnover state. This was followed by a technetium- 99 m MDP bone scintigraphic scan which showed irregular increased tracer activity in the skull, clavicle, sternum, scapulae, humeri, multiple ribs, vertebrae, pelvic bones and femorii suggestive of a metastatic disease. Upon further evaluation, his prostate specific antigen was found to be markedly elevated [791.84 (0–4 ng/mL)], and biopsy of the prostate demonstrated acinar adenocarcinoma with a Gleason score of 8. What was perturbing was that this patient had not presented with typical lower urinary tract symptoms which might otherwise have led us to suspect prostate as the primary site of malignancy. Globally, prostate cancer is the second most frequent malignancy (after lung cancer) encountered in men.

The incidence and mortality of prostate cancer correlate with increasing age and the average age at diagnosis is 66 years. The incidence of prostate cancer in men below 50 years is 1 in 350.^[1] Malignant cells from the prostate promote osteolytic and osteoblastic activity through production of osteoblastic and osteolytic factors. Osteoblastic activity is promoted by bone morphogenetic proteins, endothelin-1, PSA, and parathyroid hormone-related protein. The receptor activator of nuclear factor kappa-B ligand (RANKL) and its receptor (RANK) signalling promote osteoclastic activity. Osteoprotegerin (OPG) binds to RANKL and prevents it from binding to its receptor, RANK thereby promoting sclerosis. The prostate specific antigen (PSA) has a major role in causing the osteoblastic bone lesions by promoting the proliferation of osteoblasts and apoptosis of osteoclasts.^[2] Treatment with GnRH analogues could result in significant relief in these patients though overall therapeutic intent is palliative in nature.

Thus, the detection of sclerotic bones even in a young male warrants thorough evaluation as it might occasionally be a harbinger of an unsuspecting malignancy – in this case of a metastatic prostate cancer.

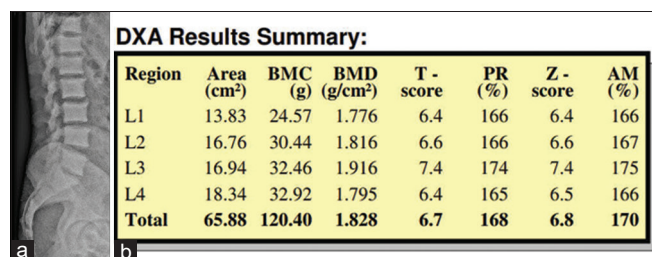


Figure 1: (a) Plain X Ray of the Lumbar spine lateral view. (b) DXA Scan of the Lumbar Spine

Financial support and sponsorship

Nil.

Conflicts of interest

There are no conflicts of interest.

Antresa Jose, Kripa Elizabeth Cherian, Nitin Kapoor, Thomas V. Paul

Department of Endocrinology, Diabetes and Metabolism, Christian Medical College, Vellore, Tamil Nadu, India


Address for correspondence: Dr. Nitin Kapoor,
Department of Endocrinology, Christian Medical College,
Vellore, Tamil Nadu, India.
E-mail: nitin.cmcvellore@gmail.com

REFERENCES

1. Perdana NR, Mochtar CA, Umbas R, Hamid AR. The risk factors of prostate cancer and its prevention: A literature review. *Acta Med Indones* 2016;48:228–38.
2. Segamwenge IL, Mgori NK, Abdallahyussuf S, Mukulu CN, Nakangombe P, Ngalyuka PK, *et al.* Cancer of the prostate presenting with diffuse osteolytic metastatic bone lesions: A case report. *J Med Case Rep* 2012;6:425.

Submitted: 03-Oct-2021**Published:** 17-Feb-2022**Accepted:** 28-Nov-2021

This is an open access journal, and articles are distributed under the terms of the Creative Commons Attribution-NonCommercial-ShareAlike 4.0 License, which allows others to remix, tweak, and build upon the work non-commercially, as long as appropriate credit is given and the new creations are licensed under the identical terms.

Access this article online	
Quick Response Code: 	Website: www.ijem.in
	DOI: 10.4103/ijem.ijem_433_21

How to cite this article: Jose A, Cherian KE, Kapoor N, Paul TV. Sclerotic bone disease in a male---A harbinger of an unsuspecting malignancy? *Indian J Endocr Metab* 2021;25:575-6.

© 2022 Indian Journal of Endocrinology and Metabolism | Published by Wolters Kluwer - Medknow