

Original Article

Description of a new approach for great auricular and auriculotemporal nerve blocks: A cadaveric study in foxes and dogs

Thaleia- Rengina Stathopoulou* , Rui Pinelas[†], Gert Ter Haar[‡], Ine Cornelis[§] and Jaime Viscasillas*

*Department of Clinical Science and Services, Royal Veterinary College, University of London, North Mymms, Hertfordshire, United Kingdom, [†]North Downs Specialist Referrals, 3 & 4 The Brewerstreet Dairy Business Park, Redhill, United Kingdom, [‡]Anicura, Medisch Centrum voor Dieren, Amsterdam, Netherlands and [§]Department of Medicine and clinical biology of small animals, University of Ghent, Merelbeke, Belgium

Abstract

Otitis externa is a painful condition that may require surgical intervention in dogs. A balanced analgesia protocol should combine systemic analgesic agents and local anaesthesia techniques. The aim of the study was to find anatomical landmarks for the great auricular and the auriculotemporal nerves that transmit nociceptive information from the ear pinna and to develop the optimal technique for a nerve block. The study consisted of two phases. In phase I, one fox cadaver was used for dissection and anatomical localization of the auricular nerves to derive landmarks for needle insertion. Eight fox cadavers were subsequently used to evaluate the accuracy of the technique by injecting methylene blue bilaterally. In phase II findings from phase I were applied in four Beagle canine cadavers. A block was deemed successful if more than 0.6 cm of the nerve's length was stained. Successful great auricular nerve block was achieved by inserting the needle superficially along the wing of the atlas with the needle pointing towards the jugular groove. For the auriculotemporal nerve block the needle was inserted perpendicular to the skin at the caudal lateral border of the zygomatic arch, close to the temporal process. The overall success rate was 24 out of 24 (100%) and 22 out of 24 (91%) for the great auricular and the auriculotemporal nerves, respectively, while the facial nerve was stained on three occasions. Our results suggest that it is feasible to achieve a block of the auricular nerves, based on anatomical landmarks, without concurrently affecting the facial nerve.

Keywords: cadaveric study, auricular nerves, canine.

Correspondence: Thaleia- Rengina Stathopoulou, Department of Clinical Science and Services, Royal Veterinary College, University of London, North Mymms, Hertfordshire, United Kingdom. E-mail: tsthathopoulou@rvc.ac.uk

Introduction

Chronic otitis externa in dogs is a painful and debilitating condition that requires long-term medical treatment at best, but can often be treated permanently only with surgical intervention. Total ear canal ablation (TECA) in combination with lateral bulla osteotomy (LBO) is the most commonly performed surgical procedure for treatment of chronic otitis externa in veterinary medicine (Mason *et al.* 1988; Beckman *et al.* 1990) that requires effective pain control. Over the last decades, the understanding of the pathophysiological mechanism of pain

and tissue damage has introduced the concept of balanced analgesia, to improve the analgesic outcome and reduce the adverse effects related to opioids (Kehlet *et al.* 1999). Dogs receiving primary analgesia with opioids frequently develop breakthrough pain or complications related to their use (dysphoria, inappetence, upper airway distress) that highlights the importance of introducing an effective local anaesthesia technique (Buback *et al.* 1996).

Two nerves, the great auricular (*auricularis magnus*) and the auriculotemporal nerve (*auriculotemporalis*) have been recognized to provide sensory

innervation in the ear canal and pinna. Previous studies evaluating the effectiveness of local anaesthesia techniques for TECA–LBO procedures did not show a significant difference in pain scores and quality of recovery compared with systemic analgesics (Buback *et al.* 1996; Radlinsky *et al.* 2005; Wolfe *et al.* 2006). However, the local anaesthesia technique and the ability to localize the relevant nerves could influence the success of a nerve block and its potential analgesic effect. In addition, facial nerve dysfunction has been reported in 13–46% of dogs undergoing TECA-LBO surgery, with a median duration of 2 weeks (range 2 days to 13 weeks) (Spivack *et al.* 2013). Apart from reasons related to the actual surgical procedure, it might be a complication of the previously described approach to the auriculotemporal nerve block due to its proximity to the facial nerve (Duke-Novakovski 2016). There is no evidence regarding the facial nerve dysfunction that is specifically caused by the nerve block.

The aim of this cadaveric study was to find anatomical landmarks for identification of the great auricular and the auriculotemporal nerves in order to develop both an effective and safe technique for local nerve block. Our hypothesis is that by utilizing specific landmarks to locate the aforementioned nerves, it will lead to their perineural infiltration without affecting the facial nerve.

Materials and methods

The study was approved by the Clinical Research Ethical Review Board (CRERB) of the Royal Veterinary College (authorization number: URN 2015-1333)

The study was conducted in two phases. Phase I involved the development and evaluation of the technique in fox cadavers and phase II the application of the technique in canine cadavers.

Phase I

Nine red fox cadavers (*Vulpes vulpes*) that were euthanized for reasons not related to this study were included. Euthanasia was performed in a humane manner.

One of the fox cadavers was used for dissection and visual identification of the great auricular and the auriculotemporal nerves.

For the great auricular nerve, the cadaver was placed in lateral recumbency. After palpating the wing of the atlas vertebra, a skin incision was made at the caudoventral border of the atlas and along the transverse process. The skin was reflected and the fascia dissected to expose the second cervical spinal nerve located deep in the platysma muscle, parallel to the jugular groove. The great auricular nerve was found to leave the cervical nerve at the dorsal level of sternocleidomastoid muscle and to continue over the lateral surface of this muscle, running between the intermediate and the peripheral auricular arteries (Fig. 1). At the base of the ear pinna it divided in two branches, the cranial and caudal branch. The cranial branch coursed towards the apex of the ear, covering the convex area of the pinna up to its lateral border and the caudal branch that provided cutaneous innervation for the skin over the parotid area. The nerve was identified and photographed.

The dissection of the auriculotemporal nerve, again in lateral recumbency, involved a skin incision in a craniocaudal direction, starting below the zygomatic arch and towards the external ear canal. The masseter muscle was cut and reflected. The auriculotemporal nerve constitutes a branch of the trigeminal nerve and it was found to separate from the

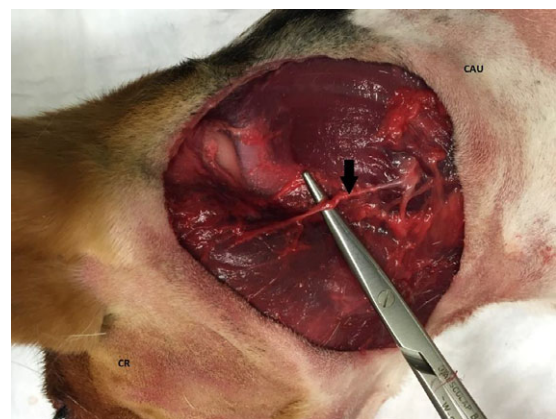


Fig. 1. Beagle canine cadaver in right lateral recumbency. Arrow pointing to the great auricular nerve, CR cranial and CAU caudal of the canine cadaver.

mandibular nerve at the oval foramen and to continue to the caudal border of the pterygoid muscle, with a short common trunk close to the medial aspect of the temporomandibular joint (TMJ) and then separate in branches. The branches were running lateral and medial in relation with the meningeal artery and they were found to innervate the tympanic membrane, the medioventral part of the pinna, as well as the skin over the zygomatic arch and ventral part of the temporalis muscle (Evans & De Lahunta 2013). The auriculotemporal nerve was identified and photographed as it emerged between the masseter muscle and the base of the auricular cartilage (Fig. 2). The facial nerve was also identified and photographed.

Based on the above anatomical landmarks the following approach was used to achieve the great auricular nerve block bilaterally in eight fox cadavers: after palpating the transverse process of the atlas, a 22G, 90 mm spinal needle (Becton Dickinson S.A. Spain) was inserted superficially for 0.3 cm aiming for the deep fascia of the subcutaneous tissue, at the level of the transverse process of the atlas, pointing ventrally towards the jugular groove for insertion of the first depot of dye. The spinal needle was then repositioned twice alongside the transverse process

to cover its entire length, depositing three depots of equal volume from caudal to cranial. (Figs. 3,4)

Access to the auriculotemporal nerve was achieved after palpating the area overlying the TMJ with the cadavers in lateral recumbency. A 22G, 90 mm spinal needle (Becton Dickinson S.A. Spain) was inserted perpendicular to the skin at the caudolateral border of the zygomatic arch and close to the temporal process for 1–3 cm depending on the size of the animal. The needle was oriented towards the TMJ and held in constant contact with the zygomatic arch at the level of the masseteric margin during the insertion (Figs 5,6).

Methylene blue dye (Methylene Blue 1%, ReAgent Chemicals, UK) was used for the completion of the nerve blocks. The volume of methylene blue used was 0.04 mL kg^{-1} for the auriculotemporal nerve and 0.2 mL kg^{-1} for the great auricular nerve and they were performed bilaterally by the same investigator (X).

After injection of the dye bilaterally all fox cadavers were dissected by two other investigators (X, X) to determine the effectiveness of the technique and length of the nerve stained. Nerves were dissected and photographed. The injection was deemed successful if the respective nerves were stained over a length of 0.6 cm (Raymond *et al.* 1989). Any degree

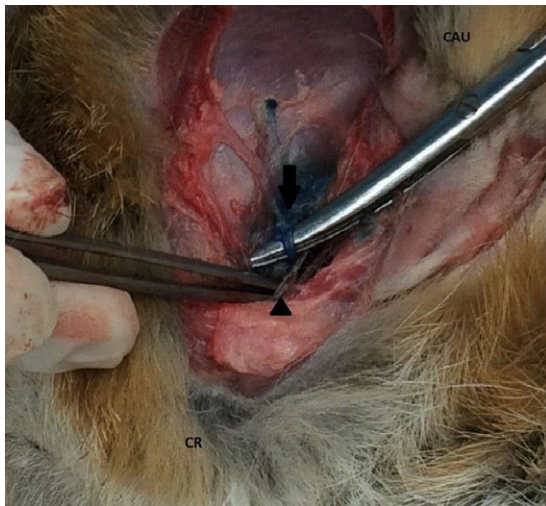


Fig. 2. Fox cadaver in right lateral recumbency: Arrow pointing to the auriculotemporal nerve and arrow head pointing to the facial nerve. CR cranial and CAU caudal of the cadaver.

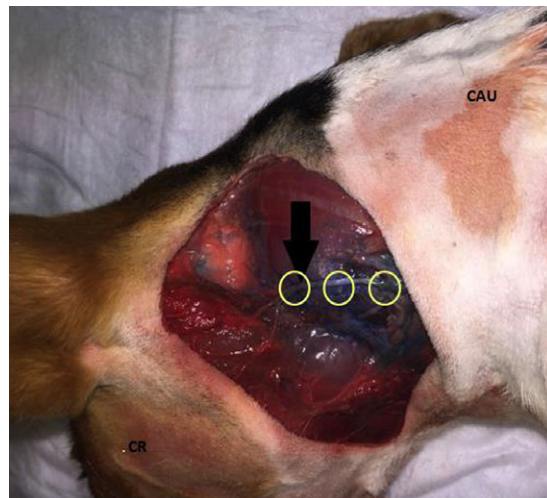

Fig. 3. Beagle canine cadaver in right recumbency: arrow pointing to the great auricular nerve after performing the nerve block with methylene blue and three circles indicating the points for methylene blue depots. CR for cranial and CAU for caudal of the canine cadaver.

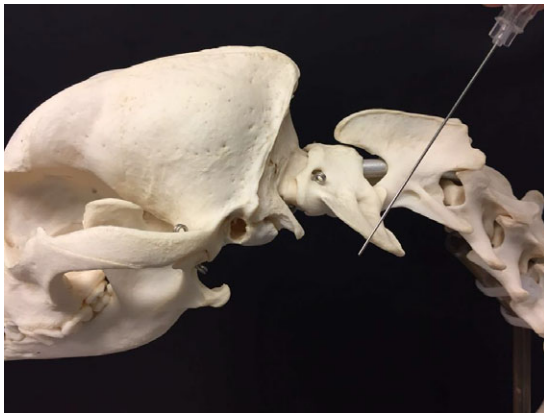


Fig. 4. Canine skull with spinal needle indicating the needle's position for the great auricular nerve block.

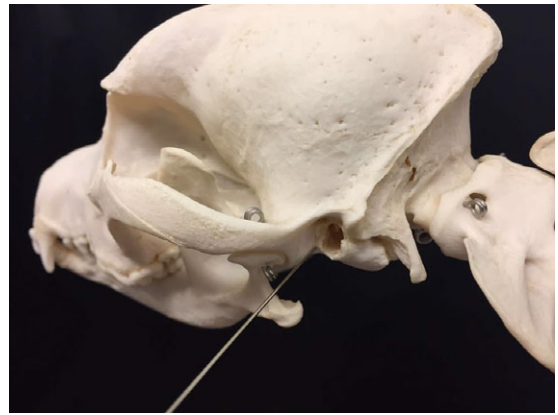


Fig. 6. Canine skull with spinal needle indicating the needle's position for the auriculotemporal nerve block.

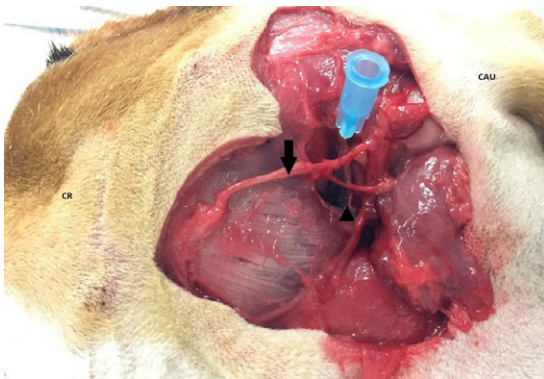


Fig. 5. Canine cadaver in right recumbency. Needle indicative of the direction for performing the local block. Facial nerve pointed with arrow and auriculotemporal nerve with arrow head. CR for cranial and CAU for caudal of the canine cadaver.

of staining of the facial nerve was recorded as a complication. The results were reported as number and percentage (n/n, %).

Phase II

Four Beagle canine cadavers that were euthanized for reasons not related to the study were included. According to the anatomical landmarks developed in phase I, the technique was reproduced in the canine cadavers to compare the anatomy, the volumes of dye utilised and the potential complications. The great auricular and auriculotemporal nerve blocks were performed bilaterally as in phase I by the same

investigator, dissected, photographed and the length of staining was assessed as described above by the same operators as in phase I. The block was again deemed successful if the respective nerve was stained over a length of 0.6 cm. Any degree of staining of the facial nerve was recorded as a complication. The results were reported as number and percentage (n/n, %).

Results

Results from phase I and II are summarized in Table 1.

Using the method described on the right and left side in all cadavers, more than 0.6 cm of the great auricular nerve was found to be dyed in 24 out of 24 (100%) of the cases when using 0.2 mL kg^{-1} of methylene blue. Though intravascular injection as result of pointing the needle towards the jugular groove was identified as a potential complication no such incidents were identified during the study. The overall success rate of the auriculotemporal nerve staining was 22 out of 24 (91%). The facial nerve was found stained in three instances, in two of which the auriculotemporal nerve was not stained and in the third case both nerves were found stained but the facial nerve less than 0.6 cm.

Discussion

Our anatomical study allowed us to implement some alterations in the technique for the great auricular

Table 1. Summative results of the cadaveric study in fox and canine cadavers

Species, number, side	Auriculotemporal <i>n</i>	Great auricular <i>n</i>	Facial <i>n</i>
Fox			
1L	Yes	Yes	No
1R	Yes	Yes	No
2L	Yes	Yes	No
2R	No	Yes	Yes
3L	Yes	Yes	No
3R	Yes	Yes	No
4L	Yes	Yes	No
4R	Yes	Yes	Yes
5L	Yes	Yes	No
5R	Yes	Yes	No
6L	Yes	Yes	No
6R	Yes	Yes	No
7L	No	Yes	Yes
7R	Yes	Yes	No
8L	Yes	Yes	No
8R	Yes	Yes	No
	14/16 (88%)	16/16 (100%)	0/16
Canine			
1L	Yes	Yes	No
1R	Yes	Yes	No
2L	Yes	Yes	No
2R	Yes	Yes	No
3L	Yes	Yes	No
3R	Yes	Yes	No
4L	Yes	Yes	No
4R	Yes	Yes	No
	8/8 (100%)	8/8 (100%)	0/8

The block was done bilaterally on left (L) and right side (R). A block was deemed successful (yes) when >0.6 cm of its length was stained with methylene blue and not successful (no) when not stained or >0.6 cm.

and the auriculotemporal nerve blocks compared with previously described techniques. Landmarks described for the great auricular block in the veterinary literature (Duke-Novakovski 2016; Martínez 2016) so far have relied upon palpating either the hyoid bone from the larynx in thinner animals or the area defined ventrally by the wing of atlas and caudally by the tympanic bulla. The local anaesthetic would be subsequently injected rostrally to the above sites after palpation of the vertical ear canal or parallel to the transverse process of the atlas. In contrast, we injected the methylene blue relatively superficially aiming for the deep fascia of the subcutaneous tissue along the wing of the atlas with the needle pointing towards the jugular groove. Repositioning

of the needle is necessary depending on the size of the animal to cover the entire length of the transverse process of the atlas. Using this technique, the great auricular nerve is blocked before it divides into branches, potentially leading to better quality analgesia as a wider area of sensory innervation is likely to be covered.

Previously described techniques for the auriculotemporal nerve block involved the injection of the local anaesthetic just rostral to the vertical ear canal (Duke-Novakovski 2016; Lerche *et al.* 2016). In the presented study, the auriculotemporal nerve is described in reference to the TMJ. The close anatomic relationship between the TMJ and the auriculotemporal nerve was previously described in human literature (Schmidt *et al.* 1998) with the latter being associated with cases of pain and numbness in the TMJ area; the above is not proven to occur in the dog and the anatomical differences among species should be considered. In this study, the auriculotemporal nerve was in close anatomical relationship with the TMJ in all cadavers.

Facial nerve paresis or paralysis is identified as a major complication of the TECA-LBO procedure (Spivack *et al.* 2013); additionally, facial nerve deficits have also been reported as a potential complication of auricular nerve blocks (Duke-Novakovski 2016; Lerche *et al.* 2016). In our study the facial nerve was dyed in three occasions; although considered a complication in our study, the length of nerve staining was consistently less than 0.6 cm, which is considered not to be sufficient level to produce clinical blockade (Raymond *et al.* 1989).

The present study was not without limitations. The study was performed in fox cadavers and the results were compared with four canine cadavers to confirm the anatomical landmarks and the application of the technique. Red foxes (*Vulpes vulpes*) belong to the sub-family of Canidae (Fox 1969) and they were used for the anatomical study due to cadaver availability and comparable anatomy with the dogs. Our findings were applied later in the four Beagle canine cadavers with the same results, which confirmed our hypothesis for comparable anatomy between foxes and the specific canine breed. Possible breed variations cannot however be excluded given the disparity in size and skull

anatomy in different dog breeds. Also, the previously described central projection of the auricular branches of the vagus nerve (Chien *et al.* 1996) was not identified in the present anatomical study; it was assumed that the great auricular and auriculotemporal nerve blocks were sufficient to provide additional analgesia for the TECA-LBO procedures. In addition, as the great auricular and the auriculotemporal blocks are based on external landmarks there is an expected degree of variability despite the effort to diminish that, by having the same investigator performing the blocks. The length of staining that was accepted as adequate to produce clinical effect was based on previous cadaveric studies (Raymond *et al.* 1989) and as such, to ensure that adequate analgesia is achieved, further clinical evaluation is needed.

Conclusion

Our study described a new approach for the great auricular and auriculotemporal nerve blocks based on anatomical landmarks which led to adequate staining of the great auricular and the auriculotemporal nerves by rarely affecting the facial nerve. Further clinical studies are needed to evaluate the application and the potential benefit of this technique in dogs undergoing TECA-LBO surgical procedures.

Acknowledgement

There are no acknowledgements to declare.

Source of funding

There were no external sources of funding for the completion of this study.

Conflict of Interest

The authors declare no conflicts of interest.

Ethical statement

The authors confirm that the ethical policies of the journal, as noted on the journal's author guidelines

page, have been adhered to and the appropriate ethical review committee approval has been received.

Contributions

There are no contributions to declare.

References

- Beckman S.L., Henry W.B. Jr & Cechner P. (1990) Total ear canal ablation combining bulla osteotomy and curettage in dogs with chronic otitis externa and media. *Journal of the American Veterinary Medical Association* **196**, 84–90.
- Buback J.L., Boothe H.W., Carroll G.L. & Green R.W. (1996) Comparison of three methods for relief of pain after ear canal ablation in dogs. *Veterinary Surgery* **25**, 380–385.
- Chien C.-H., Shieh J.-Y., Ling E.-A., Tan C.-K. & Wen C.-Y. (1996) The composition and central projections of the internal auricular nerves of the dog. *Journal of Anatomy* **189**(Pt 2), 349.
- Duke-Novakovski T. (2016) Pain Management II: Local and regional anaesthetic techniques. In: *BSAVA Manual of Canine and Feline Anaesthesia and Analgesia*. (eds Duke-Novakovski T, De Vries M, Seymour C), 2nd edn, pp 148–150. BSAVA: Gloucester, United Kingdom.
- Evans HE, De Lahunta A. (2013). *Miller's Anatomy of the Dog*. Elsevier Health Sciences: Missouri, United States.
- Fox M.W. (1969) The anatomy of aggression and its ritualization in Canidae: a developmental and comparative study. *Behaviour* **35**, 242–258.
- Kehlet H., Werner M. & Perkins F. (1999) Balanced analgesia. *Drugs* **58**, 793–797.
- Martínez F. (2016) Blocks of the head. In: *Handbook of Small Animal Regional Anesthesia and Analgesia Techniques*, 48–51. (eds P. Lercher, T. Aarnes, G. Covey-Crump & F. Martinez), WileyBlackwell.
- Mason L., Harvey C.E. & Orsher R.J. (1988) Total Ear Canal Ablation Combined with Lateral Bulla Osteotomy for End-Stage Otitis in Dogs Results in Thirty Dogs. *Veterinary Surgery* **17**, 263–268.
- Radlinsky M.G., Mason D.E., Roush J.K. & Pineda R. (2005) Use of a continuous, local infusion of bupivacaine for postoperative analgesia in dogs undergoing total ear canal ablation. *Journal of the American Veterinary Medical Association* **227**, 414–419.
- Raymond S.A., Steffensen S.C., Gugino L.D. & Strichartz G.R. (1989) The role of length of nerve exposed to local anesthetics in impulse blocking action. *Anesthesia and Analgesia* **68**, 563–570.

- Schmidt B.L., Pogrel M.A., Necoechea M. & Kearns G. (1998) The distribution of the auriculotemporal nerve around the temporomandibular joint. *Oral Surgery, Oral Medicine, Oral Pathology Oral Radiology and Endodontology* **86**, 165–168.
- Spivack R.E., Elkins A.D., Moore G.E. & Lantz G.C. (2013) Postoperative complications following TECA-LBO in the dog and cat. *Journal of the American Animal Hospital Association* **49**, 160–168.
- Wolfe T.M., Bateman S.W., Cole L.K. & Smeak D.D. (2006) Evaluation of a local anesthetic delivery system for the postoperative analgesic management of canine total ear canal ablation—a randomized, controlled, double-blinded study. *Veterinary Anaesthesia and Analgesia* **33**, 328–339.