

A new promising oncogenic target (p.C382R) for treatment with pemigatinib in patients with cholangiocarcinoma

Louisa Hempel¹, Constantin Lapa, Alexander Dierks, Andreas Gaumann, Josef Scheiber, Julia Veloso de Oliveira, Patrick Philipp², Cristina Oyarzun Laura, Stefan Wesarg, Sebastian Robert and Dirk Hempel

Ther Adv Med Oncol

2022, Vol. 14: 1–11

DOI: 10.1177/
17588359221125096

© The Author(s), 2022.
Article reuse guidelines:
sagepub.com/journals-
permissions

Abstract: Point mutations of the fibroblast growth factor receptor (FGFR)2 receptor in intrahepatic cholangiocarcinoma (iCC) are mainly of unknown functional significance compared to FGFR2 fusions. Pemigatinib, a tyrosine kinase inhibitor, is approved for the treatment of cholangiocarcinoma with FGFR2 fusion/rearrangement. Although it is hypothesized that FGFR2 mutations may cause uncontrolled activation of the signaling pathway, the data for targeted therapies for FGFR2 mutations remain unclear. *In vitro* analyses demonstrated the importance of the p.C382R mutation for ligand-independent constitutive activation of FGFR2 with transforming potential. The following report describes the clinical case of a patient diagnosed with an iCC carrying a FGFR2 p.C382R point mutation which was detected in liquid, as well as in tissue-based biopsies. The patient was treated with pemigatinib, resulting in a sustained complete functional remission in fluorodeoxyglucose-positron emission tomography/computed tomography over 10 months to date. The reported case is the first description of a complete functional remission under the treatment with pemigatinib in a patient with p.C383R mutation.

Keywords: cholangiocarcinoma, FGFR2, mixed-all-nominated-in-one method, next-generation sequencing, targeted therapy, tyrosine kinase inhibitor

Received: 8 May 2022; revised manuscript accepted: 22 August 2022.

Introduction

Cholangiocarcinoma (CCA) accounts for 3% of upper gastrointestinal carcinomas.¹ The prognosis of the disease is poor, as most patients are diagnosed in an unresectable late stage. Clinically, extrahepatic CCA, which includes perihilar CCA and distal CCA is distinguished from intrahepatic CCA (iCC), which can be characterized by a different molecular profile and clinical presentation. With the increasing efforts of molecular diagnostics in the context of personalized medicine, CCAs could be further classified. It was shown that oncogenic and targetable gene alterations occur in about 50% of CCAs.² Alterations in IDH1 and fibroblast growth factor receptor (FGFR)2 genes are found nearly exclusively in iCC.¹

Based on findings of the FIGHT 202 trial, pemigatinib was recently approved in the United States and Europe for the treatment of patients with FGFR2 fusions and rearrangements.^{3,4}

The FGFR belongs to the tyrosine kinase family and is a single-pass membrane protein consisting of three N-terminal immunoglobulin-like extracellular domains (D1–3), a transmembrane alpha helix domain and an intracellular tyrosine kinase domain (Figure 1).⁵ Ligand binding of the fibroblast growth factor and a cofactor (heparin) is required for dimerization of FGFR and thus the activation of the receptor interaction.^{6,7} Ligand binding to FGFR2 triggers the dimerization of the receptor and results in a tight conjunction of both transmembrane alpha helices followed by an

Correspondence to:

Louisa Hempel
Medical School, Sigmund
Freud University,
Freudplatz 3, Vienna 1020,
Austria
louisa.hempel@med.sfu.ac.at

Constantin Lapa
Alexander Dierks
University Hospital
Augsburg, Department
of Nuclear Medicine,
Augsburg, Germany

Andreas Gaumann
Molekularpathologie
Suedbayern, Kaufbeuren,
Germany

Josef Scheiber
BioVariance GmbH,
Waldsassen, Germany

Julia Veloso de Oliveira
Patrick Philipp
Fraunhofer Institute
of Optics, System
Technologies and Image
Exploitation IOSB,
Karlsruhe, Germany

Cristina Oyarzun Laura
Stefan Wesarg
Fraunhofer Institute
for Computer Graphics
Research IGD, Darmstadt,
Germany

Sebastian Robert
Rosenheim Technical
University of Applied
Sciences, Rosenheim,
Germany

Dirk Hempel
Institute of Translational
Molecular Tumor
Research, Freising,
Germany

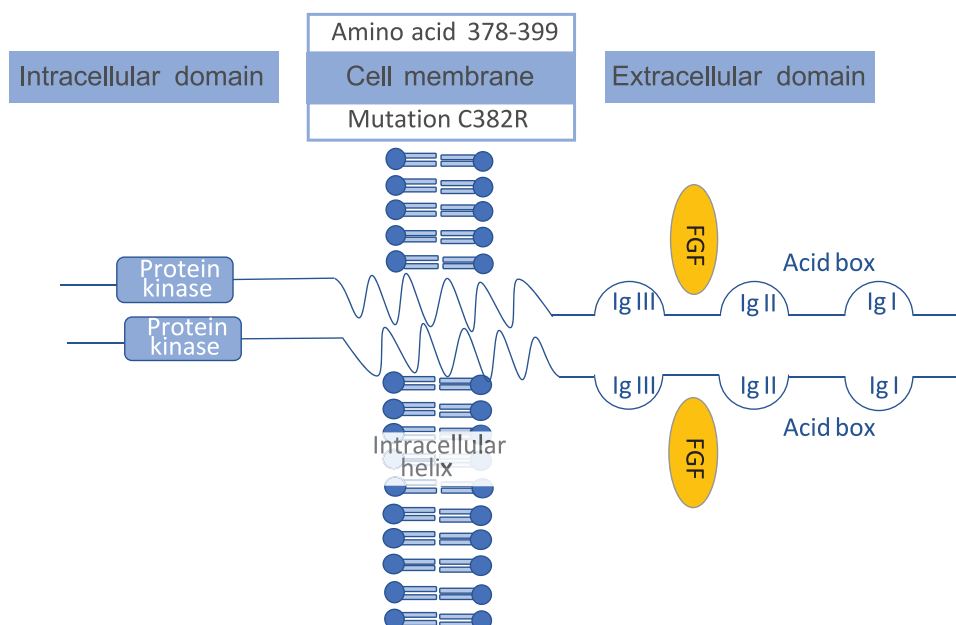


Figure 1. Structure of FGFR2: three extracellular N-terminal immunoglobulin-like extracellular domains (Ig I–III), a transmembrane alpha helix domain, and an intracellular tyrosine kinase domain. FGFR, fibroblast growth factor receptor.

activation of the intracellular protein kinase domain. This results in the autophosphorylation of the receptor. Subsequently, downstream pathways are activated (phospholipase C cascade and phospholipase C γ , RAS-RAF-MAPK, and PI3K-AKT-mTOR) resulting in proliferation, activation, and transforming signals.⁸ PTEN is the main inhibitor of AKT in the PI3K-AKT-mTOR pathway (Figure 2).^{8,9}

In the case of FGFR2 fusion/rearrangement, ligand-independent continuous receptor activation occurs with a sustained proliferation signal to the cell.⁷ The FGFR2 has a gatekeeper function at location V564. After the binding of pemigatinib N549, K641 and E565 form a hydrogen bond with an inactivating conformation of the activation loop. K659 is essential for stabilizing this inactivating conformation.¹ Pemigatinib can inhibit both wild-type receptor and ligand-independent activations of FGFR2 by receptor fusion/rearrangement. In contrast, there are only few data available on the functional relevance of FGFR2 mutations.

An *in vitro* study from 1997 shows that the p.C382R mutation leads to ligand-independent, constitutive activation of the intracellular tyrosine kinase. It was hypothesized that the point mutation

results in a permanent tight junction of intracellular alpha helices with subsequent ligand-independent activation of receptor and downstream pathways (Figure 3).¹⁰ Moreover, it was reported that the mutation as such is oncogenic.¹¹

Clinical case

A 74-year-old male was diagnosed with an advanced iCC of both liver lobes and pulmonary metastases (Figures 5 and 6). First-line chemotherapy with gemcitabine 800 mg/m², cisplatin 25 mg/m², and nab-paclitaxel 100 mg/m² days 1 and 8 qd22 was initiated. After the fifth treatment cycle, progressive disease was observed. Biopsies of the liver lesions as well as a liquid biopsy were taken and a hybrid capture-based next-generation sequencing (NGS; FoundationOne CDx, Penzberg, Germany) was performed for the tissue biopsies and FoundationOne Liquide CDx for the blood samples.⁹ The test is based on the examination of 324 genes as well as introns of 34 genes known to be involved in rearrangements. In addition, tumor mutation burden and microsatellite instability were evaluated.^{12–14} Sequencing revealed a p.C382R mutation located in the transmembrane receptor domain. The p.C382R was detected in both specimens with a variant allele frequency of 76.48% in the tissue biopsy

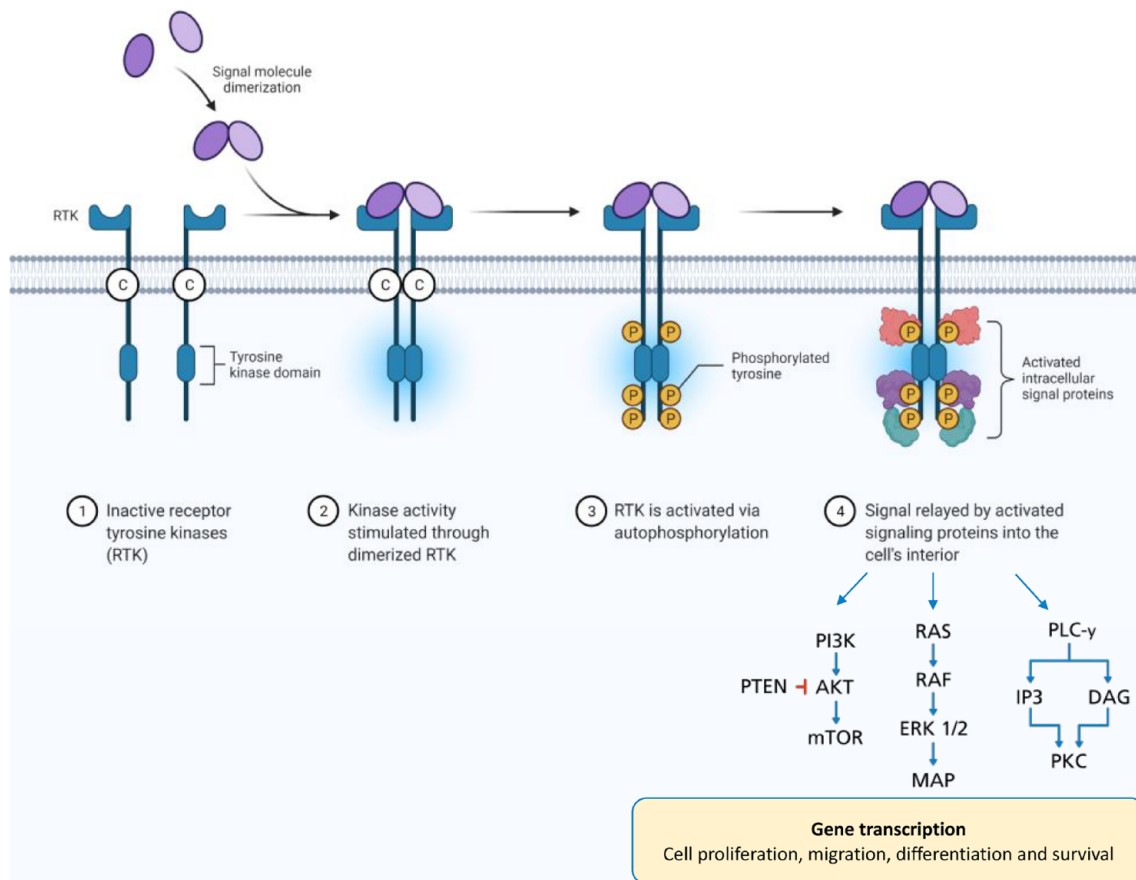


Figure 2. Regulation of FGFR2 after ligand binding and subsequent activation of intracellular pathways. The FGFR2 protein receptor consists of an extracellular domain responsible for ligand binding (FGF), a transmembrane alpha helix, and an intracellular tyrosinase domain. Ligand binding of FGF to FGFR2 results in dimerization of the two homologous protein chains of the receptor. This leads to close contact of the two intracellular alpha helix domains, followed by activation of the intracellular tyrosine kinase. The resulting autophosphorylation of FGFR2 subsequently leads to the activation of downstream signaling pathways (PI3K, RAS, and PLC-gamma) with effects on cell proliferation, cell differentiation, and cell survival.⁹ FGFR, fibroblast growth factor receptor.

and 8.1% in the blood sample. Regarding downstream signaling pathways, we detected a PTEN alteration (loss of exons 7–9 in tissue samples and loss of exons 3–8 in the liquid biopsy). The sequencing results are shown in Table 1. The results of the histologic examination are shown in Figure 4.

Furthermore, we performed an *in silico* study to understand the potential mode of p.C382R action. To modulate and visualize the protein structure results from p.C382R, we used AlphaFold2 (<https://alphafold.ebi.ac.uk/entry/P21802>). The evaluation revealed that the p.C382R mutation is located in the transmembrane domain at a position that is crucial for the oncogenic tyrosine kinase activation but does not interfere with the

binding ability and inhibition of autophosphorylation of FGFR by pemigatinib.

Following the promising *in vitro* data for pemigatinib-targeted treatment and the reported results of three patients carrying FGFR2 p.C382R mutations who were treated with pemigatinib in the FIGHT 202 trial, we decided to initiate therapy after a discussion of the clinical case in the molecular tumor board (MTB).¹⁰

Pemigatinib of 13.5 mg was administered once daily for 14 days, followed by 7 days of therapy-free interval. The treatment outcome was evaluated by magnetic resonance imaging (MRI) and fluorodeoxyglucose-positron emission tomography/computed tomography (FDG-PET/CT)

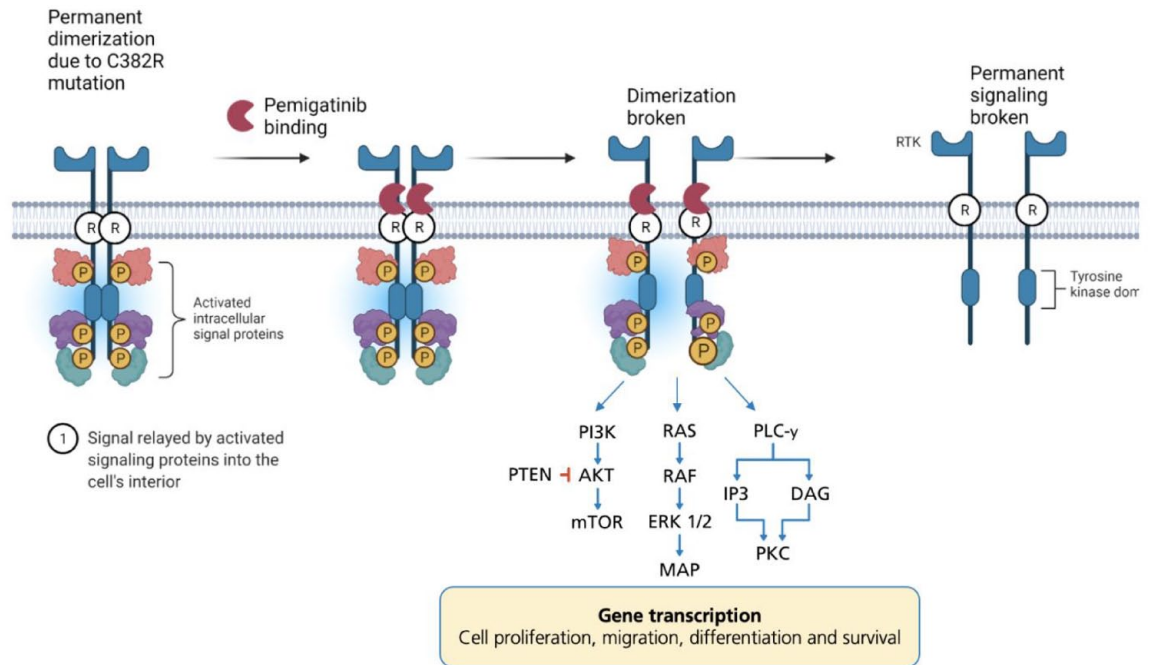


Figure 3. Ligand-independent dimerization and subsequent activation of mutant FGFR2 (p.C382R). Binding of pemigatinib leads to disruption of dimerization and thus prevents permanent activation of intracellular cell proliferation pathways. The p.C382R mutation of the FGFR2 receptor affects the transmembrane alpha helix domain of the receptor. This results in ligand-independent close contact of the transmembrane domains of both receptor chains and ligand-independent dimerization of the receptor. Herein, the activation of the intracellular tyrosine kinase domains with subsequent autophosphorylation of the receptor occurs. Binding of pemigatinib to the extracellular domains of the receptor abrogates ligand-independent receptor activation, resulting in inactivation of receptor autophosphorylation and inhibition of downstream signaling pathways. FGFR, fibroblast growth factor receptor.

before pemigatinib administration and after 3 months (Figures 5 and 6). In the pre- and post-MRI image data, an interactive tumor delineation method previously applied to liver CT data was used to determine the change in tumor size.¹⁵ The images show a significant decrease in the tumor lesion volume from 453.9 to 133.7 ml after 3 months of treatment (Figure 5).

The FDG-PET/CT revealed a complete functional remission of the iCC and lung metastases after 3 months of treatment (Figure 6). The therapy is well tolerated without any side effects. The patient continues to be treated with 13.5 mg as described above. Over the course of the treatment, tumor markers that were elevated at baseline measurement decreased to a plateau (Figure 7).

Discussion

The results of the FIGHT 202 phase II trial led to the approval of the tyrosine kinase inhibitor (TKI) pemigatinib for the treatment of patients with CCA

and fusion/rearrangement of FGFR2. In the FIGHT 202 trial, potentially targetable oncogenic driver alterations were detected in 44.5% of the enrolled patients.⁴ Of 20 patients without fusion/rearrangement of FGFR2, four carried a p.C382R mutation.¹⁰ Of these, three patients had co-occurrence of a BAP1 variant and responded to treatment. The best overall response of these three patients was stable disease with tumor shrinkage of -26% and -30.6% and a reported progression-free survival (PFS) of 6.9; 4.0 and 9.0 months.¹⁰ Our case report is the first study that showed a complete clinical remission of a patient treated with pemigatinib who carried a FGFR2 point mutation. The p.C382R mutation results in replacement of cysteine by arginine at amino acid position 382 of the transmembrane domain of FGFR2. The mutation results in an uncontrolled and prolonged downstream activation of FGFR2 pathways. *In vitro* experiments demonstrated that p.C383R leads to a constitutive ligand-independent activation of the intracellular tyrosine kinase domain of FGFR2, resulting in autophosphorylation of the

Table 1. Sequencing results revealed no germline alterations. The microsatellite status was stable, and the tumor mutational burden was classified as low with 3 Muts/Mb.

Antibody	Antigen	Provider	Dilution	Epitope retrieval	Incubation
Mouse IgG1, kappa	CK 7, clone: OV-TL	DCS GmbH	1:500	Pressure cooker in citrate buffer 20 min	Overnight RT
Mouse IgG1	Ki-67, clone: K-2	Zytomed GmbH	1:500	Pressure cooker in citrate buffer 20 min	Overnight RT
rabbit IgG1	Her-2, clone: SP3	Zytomed GmbH	1:75	Pressure cooker in citrate buffer 20 min	Overnight RT
rabbit IgG1	PD-L1, clone: Cal10	Zytomed GmbH	1:50	Pressure cooker in citrate buffer 20 min	Overnight RT
NGS results of liquid biopsy					
Blood tumor mutational burden			3 Muts/Mb		
Microsatellite status			MSS		
PIK3CA (H1047R)			0.16%		
ARID1A (A45fs*6)			6.6%		
FGFR2 (C382R)			8.1%		
MTOR (S2013G)			0.14%		
PTEN (deletion exons 3–8)			0.57%		
NGS results of tissue biopsy					
Gene	Protein effect		CNA		VAF (%)
FGFR2	C382R		–		76.48
ARIA1A	A45fs*6		–		67.81
MYC	Amplification – equivocal		6		–
PARP1	Amplification – equivocal		6		–
CNA, Copy Number Alteration; NGS, next-generation sequencing; VAF, variant allele frequency.					

receptor with subsequent activation of the downstream pathway.¹²

The clinical response under treatment with pemetinib is further supported by *in vitro* data of Nakamura and colleagues.⁷ They investigated the transformation activity and drug sensitivity of 110 FGFR variants using the so-called mixed-all-nominated-in-one (MANO) method.⁷ The MANO method is a functional assay using Ba/F3 cells colony stimulating factor or interleukin 3-dependent, murine pro-B-cells and mouse fibroblast cell line 3T3 which was previously described.⁷ An IC₅₀ < 10 nM was determined for growth inhibition of 3T3 cells bearing a FGFR2

p.C382R mutation treated *in vitro* with pemetinib. In the last decades, several *in vitro* and *in vivo* models have been developed to explore and increase their complexity and reliability to investigate treatment response in CCA.¹⁶ However, especially in CCA, the tumor microenvironment needs to be further investigated to evaluate additional therapies and biomarkers, which was recently discussed in a review by Massa *et al.*¹⁶

In our patient, we simultaneously detected a loss of PTEN exons 7–9 in tissue biopsy and loss of exons 3–8 in the liquid biopsy of this patient, leading to a functional loss of PTEN. PTEN is known to be a key modulator of the PIK3CA-AKT

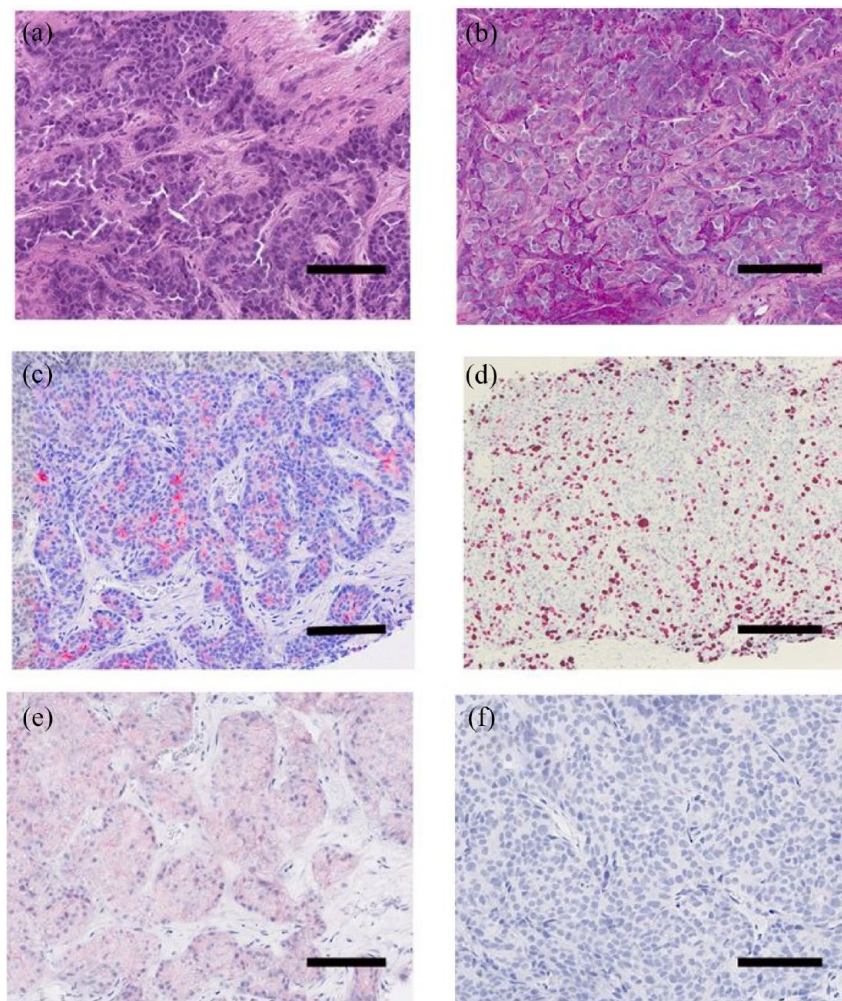


Figure 4. The histologic examination revealed a solid tumor mass with pleomorphic cells and a moderate desmoplastic stromal reaction (a: HE) and some cells with intracellular mucin deposits (b: PAS) (100 μ m). Immunohistochemistry showed a focal reaction for cytokeratin 7 (c) and a strong proliferative activity for Ki67 (d) (100 μ m). The staining for HER-2 was only weakly present in the tumor cells (e) and no staining could be seen for PD-L1 (f) (100 μ m). HE, hematoxylin and eosin; HER-2, human epidermal growth factor receptor 2; PAS, periodic acid Schiff; PD-L1, programmed death-ligand 1.

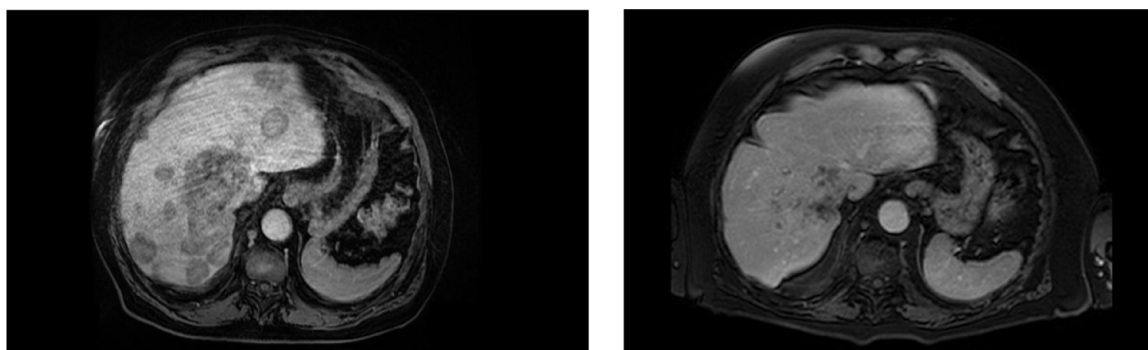


Figure 5. MRI scan on the left side shows the diffuse lesion expansion after the fifth cycle of first-line chemotherapy. The scan on the right side shows the response after 3 months in which the patient is in complete remission. MRI, magnetic resonance imaging.

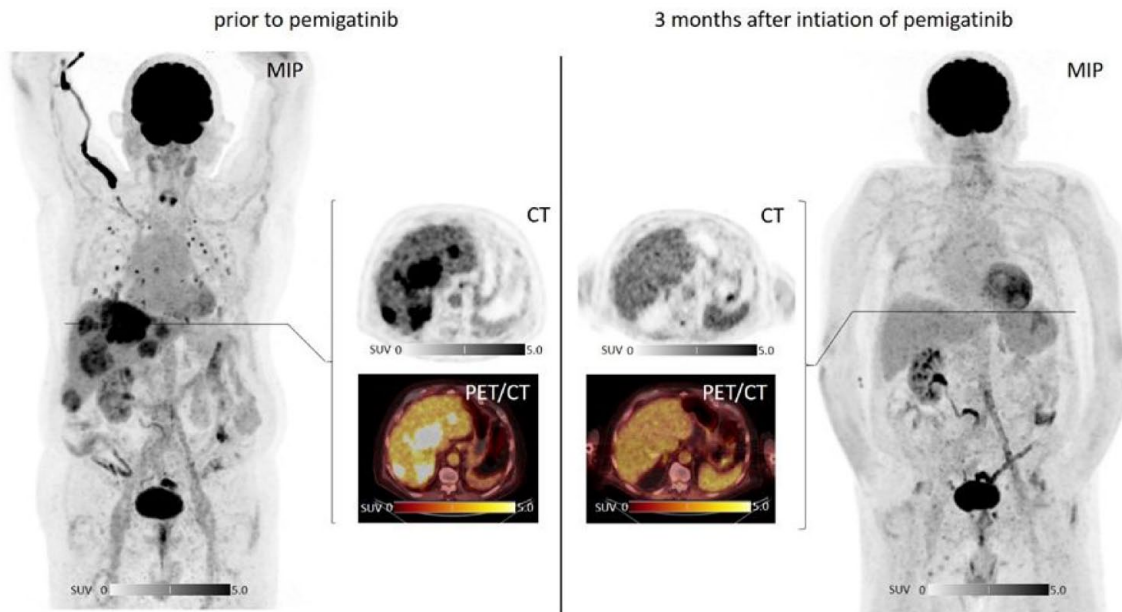


Figure 6. Display of complete metabolic remission 3 months after initiation of pemigatinib. Shown are MIPs (outer columns), transaxial slices of CT (inner upper column) as well as fused PET/CT (inner lower column). The patient initially presented with multiple pulmonary as well as hepatic metastases. The follow-up imaging revealed complete metabolic resolution of all lesions. CT, computed tomography; MIPs, maximum intensity projections; PET, positron emission tomography.

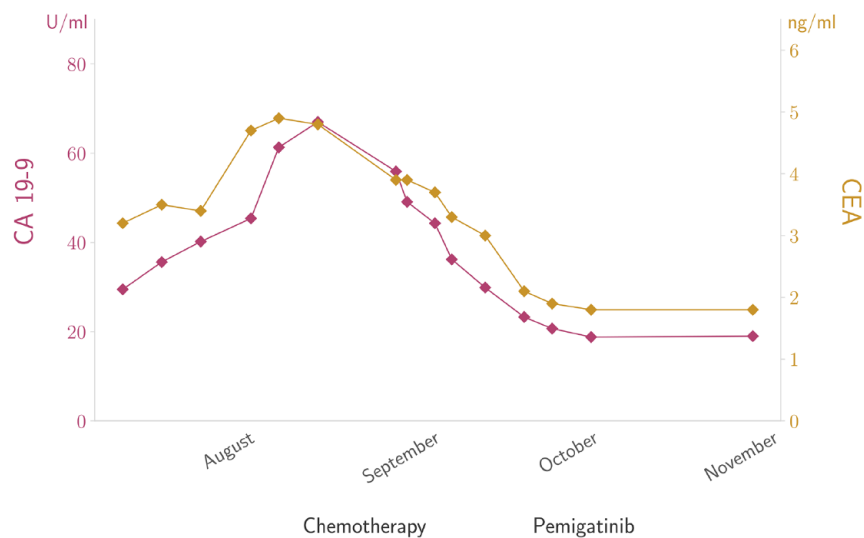


Figure 7. Development of tumor markers during the clinical course and treatment. During therapy with pemigatinib, a significant decrease in the CA19-9 and CEA was observed resulting in a plateau representing complete remission. CA, carbohydrate antigen; CEA, carcinoembryonic antigen.

pathway. As a functional tumor suppressor, the loss of PTEN may additionally activate the downstream pathway of mutated receptor tyrosine kinases FGFR2.

These findings are also supported by data from a study published in 2015, which describes the mechanism of FGFR dimerization and activation.⁹ The authors investigated the effect of

different mutations in the transmembrane domain of FGFRs and showed that the FGFR3 A391E mutation, that occurred analogously in the transmembrane domain of FGFR3, led to stabilization of the receptor dimer, which ultimately mimics the effect of the ligand binding and explains the activation of FGFR2 due to p.C382R.⁹

Although the expansion of treatment options has been broadened by the approval of pemigatinib, studies have shown that the efficacy can be significantly limited by the emergence of acquired resistance.^{4,17} Secondary polyclonal mutations, in particular, can lead to these resistance mechanisms and underscore the importance of further research efforts to optimize the use of these molecularly targeted therapies.^{3,17,18} Pemigatinib is a reversible ATP-competitive FGFR inhibitor. As shown in studies, the occurrence of drug resistance due to mutations within the binding site is relatively common with reversible ATP-competitive kinase inhibitors.^{19–22} In contrast, kinase inhibitors that inhibit kinase activity irreversibly through covalent binding can achieve a longer treatment response compared to ATP-competitive inhibitors.^{22–24} Futibatinib is an irreversible FGFR1–4 inhibitor and covalently binds to the FGFR kinase domain, inhibiting FGFR phosphorylation and thus downstream signaling. A study by Sootome *et al.*²⁵ showed that the frequency of occurrence of drug-resistant clones was lower with futibatinib than with a reversible ATP-competitive FGFR inhibitor.^{22,24} Futibatinib inhibited multiple drug-resistant FGFR2 mutants, including FGFR2 V565I/L gatekeeper mutants, with greater efficacy than all reversible FGFR inhibitors tested (IC₅₀, 1.3–50.6 nmol/L).²⁴ Irreversible and reversible FGFR inhibitors differ in their binding region. Futibatinib binds covalently to a highly conserved P-loop cysteine residue in the ATP pocket of FGFR (C492 in the FGFR2-IIIb isoform). Reversible binding of inhibitors occurs mainly in the hinge region of the ATP-binding pocket of FGFR, where drug-resistant mutations are frequently detected. Thus, the use of futibatinib is particularly suggested in patients with resistance to prior TKI therapies.²⁴

Acquired resistance in the form of polyclonal FGFR2 kinase domain mutations may shorten response. This underscores the utility of serial biopsy and circulating tumor DNA (ctDNA) analyses to identify resistance mechanisms and to guide the selection of FGFR inhibitors, as discussed in a study by Goyal *et al.*¹⁷ The study showed that

polyclonal mutations in the FGFR2 kinase domain could be detected when cell-free DNA biopsy samples were taken at different stages (at baseline and after progression) reflecting the state of resistance.¹⁷ ctDNA analysis can detect a greater extent of resistance mechanisms than tumor biopsy alone which, in terms of tumor heterogeneity, may play a role in resistance mechanisms and the frequently observed mixed response to FGFR inhibitors.³ Thus, serial ctDNA analysis represents a method that can provide complementary information on FGFR resistance mechanisms.²⁵

Nevertheless, tissue biopsy is necessary to confirm the histologic diagnosis of CCA. In addition, multigene analysis should be performed in all patients with iCC, as targeted oncogenic alterations are detectable in approximately 50% of cases.^{2,26} In tissue-based molecular analysis, the quality of the extracted DNA is often insufficient for multigene analysis. Combined diagnostics with ctDNA and proteins using liquid biopsies (omics) will gain importance in the future, both for initial diagnosis and for monitoring during treatment. Our case report also shows that liquid biopsy provides a reliable result compared with tissue-based NGS analysis. Nevertheless, the diagnosis of CCA at an early stage remains a clinical challenge, especially in patients with primary sclerosing cholangitis and biliary strictures.

Another FGFR inhibitor currently being investigated in clinical trials is derazantinib.^{27,28} The FIDES-01 phase II trial is evaluating the efficacy of derazantinib, which is directed against FGFR1–3 and the CSF1R kinase in patients with advanced iCC.^{27,29} The fact that the FIDES-01 study includes patients with FGFR2 mutation or amplification (FGFR^{M/A}) in addition to patients with FGFR2 fusion is of particular interest.²⁹ The results of an interim analysis of 23 patients were presented at ASCO 2022.²⁹ In the interim analysis, two patients (8.7%) showed partial remission and 15 patients (65.2%) presented with stable disease, resulting in a disease control rate of 73.9%. The median PFS was 7.3 months. The authors describe a clinical response in all molecular subtypes enrolled in the FGFR^{M/A} group.²⁹ These data underline that not only FGFR2 fusions, but also mutations or amplifications are actionable targets in iCC. These results should be discussed in MTBs and be considered when recommending therapy. Given that derazantinib also inhibits CSF1R kinase, it is hypothesized that the

inhibition of CSF1R leads to reactivation of exhausted T cells, can reverse tumor-induced immunosuppression, and supports macrophage activity. Therefore, it is hypothesized that the combination of derazantinib and atezolizumab (anti-programmed death-ligand 1) may result in improved efficacy due to inhibition of immunosuppressive stromal cells by the TKI *via* CSF1R and checkpoint inhibition *via* PD-L1.²⁸ This combination is being investigated in the ADVANCE phase II trial (NCT05174650) led by Arndt Vogel and colleagues, which is currently recruiting and aims to enroll 37 patients.

Conclusion

The reported clinical case in conjunction with the three reported patients in the FIGHT 202 trial demonstrates the oncogenic relevance of the p.C382R mutation of the FGFR2 receptor. The gene variant is clinically relevant as it is sensitive to targeted therapy with pemigatinib. To our knowledge, the reported case is the first description of complete functional remission with pemigatinib in a patient with p.C382R mutation. This report highlights the importance of the transforming activity and drug sensitivity of p.C382R mutations based on *in vitro* assay as described by Nakamura for *in vivo* clinical application.⁷ Furthermore, the comparison of tissue-based NGS in conjunction with liquid biopsy demonstrates that also blood samples are suitable to detect potentially druggable actionable driver mutations in patients with metastatic iCC. Sequencing of serial biopsies and ctDNA could prolong the duration of response to targeted treatments and become a fundamental tool in the daily management of these patients.³⁰ Multigene sequencing should be performed in every patient with advanced iCC, as not only FGFR fusions/rearrangements but also other alterations have oncogenic potency and may respond to targeted treatment. However, many challenges remain, such as the management of secondary polyclonal mutations, the ideally timed use of liquid biopsies, and the identification of biomarkers predictive of response to FGFR inhibitors.

Declarations

Ethics approval and consent to participate

Patients were informed by an oncological as well as a genetics specialist before they provided

written informed consent for the collection of tumor samples and NGS analysis as well as the publication of the case report. The clinical case was presented in the MTB which consisted of an interdisciplinary team coordinated by the Cancer Center Dachau and includes experts in clinical and translational oncology, pathology, bioinformatics, molecular biology, radiology, and human genetics. The study was conducted according to the guidelines of the Declaration of Helsinki of 1964 and its later amendments.

Consent for publication

The patient consented to the publication of the data in the present anonymized form as well as to the publication of the image material and the description of the clinical course.

Author contribution(s)

Louisa Hempel: Investigation; Validation; Visualization; Writing – original draft; Writing – review & editing.

Constantin Lapa: Resources; Visualization; Writing – review & editing.

Alexander Dierks: Writing – original draft.

Andreas Gaumann: Resources; Supervision; Validation; Writing – review & editing.

Josef Scheiber: Software; Validation; Visualization; Writing – review & editing.

Julia Veloso de Oliveira: Software; Visualization; Writing – review & editing.

Patrick Philipp: Software; Validation; Visualization; Writing – review & editing.

Cristina Oyarzun Laura: Resources; Software; Writing – review & editing.

Stefan Wesarg: Conceptualization; Software; Writing – review & editing.

Sebastian Robert: Resources; Software; Writing – original draft; Writing – review & editing.

Dirk Hempel: Supervision; Validation; Writing – original draft; Writing – review & editing.

Acknowledgements

None.

Funding

The authors received no financial support for the research, authorship, and/or publication of this article.

Competing interests

The authors declare that there is no conflict of interest.

Availability of data and materials

The NGS panel sequencing dataset generated during the current study is not publicly available as these are patient samples with potentially identifiable genetic information and there is no patient consent for depositing this sequencing data in a public repository. However, the data are available from the corresponding author on reasonable request.

ORCID iDs

Louisa Hempel  <https://orcid.org/0000-0001-5145-4705>

Patrick Philipp  <https://orcid.org/0000-0002-7968-9757>

References

- Lowery MA, Ptashkin R, Jordan E, *et al.* Comprehensive molecular profiling of intrahepatic and extrahepatic cholangiocarcinomas: potential targets for intervention. *Clin Cancer Res* 2018; 24: 4154–4161.
- Lamarca A, Edeline J and Goyal L. How I treat biliary tract cancer. *ESMO Open* 2022; 7:100378.
- Rizzo A, Ricci AD and Brandi G. Pemigatinib: hot topics behind the first approval of a targeted therapy in cholangiocarcinoma. *Cancer Treat Res Commun* 2021; 27: 100337.
- Abou-Alfa GK, Sahai V, Hollebecque A, *et al.* Pemigatinib for previously treated, locally advanced or metastatic cholangiocarcinoma: a multicentre, open-label, phase 2 study. *Lancet Oncol* 2020; 21: 671–684.
- Li F, Peiris MN and Donoghue DJ. Functions of FGFR2 corrupted by translocations in intrahepatic cholangiocarcinoma. *Cytokine Growth Factor Rev* 2020; 52: 56–67.
- Krook MA, Reeser JW, Ernst G, *et al.* Fibroblast growth factor receptors in cancer: genetic alterations, diagnostics, therapeutic targets and mechanisms of resistance. *Br J Cancer* 2021; 124: 880–892.
- Nakamura IT, Kohsaka S, Ikegami M, *et al.* Comprehensive functional evaluation of variants of fibroblast growth factor receptor genes in cancer. *NPJ Precis Oncol* 2021; 5: 66.
- Lemmon MA and Schlessinger J. Cell signaling by receptor tyrosine kinases. *Cell* 2010; 141: 1117–1134.
- Sarabipour S and Hristova K. Mechanism of FGF receptor dimerization and activation. *Nat Commun* 2016; 7: 10262.
- Silverman IM, Hollebecque A, Friboulet L, *et al.* Clinicogenomic analysis of *FGFR2*-rearranged cholangiocarcinoma identifies correlates of response and mechanisms of resistance to pemigatinib. *Cancer Discov* 2021; 11: 326–339.
- Li Y, Mangasarian K, Mansukhani A, *et al.* Activation of FGF receptors by mutations in the transmembrane domain. *Oncogene* 1997; 14: 1397–1406.
- Allegretti M, Fabi A, Buglioni S, *et al.* Tearing down the walls: FDA approves next generation sequencing (NGS) assays for actionable cancer genomic aberrations. *J Exp Clin Cancer Res* 2018; 37: 47.
- Chalmers ZR, Connelly CF, Fabrizio D, *et al.* Analysis of 100,000 human cancer genomes reveals the landscape of tumor mutational burden. *Genome Med* 2017; 9: 34.
- Frampton GM, Fichtenholtz A, Otto GA, *et al.* Development and validation of a clinical cancer genomic profiling test based on massively parallel DNA sequencing. *Nat Biotechnol* 2013; 31: 1023–1031.
- Oyarzun Laura C, Drechsler K, Wesarg S, *et al.* Accurate physics-based registration for the outcome validation of minimal invasive interventions and open liver surgeries. *IEEE Trans Biomed Eng* 2017; 64: 362–371.
- Massa A, Varamo C, Vita F, *et al.* Evolution of the experimental models of cholangiocarcinoma. *Cancers (Basel)* 2020; 12: 2308.
- Goyal L, Saha SK, Liu LY, *et al.* Polyclonal secondary *FGFR2* mutations drive acquired resistance to FGFR inhibition in patients with *FGFR2* fusion-positive cholangiocarcinoma. *Cancer Discov* 2017; 7: 252–263.
- Smyth EC, Babina IS and Turner NC. Gatekeeper mutations and intratumoral heterogeneity in *FGFR2*-translocated cholangiocarcinoma. *Cancer Discov* 2017; 7: 248–249.
- Nakamura H, Arai Y, Totoki Y, *et al.* Genomic spectra of biliary tract cancer. *Nat Genet* 2015; 47: 1003–1010.
- Borad MJ, Champion MD, Egan JB, *et al.* Integrated genomic characterization reveals novel,

- therapeutically relevant drug targets in FGFR and EGFR pathways in sporadic intrahepatic cholangiocarcinoma. *PLoS Genetics* 2014; 10: e1004135.
21. Borger DR, Tanabe KK, Fan KC, *et al.* Frequent mutation of isocitrate dehydrogenase (IDH)1 and IDH2 in cholangiocarcinoma identified through broad-based tumor genotyping. *Oncologist* 2012; 17: 72–79.
 22. Goyal L, Kongpetch S, Crolley VE, *et al.* Targeting FGFR inhibition in cholangiocarcinoma. *Cancer Treat Rev* 2021; 95: 102170.
 23. Ross JS, Wang K, Gay L, *et al.* New routes to targeted therapy of intrahepatic cholangiocarcinomas revealed by next-generation sequencing. *Oncologist* 2014; 19: 235–242.
 24. Sootome H, Fujita H, Ito K, *et al.* Futibatinib is a novel irreversible FGFR 1–4 inhibitor that shows selective antitumor activity against FGFR-deregulated tumors. *Cancer Res* 2020; 80: 4986–4997.
 25. Rizzo A, Ricci AD, Tavolari S, *et al.* Circulating tumor DNA in biliary tract cancer: current evidence and future perspectives. *Cancer Genomics Proteomics* 2020; 17: 441–452.
 26. Bekaii-Saab TS, Bridgewater J and Normanno N. Practical considerations in screening for genetic alterations in cholangiocarcinoma. *Ann Oncol* 2021; 32: 1111–1126.
 27. Braun S, McSheehy P, Litherland K, *et al.* Derazantinib: an investigational drug for the treatment of cholangiocarcinoma. *Expert Opin Investig Drugs* 2021; 30: 1071–1080.
 28. Droz Dit Busset M, Braun S, El-Rayes B, *et al.* Efficacy of derazantinib (DZB) in patients (pts) with intrahepatic cholangiocarcinoma (iCCA) expressing FGFR2-fusion or FGFR2 mutations/ amplifications. *Ann Oncol* 2019; 30: v276–v277.
 29. Javle MM, Abou-Alfa GK, Macarulla T, *et al.* Efficacy of derazantinib in intrahepatic cholangiocarcinoma patients with FGFR2 mutations or amplifications: interim results from the phase 2 study FIDES-01. *J Clin Oncol* 2022; 40: 427.
 30. Rizzo A, Ricci AD, Tober N, *et al.* Second-line treatment in advanced biliary tract cancer: today and tomorrow. *Anticancer Res* 2020; 40: 3013–3030.

Visit SAGE journals online
journals.sagepub.com/
home/tam

 SAGE journals