

BK Polyomavirus-Induced Nephropathy in Native Kidney

Review began 01/20/2023

Review ended 01/28/2023

Published 01/30/2023

© Copyright 2023

Munjal et al. This is an open access article distributed under the terms of the Creative Commons Attribution License CC-BY 4.0., which permits unrestricted use, distribution, and reproduction in any medium, provided the original author and source are credited.

Ripudaman S. Munjal¹, Jaskaran Munjal², Pulkit Gandhi^{3,4}, Nikhil Gupta⁵

1. Nephrology, San Joaquin General Hospital, Stockton, USA 2. Internal Medicine, Shri Ram Murti Smarak Institute of Medical Sciences, Bareilly, IND 3. Nephrology, Lake Erie College of Osteopathic Medicine, Erie, USA 4. Nephrology, Rochester Regional Health, Rochester, USA 5. Internal Medicine, San Joaquin General Hospital, Stockton, USA

Corresponding author: Ripudaman S. Munjal, ripudaman.munjal@hotmail.com

Abstract

BK polyomavirus has been well-studied as an opportunistic infection in immunocompromised kidney transplant patients. In the majority of the population, BK polyomavirus establishes a lifelong infection in renal tubular and uroepithelial cells; however, in an immunocompromised state, the virus can reactivate and can lead to BK polyomavirus-associated nephropathy (BKN). In this case, the patient was a 46-year-old male with a past medical history of HIV, compliant with antiretroviral therapy (ART), and B-cell lymphoma treated with chemotherapy. The patient presented with worsening kidney function of unknown etiology. This prompted further assessment with a kidney biopsy. Kidney biopsy findings were consistent with BKN. In the literature, BKN has been studied in renal transplant patients; however, it rarely involves native kidneys.

Categories: Infectious Disease, Nephrology, Transplantation

Keywords: nephropathy, bk polyomavirus, immunosuppressed, dialysis, chronic kidney disease, acute kidney injury, bk nephropathy

Introduction

The BK virus is a human polyomavirus that was first discovered in 1971 in the urine of a kidney transplant recipient [1]. It shares similar features with the simian virus 40 (SV40) and JC virus. Infection with the BK virus is endemic; the primary BK virus is typically acquired in childhood, with the seroprevalence rate in adults reaching 80% [2,3]. After infection, the virus remains dormant within the genitourinary epithelium. It is usually asymptomatic in immunocompetent hosts [4]. BK polyomavirus can cause BK nephropathy (BKN), ureteral stricture, and hemorrhagic cystitis in immunocompromised hosts [5]. BKN was thought to be a disease of kidney allografts, only affecting kidney transplant recipients. BKN occurs in 1% to 10% of patients with kidney transplantation [6]. Native kidney BKN is rare, especially without a history of prior organ transplantation. There is growing literature on BKN in immunocompromised patients [7]. Definitive diagnosis is made by a kidney biopsy and detection of polyomavirus in tubular cells of the kidney with the antigen simian virus 40 (SV40) of the virus using the SV40 stain [8]. Here, we describe a biopsy-proven native kidney BKN in an immunocompromised patient with no history of organ transplantation.

Case Presentation

A 46-year-old male was admitted to the hospital with pain in the abdomen and an acute kidney injury. His medical history included HIV, diagnosed about two years before presentation, and B-cell lymphoma, diagnosed about one year before presentation. B-cell lymphoma was treated with rituximab, etoposide phosphate, prednisone, vincristine sulfate, cyclophosphamide, and doxorubicin hydrochloride (R-EPOCH). B-cell lymphoma was in remission, and no further treatment was planned. HIV was treated with a combination pill containing bicittegravi, emtricitabine, and tenofovir alafenamide. Despite the patient being compliant with his HIV medications, his clusters of differentiation 4 (CD4) count was low (25 cells/mm³). The HIV viral load was not checked at the time of presentation. The patient did not have any other complaints other than a pain in the abdomen, which resolved spontaneously.

He was noted to have had progressive worsening of kidney function over the course of six months prior to presentation. Creatinine worsened from 1.0 mg/dL with an eGFR of 72 mL/min/1.73m² to creatinine of 3.63 mg/dL with an estimated glomerular filtration rate (eGFR) of 18 mL/min/1.73m² [Table 1]. Urinalysis with urine microscopy was unremarkable. The kidney ultrasound was unremarkable. The cause of the progressive worsening of kidney function was unknown, prompting a kidney biopsy. Kidney biopsy results confirmed BKN with a positive stain for SV40. Serum and urine samples were also checked for BK polyomavirus. Serum BK virus polymerase chain reaction (PCR) showed 5,391,435 copies/mL (normal: <500 copies/mL), and urine BK virus PCR showed > 500 million copies/mL (normal: <500 copies/mL).

How to cite this article

Munjal R S, Munjal J, Gandhi P, et al. (January 30, 2023) BK Polyomavirus-Induced Nephropathy in Native Kidney. Cureus 15(1): e34410. DOI 10.7759/cureus.34410

Date	Serum creatinine (mg/dL)	eGFR (mL/min/1.73m2)
August 2021	1	72
September 2021	1.95	37
October 2021	2.25	34
February 2022	3.63	18

TABLE 1: Kidney function tests of the patient

Serum creatinine is measured as milligrams per deciliter (mg/dL); eGFR: estimated glomerular filtration rate; eGFR is measured as milliliters per minute per body surface (mL/min/1.73m2)

The patient could not receive any of the treatment options. The patient was followed up after hospital discharge but was noted to have continued worsening kidney functions. He unfortunately required kidney replacement therapy in the form of hemodialysis four months after the initial presentation.

Pathology

The sample for pathology contained a small core. One of the five glomeruli was globally sclerotic. Glomeruli were histologically unremarkable. Numerous viral inclusions (Figure 1) involving a large number of cells were seen. SV40 immunostain (Figure 2) was positive in nuclei with inclusions indicative of polyomavirus nephropathy. Immunofluorescence had no specific staining of immunoglobulin G (IgG), immunoglobulin A (IgA), immunoglobulin M (IgM), complement component 3 (C3), kappa, or lambda light chains.

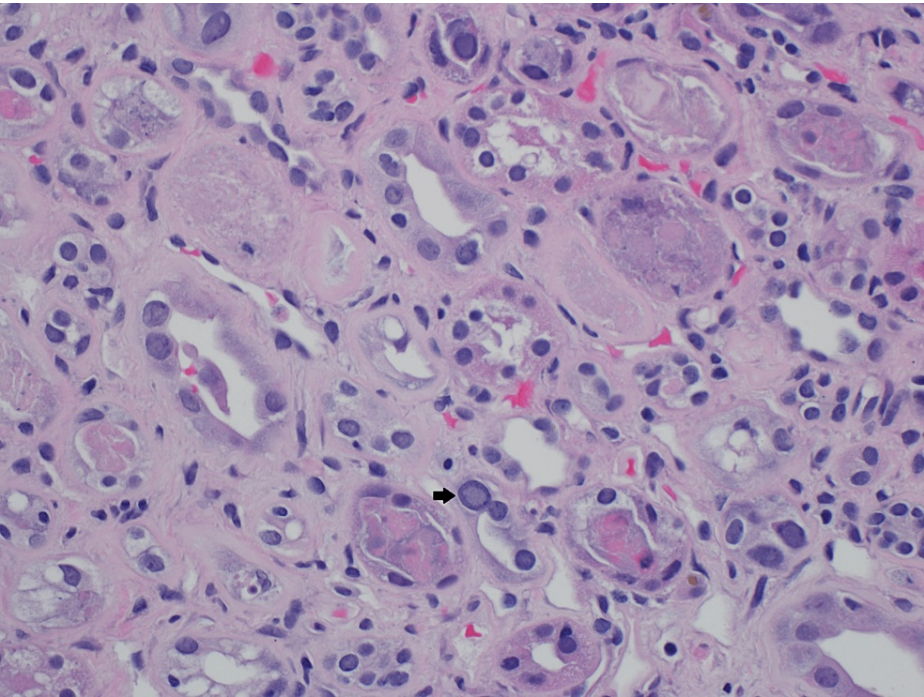


FIGURE 1: Kidney biopsy with viral inclusions

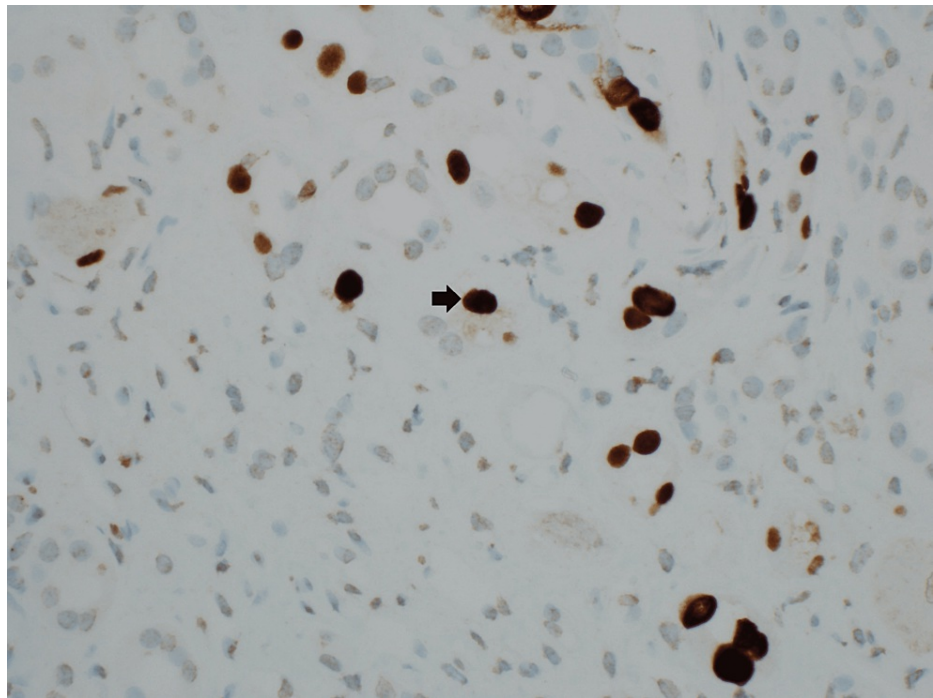


FIGURE 2: Kidney biopsy: simian virus 40 (SV40) immunostain

Discussion

The BK virus is a DNA virus of the Polyomaviridae family that causes interstitial nephritis in immunosuppressed patients [9]. It is caused by the reactivation of the BK virus, which leads to inflammation and damage to the kidney tissue. It is a known occurrence after kidney transplantation. BKN usually affects 1%-15% of kidney transplant recipients, which can be associated with allograft loss [10,11]. The BK virus is rare in native kidneys; most cases have been reported in bone marrow transplant patients [7]. There is limited literature on non-transplant native kidney BKN. BKN is a potential cause of kidney dysfunction in both native and transplanted kidneys. A high percentage of patients (21.5%) who are diagnosed with BKN require chronic dialysis, as in the case report presented here [12]. This makes it very important to consider the BK virus as a potential cause of worsening kidney functions, especially in immunosuppressed individuals. More cases being reported are helping to better understand the disease.

The diagnosis of BKN includes BK virus PCR in blood and urine, but a definitive diagnosis is made by a kidney biopsy [8]. The non-invasive method of initial diagnostic tests may be readily available and help in early diagnosis. The utility of screening immunocompromised patients with PCR remains to be studied.

No effective therapy is currently available for BKN. In kidney transplant recipients, a reduction in immunosuppression can be effective in treating BKN [4]. In individuals where reduction in immunosuppression is not possible or in immunocompetent patients, leflunomide can be considered, as it has shown some benefits [13,14,15]. Other alternate therapies include rapamycin (mTOR) inhibitors, fluoroquinolones, cidofovir, and intravenous immunoglobulin (IVIg) [16,17,18,19].

In the case we present, the patient was not able to get any of the available treatment options. The HIV medications were continued. Although the HIV viral load was not checked initially, it was undetectable on the follow-up visit, and the CD4 count continued to be low. Unfortunately, the patient's kidney function continued to worsen, requiring kidney replacement therapy.

Conclusions

BKN should be considered in the differential diagnosis for worsening kidney function in immunocompromised patients with no clear diagnosis, even in patients who are not organ transplant recipients. Non-invasive tests can be considered for possible early diagnosis. As it has a high incidence of progressing to end-stage kidney disease requiring chronic kidney replacement therapy, early diagnosis and prompt treatment can prove to be beneficial.

Additional Information

Disclosures

Human subjects: Consent was obtained or waived by all participants in this study. **Conflicts of interest:** In compliance with the ICMJE uniform disclosure form, all authors declare the following: **Payment/services info:** All authors have declared that no financial support was received from any organization for the submitted work. **Financial relationships:** All authors have declared that they have no financial relationships at present or within the previous three years with any organizations that might have an interest in the submitted work. **Other relationships:** All authors have declared that there are no other relationships or activities that could appear to have influenced the submitted work.

References

- Gardner SD, Field AM, Coleman DV, Hulme B: New human papovavirus (B.K.) isolated from urine after renal transplantation. *Lancet*. 1971, 1:1253-7. [10.1016/s0140-6736\(71\)91776-4](#)
- Gossai A, Waterboer T, Nelson HH, et al.: Seroepidemiology of human polyomaviruses in a US population. *Am J Epidemiol*. 2016, 183:61-9. [10.1093/aje/kwv155](#)
- Egli A, Infanti L, Dumoulin A, et al.: Prevalence of polyomavirus BK and JC infection and replication in 400 healthy blood donors. *J Infect Dis*. 2009, 199:837-46. [10.1086/597126](#)
- Sawinski D, Goral S: BK virus infection: an update on diagnosis and treatment. *Nephrol Dial Transplant*. 2015, 30:209-17. [10.1093/ndt/gfu023](#)
- Rajpoot DK, Gomez A, Tsang W, Shanberg A: Ureteric and urethral stenosis: a complication of BK virus infection in a pediatric renal transplant patient. *Pediatr Transplant*. 2007, 11:433-5. [10.1111/j.1399-3046.2006.00673.x](#)
- Ramos E, Drachenberg CB, Wali R, Hirsch HH: The decade of polyomavirus BK-associated nephropathy: state of affairs. *Transplantation*. 2009, 87:621-30. [10.1097/TP.0b013e318197c17d](#)
- Sharma SG, Nicleleit V, Herlitz LC, et al.: BK polyoma virus nephropathy in the native kidney. *Nephrol Dial Transplant*. 2013, 28:620-31. [10.1093/ndt/gfs537](#)
- Manuel O, Toso C, Pascual MA -: 84 - Kidney and pancreas transplant recipients. *Infect Dis*. 2017, 1:762-9.
- Kuppachi S, Kaur D, Holanda DG, Thomas CP: BK polyoma virus infection and renal disease in non-renal solid organ transplantation. *Clin Kidney J*. 2016, 9:310-8. [10.1093/ckj/sfv143](#)
- Brennan DC, Agha I, Bohl DL, et al.: Incidence of BK with tacrolimus versus cyclosporine and impact of preemptive immunosuppression reduction. *Am J Transplant*. 2005, 5:582-94. [10.1111/j.1600-6143.2005.00742.x](#)
- Hirsch HH, Randhawa P: BK polyomavirus in solid organ transplantation. *Am J Transplant*. 2013, 13 Suppl 4:179-88. [10.1111/ajt.12110](#)
- Shah A, Kumar V, Palmer MB, Trofe-Clark J, Laskin B, Sawinski D, Hogan JJ: Native kidney BK virus nephropathy, a systematic review. *Transpl Infect Dis*. 2019, 21:e13083. [10.1111/tid.13083](#)
- Nesselhauf N, Strutt J, Bastani B: Evaluation of leflunomide for the treatment of BK viremia and biopsy proven BK nephropathy; a single center experience. *J Nephropathol*. 2016, 5:34-7. [10.15171/jnp.2016.06](#)
- Faguer S, Hirsch HH, Kamar N, et al.: Leflunomide treatment for polyomavirus BK-associated nephropathy after kidney transplantation. *Transpl Int*. 2007, 20:962-9. [10.1111/j.1432-2277.2007.00523.x](#)
- Josephson MA, Gillen D, Javaid B, et al.: Treatment of renal allograft polyoma BK virus infection with leflunomide. *Transplantation*. 2006, 81:704-10. [10.1097/01.tp.0000181149.76113.50](#)
- Kuypers DR, Vandooren AK, Lerut E, et al.: Adjuvant low-dose cidofovir therapy for BK polyomavirus interstitial nephritis in renal transplant recipients. *Am J Transplant*. 2005, 5:1997-2004. [10.1111/j.1600-6143.2005.00980.x](#)
- Vats A, Shapiro R, Singh Randhawa P, et al.: Quantitative viral load monitoring and cidofovir therapy for the management of BK virus-associated nephropathy in children and adults. *Transplantation*. 2003, 75:105-12. [10.1097/00007890-200301150-00020](#)
- Santeusano AD, Lukens BE, Eun J: Antiviral treatment of BK virus viremia after kidney transplantation. *Am J Health Syst Pharm*. 2017, 74:2037-45. [10.2146/ajhp160585](#)
- Johnston O, Jaswal D, Gill JS, Doucette S, Fergusson DA, Knoll GA: Treatment of polyomavirus infection in kidney transplant recipients: a systematic review. *Transplantation*. 2010, 89:1057-70. [10.1097/TP.0b013e3181d0e15e](#)