

CASE REPORT

A rare case of hypercalcemic encephalopathy from ectopic secretion of parathyroid hormone

Franchesca Gabrielle Concha Gabriel  | Rosalina Espiritu Picar

Section of Neurology, Department of
Neurosciences, Makati Medical Center,
Makati, Philippines

Correspondence

Franchesca Gabrielle Concha Gabriel,
Section of Neurology, Department of
Neurosciences, Makati Medical Center,
2 Amorsolo St., Legaspi Village, Makati,
Metro Manila, Philippines.
Email: fgcgabriel@gmail.com

Abstract

Altered mental status can be the initial presenting symptom of an ectopic hyperparathyroidism from severe hypercalcemia. A high index of suspicion for paraneoplastic hypercalcemia and a systematic approach to diagnosis should be considered.

KEYWORDS

ectopic secretion of parathyroid hormone, encephalopathy, hypercalcemia

1 | INTRODUCTION

Hypercalcemia of malignancy secondary to an ectopic secretion of intact parathyroid hormone (PTH) by a nonparathyroid tumor is rare comprising only less than 1% of cases. The most common mechanisms of hypercalcemia in malignancy are parathyroid hormone-related protein secretion and bone marrow invasion, comprising more than 80% of cases. Meanwhile, increased levels of parathyroid hormone in the setting of hypercalcemia are commonly due to a parathyroid tumor (primary hyperparathyroidism). Of the cases of ectopic PTH secretion, only three were found to be of ovarian origin and none of which presented with neurologic symptoms.^{1,2}

This paper describes a previously well patient presenting with delirium, who on further workup was discovered to have severe hypercalcemia from an ectopic secretion of PTH by a large cell neuroendocrine ovarian carcinoma. Since 1991, only 41 cases of neuroendocrine ovarian carcinoma were reported and the most frequent presenting symptoms were abdominal distention and palpable abdominal mass. This is only the 3rd reported case of a PTH-secreting ovarian neuroendocrine tumor and the first to have initially presented with neurologic symptoms.^{1,3}

2 | CASE

A 45 year-old nulligravid woman presented with a 3-day history of generalized body weakness with onset of behavioral changes two days before admission. She had episodes of restlessness, incoherent speech, and visual hallucinations, accompanied by undocumented fever. She was brought to a hospital and underwent a plain cranial CT scan which was unremarkable. She was then transferred to this institution for further management. She had an undocumented weight loss and irregular menstruation. She had a history of a biopsy-confirmed benign pulmonary lobe mass in 2013. On initial examination, she was delirious, disoriented and incoherent, unable to name objects, and could only follow one-step commands. There were no focal neurologic deficits or signs of meningeal irritation. She had symptoms of generalized tremulousness most prominent during movement and mild pendular nystagmus on primary gaze. A firm, nontender, nonmoveable right lower quadrant mass measuring 8 × 6 cm was palpated.

Consideration of acute encephalitis prompted lumbar puncture and CSF studies with findings of normal opening pressure, and only mildly elevated CSF protein at 47.8 mg/dL. Further CSF tests for antibodies to NMDA, AMPA, GABA(B), mGluR1

and mGluR5 receptors, LGI1, and Caspr2 were negative decreasing likelihood of a viral or autoimmune encephalitis.

Electroencephalogram showed diffuse slowing of background activity with rare epileptiform discharges on the left frontotemporal region. Valproic acid 500 mg two times daily was started. Laboratories showed hypercalcemia (16.6 mg/dL), elevated creatinine (1.44 mg/dL), hypokalemia (3.3 mg/dL), elevated CRP (47.7 mg/dL), elevated alkaline phosphatase (205 U/L), and normal phosphorus (3.61 mg/dL). The patient was initially treated with hydration, furosemide, calcitonin, and cinacalcet. Hemodialysis was initiated. Investigation of hypercalcemia showed markedly elevated intact PTH levels at 306.7 pg/mL (NV: 15–65 pg/mL). Ultrasound of the neck and sestamibi scan were negative for a parathyroid adenoma. Primary hyperparathyroidism was ruled out, and an ectopic secretion of PTH was considered.

Contrast-enhanced CT scan of the whole abdomen showed enhancing foci within the uterine wall measuring 2.8×5.2 cm and 1.8×2.5 cm. There were enhancing masses in the bilateral hemipelvis measuring $8.4 \times 5.0 \times 6.4$ cm in the right and $3.4 \times 2.5 \times 4.1$ cm in the left (Figure 1). The

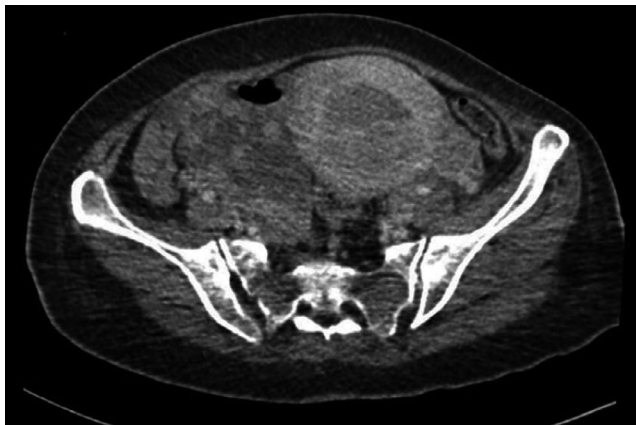

FIGURE 1 Contrast-enhanced CT scan of the whole abdomen showing enhancing masses in the bilateral hemipelvis, larger on the right

patient underwent extrafascial hysterectomy, bilateral salpingo-oophorectomy, and bilateral lymphadenectomy. PTH and calcium levels were monitored preoperatively (326.89 pg/mL), 6 hours post-op (78.38 pg/mL) and 24 hours post-op (77.0 pg/mL). There was significant decrease in the level of PTH after removal of the tumor with no recurrence of PTH elevation or hypercalcemia postoperatively (Figure 2).

Preoperatively, mental status examination revealed impaired executive attention, difficulty of both memory storage and retrieval, and disorder of thought content—tangentiality and occasional visual hallucinations. There was a significant improvement in the mental status postoperatively—becoming more coherent and oriented, still with impaired attention and concentration, as well as short-term memory difficulty but with no tangentiality or flight of ideas.

Histopathologic diagnosis showed a large cell neuroendocrine carcinoma involving bilateral ovaries with metastasis to the myometrium and pelvic lymph nodes (Figure 3). Immunohistochemistry was positive for both synaptophysin and chromogranin.

3 | DISCUSSION

Neurologic abnormalities could be the initial presentation of a systemic disease. Endocrine problems, particularly hypercalcemia and hyperparathyroidism, are among those that may present with neurologic symptoms. Altered mental status is a common reason for consult in the emergency department.⁴ Delirium can be caused by metabolic and endocrine abnormalities including hypercalcemia and hyperparathyroidism. Patients usually have disorientation, irritability, delusions, or hallucinations.^{5–7}

Malignancy-associated hypercalcemia, commonly attributed to expression of parathyroid hormone-related protein, was reported in 20%–30% of cancer patients.⁸ Less than 1% of hypercalcemia from malignancy is secondary to ectopic hyperparathyroidism. Although not pathologically

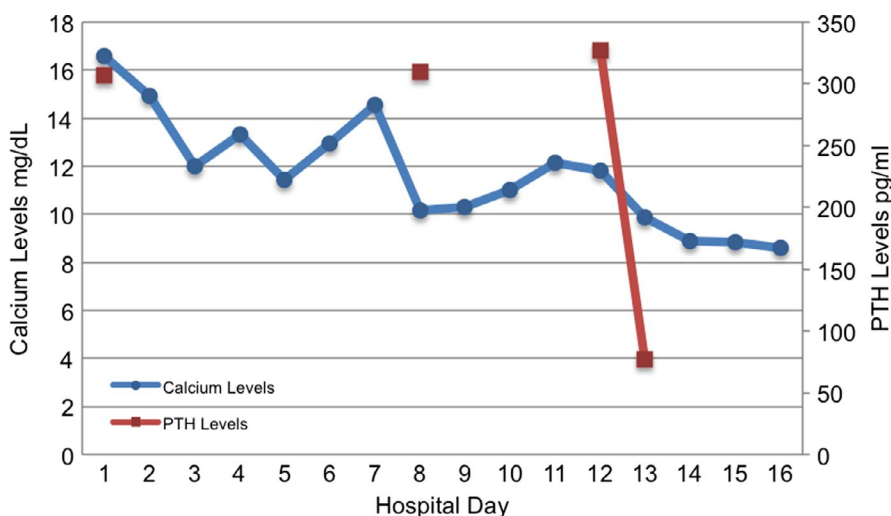


FIGURE 2 Time course of the decline of serum concentrations of calcium and PTH after resection of an ovarian carcinoma

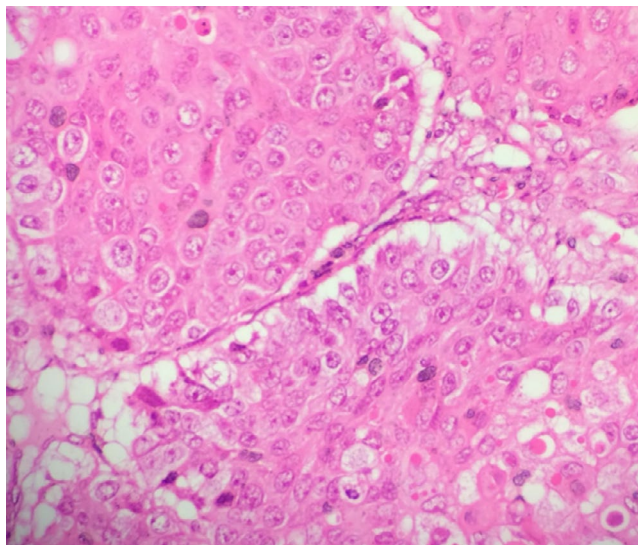


FIGURE 3 Ovarian carcinoma showing nests of cells with atypical and pleomorphic, centrally located nuclei, and prominent nucleoli (hematoxylin-eosin, x400)

confirmed, the decrease in PTH and calcium levels postoperatively suggests that the ovarian tumor is PTH-secreting.

Hypercalcemia manifests with nonspecific and multisystemic causing GI, renal, cardiac, musculoskeletal, and neurologic symptoms.⁷ Neurologic symptoms occur in 40% of patients.⁵ Severity of hypercalcemia is related to worse clinical presentations. Mild hypercalcemia (10.5–11.9 mg/dL) manifests as anxiety or depression, moderate hypercalcemia (12–13.9 mg/dL) as cognitive dysfunction, and severe hypercalcemia (>14 mg/dL) as lethargy, confusion, stupor, or coma.⁹ The abrupt increase in the calcium levels affects the severity of the neurologic manifestation such that an acute severe hypercalcemia would present with more severe neurologic dysfunction compared to chronic hypercalcemia.^[10,11]

Seizures are rare and can be seen at serum calcium levels ≥ 10.5 mg/dL.^{5,10} Electroencephalographic abnormalities vary depending on calcium levels. With calcium levels at 13 mg/dL, EEG shows fast activity and paroxysms of delta and theta slowing. Worsening of slowing of background activities and increase in theta/delta bursts are noted with further increase in calcium.^[10,11,12]

The proposed mechanisms for neurologic effects of hypercalcemia are reversible cerebral vasospasm and vasogenic edema, thought to be responsible for symptoms of encephalopathy and seizures. Hypercalcemia may lead to vasospasm by promoting actin-myosin coupling leading to activation of vascular smooth muscles.¹³

4 | CONCLUSION

This study highlights that altered mental status or delirium can be the initial presenting symptom of an ectopic hyperparathyroidism from severe hypercalcemia. A high index of

suspicion for paraneoplastic hypercalcemia and a systematic approach to diagnosis should be considered.

CONFLICT OF INTEREST

None declared.

AUTHOR CONTRIBUTIONS

FG: was involved in management of the case, drafting the manuscript, and revising it. RP: was involved in the diagnosis and management of the case, revising of the manuscript, and final approval.

ORCID

Franchesca Gabrielle Concha Gabriel  <https://orcid.org/0000-0001-6949-879X>

REFERENCES

- Kandil E, Noureldine S, Khalek MA, Daroca P, Friedlander P. Ectopic secretion of parathyroid hormone in a neuroendocrine tumor: a case report and review of the literature. *Int J Clin Exp Med*. 2011;4(3):234–240.
- Chen L, Dinh TA, Haque A. Small cell carcinoma of the ovary with hypercalcemia and ectopic parathyroid hormone production. *Arch Pathol Lab Med*. 2005;129(4):531–533.
- Ohira S, Itoh K, Shiozawa T, et al. Ovarian nonsmall cell neuroendocrine carcinoma with paraneoplastic parathyroid hormone-related hypercalcemia. *Int J Gynecol Pathol*. 2004;23:393–397.
- Kanich W, Brady WJ, Huff JS, Perron AD, Holstege C, Lindbeck G, Carter CT. Altered mental status: Evaluation and etiology in the ED. *The American Journal of Emergency Medicine*. 2002;20(7):613–617.
- Posner JB, Plum F. *Plum and Posner's Diagnosis of Stupor and Coma*, 4th edn. New York: Oxford University Press; 2007.
- Ahmad S, Kuraganti G, Steenkamp D. Hypercalcemic crisis: a clinical review. *Am J Med*. 2015;128(3):239–245.
- Carroll R, Matfin G. Endocrine and metabolic emergencies: hypercalcaemia. *Ther Adv Endocrinol Metab*. 2010;1(5):225–234.
- Stewart AF. Hypercalcemia associated with cancer. *N Engl J Med*. 2005;352(4):373–379.
- Inzucchi SE. Understanding hypercalcemia: its metabolic basis, signs, and symptoms. *Postgrad Med*. 2004;115:69–70,73–76.
- Castilla-Guerra L, Fernández-Moreno MDC, López-Chozas JM, Fernández-Bolaños R. Electrolytes Disturbances and Seizures. *Epilepsia*. 2006;47:1990–1998.
- Marx SJ. Hyperparathyroid and hypoparathyroid disorders. *N Engl J Med*. 2000;343:1863–1875.
- Kaplan PW. The EEG in metabolic encephalopathy and coma. *J Clin Neurophysiol*. 2004;21:307–318.
- Chen T-H, Huang C-C, Chang Y-Y, Chen Y-F, Chen W-H, Lai S-L. Vasoconstriction as the Etiology of Hypercalcemia-induced Seizures. *Epilepsia*. 2004;45:551–554.

How to cite this article: Gabriel FGC, Picar RE. A rare case of hypercalcemic encephalopathy from ectopic secretion of parathyroid hormone. *Clin Case Rep*. 2020;8:423–425. <https://doi.org/10.1002/ccr3.2631>