



Management of Secondary Angle Closure Glaucoma

¹Parivadhini Annadurai, ²Lingam Vijaya

ABSTRACT

Secondary angle closure glaucomas are a distinct entity from primary angle closure glaucoma (PACG). Unlike PACG, secondary angle closure glaucoma's have an identifiable contributory factor/s for angle closure and obstruction of aqueous flow which is usually unrelieved by iridotomy. The treatment of each type of secondary angle closure glaucoma is varied, so identification of the primary cause aids in its effective management.

Keywords: Pupillary block, Neovascular glaucoma, Iridocorneal endothelial syndrome, Aqueous misdirection syndrome, Ciliary body swelling.

How to cite this article: Annadurai P, Vijaya L. Management of Secondary Angle Closure Glaucoma. *J Current Glau Prac* 2014;8(1):25-32.

Source of support: Nil

Conflict of interest: None

INTRODUCTION

In secondary angle closure glaucoma, the underlying cause can close the angle directly by local iris and angle factors or by acting to move the crystalline lens forward causing pupillary block (secondary pupillary block). This is important since some of these patients with secondary pupillary block will respond to laser iridotomy. They are common causes of glaucoma and can produce high elevations of intraocular pressure (IOP) and ocular morbidity. This review will discuss the risk factors, signs and symptoms, pathophysiology, imaging and the treatment modalities of secondary angle closure glaucomas.

Secondary angle closure glaucoma's can be categorized by the existence of pupillary block or not though some overlap can be seen (Table 1).

Aqueous Misdirection Syndrome

The aqueous misdirection syndrome is a form of secondary angle closure glaucoma occurring postsurgery with raised intraocular pressure (IOP), shallow or flat anterior chamber (AC) in the presence of a patent peripheral iridectomy (PI)¹

(Figs 1A to C). It is unresponsive to miotic or filtering surgery. It can occur after filtering surgery,² cataract³/combined surgery, surgical peripheral iridectomy, following suturelysis,⁴ glaucoma drainage device implantation⁵ or even after laser iridotomy.⁶ The predisposing factors are pre-existing angle closure glaucoma, shallow anterior chamber due to wound leak or overfiltration.

The pathophysiology is not completely understood, but is believed that the primary mechanism is a blockage of anterior aqueous flow at the level of the ciliary body combined with an inherent impermeability defect in the anterior hyaloid.⁷ Recently, choroidal expansion has been proposed as a contributory factor as evidenced by ultrasound biomicroscopy (UBM) studies showing fluid in the suprachoroidal space in some patients with ciliary block glaucomas.⁸

Clinical Features

It is seen in the postoperative period anytime from the 1st day to weeks, sometimes months later. The features are axial shallowing of AC, high IOP or normal IOP in case of functioning blebs, patent PI, closed angle on gonioscopy and ciliary processes can be seen rotated forward pressing against the base of the iris in case of choroidal effusions. UBM shows anterior rotation of ciliary processes pressing against the lens equator (or anterior hyaloid in aphakia).⁹

The principles of treatment are to relieve the obstruction of aqueous flow and restore normal intraocular pressure by medical therapy, to surgically correct the block to aqueous flow, re-establish a normal aqueous flow pathway and drain the aqueous from its abnormal location.

Medical Therapy

Rule out pupillary block by verifying or creating a patent iridectomy/iridotomy. Start mydriatic-cycloplegic therapy¹⁰ consisting of 1% atropine and 5% phenylephrine twice a day in phakic and pseudophakic eyes. This tightens the lens-zonular diaphragm to resist the force from behind and also dilate the ciliary body ring to move the ciliary body away from peripheral anterior hyaloid. Fifty percent success rate has been noted with this therapy. Additionally, topical steroids, aqueous suppressants are used to reduce inflammation and IOP. Osmotics help to lower the IOP as well as to reduce the vitreous volume. Conservative treatment is advised for 5 days to see for resolution.

YAG hyaloidotomy disrupts the anterior hyaloid face allowing aqueous to drain out of the vitreous. It's an elective

¹Associate Consultant, ²Director

^{1,2}Department of Glaucoma, Smt Jadhavbai Nathmal Singhvee Glaucoma Services, Sankara Nethralaya, Chennai, Tamil Nadu India

Corresponding Author: Lingam Vijaya, Director, Smt Jadhavbai Nathmal Singhvee Glaucoma Services, Sankara Nethralaya Chennai-600006, Tamil Nadu, India, e-mail: drlv@snmail.org

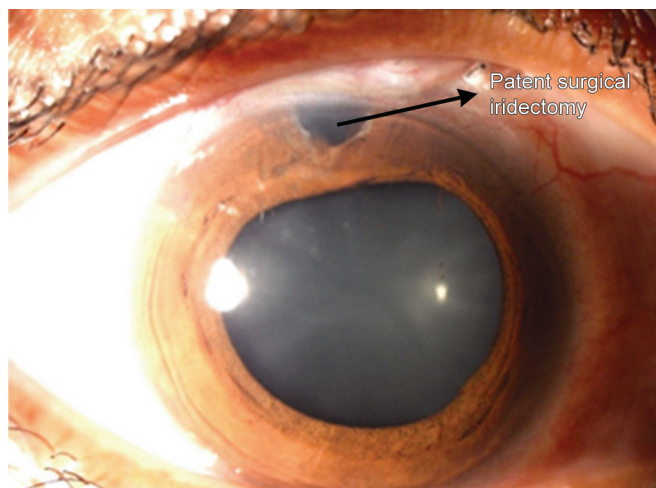


Fig. 1A: Aqueous misdirection post filtering surgery showing a patent surgical iridectomy

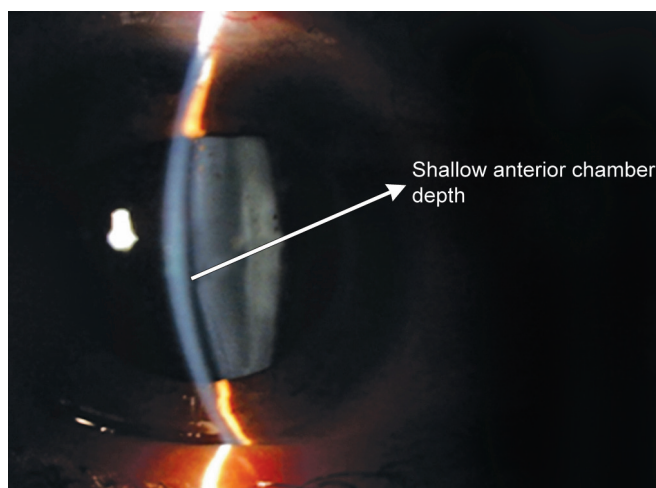


Fig. 1B: Slit photo showing shallow anterior chamber

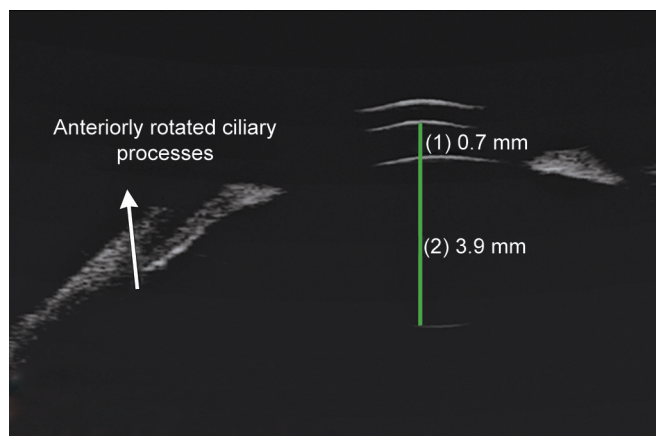


Fig. 1C: UBM showing shallow anterior chamber with anterior rotation of ciliary processes

procedure done in pseudophakics and aphakics through the surgical iridectomy, first perforating the posterior lens capsule and then the hyaloid face. Slight deepening of the anterior chamber is noticeable immediately, dramatic deepening is noticeable after 12 to 24 hours.

Table 1: Classification of secondary angle closure glaucomas

| With pupillary block | Without pupillary block |
|----------------------|--|
| Aqueous misdirection | Neovascular glaucoma |
| | Iridocorneal endothelial syndromes (ICE) |
| | Inflammatory glaucoma |
| | Ciliary body cysts, tumors |
| | Scleral buckling and postvitrectomy procedures |
| | Ciliary body swelling secondary to: |
| | a. Central retinal vein occlusion (CRVO) |
| | b. Panretinal photocoagulation (PRP) |
| | c. Drugs or inflammation |

Surgical Therapy

In cases of medical and laser therapy failure, vitreous surgery almost always cures this condition. The surgery is intended to establish an opening through the anterior hyaloid membrane and the vitreous body for aqueous humour to escape forward to the posterior and anterior chambers. Pars plana vitrectomy^{2,3} is done in pseudophakic and aphakic eyes and IOP control is achieved in 67 to 100% of cases. Vitrectomy-phacoemulsification-vitrectomy¹¹ was studied in 5 phakic eyes, the preliminary vitrectomy was limited to core vitrectomy to debulk the vitreous, the residual vitrectomy, zonulohyaloidectomy and peripheral iridectomy was performed to create a free communication between the anterior and posterior chambers. Cyclo diode laser photocoagulation has also been proposed in patients with failed medical therapy to break the cycle of aqueous misdirection and prevent future recurrences.¹²

YAG PI done preoperatively in occludable eyes can reduce aqueous misdirection. In patients with increased risk like in decompression related shallowing of the anterior chamber, using viscoelastics during surgery, tighter closure and cycloplegics after surgery prevents aqueous misdirection. It must be remembered that recurrence can occur so vigorous follow-up and chronic atropine drops may be necessary. The fellow eye is also at a high-risk for aqueous misdirection.

Neovascular Glaucoma

Neovascular glaucoma (NVG) arises in response to retinal ischemia, the common predisposing factors being central retinal vein occlusion and diabetic retinopathy. An NVG patient requires a broad diagnostic workup to determine the underlying cause¹³ and also a predisposed patient requires careful monitoring to detect NVG in its earliest stages.

The pathogenesis of NVG is retinal ischemia which produces angiogenic factors (VEGF, angiogenin, PDGF, TGF- α , β , TNF- α) which in turn causes new vessel formation on the iris and angle leading to formation of fibrovascular membrane which eventually contracts to form peripheral

anterior synechiae (PAS) and ultimately complete closure of the angle. VEGF levels are elevated to 40 to 100 times normal in aqueous and vitreous of patients with rubeosis and NVG.¹⁴

The clinicopathologic course and treatment may be described in the following stages.¹⁵

Rubeosis Stage (Preglaucoma)

Neovascularization is typically first seen in the pupillary border;¹⁶ however, gonioscopy should be done in all patients under the risk to look for angle neovascularization, since it can precede iris neovascularization.¹⁷ The IOP is usually normal, rubeosis is seen as fine randomly oriented vessels near pupillary border or may be first seen in the angle in diabetic and CRVO patients.¹⁸ Pan retinal photocoagulation (PRP) is indicated which decreases the retinal oxygen demand, thereby reducing the stimulus for release of angiogenesis factors.¹⁹

Open-angle Glaucoma Stage

The rubeosis is more florid in this stage with elevated IOP and open angles with intense neovascularization of the angle. PRP can reverse IOP elevation in this stage. Aqueous suppressants, topical corticosteroids and atropine are used.

Angle Closure Glaucoma Stage

PAS formation can eventually close the angle with ectropion uveae formation resulting in severe glaucoma requiring surgical intervention. PRP is still useful in this stage to reduce IOP if synechial closure is less than 270°²⁰ and even if the angle is closed for more than 270° PRP is useful in reducing anterior segment neovascularization before any surgical intervention.²¹

Filtering surgery is rarely successful because of the risk of bleeding and postoperative progression of fibrovascular membrane. In a study in NVG patients, mitomycin C (MMC) augmented trabeculectomy yielded success rates of 62.6, 58.2 and 51.7% at 1, 2 and 5 years respectively.²² Modified trabeculectomy can be performed with intraocular bipolar cautery of peripheral iris and ciliary processes to prevent bleeding.²³ Intracameral Bevacizumab (avastin)²⁴ has been tried in NVG patients resulting in rapid regression of the iris and angle neovascularization and could act as an adjunct in the surgical treatment of these patients. Preoperative intravitreal bevacizumab combined with mitomycin C augmented trabeculectomy has been studied to be a safe and effective method for controlling IOP in NVG, though long-term effects are not known.²⁵ Even comparative studies between combined intravitreal bevacizumab (IVB) and trabeculectomy with MMC verses trabeculectomy with

mitomycin C alone concluded that IVB significantly reduces postoperative hyphema and controls early postoperative IOP with no difference in long-term results.²⁶

GDSS have gained wide acceptance as a primary procedure for NVG patients because the tube bypasses the fibrovascular membrane. The aqueous tube shunts have reported success rates of 22 to 97% in these patients.^{27,28} Molteno tube shunts²⁹ Ahmed glaucoma valve³⁰ and Baerveldt glaucoma implants³¹ have shown comparable success rates. Successful IOP control was achieved with combined pars plana vitrectomy and glaucoma drainage implant in selected patients with refractory NVG.³²

In eyes with little or no visual potential, treatment is mainly with topical cycloplegics, steroids and aqueous suppressants. Ablation of the ciliary body is undertaken in cases of symptomatic patients. Bloom et al reported a mean IOP reduction of 53% in 25 patients with diode laser for refractory glaucoma.³³ However of note is the study by Ramli et al³⁴ that underlying NVG was a significant risk factor for hypotony post transscleral cyclophotocoagulation. A less aggressive energy setting and a more limited treatment was advised to prevent hypotony.

Iridocorneal Endothelial Syndromes

Iridocorneal endothelial (ICE) syndrome is a spectrum of ocular diseases characterized by corneal endothelial abnormalities, unilateral glaucoma and iris stromal abnormalities.³⁵ They include progressive iris atrophy, Chandler syndrome and Cogan-Reese syndrome (Figs 2A to C). They may be regarded as different manifestations of the same disease process. It is caused by an abnormal corneal endothelium which forms a membrane (ICE membrane) over the anterior surface of the iris and the angle structures, which on contraction distorts the iris, forms peripheral anterior synechiae and closes the angle leading to glaucoma.³⁶ Half of all the patients of ICE syndrome develop glaucoma.³⁷

Management of glaucoma in ICE syndromes is difficult and medical therapy is restricted to aqueous suppressants which is often unsuccessful.³⁸ The success rate of filtering surgery is also lower than most other forms of glaucoma.^{39,40} A study of surgical outcome of trabeculectomy with MMC in 10 ICE syndrome patients showed 8 of 10 patients having adequate IOP control after filtering surgery with mitomycin-C, with a mean follow-up of 14.9 months. The results of their study suggested that trabeculectomy with adjunctive mitomycin-C may offer better intermediate-term success than trabeculectomy alone or trabeculectomy with 5-fluorouracil.⁴¹ Failure of filtering surgery is often due to the continued growth of the endothelial membrane over the filtration site.

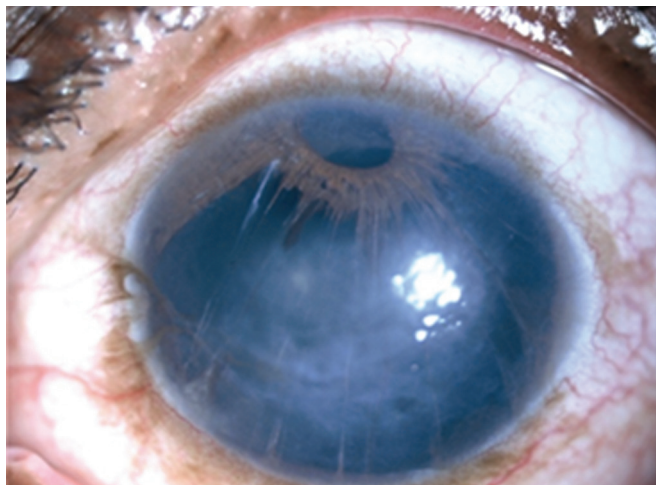


Fig. 2A: Progressive iris atrophy

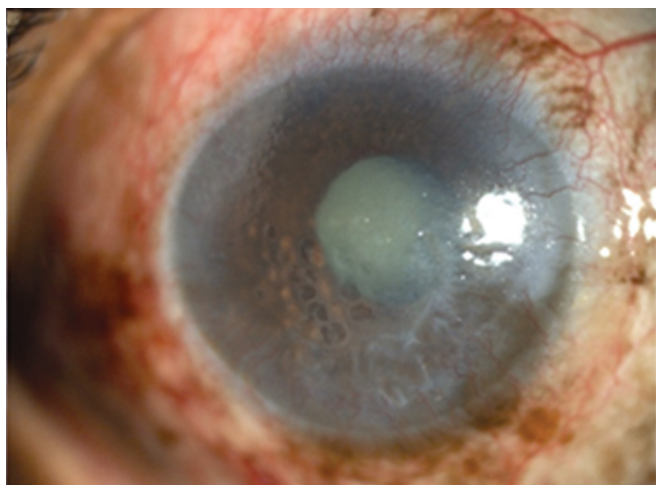


Fig. 2B: Chandler's syndrome

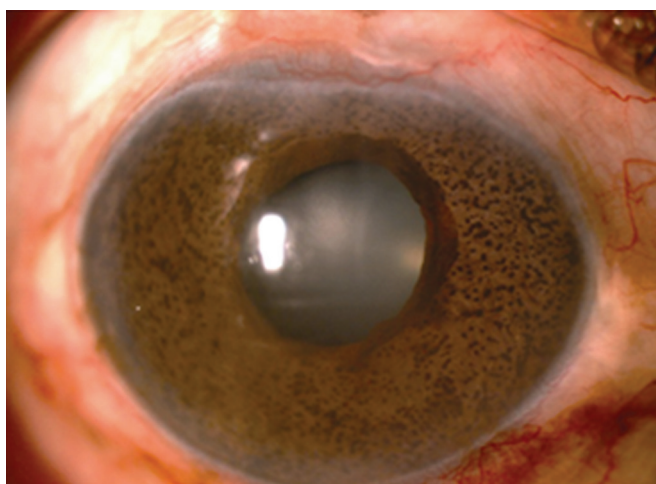


Fig. 2C: Cogan-Reese syndrome

With GDDs the growth of ICE membrane over the ostium is bypassed. A long-term study of 10 patients with ICE syndrome⁴² showed IOP control of less than 21 mm Hg in four patients and in three required tube repositioning due to membrane formation. They proposed that in ICE patients

the tube should be left long in the anterior chamber away from the potential source of ICE cells and entry through pars plana can be used in pseudophakic vitrectomized eyes.

Cyclophotocoagulation is indicated in eyes with refractory glaucoma who have failed trabeculectomy or shunt surgery.

Inflammatory Glaucoma

Glaucoma is a potentially devastating complication of uveitis and remains a therapeutic challenge despite availability of new modalities of treatment in both the conditions.⁴³

Inflammation can produce secondary angle closure glaucoma with pupillary block mechanism due to posterior synechiae formation or without pupillary block due to inflammatory peripheral iris swelling, exudates in the angle contracting to form PAS or due to forward rotation of the ciliary body. PAS form easily in eyes with shallow anterior chamber and in eyes with chronic inflammatory processes.

Inflammatory glaucoma can occur after trauma, surgery, idiopathic inflammatory condition or due to specific uveitic entities.

Principles of Management

Usually control of inflammation alone leads to normalization of IOP. Management of inflammation is done by topical or systemic corticosteroids, mydriatics-cycloplegics and systemic immunosuppressives. Medical therapy to control IOP basically involves aqueous suppressants. Intracameral tissue plasminogen activator has been reported to be of use in impending pupillary block glaucoma due to acute fibrinous HLA-B27 uveitis.⁴⁴

YAG PI is done for pupillary block glaucomas, although fibrin can close small iridotomies in an inflamed eye.⁴⁵ When this is unsuccessful surgical iridectomy is useful if less than 75% of the angle is closed by PAS.⁴⁶

If medical or laser therapy is unable to control the IOP then filtration surgery has to be considered. Trabeculectomy in uveitic eyes generally carries less success due to acceleration of wound healing by postoperative fibrinous and cellular responses.⁴⁷ Antimetabolites like 5FU and Mitomycin C are used to increase the success of trabeculectomy in uveitic eyes (5FU, MMC). A success of 95% (IOP less than 21 mm Hg with 1 or no medication) was achieved with MMC augmented trabeculectomy.⁴⁸ Aggressive anti-inflammatory therapy should be given before and after trabeculectomy in these patients.

All the three glaucoma drainage implants (Molteno, Baerveldt and Ahmed valve) have been tried with a success of 79% with Molteno implants,⁴⁹ 94% with Ahmed valve^{50,51} and 91.7% with Baerveldt implant.⁵²

Trabeculodialysis⁵³ (a modified goniotomy) was studied in children with inflammatory glaucomas with a success of 60%. Goniotomy in chronic childhood uveitis was reported to be successful in 75% of their patients by Freedman et al.⁵⁴

Transscleral diode cyclophotocoagulation is considered in low visual potential eyes; however, the rate of hypotony in uveitis eyes can be higher (19%) than other refractory glaucomas.⁵⁵

Ciliary Body Cysts

Benign iris/ciliary body cysts can cause glaucoma if they are multiple by pushing the peripheral iris forward to close the angle and cause raised intraocular pressure. The onset of glaucoma can mimic acute angle closure glaucoma. It is also called as pseudoplateau iris since it produces a clinical picture identical to plateau iris. Cysts should be suspected when plateau iris configuration appears more in one segment of the angle giving a characteristic bumpy contour to the peripheral iris. They are often multiple and diffusely distributed.⁵⁶ Around 10% of the iris cysts can be because glaucoma associated with or without pupillary block glaucoma. They can be confirmed and their extent can be noted by UBM.⁵⁷

Laser iridotomy,⁵⁸ Argon laser iridoplasty,⁵⁹ Laser cystostomy and intermittent pilocarpine therapy⁶⁰⁻⁶² have been described as therapeutic approaches.

Glaucoma following Scleral Buckling Procedures

Here angle closure glaucoma is produced by swelling of the ciliary body due to impaired venous drainage from the vortex veins by the scleral buckle. The incidence of angle closure glaucoma after scleral buckling procedures range from 1.4 to 4.4%.⁶³ The risk factors are pre-existing narrow angles, use of an encircling band, placement of the band anterior to the equator and high myopia.

It usually resolves spontaneously over several days to weeks. Cycloplegics are used to shift the lens-iris diaphragm posteriorly by relaxing the ciliary muscle and topical steroids to reduce the inflammation. IOP is reduced by means of aqueous suppressants. Miotics should be avoided. Laser PI is not beneficial; rather laser iridoplasty is useful in opening the angle in some of these patients.⁶⁴

GDDs offer an alternative approach in uncontrolled glaucoma as evidenced by the study done by Scott Ingrid U et al with Baerveldt glaucoma implant in eyes with pre-existing episcleral bands where IOP control was achieved in all 16 patients with or without medications during the follow-up period of 19.1 to 45.5 months with none of the usual complications reported with glaucoma drainage devices (GDD).⁶⁵

Intraocular gases have been increasingly used in vitreo-retinal surgeries for tamponade effect on the retinal breaks. The gases used are air, Perfluoropropane (C3F8), sulphur hexafluoride (SF6). SF6⁶⁶ expands to twice its volume within 24 to 48 hours and stays in the eye for 10 to 14 days, C3F8 expands to four times its volume in 48 to 72 hours and stays for 55 to 65 days.⁶⁷ The increase in the volume of the gas causes anterior displacement of the lens-iris diaphragm even when prone position is maintained. The IOP rise is high during the period of maximum expansion of gas. The incidence of IOP elevation with SF6 has been reported to range from 6.1 to 67%, maximum with 100% SF6 and minimum with 20% SF6.⁶⁸ C3F8 causes IOP elevation of 18 to 59%, minimum when 14% of C3F8 is used.⁶⁹ Patients should be instructed to maintain head down position to prevent forward movement of iris lens diaphragm. They should be warned against air travel due to IOP variation during atmospheric changes.⁷⁰

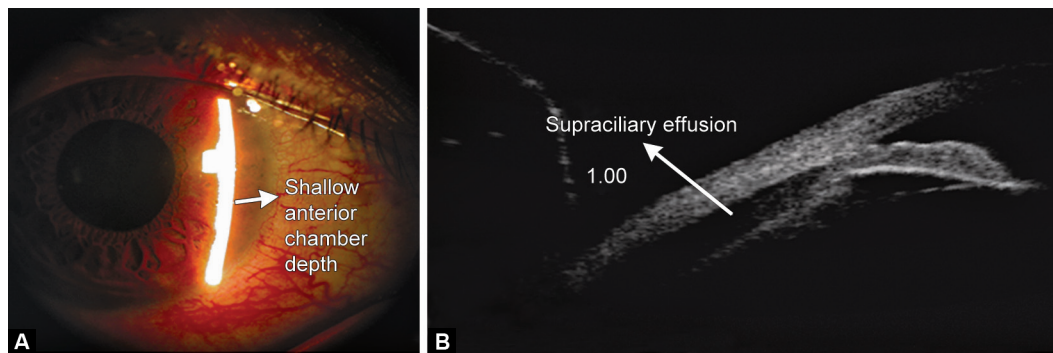
Medical therapy consists of aqueous suppressants. If IOP is not responsive to medical therapy then aspiration of a portion of gas may be performed to lower IOP. Laser PI is useful in pupillary block.

Glaucoma after Silicone Oil Injection

Silicone oil is used as a vitreous substitute for retinal tamponade. It can produce glaucoma by pupillary block, inflammation, synechial closure, neovascularization, migration of oil into anterior chamber or by open angle mechanism. Secondary glaucoma after silicone oil injection has been reported to be in 6 to 30% of eyes.⁷¹ Angle closure glaucoma can occur after silicone oil injection due to synechial closure. Overfilling of the oil in the eye has to be avoided to prevent secondary glaucoma. Inferior prophylactic iridectomy prevents pupillary block in pseudophakic and aphakic eyes. Medical therapy consists of aqueous suppressants, corticosteroids and cycloplegics. Postoperative closed iridectomies due to fibrin can be relieved by laser PI.

Silicone oil removal⁷² with or without concurrent glaucoma surgery has been performed to lower IOP, but oil removal carries some risk of retinal detachment. In patients with complete synechial closure silicone oil removal alone cannot be expected to lower IOP, rather glaucoma surgery is indicated in such cases and the decision to remove silicone oil or not depends on the relative risk of redetachment on oil removal and emulsification of oil.⁷³ If silicone oil remains in the eye, the GDD should be positioned in the inferior quadrant.⁷⁴

Cyclophotocoagulation by transscleral cytophotocoagulation (TSC) or endo cytophotocoagulation (ECP) can be used⁷⁵ in refractory cases. Eyes with relatively intact central



Figs 3A and B: (A) Shallow anterior chamber depth due to topiramate induced angle closure, (B) UBM showing supraciliary effusion following topiramate intake causing secondary angle closure

visual acuity are appropriate candidates for ECP and can be combined with intraocular surgery.⁷⁶

Ciliary Body Swelling

Secondary angle closure glaucoma can occur due to ciliary body (CB) swelling secondary to vortex vein obstruction (venous stasis), drugs or inflammation.

Vortex vein obstruction occurs secondary to extensive PRP or CRVO producing angle closure glaucoma similar to scleral buckling procedures. It is a self limiting condition and will resolve with or without medical therapy. Laser PI has no role in this condition.

Ciliary body swelling secondary to drug use is an idiosyncratic reaction causing relaxation of zonules, anterolateral rotation of the ciliary body leading to anterior displacement of iris—lens diaphragm producing induced myopia. Choroidal detachment and supraciliary effusions are frequently present detected by UBM. Sulfa-based drugs are associated with this type of secondary angle closure glaucomas like topiramate⁷⁷ (Figs 3A and B), acetazolamide,⁷⁸ hydrochlorothiazide and contrimoxazole. It presents as bilateral angle closure glaucoma. The management requires stopping of the drug, instituting aqueous suppressants and cycloplegics.⁷⁹ Miotics, topical and systemic carbonic anhydrase inhibitors are contraindicated and laser PI has no role.

CONCLUSION

Secondary angle closure glaucomas require meticulous history taking, clinical examination, if necessary anterior segment imagings like UBM to identify the specific cause if possible and formulate a treatment plan to avoid ocular morbidity.

REFERENCES

- Luntz MH, Rosenblatt M. Malignant glaucoma. *Surv Ophthalmol* 1987 Sep-Oct;32(2):73-93.
- Harbour JW, Rubsam PE, Palmberg P. Pars plana vitrectomy in the management of phakic and pseudophakic malignant glaucoma. *Arch Ophthalmol* 1996 Sep;114(9):1073-1078.
- Lynch MG, Brown RH, Michels RG, Pollack IP, Stark WJ. Surgical vitrectomy for pseudophakic malignant glaucoma. *Am J Ophthalmol* 1986 Aug;102(2):149-153.
- DiSclafani M, Liebmann JM, Ritch R. Malignant Glaucoma following argon laser release of scleral flap sutures after trabeculectomy. *Am J Ophthalmol* 1989 Nov;108(5):597-598.
- Greenfield DS, Tello C, Budenz DL, Liebmann JM, Ritch R. Aqueous misdirection after glaucoma drainage device implantation. *Ophthalmology* 1999 May;106(5):1035-1040.
- Cashwell LF, Martin TJ. Malignant glaucoma after laser iridotomy. *Ophthalmology* 1992 May;99(5):651-659.
- Epstein, DL. The malignant glaucoma syndromes. In: Epstein DL, Allingham RR, Schuman JS, editors. *Chandler and Grant's Glaucoma*. 4th ed. Baltimore: Williams & Wilkins; 1997. p. 285-303.
- Lieberman, MF.; Lee, DA. Diagnosis and management of malignant glaucoma. In Higginbotham EJ, Lee DA, editors. *Clinical guide to glaucoma management*, Woburn, MA, Butterworth Heinemann/ Elsevier, 2004.
- Trope GE, Pavlin CJ, Bau A, Baumal CR, Foster FS. Malignant glaucoma: Clinical and ultrasound biomicroscopic features. *Ophthalmology* 1994 Jun;101(6):1030-1335.
- Chandler PA, Grant WM. Mydriatic-cycloplegic treatment in malignant glaucoma. *Arch Ophthalmol* 1962 Sep;68:353-359.
- Sharma A, Sii F, Shah P, Kirkby GR. Vitrectomy-phacoemulsification-vitrectomy for the management of aqueous misdirection syndromes in phakic eyes. *Ophthalmology* 2006 Nov;113(11):1968-1973.
- Stumpf TH, Austin M, Bloom PA, McNaught A, Morgan JE. Transscleral cyclodiode laser photocoagulation in the treatment of aqueous misdirection syndrome. *Ophthalmology* 2008 Nov;115(11):2058-2061.
- Sivak-Callcott JA, O'Day DM, Gass JD, Tsai JC. Evidence-based recommendations for the diagnosis and treatment of neovascular glaucoma. *Ophthalmology* 2001 Oct;108(10):1767-1776.
- Tripathi RC, Li J, Tripathi BJ, Chalam KV, Adamis AP. Increased level of vascular endothelial growth factor in aqueous humour of patients with neovascular glaucoma. *Ophthalmology* 1998 Feb;105(2):232-237.
- Allingham, RR.; Karim, F.; Sharon DF, et al. *Shields Textbook of Glaucoma*. New Delhi, India: Wolters Kluwer Pvt Ltd; 2011. Chapter 19, Glaucoma associated with disorder of the retina, vitreous and choroid,
- Browning DJ. Risk of missing angle neovascularization by omitting angle screening gonioscopy in patients with diabetes mellitus. *Am J Ophthalmol* 1991 Aug 15;112(2):212.

17. Blinder KJ, Friedman SM, Mames RN. Diabetic iris neovascularization. *Am J Ophthalmol* 1995 Sep;120(3):393-395.
18. Browning DJ, Scott AQ, Peterson CB, Warnock J, Zhang Z. The risk of missing angle neovascularization by omitting angle screening gonioscopy in acute central retinal vein occlusion. *Ophthalmology* 1998 May;105(5):776-784.
19. Little HL, Rosenthal AR, Dellaporta A, Jacobson DR. The effect of pan-retinal photo-coagulation on rubeosis iridis. *Am J Ophthalmol* 1976 Jun;81(6):804-809.
20. Flanagan DW, Blach RK. Place of panretinal photocoagulation and trabeculectomy in the management of neovascular glaucoma. *Br J Ophthalmol* 1983 Aug;67(8):526-528.
21. Goodart R, Blankenship G. Panretinal photocoagulation influence on vitrectomy results for complications of diabetic retinopathy. *Ophthalmology* 1980 Mar;87(3):183-188.
22. Takihara Y, Inatani M, Fukushima M, Iwao K, Iwao M, Tanihara H. Trabeculectomy with mitomycin C for neovascular glaucoma: prognostic factors for surgical failure. *Am J Ophthalmol* 2009 May;147(5):912-918.
23. Herschler J, Agness D. A modified filtering operation for neovascular glaucoma. *Arch Ophthalmol* 1979 Dec;97(12):2339-2341.
24. Duch S, Buchacra O, Milla E, Andreu D, Tellez J. Intracameral bevacizumab (Avastin) for neovascular glaucoma: a pilot study in 6 patients. *J Glaucoma* 2009 Feb;18(2):140-143.
25. Fakhraie G, Katz JL, Prasad A, Eslami Y, Sabour S, Zarei R, Moghimi S. Surgical outcomes of intravitreal bevacizumab and guarded filtration surgery in neovascular glaucoma. *J Glaucoma* 2010 Mar;19(3):212-218.
26. Takihara Y, Inatani M, Kawaji T, Fukushima M, Iwao K, Iwao M, Tanihara H. Combined intravitreal bevacizumab and trabeculectomy with mitomycin C versus trabeculectomy with mitomycin C alone for neovascular glaucoma. *J Glaucoma* 2011 Mar;20(3):196-201.
27. Hong CH, Arosemena A, Zurakowski D, Ayyala RS. Glaucoma drainage devices: a systematic literature review and current controversies. *Surv Ophthalmol* 2005 Jan-Feb;50(1):48-60.
28. Assaad MH, Baerveldt G, Rockwood EJ. Glaucoma drainage devices: pros and cons. *Curr Opin Ophthalmol* 1999 Apr;10(2):147-153.
29. Mermoud A, Salmon JF, Alexander P, Straker C, Murray AD. Molteno tube implantation for neovascular glaucoma. Long-term results and factors influencing the outcome. *Ophthalmology* 1993 Jun;100(6):897-902.
30. Park UC, Park HK, Kim MD, Yu HG. Ahmed glaucoma valve implantation for neovascular glaucoma after vitrectomy for proliferative diabetic retinopathy. *J Glaucoma* 2011 Sep;20(7):433-438.
31. Sidoti PA, Dunphy TR, Baerveldt G, LaBree L, Minckler DS, Lee PP, Heuer DK. Experience with the Baerveldt glaucoma implant in treating neovascular glaucoma. *Ophthalmology* 1995 Jul;102(7):1107-1118.
32. Scott IU, Alexandrakis G, Flynn HW Jr, Smiddy WE, Murray TG, Schiffman J, Gedde SJ, Budenz DL, Fantes F, Parrish RK. Combined pars plana vitrectomy and glaucoma drainage implant placement for refractory glaucoma. *Am J Ophthalmol* 2000 Mar;129(3):334-341.
33. Bloom PA, Tsai JC, Sharma K, Miller MH, Rice NS, Hitchings RA, Khaw PT. "Cyclodiode". Trans-scleral diode laser cyclophotocoagulation in the treatment of advanced refractory glaucoma. *Ophthalmology* 1997 Sep;104(9):1508-1520.
34. Ramli N, Htoon HM, Ho CL, Aung T, Perera S. Risk factors for hypotony after transscleral diode cyclophotocoagulation. *J Glaucoma* 2012 Mar;21(3):169-173.
35. Eagle RC Jr, Font RL, Yanoff M, Fine BS. Proliferative endotheliopathy with iris abnormalities. The iridocorneal endothelial syndrome. *Arch Ophthalmol* 1979 Nov;97(11):2104-2111.
36. Campbell DG, Shields MB, Smith TR. The corneal endothelium and the spectrum of essential iris atrophy. *Am J Ophthalmol* 1978 Sep;86(3):317-324.
37. Laganowski HC, Kerr Muir MG, Hitchings RA. Glaucoma and the iridocorneal endothelial syndrome. *Arch Ophthalmol* 1992 Mar;110(3):346-350.
38. Patel A, Kenyon KR, Hirst LW, Quigley HA, Stark WJ, Meyer RF, Green WR. Clinicopathologic features of Chandler's syndrome. *Surv Ophthalmol* 1983 Mar-Apr;27(5):327-344.
39. Kidd M, Hetherington J, Magee S. Surgical results in Iridocorneal endothelial syndrome. *Arch Ophthalmol* 1988 Feb;106(2):199-201.
40. Wright MM, Grajewski AL, Cristol SM, Parrish RK. 5-Fluorouracil after trabeculectomy and the iridocorneal endothelial syndrome. *Ophthalmology* 1991 Mar;98(3):314-316.
41. Lanzl IM, Wilson RP, Dudley D, Augsburger JJ, Aslanides IM, Spaeth GL. Outcome of trabeculectomy with mitomycin-C in the iridocorneal endothelial syndrome. *Ophthalmology* 2000 Feb;107(2):295-297.
42. Kim DK, Aslanides IM, Schimdt CM Jr, Spaeth GL, Wilson RP, Augsburger JJ. Long-term outcome of aqueous shunt surgery in 10 patients with iridocorneal endothelial syndrome. *Ophthalmology* 1999 May;106(5):1030-1034.
43. Moorthy RS, Mermoud A, Baerveldt G, Minckler DS, Lee PP, Rao NA. Glaucoma associated with uveitis. *Surv Ophthalmol* 1997 Mar-Apr;41(5):361-394.
44. Skolnick CA, Fiscella RG, Tessler HH, Goldstein DA. Tissue plasminogen activator to treat impending pupillary block glaucoma in patients with acute fibrinous HLA-B27 positive iridocyclitis. *Am J Ophthalmol* 2000 Mar;129(3):363-366.
45. Schwartz LW, Moster MR, Spaeth GL, Wilson RP, Poryzees E. Neodymium-YAG laser iridectomies in glaucoma associated with closed or occludable angles. *Am J Ophthalmol* 1986 Jul;102(1):41-44.
46. Kanski, JJ.; McAllister, JA. Glaucoma associated with uveitis diagnosis and therapy. In: Cairns JE, editor. *Glaucoma*. Vol. 11. London: Grune and Stratton; 1986. p. 851-859.
47. Skuta GL, Parrish RK 2nd. Wound healing in glaucoma filtering surgery. *Surv Ophthalmol* 1987 Nov-Dec;32(3):149-170.
48. Prata JA Jr, Neves RA, Minckler DS, Mermoud A, Heuer DK. Trabeculectomy with mitomycin C in glaucoma associated with uveitis. *Ophthalmic Surg* 1994 Sep-Oct;25(9):616-620.
49. Hill RA, Nguyen QH, Baerveldt G, Forster DJ, Minckler DS, Rao N, Lee M, Heuer DK. Trabeculectomy and Molteno implantation for glaucomas associated with uveitis. *Ophthalmology* 1993 Jun;100(6):903-908.
50. Gil-Carrasco F, Salinas-VanOrman E, Recillas-Gispert C, Paczka JA, Gilbert ME, Arellanes-García L. Ahmed valve implant for uncontrolled uveitic glaucoma. *Ocul Immunol Inflamm* 1998 Mar;6(1):27-37.
51. Da Mata A, Burk SE, Netland PA, Baltatzis S, Christen W, Foster CS. Management of uveitic glaucoma with Ahmed glaucoma valve implantation. *Ophthalmology* 1999 Nov;106(11):2168-2172.

52. Ceballos EM, Parrish RK 2nd, Schiffman JC. Outcome of Baerveldt glaucoma drainage implants for the treatment of uveitic glaucoma. *Ophthalmology* 2002 Dec;109(12):2256-2260.
53. Kanski JJ, McAllister JA. Trabeculodialysis for inflammatory glaucoma in children and young adults. *Ophthalmology* 1985 Jul;92(7):927-930.
54. Freedman SF, Rodriguez-Rosa RE, Rojas MC, Enyedi LB. Goniotomy for glaucoma secondary to chronic childhood uveitis. *Am J Ophthalmol* 2002 May;133(5):617-621.
55. Murphy CC, Burnett CA, Spry PG, Broadway DC, Diamond JP. A two centre study of the dose-response relation for transscleral diode laser cyclophotocoagulation in refractory glaucoma. *Br J Ophthalmol* 2003 Oct;87(10):1252-1257.
56. Azuara-Blanco A, Spaeth GL, Araujo SV, Augsburger JJ, Terebuh AK. Plateau iris syndrome associated with multiple ciliary body cysts. Report of three cases. *Arch Ophthalmol* 1996 Jun;114(6):666-668.
57. Ritch R, Liebmann JM. Role of ultrasound biomicroscopy in the differentiation of block glaucomas. *Curr Opin Ophthalmol* 1998 Apr;9(2):39-45.
58. Bron AJ, Wilson CB, Hill AR. Laser treatment of primary ring-shaped epithelial iris cyst. *Br J Ophthalmol* 1984 Dec;68(12):859-865.
59. Crowston JG, Medeiros FA, Mosaed S, Weinreb RN. Argon laser iridoplasty in the treatment of plateau-like iris configuration as result of numerous ciliary body cysts. *Am J Ophthalmol* 2005 Feb;139(2):381-383.
60. Lois N, Shields CL, Shields JA, Mercado G. Primary cysts of the iris pigment epithelium. Clinical features and natural course in 234 patients. *Ophthalmology* 1998 Oct;105(10):1879-1885.
61. Vela A, Rieser JC, Campbell DG. The heredity and treatment of angle-closure glaucoma secondary to iris and ciliary body cysts. *Ophthalmology* 1984 Apr;91(4):332-337.
62. Kuchenbecker J, Motschmann M, Schmitz K, Behrens-Baumann W. Laser iridocystotomy for bilateral acute angle-closure glaucoma secondary to iris cysts. *Am J Ophthalmol* 2000 Mar;129(3):391-393.
63. Kreiger AE, Hodgkinson BJ, Frederick AR Jr, Smith TR. The results of retinal detachment surgery. Analysis of 268 operations with a broad scleral buckle. *Arch Ophthalmol* 1971 Oct;86(4):385-394.
64. Burton TC, Folk JC. Laser iris retraction for angle-closure glaucoma after retinal detachment surgery. *Ophthalmology* 1988 Jun;95(6):742-748.
65. Scott IU, Gedde SJ, Budenz DL, Greenfield DS, Flynn HW Jr, Feuer WJ, Mello MO Jr, Krishna R, Godfrey DG. Baerveldt drainage implants in eyes with a preexisting scleral buckle. *Arch Ophthalmol* 2000 Nov;118(11):1509-1513.
66. Chang, S. Intraocular gases. In: Ryan SJ, editor. *Retina*. St Louis, MO: Mosby; 1994. p. 2115-2129.
67. Lincoff A, Haft D, Liggett P, Reifer C. Intravitreal expansion of perfluorocarbon bubbles. *Arch Ophthalmol* 1980 Sep;98(9):1646.
68. Lean JS, Boone DC, Azen SP, et al. Vitrectomy with silicone oil or sulfur hexafluoride gas in eyes with severe proliferative vitreoretinopathy: Results of a randomized clinical trial. Silicone Study Report 1. *Arch Ophthalmol* 1992 Jun;110(6):770-779.
69. McCuen B, Azen SP, Boone DC, et al. Vitrectomy with silicone oil or perfluoropropane gas in eyes with severe proliferative vitreoretinopathy: results of a randomized clinical trial. Silicone Study Report 2. *Arch Ophthalmol* 1992 Jun;110(6):780-792.
70. Mills MD, Devenyi RG, Lam WC, Berger AR, Beijer CD, Lam SR. An assessment of intraocular pressure rise in patients with gas-filled eyes during simulated air flight. *Ophthalmology* 2001 Jan;108(1):40-44.
71. Honavar SG, Goyal M, Majji AB, Sen PK, Naduvilath T, Dandona L. Glaucoma after pars plana vitrectomy and silicone oil injection for complicated retinal detachments. *Ophthalmology* 1999 Jan;106(1):169-177.
72. Budenz DL, Taba KE, Feuer WJ, Eliezer R, Cousins S, Henderer J, Flynn HW Jr. Surgical management of secondary glaucoma after pars plana vitrectomy and silicone oil injection for complex retinal detachment. *Ophthalmology* 2001 Sep;108(9):1628-1632.
73. Nguyen QH, Lloyd MA, Heuer DK, Baerveldt G, Minckler DS, Lean JS, Liggett PE. Incidence and management of glaucoma after intravitreal silicone oil injection for complicated retinal detachments. *Ophthalmology* 1992 Oct;99(10):1520-1526.
74. Gedde SJ. Management of glaucoma after retinal detachment surgery. *Curr Opin Ophthalmol* 2002 Apr;13(2):103-109.
75. Lima FE, Magacho L, Carvalho DM, Susanna R Jr, Avila MP. A prospective, comparative study between endoscopic cytophotocoagulation and the Ahmed drainage implant in refractory glaucoma. *J Glaucoma* 2004 Jun;13(3):233-237.
76. Uram M. Combined phacoemulsification, endoscopic ciliary process photocoagulation and intraocular lens implantation in glaucoma management. *Ophthalmic Surg* 1995 Jul-Aug;26(4):346-352.
77. Fraunfelder FW, Fraunfelder FT, Keates EU. Topiramate-associated acute, bilateral, secondary angle-closure glaucoma. *Ophthalmology* 2004 Jan;111(1):109-111.
78. Narayanaswamy AK, Antrolkar M, Vijaya L. Acetazolamide-induced glaucoma. *Asian J Ophthalmol* 2007;9(5):213-215.
79. Lachkar Y, Bouassida W. Drug-induced acute angle closure glaucoma. *Curr Opin Ophthalmol* 2007 Mar;18(2):129-133.